

Access this article online

Quick Response Code:



Website:

http://www.braincirculation.org

DOI:

10.4103/bc.bc\_49\_21

# Flow diversion in anterior cerebral artery aneurysms

Katarina Dakay, Jared Blaine Cooper, Jacob D. Greisman<sup>1</sup>, Gurmeen Kaur, Fawaz Al-Mufti, Chirag D. Gandhi, Justin G. Santarelli

## Abstract:

**INTRODUCTION:** Anterior cerebral artery (ACA) aneurysms are commonly encountered in clinical practice but can be challenging to treat. Flow diversion is a viable treatment in this population.

**METHODS:** We retrospectively evaluated patients treated at our center from May 2017 to December 2020 who underwent flow diversion for an ACA aneurysm at or distal to the anterior communicating artery (ACOM). We defined ACA aneurysms as any aneurysm involving the ACOM itself, at the junction of the ACA with the ACOM (A1/A2), or in distal A2/A3 branches; both ruptured and unruptured aneurysms were included. Baseline and follow-up clinical and angiographic data were collected; the primary measure was elimination of the aneurysm on follow-up angiogram. Patients underwent flow diversion with a Pipeline stent. A single flow diverting stent was placed in the dominant ACA spanning from the A2 segment extending into the A1 segment; two patients required H-pipe technique. Distal aneurysms were treated with a single Pipeline device deployed across the parent vessel, covering the aneurysm.

**RESULTS:** Two-seven patients underwent a total of 28 flow diversion procedures; median age was 57 and 16 (59.3%) were male. Thirteen (48.2%) patients presented with subarachnoid hemorrhage; of these, four were treated within 6 weeks of the index hemorrhage. Most patients (22; 81.5%) had significant ACA asymmetry. There was one postoperative intracerebral hemorrhage and one groin complication. Follow-up data were available for 19 patients, 15 (78.9%) of which showed no residual aneurysm and 17 (89.5%) had protection of the dome.

**CONCLUSION:** Flow diversion of ACA aneurysms can be a primary treatment modality in an unruptured aneurysm or a complement to initial coil protection of a ruptured aneurysm. Further studies are needed to confirm these results.

## Keywords:

Aneurysm, anterior communicating artery, endovascular treatment, flow diversion, Pipeline

Department of  
Neurosurgery,  
Westchester Medical  
Center, New York Medical  
College, <sup>1</sup>Department of  
Neurosurgery, New York  
Medical College, Valhalla,  
New York, USA

## Address for correspondence:

Dr. Justin G. Santarelli,  
Department of  
Neurosurgery, New York  
Medical College, 100  
Woods Rd., Valhalla, NY  
10595, USA.  
E-mail: justin.santarelli@  
wmchealth.org

Submission: 23-06-2021  
Revised: 22-07-2021  
Accepted: 23-08-2021  
Published: 21-12-2021

## Introduction

The anterior cerebral artery (ACA) is a common location for aneurysm formation, particularly at the anterior communicating artery (ACOM); the latter has been shown to confer a higher risk of rupture as compared to other locations in the anterior circulation,<sup>[1,2]</sup> thus, treatment is often offered for smaller, unruptured aneurysms. It has been suggested that treatment should be offered for unruptured

This is an open access journal, and articles are distributed under the terms of the Creative Commons Attribution-NonCommercial-ShareAlike 4.0 License, which allows others to remix, tweak, and build upon the work non-commercially, as long as appropriate credit is given and the new creations are licensed under the identical terms.

For reprints contact: WKHLRPMedknow\_reprints@wolterskluwer.com

anterior communicating aneurysms measuring >4 mm,<sup>[3]</sup> in the absence of complicating factors. Endovascular coiling is commonly employed in the treatment of intracranial aneurysms; however, coil embolization can be technically challenging in many cases due to small aneurysm dome size, presence of multiple perforating vessels, and superior or posterior dome orientation.<sup>[4,5]</sup> Stent-assisted coiling may allow for placement of coils in broad-based aneurysms, however, is associated with a higher treatment morbidity than coiling alone.<sup>[5]</sup> Flow diversion, which allows for redirection of flow away from the aneurysm

**How to cite this article:** Dakay K, Cooper JB, Greisman JD, Kaur G, Al-Mufti F, Gandhi CD, *et al.* Flow diversion in anterior cerebral artery aneurysms. *Brain Circ* 2021;7:247-52.

and through the treated parent vessel, leads to gradual endothelialization and thrombosis with subsequent occlusion of the aneurysm. Flow diversion has been well described in the treatment of proximal anterior circulation aneurysms<sup>[6]</sup> but is less studied for more distal aneurysms such as those affecting the circle of Willis and ACOM complex. We describe a single-center case series of patients who underwent flow diversion for ACOM aneurysms at our center.

## Methods

### Data collection

We retrospectively evaluated all patients treated at our center from May 2017 to December 2020 who underwent flow diversion for an ACA aneurysm. The study was approved by the Westchester Medical Center Institutional Review Board. We defined ACA aneurysms as any aneurysm involving the ACOM itself, at the junction of the ACA with the ACOM (A1/A2), or in distal A2/A3 branches; both ruptured and unruptured aneurysms were included. We collected baseline clinical and demographic data and angiographic data from both pre- and posttreatment imaging when available; the primary measure was complete occlusion of the aneurysm on follow-up angiogram, defined as no residual filling of either neck or dome of the aneurysm. Parent vessel stenosis and peri-procedural complications were collected as secondary outcomes.

### Treatment

Patients underwent flow diversion with a Pipeline stent under general anesthesia; the procedure was performed under transfemoral access with an 8Fr 45 cm sheath using the Cook shuttle (Cook Medical) as the guide catheter, with the Phenom Plus (Medtronic) as the intermediate and the Phenom 027 microcatheter (Medtronic) for distal access. The Navien (Medtronic) intermediate catheter was used in lieu of the Phenom Plus in a minority of cases. A single flow diverting stent was placed in the dominant ACA spanning from the A2 segment extending into the A1 segment in a majority of cases; one case utilized two stents for an H-pipe technique. Patients with an azygous ACA or absence of one of the A1 segments were not treated with Pipeline due to the necessity of preserving flow across the ACOM in this instance. Aneurysms distal to the ACOM were treated with a single Pipeline device deployed across the parent vessel, covering the aneurysm.

Patients with ruptured aneurysms were treated with flow diversion on a delayed basis several weeks after the subarachnoid hemorrhage after initial coiling to protect the rupture point; patients must have had serial CTs demonstrating resolving/stable hemorrhage, discontinuation of their external ventricular drain, and

angiographic runs must demonstrate no evidence of significant parent vessel vasospasm prior to flow diversion treatment. Patients with large or significant hematoma volume received treatment in a delayed fashion, several days or weeks after the initial hemorrhage, at the discretion of the treating neurosurgeon. We defined treatment within the acute to early subacute window as within 6 weeks of the causative subarachnoid hemorrhage; data regarding hydrocephalus and vasospasm incidence were collected for these patients. Admitted patients receiving flow diversion as an adjunctive treatment for a previously ruptured aneurysm were typically given a loading dose of 650 mg of aspirin and 300 mg of clopidogrel at least 12 h prior to the procedure; patients being treated electively began taking 325 mg of aspirin and 75 mg of clopidogrel beginning 5–7 days prior to the procedure. Intraoperative assays (VerifyNow) were checked prior to placement of the flow diverting stent to ensure therapeutic status. Dual antiplatelet therapy was continued for a minimum of 6 months following the flow diverting stent, with longer courses for patients with evidence of intimal hyperplasia or stenosis on their follow-up angiogram.

### Imaging interpretation

Follow-up angiogram was performed at approximately 6 months after flow diversion treatment, with a second follow-up angiogram at 1 year posttreatment. Occlusion was defined as no evidence of residual filling of either the dome or neck of the aneurysm and collected as a binary variable. Complete occlusion was defined as no filling of the aneurysm on arterial, capillary, or venous phases. The aneurysm was considered protected if there was either complete occlusion or filling confined to an entry remnant, defined as a trace neck remnant with no filling of the body or dome. Residual aneurysmal filling was assessed on both the ipsilateral and the contralateral internal carotid artery angiogram.

## Results

### Baseline demographics

A total of 28 procedures were performed on 27 patients during the study period [Table 1]. The median age was 57 and 16 were male. Thirteen patients presented with subarachnoid hemorrhage, and 14 were unruptured. Of the patients with ruptured aneurysms, four were treated within the acute to early subacute period, which we defined as within 6 weeks of the causative subarachnoid hemorrhage; time to treatment ranged from 1 day to 49 days with a median of 19.5 days. The remainder of the patients were treated >6 weeks from the subarachnoid hemorrhage, with a median time to treatment of 141 days (range, 91–203).

Of the 4 patients with ruptured aneurysms who were treated in the acute to early subacute period, two

developed symptomatic vasospasm which was medically managed in both cases without the need for angioplasty. Two patients required an external ventricular drain on admission; however, neither patient required permanent cerebrospinal fluid diversion. Both patients who required an external ventricular drain were treated with flow diversion only after successful weaning and removal of the drain.

The median aneurysm size was 4 mm, with a range from 1.5 to 15 mm. Most patients had significant ACA asymmetry with a significant caliber difference between the A1 segments (22; 81.5%). In most cases of asymmetry, the left A1 was dominant. Thirteen patients (48.2%) had been previously treated with aneurysmal recurrence or residual.

### Treatment

In 25 (92.6%) patients, a single flow diverting stent was utilized; one patient underwent bilateral A2 to A1 Pipeline utilizing the “H-pipe” technique on the initial procedure and a second patient underwent staged H-pipe treatment. Procedural success was achieved in 100% of patients. There was one peri-operative access site complication requiring surgical intervention. There was one peri-operative case of intracerebral hemorrhage (ICH) that was managed by decompressive craniectomy and hematoma evacuation. No cases of intraoperative thrombosis or stroke were observed.

### Follow-up data

Of 27 patients, one patient was lost to follow-up and one patient died after a prolonged hospital course. Six patients were pending follow-up angiogram at the time of this manuscript. Follow-up angiogram data were available for 19 patients [Table 2], with a median time of 7.5 months. Due to the COVID-19 pandemic, follow-up angiogram was delayed in some patients.

Of the 19 patients, 15 (78.9%) patients exhibited complete elimination of the aneurysm and 17 (89.5%) had protection of the dome; an example is provided in Figure 1. Of the four patients with residual filling, one had a relatively larger sized aneurysm measuring 9 mm and one underwent a fairly early follow-up angiogram at 3 months postflow diversion. The third patient had a complex pericallosal A2/A3 aneurysm with trace, static neck residual on the last follow-up angiogram. Finally, one patient continued to have filling from the contralateral ACA. The patient who underwent staged H-pipe treatment had successful complete occlusion of the aneurysm on follow-up angiogram.

Six patients demonstrated mild narrowing/intimal hyperplasia of the parent vessel on follow-up angiogram; however, no patients had hemodynamically significant

**Table 1: Baseline and clinical features**

Demographics and treatment characteristics	n (%); median (range)
Male	16 (59.3)
Age	57 (38-85)
Ruptured	13 (48.2)
Previously coiled	13 (48.2)
Location of aneurysm	
ACOM	15 (55.5)
Left A1/A2	9 (33.3)
Right A1/A2	2 (7.4)
A2/A3 pericallosal	1 (3.7)
Median aneurysm size (mm)	4 (1.5-15)
ACA asymmetry	22 (81.5)
Ipsilateral A1/A2 technique	25 (92.6)
H-pipe technique	2 (7.4)
Overall complications	2 (7.4)
Groin complication	1 (3.7)
Intracerebral hemorrhage	1 (3.7)
Mortality	1 (3.7)
Subarachnoid hemorrhage after treatment	0
Follow-up angiogram	20 (74.1)

ACOM: Anterior communicating artery, ACA: Anterior cerebral artery

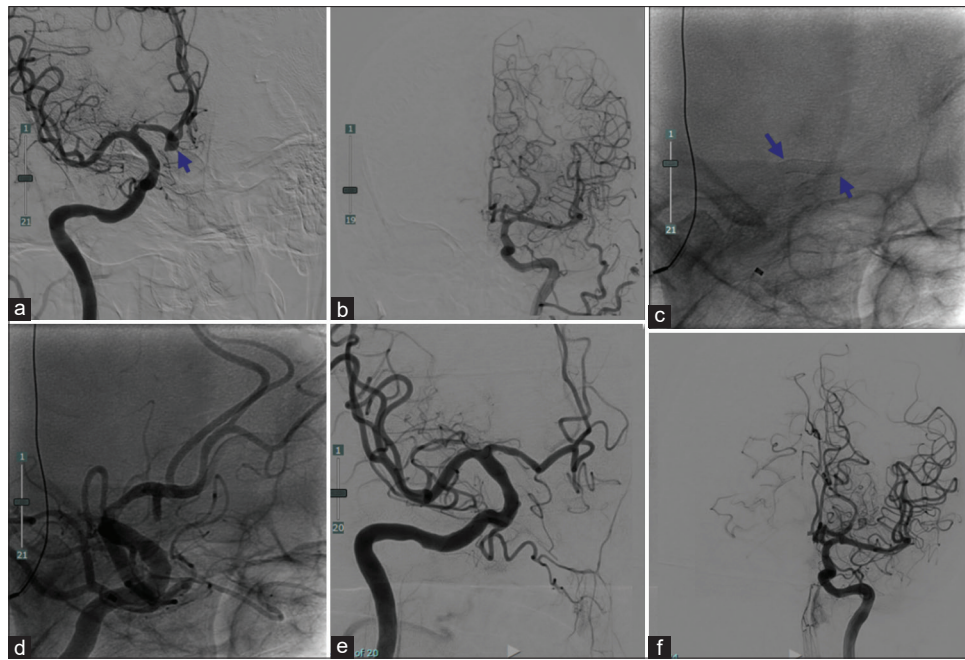
**Table 2: Follow-up data (n=19)**

	n (%)
Treatment to most recent angiogram (months)	7.5 (3-20)
Total occlusion	15 (78.9)
Entry remnant	2 (3.7)
Subtotal filling	0
Total filling	2 (7.4)
Intimal hyperplasia	6 (22.2)
Protection of dome	18 (95.7)

stenosis or occlusion of the parent vessel on follow-up. There were no reported cases of interval subarachnoid hemorrhage following Pipeline treatment to date to the time of writing this manuscript.

## Discussion

Flow diversion can be a durable and effective treatment for ACA aneurysms. Advantages of this method as primary treatment include avoiding the risk of microcatheterization of small aneurysms, which entails a rupture risk, particularly in aneurysms with a small dome.<sup>[7]</sup> In addition, the use of a flow diverting stent avoids the risk of coil compaction or migration and allows for the treatment of aneurysms which may not otherwise be amenable to coiling due to broad-necked or irregular morphology. Flow diversion can be useful as a treatment for recurrent or residual aneurysms after coiling; in patients with previously ruptured aneurysms where coil embolization may have been incomplete due to preservation of branches or perforators, flow diversion can be employed as a delayed treatment to eliminate



**Figure 1:** Patient example of flow diversion of an anterior communicating artery aneurysm. (a) pretreatment angiogram shows the aneurysm filling the right internal carotid artery; (b) left internal carotid artery shows no filling of the anterior communicating artery or aneurysm via the left internal carotid artery; (c) single shot shows deployment of the flow diverting stent spanning from the right A2 to A1; (d) shows immediate poststent deployment angiogram; (e) elimination of the aneurysm on follow-up angiogram; (f) increased caliber and territory of the left anterior cerebral artery territory after right anterior cerebral artery pipeline

the aneurysm. Major considerations associated with flow diversion include the need for dual antiplatelet therapy for several months as well as lifelong aspirin; in patients who present initially with rupture, we waited a period of several weeks prior to flow diverting a remnant or recurrent aneurysm until the risk of dual antiplatelet therapy was felt to be acceptable. In addition, there is a risk of in-stent stenosis or thrombosis; while we observed no cases of procedure-related stroke or occlusion in our series, we did observe nonflow limiting intimal hyperplasia in a minority of patients which was asymptomatic in all cases.

One patient in our series developed a periprocedural neurological complication (ICH). The 7.4% overall complication rate, and 3.7% neurological complication rate observed in our cohort is consistent with other literature regarding the use of the Pipeline device for treating aneurysms in general with neurological complication rates mostly in the range of 5%–13.5%.<sup>[5]</sup>

Considerations specific to the ACOM location include the possibility that the aneurysm may continue to fill through the contralateral ACA. We have generally observed that flow diversion is more likely to be successful in aneurysms that are located at the A1-A2 junction or asymmetrically rather than true ACOM aneurysms; however, one series found that only 13% of ACOM aneurysms were true ACOM aneurysms and most occurred at the A1-A2 junction.<sup>[8]</sup> We did not treat patients with azygous ACAs with this treatment

modality, as in that case preserving flow across the ACOM was imperative. In general, the contralateral, uncovered A1 segment will typically increase in prominence on the follow-up angiogram, such that each A1 segment supplies its ipsilateral territory without relying on substantial cross-flow across the ACOM. In the case of true ACOM aneurysms, it may be more likely that patients require a second, contralateral flow diversion procedure to completely eliminate the aneurysm.

Our 100% successful deployment rate, comparable to other studies, supports the technical feasibility of the Pipeline device to treat ACOM and distal ACA aneurysms. Furthermore, the Pipeline device was used as the initial treatment modality in 14 of the 27 aneurysms treated. Therefore, our results suggest that not only is the Pipeline device a feasible treatment for ruptured and unruptured aneurysms but that it should be considered as a first-line treatment modality for unruptured cases.

Previous series of Pipeline flow diverters for ACOM aneurysms report complete occlusion rates ranging from 25% to 100% [Table 3];<sup>[9-17]</sup> other flow diverters such as the Silk and p64 have also been utilized in the management of ACOM aneurysms. Meta-analyses of ACA and ACOM flow diversion treatments including various commercially available flow diverters have reported a 79% occlusion rate at the last follow-up.<sup>[18,19]</sup> To date, we report that none of the 27 patients included in this study experienced recurrent subarachnoid hemorrhage after Pipeline treatment, regardless of angiographic outcome

**Table 3: Published series of anterior communicating artery aneurysm flow diversion in the literature**

Author	Publication year	Location of aneurysm	Total number of aneurysms	Occlusion rate (%)	All complications (%)	Stenosis rate (%)	Thromboembolic complications (%)	Hemorrhagic complications (%)	Duration of DAPT
Amuluru <i>et al.</i>	2019	ACOM	11	100% at 6.5 months	28	18	10.0	0	At least 6 months, then dependent on follow-up angiogram
Dabus <i>et al.</i>	2017	A1 (1), ACOM (13), or A2-pericallosal (6)	20	69% at 10 months	10.0	5	5	5	6 months
Colby <i>et al.</i>	2017	ACOM (26), A1-A2 junction (15)	41	85% at ~6-7 months	10.0	Not reported	2	4	ASA 325 and clopidogrel 75 mg x 6 months, then ASA 325 for additional 6 months then 81 mg aspirin lifelong barring intimal hyperplasia
Lin <i>et al.</i>	2017	ACOM	6	83.3%	16.7	16.7	0	0	ASA and clopidogrel for 5 days prior to procedure; total duration not reported
Martinez-Galdamez <i>et al.</i>	2014	ACOM (1), A1-A2 junction (3)	4	75% at 6 months (one lost to follow-up)	50.0	25 (asymptomatic)	50.0	0	ASA 100–325 mg, clopidogrel 75 mg at least until follow-up angiogram
Sulttan-Qurraie <i>et al.</i>	2017	ACOM	3	100% at mean of 10 months	0	0	0	0	ASA and clopidogrel for 5 days prior to procedure; duration of DAPT not reported
Pagiola <i>et al.</i>	2019	ACOM	8 (multiple FD used; included only the PED patients)	62.5% (3 lost to follow up)	26.7 (for entire cohort including other FD; included asymptomatic clot intraoperatively treated)	Not reported (for pipeline subgroup)	3 (for entire cohort spanning multiple devices)	0	Aspirin and clopidogrel before 2015, Aspirin and ticagrelor after 2015
Gawlitza <i>et al.</i>	2015	ACOM	4	25% total; 75% slow flow	25 (asymptomatic stroke)	0	25	0	Not reported

ACOM: Anterior communicating artery, DAPT: Dual antiplatelet therapy, PED: Pipeline device, ASA: Aspirin, FD: Flow diversion

as occluded or revealing stasis with residual filling. Consistent with prior literature, delayed Pipeline-related complications are unlikely. Therefore, even in the absence of complete occlusion, our results suggest a protective effect conferred by Pipeline device treatment, preventing future rupture and subarachnoid hemorrhage.

Our study is limited in that it is a single-center, retrospective series; additionally, some patients were pending follow-up at the time of this manuscript. However, this series adds to the literature demonstrating the feasibility and safety of treating ACOM aneurysms with the Pipeline flow diverting stent.

## Conclusion

Aneurysms of the anterior communicating complex and distal ACA are common but can be technically difficult to achieve complete and stable coil occlusion given their size, multiple perforators and branches in close proximity, and angulation. Flow diversion has well-documented technical success for treatment of recurrent or uncoilable proximal anterior circulation aneurysms but is less studied in aneurysms of the ACA. In our single-center series, we demonstrate that flow diversion of ACA aneurysms can be a durable and effective treatment for recurrent or residual ruptured aneurysms, as well as a primary treatment for unruptured aneurysms. Further follow-up and additional studies are needed to confirm these results.

## Declaration of patient consent

As this was a retrospective study, written informed consent was not required.

## Financial support and sponsorship

Nil.

## Conflicts of interest

There are no conflicts of interest.

## References

- Juvela S, Poussa K, Lehto H, Porras M. Natural history of unruptured intracranial aneurysms: A long-term follow-up study. *Stroke* 2013;44:2414-21.
- Investigators TUJ, The UCAS Japan Investigators. The natural course of unruptured cerebral aneurysms in a Japanese cohort. *N Engl J Med* 2012;366:2474-82.
- Bijlenga P, Ebeling C, Jaegersberg M, Summers P, Rogers A, Waterworth A, *et al.* Risk of rupture of small anterior communicating artery aneurysms is similar to posterior circulation aneurysms. *Stroke* 2013;44:3018-26.
- Uemura A, Kamo M, Matsukawa H. Angiographic outcome after endovascular therapy for anterior communicating artery aneurysms: Correlation with vascular morphological features. *Jpn J Radiol* 2012;30:624-7.
- O'Neill AH, Chandra RV, Lai LT. Safety and effectiveness of microsurgical clipping, endovascular coiling, and stent assisted coiling for unruptured anterior communicating artery aneurysms: A systematic analysis of observational studies. *J Neurointerv Surg* 2017;9:761-5.
- Becske T, Potts MB, Shapiro M, Kallmes DF, Brinjikji W, Saatci I, *et al.* Pipeline for uncoilable or failed aneurysms: 3-year follow-up results. *J Neurosurg* 2016;127:81-8.
- Schuetz AJ, Hui FK, Spiotta AM, Obuchowski NA, Gupta R, Moskowitz SI, *et al.* Endovascular therapy of very small aneurysms of the anterior communicating artery: Five-fold increased incidence of rupture. *Neurosurgery* 2011;68:731-7.
- Wong H, Banfield J, Hughes N, Shankar JJ. Are anterior communicating aneurysms truly anterior communicating aneurysms? An observational study. *World Neurosurg* 2019;125:e1089-92.
- Amuluru K, Al-Mufti F, Romero CE. Flow diversion treatment of anterior communicating artery region aneurysms. *J Neuroradiol* 2019 Jun 20:S0150-9861(19)30110-5. [doi: 10.1016/j.neurad.2019.06.002].
- Dabus G, Grossberg JA, Cawley CM, Dion JE, Puri AS, Wakhloo AK, *et al.* Treatment of complex anterior cerebral artery aneurysms with Pipeline flow diversion: Mid-term results. *J Neurointerv Surg* 2017;9:147-51.
- Martínez-Galdámez M, Romance A, Vega P, Vega A, Caniego JL, Paul L, *et al.* Pipeline endovascular device for the treatment of intracranial aneurysms at the level of the circle of Willis and beyond: Multicenter experience. *J Neurointerv Surg* 2015;7:816-23.
- Colby GP, Bender MT, Lin L-M, Beaty N, Huang J, Tamargo RJ, *et al.* Endovascular flow diversion for treatment of anterior communicating artery region cerebral aneurysms: A single-center cohort of 50 cases. *J Neurointerv Surg* 2017;9:679-85.
- Lin LM, Iyer RR, Bender MT, Monarch T, Colby GP, Huang J, *et al.* Rescue treatment with pipeline embolization for postsurgical clipping recurrences of anterior communicating artery region aneurysms. *Interv Neurol* 2017;6:135-46.
- Bhatia KD, Kortman H, Orru E, Klostranec JM, Pereira VM, Krings T. Periprocedural complications of second-generation flow diverter treatment using Pipeline Flex for unruptured intracranial aneurysms: A systematic review and meta-analysis. *J Neurointerv Surg* 2019;11:817-24.
- Sultan-Qurraie A, Sattar A, Wazni W, Noufal M, Zaidat O. Anterior communicating artery aneurysm treatment with the pipeline embolization device: A single-center experience with long-term follow-up. *Interv Neurol* 2017;6:126-34.
- Pagiola I, Mihalea C, Caroff J, Ikka L, Chalumeau V, Yasuda T, *et al.* Flow diversion treatment of aneurysms of the complex region of the anterior communicating artery: Which stent placement strategy should "I" use? A single center experience. *J Neurointerv Surg* 2019;11:1118-22.
- Gawlitza M, Januel A-C, Tall P, Bonneville F, Cognard C. Flow diversion treatment of complex bifurcation aneurysms beyond the circle of Willis: A single-center series with special emphasis on covered cortical branches and perforating arteries. *J Neurointerv Surg* 2016;8:481-7.
- Cagnazzo F, Limbucci N, Nappini S, Renieri L, Rosi A, Laiso A, *et al.* Flow-diversion treatment of unruptured saccular anterior communicating artery aneurysms: A systematic review and meta-analysis. *AJNR Am J Neuroradiol* 2019;40:497-502.
- Sorenson TJ, Mendes Pereira V, Rangel Castilla L, Hilditch CA, Nicholson PJ, Brinjikji W. Treatment of anterior cerebral artery and anterior communicating artery aneurysms with flow-diversion devices: A systematic review and meta-analysis. *J Neurosurg Sci* 2020;64:200-5.