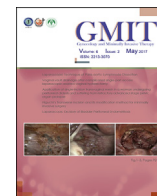



Contents lists available at ScienceDirect

Gynecology and Minimally Invasive Therapy

journal homepage: www.e-gmit.com

Case report

Isolated fallopian tube torsion diagnosed and treated with laparoscopic surgery: A case report

Fumitake Ito ^{a, *}, Hiroshi Tatsumi ^a, Akiko Takahata ^b, Sachimi Yamada ^b, Izumi Kusuki ^a, Jo Kitawaki ^a^a Department of Obstetrics and Gynecology, Kyoto Prefectural University of Medicine, Graduate School of Medical Science, Kyoto, Japan^b Department of Radiology, Kyoto Prefectural University of Medicine, Graduate School of Medical Science, Kyoto, Japan

ARTICLE INFO

Article history:

Received 24 March 2016
 Received in revised form
 10 June 2016
 Accepted 16 June 2016
 Available online 25 July 2016

Keywords:

acute abdominal pain
 isolated fallopian tube torsion
 laparoscopic surgery

ABSTRACT

Among diseases causing acute lower abdominal pain in women, isolated fallopian tube torsion is very rare, with an annual prevalence of 1 in 1.5 million. Because it has fewer findings on imaging compared to adnexal torsion, the correct diagnosis can rarely be made before an operation. We present a case of isolated fallopian tube torsion that was suspected preoperatively by its clinical course and findings on computed tomography. A 24-year-old woman repeatedly experienced acute colicky pain in the right lower back. Transvaginal ultrasonography and magnetic resonance imaging showed a right pelvic cystic lesion with intact ovaries; these findings led us to schedule a laparoscopic examination. However, the patient presented to the emergency room with acute severe right back pain. The preoperative diagnosis considering the computed tomography findings and clinical course was consistent with fallopian tube torsion. An earlier diagnosis may have helped to preserve the fallopian tube and future fertility.

Copyright © 2016, The Asia-Pacific Association for Gynecologic Endoscopy and Minimally Invasive Therapy. Published by Elsevier Taiwan LLC. This is an open access article under the CC BY-NC-ND license (<http://creativecommons.org/licenses/by-nc-nd/4.0/>).

Introduction

While torsion of the adnexa is a fairly common cause of acute lower abdominal pain in women, isolated fallopian tube torsion is very rare.¹ Because isolated fallopian tube torsion lacks specific symptoms, clinical observations, and imaging characteristics, laparoscopic examination is necessary for a correct diagnosis.² Herein, we present a rare case of isolated fallopian tube torsion that was suspected preoperatively and was successfully treated with laparoscopic surgery.

Case Report

The patient was a 24-year-old, nulliparous, gravida 0 woman. Swelling of the right fallopian tube was identified at another hospital 3 months prior to the first examination at our hospital. A magnetic resonance imaging (MRI) examination was scheduled,

but the patient experienced acute pain in the right lower back and came to our department for examination. When the patient came in for the examination at our department, the pain had lessened.

During the initial examination at our department, a well-defined cystic lesion (78 mm × 30 mm) was identified in the right pelvis on a transvaginal ultrasonography scan. Internally, the lesion had uniformly low echogenicity, suggesting an incomplete wall-like structure. There was no clear continuity between the cystic lesion and the uterus, and there was no abnormal finding in either ovary. Blood biochemistry results for white blood cell (WBC) count and C-reactive protein (CRP) level were $4.1 \times 10^9/L$ and 0.01 mg/dL, respectively; thus, an increase in inflammatory response was not confirmed. Tumor markers—carcinoembryonic antigen, cancer antigen 19-9, and cancer antigen 125—were negative, and there was no notable abnormal finding considering the results of other biochemical examinations. A chlamydia antigen test was negative.

Considering the possibility of urinary calculi, abdominal computed tomography (CT) was performed. No clear ureteral calculi were observed on the CT examination, but in addition to the pelvic cyst, kidney stones were confirmed on the left side. A definitive diagnosis was not achieved, and a pelvic MRI examination was scheduled for a later date. On the pelvic MRI examination, the margin of the pelvic cyst was lobulated, indicating the possibility of septae (Figure 1). As both ovaries could be visualized, a

Conflicts of interest: The authors have no conflicts of interest relevant to this article.

* Corresponding author. Department of Obstetrics and Gynecology, Kyoto Prefectural University of Medicine, 465 Kajii-cho, Kamigyo-ku, Kyoto 602-8566, Japan.

E-mail address: fitoh@koto.kpu-m.ac.jp (F. Ito).

<http://dx.doi.org/10.1016/j.gmit.2016.06.006>

2213-3070/Copyright © 2016, The Asia-Pacific Association for Gynecologic Endoscopy and Minimally Invasive Therapy. Published by Elsevier Taiwan LLC. This is an open access article under the CC BY-NC-ND license (<http://creativecommons.org/licenses/by-nc-nd/4.0/>).

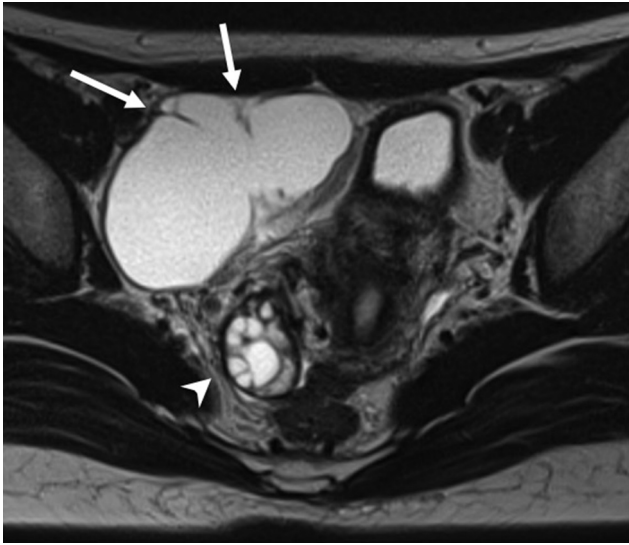


Figure 1. Axial T2-weighted magnetic resonance image showing a cystic lesion in the right pelvis with incomplete wall-like structures (arrows). An intact right ovary can be observed (arrowhead).

hydrosalpinx, parooophoritic cyst, peritoneal inclusion cyst, or mesenteric lymph cyst was suspected; however, a definitive diagnosis could yet not be achieved. Hence, a laparoscopic examination was scheduled for 1 month later. However, 1 week before the scheduled surgery, the patient experienced acute pain in the right lower back again and came to our hospital. Her body temperature at the time of examination was 37.0°C, and her vital signs were stable. The right adnexa exhibited minor tenderness. On a transvaginal ultrasonography scan, the only finding was a minor retention of ascites other than the known cystic lesion. Blood biochemistry results for WBC count and CRP level were $12.2 \times 10^9/L$ and 0.01 mg/dL, respectively. Suspecting a pelvic infection, the administration of an antimicrobial agent (2 g/d cefmetazole) was initiated. On the abdominal CT examination (Figure 2), edematous thickening of the wall of the already identified cyst was confirmed. The partial thickening of the wall showed slightly high attenuation and poor contrast effect. The previously known cystic lesion was determined to be hydrosalpinx. If the cause of the present pain was torsion of the hydrosalpinx, all the symptoms could be explained; however, administration of the antimicrobial agent was continued

without reaching a definitive diagnosis. On the 2nd day of hospitalization, blood biochemistry results for WBC count and CRP level were $10.2 \times 10^9/L$ and 0.01 mg/dL, respectively, and on the 3rd day, the results were $8.3 \times 10^9/L$ and 10.04 mg/dL, respectively. The inflammatory response had subsided and symptoms lessened. After observing this subsiding inflammatory response, a laparoscopic examination was performed on the 7th day of hospitalization.

The laparoscopic observation confirmed a small amount of intraperitoneal bloody ascites. There were no adhesions in the intestinal tract or around the liver. There were no abnormal findings of the uterus or left adnexa. Although there was no abnormal finding in the right ovary, the right fallopian tube was notably swollen. As the right fallopian tube exhibited a 1260° torsion isolated from the right ovary, and its purplish discoloration indicated necrosis (Figure 3), the right fallopian tube was resected. There were no notable complications during the surgery. As there were no notable postoperative complications, the patient was discharged 5 days after the surgery. The histopathological diagnosis of the resected fallopian tube was hydrosalpinx with massive hemorrhage and necrosis of the subepithelial smooth muscle tissue.

Discussion

Adnexa torsion accompanied by ovarian tumors is not rare, but isolated fallopian tube torsion is extremely rare.¹ The predilection age of fallopian tube torsion is 20–50 years, which includes the reproductive ages. Based on anatomical differences, fallopian tube torsion is assumed to occur more often on the right side.³

The pathogenesis of an isolated fallopian tube torsion is unclear as yet, but considering its etiology, an idea has been proposed to classify internal and external factors separately.⁴ The internal factors refer to causes within the fallopian tube, including hydrosalpinx, fallopian tube tumors, post-tubal ligation, and abnormal progression of tubal peristalsis. The external factors refer to effects of adjacent organs, including intraperitoneal adhesions, pelvic congestion, pregnancy, and spasms of the fallopian tubes due to medications. In the present case, hydrosalpinx had been present for some time but there were no abnormal findings in the surrounding tissues and organs; therefore, the case was considered an isolated fallopian tube torsion caused by internal factors. In addition, the patient had experienced acute pain more than once prior to hospitalization and the torsion finding during the surgery was significant. Therefore, it is possible that torsion had occurred repeatedly.

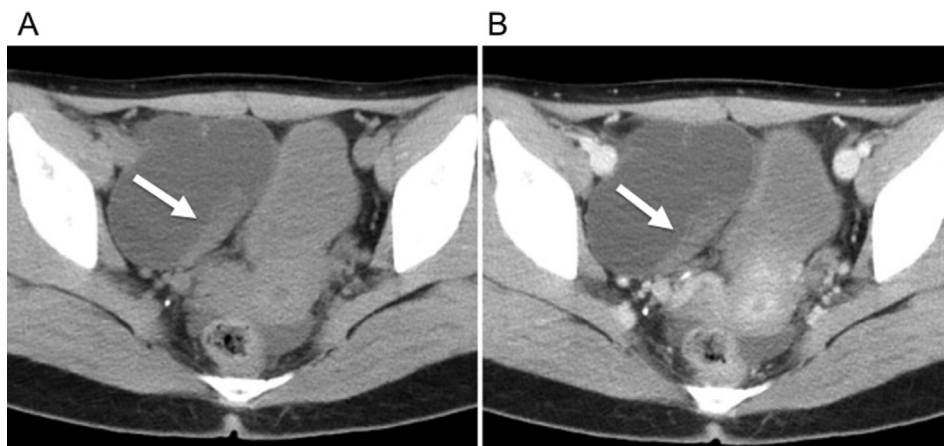


Figure 2. (A) Noncontrast pelvic computed tomographic image showing a cystic lesion in the anterior right pelvis. The partially thickened wall of the cyst shows slightly high attenuation (arrow). (B) Contrast-enhanced pelvic computed tomography scan showing poor enhancement of the cystic wall (arrow).

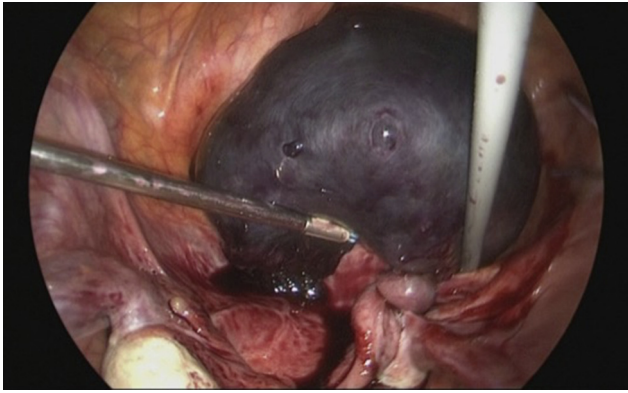


Figure 3. Intraoperative photographic image showing twisted funicular material between the swollen and congested fallopian tube and the healthy fallopian tube.

However, clear signs of torsion were not observed on CT and MRI examinations during outpatient visits.

In a case of isolated fallopian tube torsion, many patients experience flank pain; therefore, acute appendicitis, rupture of ovarian tumor, ovarian torsion, ectopic pregnancy, endometriosis pain, and other pelvic inflammatory diseases are proposed as differential diagnoses. In a case of fallopian tube torsion, unilateral adnexal pain on bimanual examinations is common. However, in the present case, there was only spontaneous pain in the right lower back and there was no evident tenderness.⁵ Generally, imaging is useful to discriminate causes of acute abdominal pain; however, it is extremely rare to diagnose isolated fallopian tube torsion based on preoperative imaging findings.² There is a report of an isolated fallopian tube torsion diagnosed on a transvaginal ultrasonography scan obtained using color Doppler.² If isolated fallopian tube torsion is actively suspected, the transvaginal ultrasonography findings, clinical course, and examination findings need to be correlated. If adnexitis is suspected based on clinical findings, in addition to a history of hydrosalpinx and tubal ligation, findings such as a dilated fallopian tube and a lumen structure with disrupted blood flow on a transvaginal ultrasonography scan would probably support such a diagnosis. Furthermore, contrast-

enhanced CT or MRI examination may be useful for the diagnosis of isolated fallopian tube torsion with findings of hydrosalpinx with a lack of enhancement accompanied by an ipsilateral normal ovary.

A preoperative definitive diagnosis is difficult, and because it takes time to exclude other diagnoses, many cases of isolated fallopian tube torsion lead to necrosis of the fallopian tubes and the need for salpingectomy. However, if surgery can be performed shortly after onset, preservation of the affected-side fallopian tube may be possible.⁶ In the present case, unfortunately, an early and preoperative diagnosis was not possible, and because necrosis of the fallopian tube was confirmed during surgery, salpingectomy was performed. In a previously reported case, fallopian tube torsion spontaneously resolved; however, the fallopian tube torsion relapsed.⁷ In the present case as well, torsion might have been repeatedly occurring and resolving; thus, if fallopian tube torsion was actively suspected on the initial examination, the fallopian tube might have been preserved.

When a woman complains of acute abdominal pain, although it is rare, isolated fallopian tube torsion needs to be considered in the differential diagnosis. Specifically, in young women, an early diagnosis is important for the preservation of the adnexa of the uterus and future fertility. In a case of acute abdominal pain that does not lead to a definitive diagnosis, an early-stage laparoscopy is important.

References

1. Cuillier F, Harper L, Birsan A. Fallopian tube torsion: five cases with no other element. *J Gynecol Obstet Biol Reprod.* 2002;31:755–764 [In French].
2. Richard 3rd HM, Parson RB, Broadman KF, Shapiro RS, Yeh HC. Torsion of the fallopian tube: progression of sonographic features. *J Clin Ultrasound.* 1998;26:374–376.
3. Lo LM, Chang SD, Lee CL, Liang CC. Clinical manifestations in women with isolated fallopian tubal torsion; a rare but important entity. *Aust N Z J Obstet Gynaecol.* 2011;51:244–247.
4. Filtenborg TA, Hertz JB. Torsion of the fallopian tube. *Eur J Obstet Gynaecol Reprod Biol.* 1981;12:177–181.
5. Gupta A, Thida W, Nazir B, Yeo CS, Low Y, Ong CL. Isolated fallopian tube torsion in prepubertal females. *Med J Malaysia.* 2015;70:259–262.
6. Wang PH, Yuan CC, Chao HT, Shu LP, Lai CR. Isolated tubal torsion managed laparoscopically. *J Am Assoc Gynecol Laparosc.* 2000;7:423–427.
7. Milki A, Jacobson DH. Isolated torsion of the fallopian tube. A case report. *J Reprod Med.* 1998;43:836–838.