

CASE REPORT

Porcelain Gallbladder

¹Apoorv Goel, ¹Ayush Agarwal, ¹Shalabh Gupta, ¹Tripta S Bhagat, ¹Gaurav Kumar, ¹Atul K Gupta

ABSTRACT

Porcelain gallbladder or calcified gallbladder is a rare entity and is considered as the end stage of chronic cholecystitis. This disease is rarely diagnosed preoperatively and usually mimics carcinoma gallbladder. Hereby, we present a rare and interesting case of porcelain gallbladder that was diagnosed preoperatively and managed by cholecystectomy.

Keywords: Carcinoma gallbladder, Chronic cholecystitis, Porcelain gallbladder, Prophylactic cholecystectomy.

How to cite this article: Goel A, Agarwal A, Gupta S, Bhagat TS, Kumar G, Gupta AK. Porcelain Gallbladder. *Euroasian J Hepato-Gastroenterol* 2017;7(2):181-182.

Source of support: Nil

Conflict of interest: None

Copyright and License information: Copyright © 2017; Jaypee Brothers Medical Publishers (P) Ltd.

This work is licensed under a Creative Commons Attribution 3.0 Unported License. To view a copy of this license, visit <http://creativecommons.org/licenses/by/3.0/>

INTRODUCTION

Porcelain gallbladder is an extremely rare condition with an incidence of 0.06 to 0.8% and considered as high risk for carcinoma gallbladder.^{1,2} The risk for malignancy ranges from 5 to 22%.³ It is also known as calcified gallbladder and is considered as end stage of chronic cholecystitis. It is more common among elderly females and due to high risk of malignant transformation it is managed by cholecystectomy.

CASE SUMMARY

A 55-year-old female presented with complaints of intermittent pain in right upper abdomen of 15 days duration. There was no history of any fever, jaundice, and vomiting. Abdominal examination was unremarkable. Ultrasound abdomen revealed a large calcified mass in gallbladder fossa with normal common bile duct and normal liver echotexture. After corroboration with X-ray abdomen (Fig. 1), the provisional diagnosis of porcelain gallbladder was made. Contrast-enhanced computed tomography (CECT) abdomen confirmed the diagnosis of porcelain gallbladder with no evidence of malignant change (Fig. 2). Liver function test was normal. Patient was planned for open cholecystectomy. Intraoperatively, it was a difficult dissection as gallbladder was completely calcified, brittle, and densely adhered to liver bed. After dissecting Calot's triangle and dividing cystic duct and artery, gallbladder was excised and sent

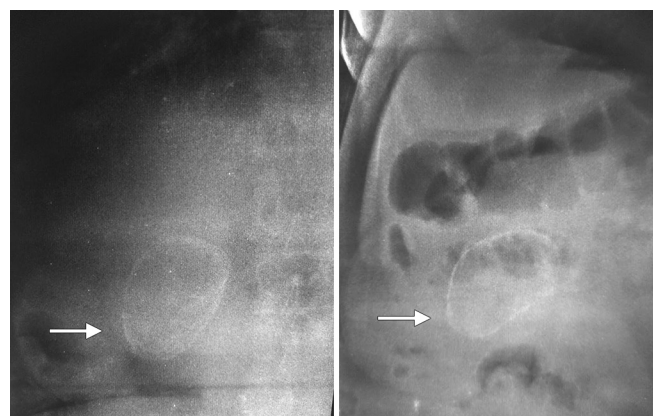

Fig. 1: Plain X-ray abdomen showing calcified gall bladder

for histopathologic examination. Postoperative recovery was uneventful.

Histopathology report revealed rigid, thickened chronically inflamed gallbladder wall with transmural calcification. Gallbladder was packed with multiple stones. Microscopic examination showed hemorrhage and fibrosis with focal muscular hypertrophy and calcification. There was no evidence of malignant change.

DISCUSSION

Porcelain gallbladder or calcified gallbladder or cholelithiasis chronica calcarea is a relatively rare condition with an incidence rate of 0.06 to 0.8%.^{1,2} It is characterized by bluish discoloration and extremely calcified wall of

¹Department of General Surgery, Santosh Medical College and Hospital, Ghaziabad, Uttar Pradesh, India

Address reprint requests to: Apoorv Goel, Department of General Surgery, Santosh Medical College and Hospital, Ghaziabad, Uttar Pradesh, India, Phone: +911204107140, e-mail: drapurvgoel@gmail.com

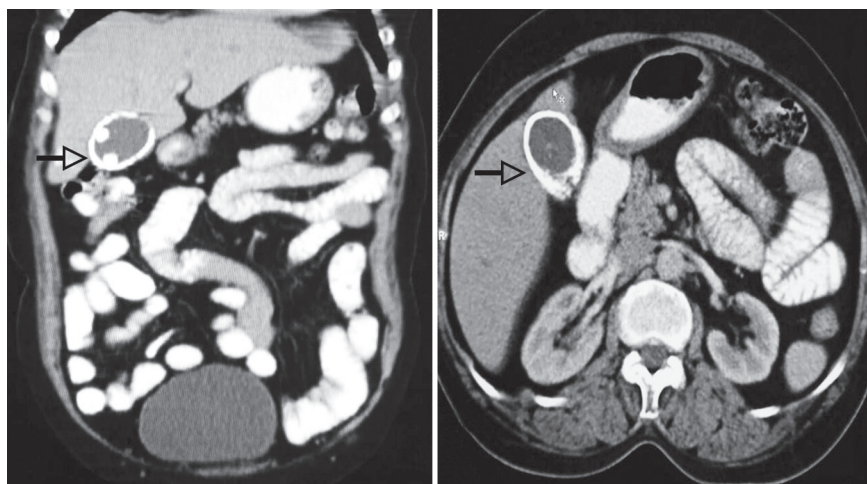


Fig. 2: Contrast-enhanced computed tomography of abdomen

gallbladder. It is commonly seen among elderly females and is associated with gallstones in about 90% of cases.¹⁻³ It is associated with high risk of malignancy and the rate may vary from 5 to 22%.^{3,4} Porcelain gallbladders are associated with gallstones in 90% of cases. The pathogenesis of gallbladder calcification is still unclear and it is considered a result of obstruction of cystic duct leading to the precipitation of calcium salts in the mucosa or as a result of chronic inflammation resulting in the hemorrhage, scarring, and hyalinization of the wall causing deposition of lime salts. Histological examination shows that the calcification is diffusely scattered throughout the mucosa, submucosa, glandular spaces, and Rokitansky-Aschoff sinuses.^{1,2,4} This chronic inflammation or the degeneration and regeneration process within the gallbladder epithelium may act as a carcinogenic stimulus.

Porcelain gallbladder patients are usually asymptomatic and this condition is diagnosed as an incidental finding on plain abdominal radiograph, sonography, and CT.⁵ There are several conditions like large opaque gallstone, calcified hydatid cyst of liver, metastatic deposits, calcified renal cysts, schistosomiasis, calcified lymph nodes, and other granulomatous diseases, which may closely mimic porcelain gallbladder. However, CT is considered as investigation of choice as it can accurately differentiate it from other causes.⁵

Porcelain gallbladder is associated with a high risk of malignancy; hence, surgical removal should not be delayed. Prophylactic cholecystectomy should be performed.⁶⁻⁸ Open cholecystectomy is preferred over

laparoscopic approach due to suspicion of malignancy as well as brittle consistency of gallbladder; however, few studies have quoted successful laparoscopic cholecystectomy in porcelain gallbladder.⁶⁻⁸

CONCLUSION

Porcelain gallbladder is a rare condition and associated with high risk of carcinoma gallbladder. Prophylactic cholecystectomy is the preferred treatment for porcelain gallbladder.

REFERENCES

1. Ashur H, Siegal B, Oland Y, Adam TG. Calcified gallbladder (porcelain gallbladder). *Arch Surg* 1978 May;113(5):594-596.
2. Opatrny L. Porcelain gallbladder. *Can Med Assoc J* 2002 Apr;166:933.
3. Stephen AE, Berger DL. Carcinoma in the porcelain gallbladder: a relationship revisited. *Surgery* 2001 Jun;129(6):699-703.
4. Puttasubbappa PS, Pallavi P. Porcelain gallbladder mimicking carcinoma gallbladder—a case report and review of literature. *Indian J Surg* 2013 Jun;75(Suppl 1):S208-S209.
5. Kane RA, Jacobs R, Katz J, Costello P. Porcelain gallbladder ultrasound and CT appearance. *Radiology* 1984;152(1):137-141.
6. Sheth S, Beford A, Chopra S. Primary gallbladder cancer: recognition of risk factors and the role of prophylactic cholecystectomy. *Am J Gastroenterol* 2000 Jun;95(6):1402-1410.
7. Puia IC, Vlad L, Iancu C, Al-Hajjar N, Pop F, Bălă O, Munteanu D. Laparoscopic cholecystectomy for porcelain gallbladder. *Chirurgia (Bucur)* 2005 Mar-Apr;100(2):187-189.
8. Welch NT, Fitzgibbons RJ Jr, Hinder RA. Beware of the porcelain gallbladder during laparoscopic cholecystectomy. *Surg Laparosc Endosc* 1991 Sep;1(3):202-205.