

Dermatoscopy: A multicolored lesion on the forehead

Engin Şenel¹

¹ Hitit University Faculty of Medicine, Department of Dermatology, Çorum, Turkey

Keywords: cutaneous carcinoma, skin cancer, basal cell carcinoma, pigmented basal cell carcinoma, dermatoscopy, dermoscopy

Citation: Senel E. Dermatoscopy: A multicolored lesion on the forehead. *Dermatol Pract Concept*. 2014;4(3):14. <http://dx.doi.org/10.5826/dpc.0403a14>.

Received: December 20, 2013; **Accepted:** December 20, 2013; **Published:** July 31, 2014

Copyright: ©2014 Şenel. This is an open-access article distributed under the terms of the Creative Commons Attribution License, which permits unrestricted use, distribution, and reproduction in any medium, provided the original author and source are credited.

Funding: None.

Competing interests: The authors have no conflicts of interest to disclose.

Corresponding author: Engin Şenel, M.D., BBA, Hitit University Faculty of Medicine, Department of Dermatology, 19200 Çorum,

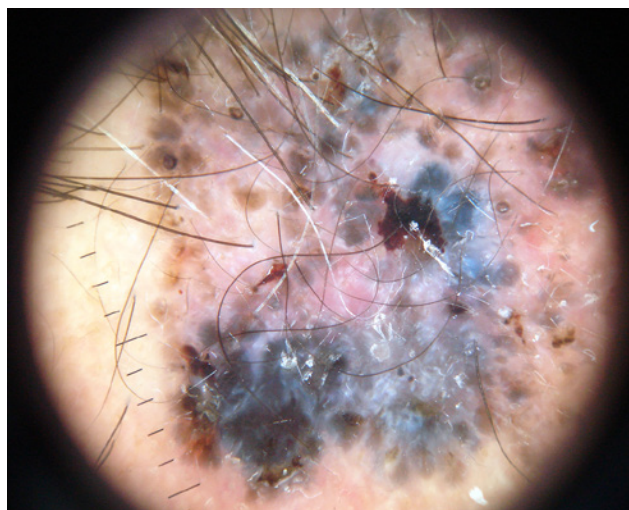
Turkey. Tel.: +90 364 2230300. Fax: +90 364 2230323. E-mail: enginsenel@enginsenel.com

The patient

A 48-year-old man presented with a two-year-history of a slowly growing pigmented lesion on his forehead. Dermatological examination revealed an irregular, multi-colored papule with a diameter of 25 x 26 mm (Figure 1). Dermatoscopic examination disclosed blue-gray globules, leaf-like structures and structureless areas (Figures 2, 3).

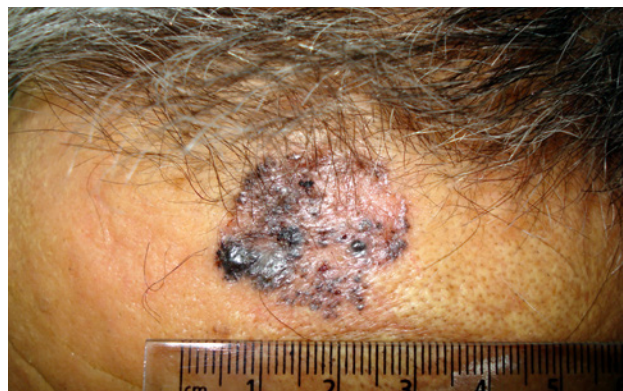
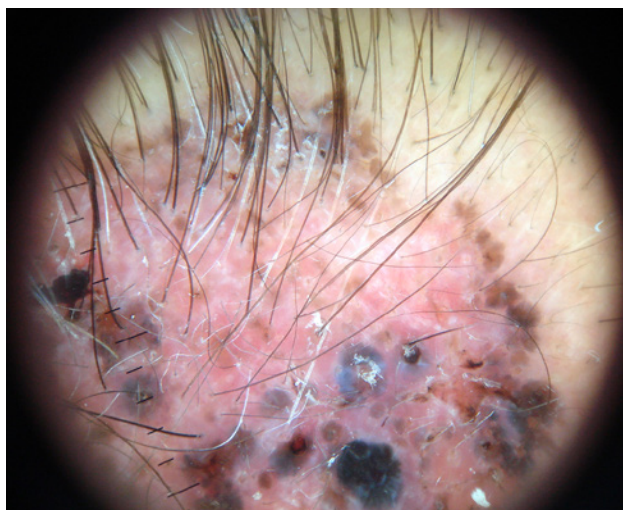
Figure 1. Pigmented lesion on forehead. [Copyright: ©2014 Senel.]



Figures 2, 3. Dermatoscopy: blue-gray globules, leaf-like structures and structureless areas. [Copyright: ©2014 Senel.]

What is your diagnosis?

Please send your answer to dpc@derm101.com. The first correct answer will receive a DL3N hand dermoscope [cordially

sponsored by 3GEN]. The case and the answer to the question will be presented in the next issue of *Dermatology Practical & Conceptual*.