

Case report

Sacituzumab Govitecan (IMMU-132) in treatment-resistant uterine serous carcinoma: A case report



Chanhee Han^a, Stefania Bellone^a, Peter E. Schwartz^a, Serengulam V. Govindan^b, Robert M. Sharkey^b, David M. Goldenberg^b, Alessandro D. Santin^{a,*}

^a Department of Obstetrics, Gynecology, and Reproductive Sciences, Yale University School of Medicine, New Haven, CT 06520, United States

^b Immunomedics, Inc., 300 The American Road, Morris Plains, NJ 07950, United States

ARTICLE INFO

Keywords:

Sacituzumab govitecan
IMMU-132
Uterine serous carcinoma
Recurrent
Treatment-resistant

ABSTRACT

Background: Uterine serous carcinoma (USC) is a biologically aggressive variant of uterine cancer. Effective treatment options for recurrent, chemotherapy-resistant USC are extremely limited.

Case: We describe a 74-year-old woman with recurrent and widespread treatment-resistant disease, who experienced a dramatic response to sacituzumab govitecan, a novel antibody-drug conjugate (ADC) targeting human trophoblast-cell-surface antigen (TROP-2), after failing multiple chemotherapy and immunotherapy. The impressive clinical response (66% reduction of target lesions by RECIST 1.1 with a duration response of over 10 months) was confirmed with serial CT scans in the absence of significant adverse events.

Conclusion: Sacituzumab govitecan may present a new treatment option for recurrent USC patients harboring Trop-2+ tumors resistant to chemotherapy. Clinical trials with sacituzumab govitecan are warranted.

1. Introduction

Uterine serous carcinoma (USC) is a rare histologic subtype of uterine cancer characterized by aggressive behavior and poor prognosis (Cirisano Jr. et al., 1999). Due to its aggressive nature and pattern of recurrence, the treatment of USC is multimodal, incorporating surgery, radiotherapy, and chemotherapy. Regardless of treatments, USC is responsible for 40% of uterine cancer-related deaths, although it accounts for only 3–10% of all uterine cancers (Boruta 2nd et al., 2009). The development of novel, effective therapeutic modalities against recurrent, chemotherapy-resistant USC remains desperately needed.

Sacituzumab-govitecan (IMMU-132) is a novel antibody-drug conjugate (ADC) comprised of a humanized anti-Trop-2 antibody (hRS7), conjugated with the active metabolite of irinotecan (SN-38) which targets human-trophoblast-cell-surface-antigen (TROP-2) (Cardillo et al., 2015). TROP-2 antigen, also known as EGP-1 (epithelial-glycoprotein-1), GA733-1 (gastric-antigen-733-1), and TACSTD2 (tumor-associated-calcium-signal-transducer), is expressed on a variety of human carcinomas including poorly-differentiated (grade 3) endometrioid adenocarcinoma and USC (Varughese et al., 2011; Bignotti et al., 2012; Goldenberg et al., 2015). Of note, TROP-2 overexpression has been shown to be a poor prognostic factor and an independent marker for predicting disease recurrence in endometrioid endometrial carcinoma (Bignotti et al., 2012). Here, we present a case of a recurrent

chemotherapy-resistant USC patient overexpressing TROP-2, who failed multiple lines of salvage chemotherapy, and experienced an impressive and durable clinical response to sacituzumab-govitecan.

2. Case

The patient is a 74-year-old woman who originally underwent a comprehensive surgical staging using a minimally invasive approach including a robotic-assisted total laparoscopic hysterectomy, bilateral-salpingo-oophorectomy, pelvic/para-aortic lymph node dissection, omentectomy, and abdominal washings in May 2013. Final pathology revealed a USC with > 50% myometrial invasion and one pelvic lymph node metastasis (stage IIIC1). She received 6 cycles of carboplatin/paclitaxel adjuvant chemotherapy treatment every 3-weeks and vaginal apex brachytherapy, which was completed on 10/13/2013. After the completion of chemotherapy, her serum cancer antigen 125 (CA125) decreased to 6.8 U/mL from 98.7 U/mL prior to treatment, and there was no evidence of the residual disease present by CT imaging.

She remained free of disease until 7/1/2015 when her CA125 was found to have increased to 142.7 U/mL. A positron-emission-tomography/computed-tomography (PET/CT) revealed recurrent disease at the vaginal cuff, in the right posterolateral liver, and in the small bowel mesentery. At that time, she was screened for human-epithelial-growth-factor-2 (HER2/neu) expression by Immunohistochemistry (IHC) and

* Corresponding author at: 333 Cedar Street, LSOG 305, PO Box 208063, New Haven, CT 06520, USA.

E-mail address: alessandro.santin@yale.edu (A.D. Santin).

by fluorescent-in-situ-hybridization-assay (FISH) to confirm c-erbB2 amplification for potential enrollment in clinical trials targeting HER2/neu with either monoclonal antibodies (i.e., trastuzumab, Herceptin™, Genentech/Roche) or pan c-erbB2 small molecule inhibitors (i.e., afatinib, Gilotrif™, Boehringer Ingelheim); clinical trials NCT01367002 and NCT02491099, respectively. Due to Her2/neu 3+ expression by IHC and c-erbB2 gene-amplification by FISH, she was enrolled in the NCT01367002 clinical trial (randomized-phase-II evaluation of carboplatin/paclitaxel with/without trastuzumab in Her2/neu+ patients with advanced/recurrent USC). She was randomized to receive carboplatin/paclitaxel without trastuzumab, and completed 6 cycles on 10/27/2015. A PET/CT on 11/19/2015 showed complete resolution of disease. Unfortunately, within 3 months of completing treatment, her CA125 increased to 127.8 U/mL. A follow-up CT scan on 2/18/2016 demonstrated recurrence with multiple new liver metastases. Secondary to the presence of platinum-resistance disease, Her2/neu 3+ expression of the tumor, and the desire of the patient, she was enrolled into the NCT02491099 clinical trial (a phase-II-evaluation of afatinib in patients with persistent/recurrent Her2-positive USC). Afatinib 40 mg orally-once-daily began on 2/26/2016. After 1-month of treatment, her CA125 level increased to 614.0 U/mL and a CT scan demonstrated the progression of the liver metastases. She was therefore removed from the NCT02491099 study, and started on dose-dense-paclitaxel (ddT, 80 mg/m²) combined with trastuzumab (4 mg/kg)(start date 4/12/2016); baseline CA125 at the time of ddT and trastuzumab initiation was elevated to 889.7 U/mL. A CT scan performed after 3 cycles revealed the progression of the hepatic disease and new peritoneal implants, with the CA125 remaining elevated (768.5 U/mL on 7/1/2016). Trastuzumab was then replaced with bevacizumab (10 mg/kg) on 7/5/2017. After 3 additional cycles of ddT/bevacizumab, her CA125 decreased to 224 U/mL and the patient continued to tolerate the treatment well. However, a CT scan after 6 cycles (dated on 12/2/2016) showed a mixed response with multiple lesions getting larger; the CA125 remained elevated to 442.1 U/mL, and a follow-up CA125 showed a further increase to 637.9 U/mL.

At this point she was counseled for enrollment in a Phase-II-clinical-trial (clinicaltrials.gov-NCT016531552) with IMMU-132, an ADC targeting TROP-2, based on the encouraging therapeutic activity shown in a phase I trial of multiple solid tumors (NCT01631552)(Starodub et al., 2015). After signing the appropriate study consent, she was started on IMMU-132 (dose: 10 mg/kg, days 1–8 of 21-day cycles) on 1/24/2017. TROP-2 expression at a 3+ level by IHC in over 90% of tumor cells was confirmed at Immunomedics, Inc. (Fig. 1). CA125 at the time of IMMU-

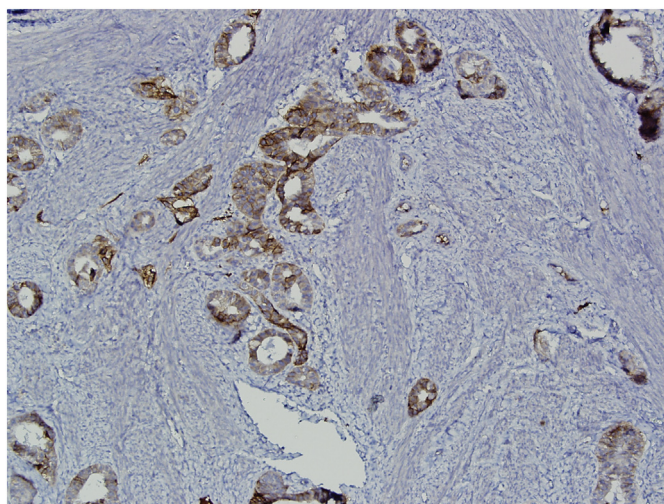


Fig. 1. Representative microscopic image of recurrent uterine serous carcinoma. Immunohistochemistry demonstrates strong Trop-2 staining. $\times 100$ magnification.

132 initiation was 679.4 U/mL. The patient tolerated IMMU-132 treatment well with mild fatigue. A CT scan after 4 cycles of IMMU-132 demonstrated significant interval improvement in all metastatic disease compared to baseline, with target lesions showing 35% size reduction by RECIST 1.1 (Fig. 2A,B), and the CA125 level decreased to 169.0 U/mL. As her treatment continued, the patient tolerated and responded well to IMMU-132. A CT scan obtained 6 months after treatment initiation continued to demonstrate a dramatic response with a 51% reduction in the target lesions from the baseline, and the CA125 decreasing to 56.3 U/mL (Fig. 2C). The patient's remarkable clinical response continues at the time of writing this case report, 10 months after treatment initiation, with a 66% tumor size reduction from the baseline image measurement by RECIST 1.1(Fig. 2D). Fig. 3 shows the patient's disease course with treatments (Fig. 3).

3. Discussion

We report a case of beneficial clinical evidence of sacituzumab-govitecan, a novel ADC targeting TROP-2, in a recurrent chemotherapy-resistant USC patient. Sacituzumab-govitecan is an ADC that targets TROP-2, a transmembrane glycoprotein overexpressed in many different epithelial cancers including biologically aggressive uterine tumors (Varughese et al., 2011; Goldenberg et al., 2015), but also in some normal epithelial cells (Cardillo et al., 2015). Previous studies have reported that 96.2% of endometrioid endometrial cancers (Type I) and 65% of USC (Type II) overexpress TROP-2 (Varughese et al., 2011; Bignotti et al., 2011). Sacituzumab-govitecan delivers the active metabolite of irinotecan (i.e., SN-38) a topoisomerase-I inhibitor, with a high drug:antibody ratio (Goldenberg et al., 2015). Camptothecin (CPT-11, irinotecan) is currently approved as a single agent for colorectal cancer and included in combination treatment regimens such as FOLFIRI (Conroy et al., 2011). IMMU-132 has unique features compared to other ADCs (Goldenberg et al., 2015): (I) Instead of using ultra-toxic drugs as a payload, IMMU-132 uses a moderately cytotoxic drug, SN-38; (II) IMMU-132 features 7 to 8 SN-38 drugs coupled with moderately a stable carbonate linker, rather than 2 to 4 drugs per antibodies with highly stable linkage in other ADCs; (III) while IMMU-132 does internalize when bound to the antigen on the membrane, this moderately stable linker cleaves at low pH, which is thought to encourage release of the drug in a tumor microenvironment as well. With these unique characteristics, IMMU-132 may deliver SN-38 to not only directly targeted cells but also to surrounding tumor cells over time, including stromal cells and vasculature cells, leading to an improved therapeutic index.

Recent studies demonstrated the efficacy and safety of IMMU-132 (Starodub et al., 2015; Bardia et al., 2017; Faltas et al., 2016; Gray et al., 2017; Heist et al., 2017). In the first-in-human trial in various types of metastatic epithelial cancers, 6 out of 25 patients (24%) had a long-term survival rate of > 15 months, 2 had a partial response (PR), and the majority of patients (16/25) had stable disease (SD) as best response (Starodub et al., 2015). In a metastatic platinum-resistant urothelial cancer study, IMMU-132 showed clinically significant responses in 3 out of 6 patients, with progression-free survival of 6.7 to 8.2 months and overall survival of 7.5+ to 11.4+ months (Faltas et al., 2016). IMMU-132 was also reported to be active against metastatic non-small-cell lung cancer (mNSCLC) and small-cell lung cancer (mSCLC) patients which were heavily pretreated: the clinical benefit rate (complete response (CR) + PR + SD \geq 4 months) was 43% for mNSCLC and 39% for mSCLC (Gray et al., 2017; Heist et al., 2017). Further encouraging results with IMMU-132 were reported in heavily-pretreated metastatic triple-negative breast cancers (mTNBC), with an objective response rate of 30% (19 PRs, 2 CRs), median response duration was 8.9 months, and a clinical benefit rate (CR + PR + SD \geq 6 months) of 46% in 69 patients who had progressed after receiving a median of 5 prior therapies (Bardia et al., 2017). Neutropenia was the most common side effect reported with grade \geq 3,

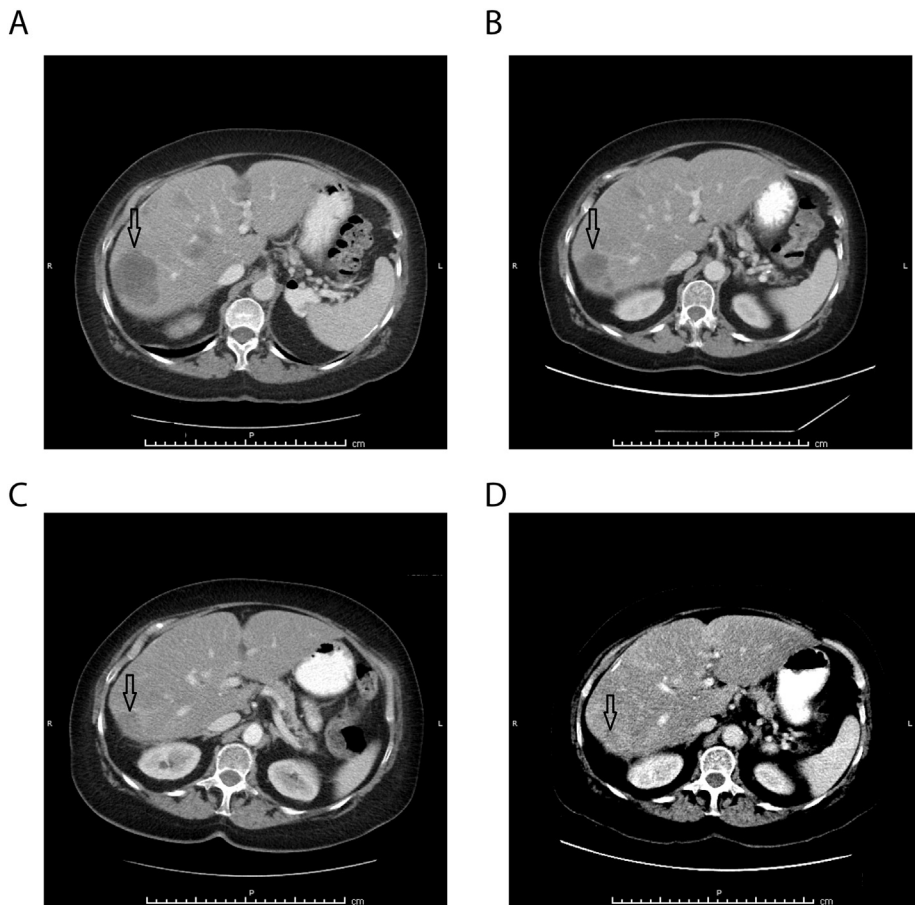


Fig. 2. Representative CT scans demonstrating activity of IMMU-132.

- A. Pretreatment images with baseline measurements of the target lesion (arrow) of the liver.
- B. Regression of the liver lesion (arrow) after 4 cycles of IMMU-132: partial response with 35% size reduction in target lesions by RECIST 1.1.
- C. Regression of the liver lesion (arrow) after 6 months of IMMU-132: partial response with 51% size reduction in target lesions by RECIST 1.1.
- D. Regression of the liver lesion (arrow) after 10 months of IMMU-132: partial response with 65.7% size reduction in target lesions by RECIST 1.1.

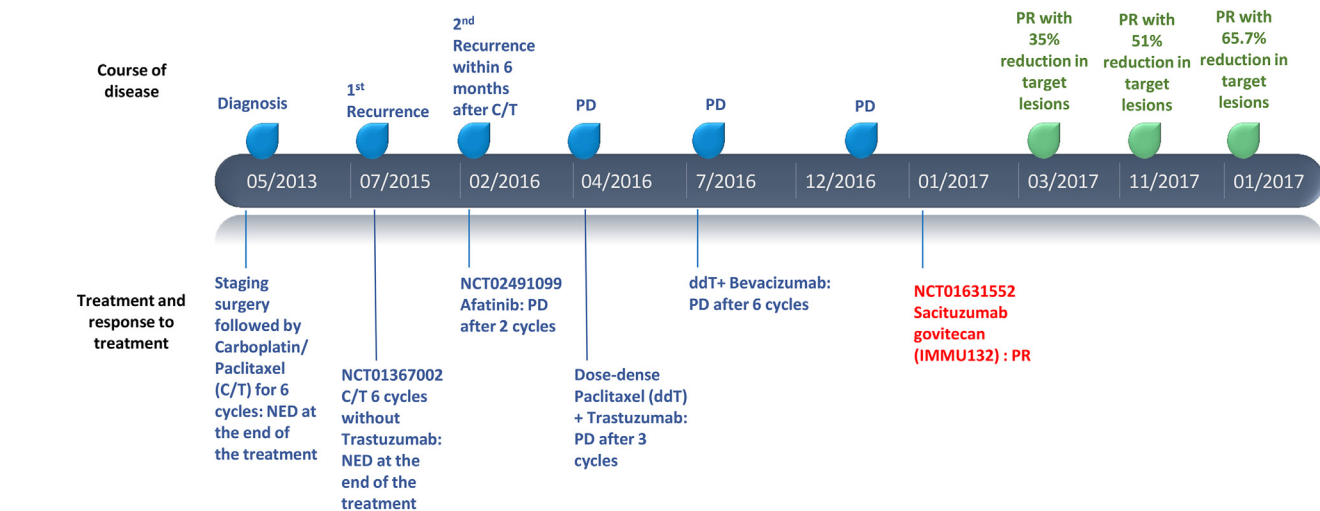


Fig. 3. Timeline of patient's disease course with treatment: (C/T, carboplatin/paclitaxel; PD, progression of disease; ddT, dose dense paclitaxel; NED, no evidence of disease; PR, partial response).

occurring in 34% to 43% of patients; however, neutropenic fever occurred only in 4% to 7% of patients (Bardia et al., 2017; Gray et al., 2017; Heist et al., 2017).

In conclusion, this report provides evidence of durable clinical response to sacituzumab-govitecan, an ADC targeting TROP-2, in a patient with metastatic/recurrent USC that was resistant to surgery/radiation/chemotherapy/trastuzumab and bevacizumab. Critically, strong TROP-2 IHC positivity was demonstrated in our patient, who had a durable clinical response continuing at 10+ months. Together, these findings demonstrate the responsiveness of therapy-resistant

metastatic/recurrent USC to this ADC in the absence of significant side effects. The findings in this case report are consistent with recent reports demonstrating impressive clinical responses to IMMU-132 in other human solid tumors (Starodub et al., 2015; Bardia et al., 2017; Faltas et al., 2016; Gray et al., 2017; Heist et al., 2017). Clinical trials in TROP-2-positive advanced or recurrent/metastatic endometrial cancer are warranted.

Consent

Written informed consent was obtained from the patient for publication of this case report. A copy of the written consent is available for review by the Editor-in-Chief of this journal on request.

Conflict of interest

Serengulam V. Govindan, Robert M. Sharkey, David M. Goldenberg declared a conflict of interest with employment and stock options to Immunomedics, Inc.

References

- Bardia, A., Mayer, I.A., Diamond, J.R., Moroese, R.L., Isakoff, S.J., Starodub, A.N., et al., 2017. Efficacy and safety of anti-Trop-2 antibody drug conjugate sacituzumab govitecan (IMMU-132) in heavily pretreated patients with metastatic triple-negative breast cancer. *J. Clin. Oncol.* 35 (19), 2141–2148.
- Bignotti, E., Ravaggi, A., Romani, C., Falchetti, M., Lonardi, S., Facchetti, F., et al., 2011. Trop-2 overexpression in poorly differentiated endometrial endometrioid carcinoma: implications for immunotherapy with hRS7, a humanized anti-trop-2 monoclonal antibody. *Int. J. Gynecol. Cancer* 21 (9), 1613–1621.
- Bignotti, E., Zanolini, L., Calza, S., Falchetti, M., Lonardi, S., Ravaggi, A., et al., 2012. Trop-2 protein overexpression is an independent marker for predicting disease recurrence in endometrioid endometrial carcinoma. *BMC Clin. Pathol.* 12, 22.
- Boruta 2nd, D.M., Gehrig, P.A., Fader, A.N., Olawaiye, A.B., 2009. Management of women with uterine papillary serous cancer: a Society of Gynecologic Oncology (SGO) review. *Gynecol. Oncol.* 115 (1), 142–153.
- Cardillo, T.M., Govindan, S.V., Sharkey, R.M., Trisal, P., Arrojo, R., Liu, D., et al., 2015. Sacituzumab govitecan (IMMU-132), an anti-Trop-2/SN-38 antibody-drug conjugate: characterization and efficacy in pancreatic, gastric, and other cancers. *Bioconjug. Chem.* 26 (5), 919–931.
- Cirisano Jr., F.D., Robboy, S.J., Dodge, R.K., Bentley, R.C., Krigman, H.R., Synan, I.S., et al., 1999. Epidemiologic and surgicopathologic findings of papillary serous and clear cell endometrial cancers when compared to endometrioid carcinoma. *Gynecol. Oncol.* 74 (3), 385–394.
- Conroy, T., Desseigne, F., Ychou, M., Bouche, O., Guimbaud, R., Becouarn, Y., et al., 2011. FOLFIRINOX versus gemcitabine for metastatic pancreatic cancer. *N. Engl. J. Med.* 364 (19), 1817–1825.
- Faltas, B., Goldenberg, D.M., Ocean, A.J., Govindan, S.V., Wilhelm, F., Sharkey, R.M., et al., 2016. Sacituzumab govitecan, a novel antibody—drug conjugate, in patients with metastatic platinum-resistant urothelial carcinoma. *Clin. Genitourin. Cancer* 14 (1), e75–e79.
- Goldenberg, D.M., Cardillo, T.M., Govindan, S.V., Rossi, E.A., Sharkey, R.M., 2015. Trop-2 is a novel target for solid cancer therapy with sacituzumab govitecan (IMMU-132), an antibody-drug conjugate (ADC). *Oncotarget* 6 (26), 22496–22512.
- Gray, J.E., Heist, R.S., Starodub, A.N., Camidge, D.R., Kio, E.A., Masters, G.A., et al., 2017. Therapy of small cell lung Cancer (SCLC) with a topoisomerase-I-inhibiting antibody-drug conjugate (ADC) targeting Trop-2, sacituzumab govitecan. *Clin. Cancer Res.* 23 (19), 5711–5719.
- Heist, R.S., Guarino, M.J., Masters, G., Purcell, W.T., Starodub, A.N., Horn, L., et al., 2017. Therapy of advanced non-small-cell lung Cancer with an SN-38-anti-Trop-2 drug conjugate, sacituzumab govitecan. *J. Clin. Oncol.* 35 (24), 2790–2797.
- Starodub, A.N., Ocean, A.J., Shah, M.A., Guarino, M.J., Picozzi Jr., V.J., Vahdat, L.T., et al., 2015. First-in-human trial of a novel anti-Trop-2 antibody-SN-38 conjugate, sacituzumab govitecan, for the treatment of diverse metastatic solid tumors. *Clin. Cancer Res.* 21 (17), 3870–3878.
- Varughese, J., Cocco, E., Bellone, S., de Leon, M., Bellone, M., Todeschini, P., et al., 2011. Uterine serous papillary carcinomas overexpress human trophoblast-cell-surface marker (Trop-2) and are highly sensitive to immunotherapy with hRS7, a humanized anti-Trop-2 monoclonal antibody. *Cancer* 117 (14), 3163–3172.