



ELSEVIER

Contents lists available at [ScienceDirect](https://www.sciencedirect.com)

## Respiratory Medicine Case Reports

journal homepage: [www.elsevier.com/locate/rmcr](http://www.elsevier.com/locate/rmcr)

# Endobronchial mucormycosis: A rare clinical entity diagnosed by endobronchial cryobiopsy

Awais Bajwa<sup>a,\*</sup>, Syed T. Hussain<sup>b</sup>, Houssein Youness<sup>b</sup>, Ravi N. Sawh<sup>c</sup>,  
Lichao Zhao<sup>c</sup>, Tony Abdo<sup>b</sup>

<sup>a</sup> Department of Medicine, University of Oklahoma Health Sciences Center, Oklahoma City, OK, 73104, USA

<sup>b</sup> Section of Pulmonary, Critical Care, and Sleep Medicine, University of Oklahoma Health Sciences Center, Oklahoma City, OK, 73104, USA

<sup>c</sup> Department of Pathology, Oklahoma City VA Health Care System, Oklahoma City, OK, 73104, USA

## ARTICLE INFO

## Keywords:

Cryobiopsy  
Diabetes mellitus  
Endobronchial mass  
Mucormycosis  
Pneumonia

## ABSTRACT

Mucormycosis is a rare fungal infection caused by fungi of the order Mucorales. The rhino-cerebral form of mucormycosis is most commonly seen in patients with diabetes mellitus, whereas pulmonary mucormycosis is a rare manifestation in patients with hematological malignancy and transplant recipients. We report a case of a 40-year-old male, with history of poorly controlled diabetes, who presented to the emergency room with a one-week history of hemoptysis. Computed Tomography (CT) of the chest was concerning for a lung mass or abscess. Flexible bronchoscopy revealed an endobronchial lesion that was biopsied with a cryoprobe. Histopathologic examination showed non-septate right-angle branching hyphae, typical of mucormycosis. He underwent surgical resection of the right middle and lower lobes and treatment with antimycotic agents with a complete recovery. This case highlights the importance of early histopathological diagnosis of pulmonary mucormycosis in preventing a fatal outcome.

## 1. Introduction

Mucormycosis is a life-threatening opportunistic mycosis that infects a broad range of hosts with qualitative or quantitative defects in innate immunity, including patients with severe neutropenia, recipients of corticosteroids or other immunosuppressive medications, and poorly controlled diabetes mellitus. The most implicated species belong to the *Rhizopus*, *Mucor*, and *Lichtheimia* (*Absidia*) genera. The primary mode of acquisition is through the inhalation of sporangiospores present in the environment. Traumatic inoculation and oral ingestion are other possible forms of transmission. Pulmonary mucormycosis results from inhalation of sporangiospores or by hematogenous or lymphatic spread. Patients present with nonspecific symptoms like cough, dyspnea, chest pain, and fever. In pulmonary mucormycosis, clinical diagnosis is difficult, and early diagnosis is paramount for this life-threatening infection. There are no reliable serological, PCR-based, or skin tests for mucormycosis. Sterile cultures do not rule out the diagnosis. Histopathology and positive cultures from various clinical specimens are the primary diagnostic modalities for mucormycosis. Treatment usually involves a combination of antifungal agents and surgical resection.

\* Corresponding author. Department of Medicine, University of Oklahoma Health Sciences Center, 800 Stanton L. Young Blvd, AAT 6300, Oklahoma City, OK, 73104, USA.

E-mail addresses: [awaisbajwa1@hotmail.com](mailto:awaisbajwa1@hotmail.com), [Awais-Bajwa@ouhsc.edu](mailto:Awais-Bajwa@ouhsc.edu) (A. Bajwa).

<https://doi.org/10.1016/j.rmcr.2022.101660>

Received 16 April 2022; Accepted 28 April 2022

Available online 3 May 2022

2213-0071/© 2022 The Authors. Published by Elsevier Ltd. This is an open access article under the CC BY-NC-ND license (<http://creativecommons.org/licenses/by-nc-nd/4.0/>).

## 2. Case report

A 40-year-old male with a past medical history of poorly controlled type 1 diabetes mellitus (HbA1c 10.3%) presented to the emergency department with a one-week history of fever, chills, shortness of breath, and hemoptysis. On admission, the patient was febrile (101 °F) and tachycardic (110 beats/min). He required 3 L of supplemental oxygen via nasal cannula to maintain oxygen saturation above 94%. The pulmonary exam was unrevealing. Laboratory workup was unrevealing, including a normal white blood cell count and procalcitonin. Chest X-ray was grossly unremarkable (Fig. 1). Computed Tomography (CT) of the chest showed a cavitary mass (3.5 × 2.9 cm) in the right lower lobe (Fig. 2). He was started on vancomycin and piperacillin/tazobactam after collecting sputum and blood cultures. Sputum was also sent for acid-fast bacillus (AFB) smear and culture. Throughout the course of hospitalization, these cultures remained negative.

Despite antibiotherapy, the patient's symptoms continued to worsen. A flexible bronchoscopy with endobronchial ultrasound-guided transbronchial needle aspiration (EBUS-TBNA) under general anesthesia was performed on day 7 of hospitalization. Bronchoscopy revealed a yellow-colored, friable, slimy, endobronchial mass occluding the right lower lobe bronchus (Fig. 3). Mediastinal and hilar lymph nodes were sampled, with rapid on-site cytology negative for malignancy. Endobronchial biopsies with cryoprobe were performed. Extraction of the lesion was attempted first with the cryoprobe, then by gastrointestinal biopsy forceps, and lastly with a polypectomy snare. However, the attempts were unsuccessful as the mass was very elastic, with the stem firmly attached to the right lower lobe parenchyma. Forceps biopsies and cytology brushing of the mass were also performed. Histopathological examination of the specimen from the mass was consistent with pulmonary mucormycosis, with broad, non-septate hyphae, characteristic of Mucorales species (Fig. 4). No malignant cells or fungal elements were seen on cytological examination of lymph nodes' aspirates, and the cultures were negative. The patient was started on Amphotericin B at 5 mg/kg daily on hospital day#11. Thoracic surgery was consulted, and right middle and lower lobes lobectomy was completed on hospital day#15 without any complication. The removed specimen is shown in Fig. 5. He finished a 14-day course of intravenous Amphotericin B with clinical improvement. He was transitioned to oral Posaconazole and discharged on hospital day#26. At the 3-month follow-up, he reported complete resolution of symptoms.

## 3. Discussion

Mucormycosis, also referred to as zygomycosis, is an opportunistic infection caused by a fungus that belongs to the class zygomycetes and is the third most common invasive fungal infection after candidiasis and aspergillosis. The most common agents of mucormycosis are *Rhizopus* spp., *Mucor* spp., and *Lichtheimia* (formerly *Absidia* and *Mycocladius*) spp. Genera of other Mucorales, such as *Rhizomucor*, *Saksenaia*, *Cunninghamella*, and *Apophysomyces*, are less common [1]. Most cases of mucormycosis result from the inhalation of fungal sporangiospores that have been released in the air or from direct inoculation of organisms into disrupted skin or gastrointestinal tract mucosa. Seasonal variations affect the incidence of mucormycosis, with most infections occurring from August to November. The incidence of mucormycosis has been increasing in recent decades, mainly due to the growth of the number of immunocompromised patients. Mucormycosis cases are being reported worldwide, but differences in the epidemiology seem to exist between developed and developing countries. In developed countries, the disease remains uncommon and is mostly seen in patients with diabetes, hematological malignancies and those who have received stem cell transplant. In contrast, in developing countries, mucormycosis occurs mainly in patients with uncontrolled diabetes and trauma [1].

The COVID-19 pandemic was associated with an increased incidence of mucormycosis including pulmonary mucormycosis [2]. COVID-19 infection, along with prolonged courses of corticosteroids and the use of immunosuppressive therapies compromise the host response and increase the risk to develop opportunistic infections, including those caused by molds [3].

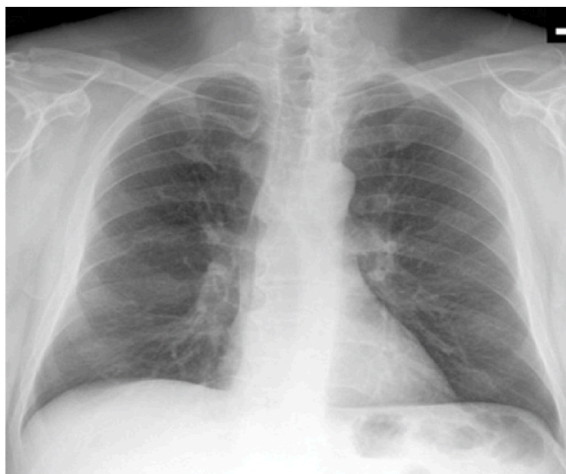


Fig. 1. Chest X-ray on admission.

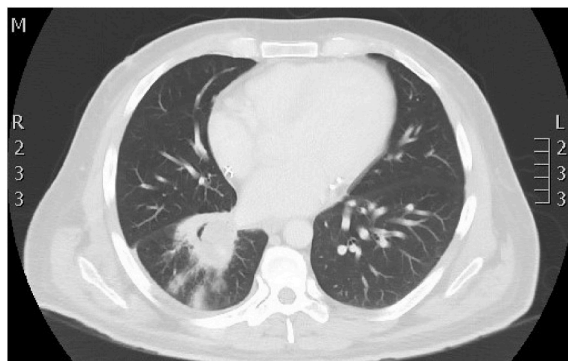


Fig. 2. Chest CT demonstrating a right lower lobe cavitating mass (3.5 × 2.9 cm).

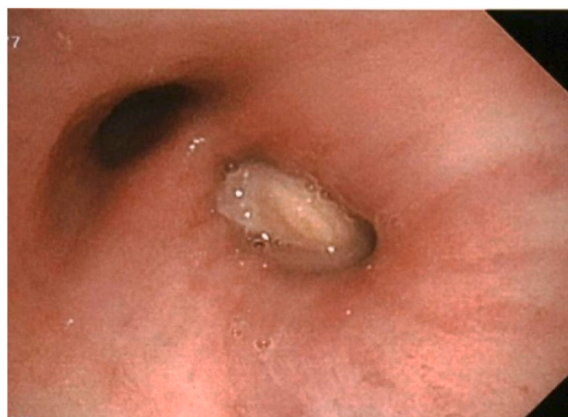

Fig. 3. Endobronchial lesion obstructing the right lower lobe bronchus.

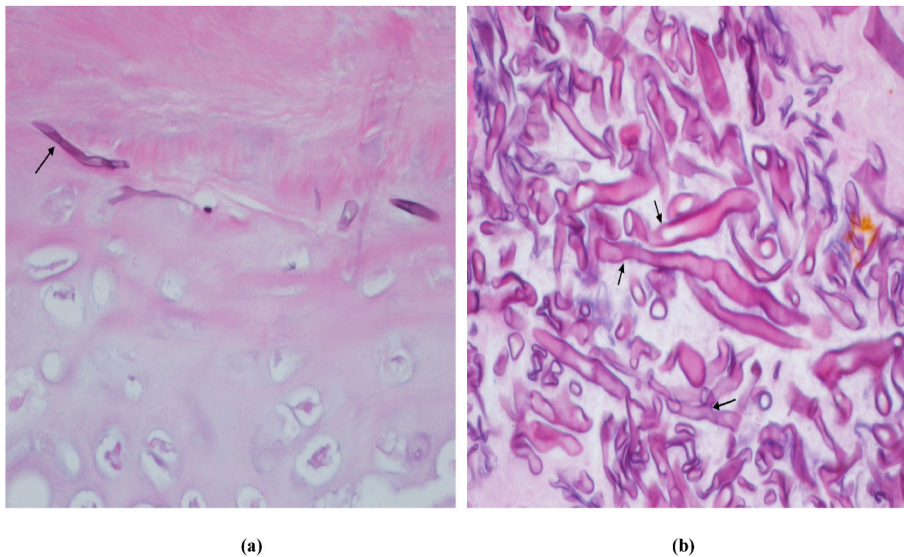


Fig. 4. (a) Fragments of necrotic cartilage with invasive fungal hyphae. (b) Broad, pauci-septate, and branching hyphae consistent with Mucorales (arrows).

Mucormycosis is usually seen in diabetic patients or patients with other risk factors, including cancer, acquired immunodeficiency syndrome, chemotherapy, organ transplantation, severe and prolonged neutropenia, iron chelation therapy, severe malnutrition, and prolonged use of corticosteroids [1]. Clinically observed forms of mucormycosis are rhino-cerebral, pulmonary, cutaneous,

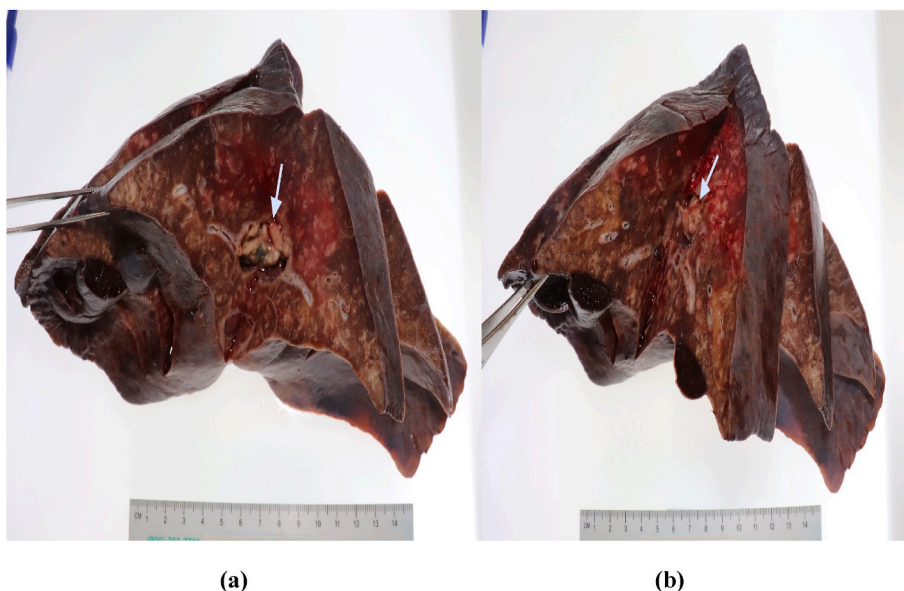


Fig. 5. (a) & (b) Showing resected right middle and lower lobes with mucor abscess seen in the airway.

gastrointestinal, disseminated, and others. The most common clinical presentations are rhino-orbito-cerebral, pulmonary, cutaneous, and disseminated mucormycosis. The percentages reported in a review by Jeong et al. were 34%, 21%, 20%, and 14%, respectively [4], while in the European study of the Working Group on Zygomycosis, they were 27%, 30%, 26%, and 15% [5].

The clinical manifestations of pulmonary mucormycosis may not be differentiated from other fungal or bacterial pulmonary infections. Patients may present with fever, cough, hemoptysis, and pleuritic chest pain. Hence, a tissue diagnosis is needed unless sputum culture is positive with imaging highly suggestive of invasive fungal infection.

Patients with suspected pulmonary mucormycosis should undergo a CT of the chest. A reversed halo sign, defined as a central area of ground glass opacity surrounded by a ring of consolidation or vessel occlusion on CT angiogram are the common findings [6]. Other radiographic presentations of pulmonary mucormycosis vary and include pulmonary infiltrates, cavity, consolidation, air crescent sign, pleural effusion, fistula, or pneumothorax [7]. In a few patients, the disease manifests as airway obstruction as the fungus invades bronchi and forms intrabronchial lesions similar to what was seen in our case. Bronchoscopy appears to be a successful diagnostic modality in diagnosing mucormycosis with airway involvement. Bronchoscopy usually reveals granulation tissue and grey-white mucoid material that frequently blocks the airway. The airways involved are typically edematous and necrotic, or lesions with an appearance suggestive of a bronchial adenoma [8]. In many cases, it is postulated that a submucosal, invasive fungal infection causes a submucosal abscess, which presents as an endobronchial mass [9]. A definitive diagnosis of endobronchial mucormycosis can only be made with a biopsy as the lesion may masquerade as a malignancy or a bacterial abscess. Sputum culture, used as a simple preliminary diagnostic method, is often negative. Histopathologically, Mucorales hyphae have variable width and are usually non-septated or pauci-septated. The wider and irregular nature of hyphae are more reliable distinguishing features than septations or angle of branching as a change in branching angles and false septations may occur during sample processing [6].

Pulmonary mucormycosis is highly angio-invasive. Fatal hemorrhage has been described in patients with endobronchial mucormycosis after a standard endobronchial forceps biopsy [10]. Therefore, the use of cryotherapy to obtain adequate size biopsy specimens while minimizing the risk of bleeding should be considered whenever possible [11]. In addition, endobronchial mucormycosis may be successfully treated with cryoablation [12]. However, the efficacy or safety of this approach is unclear. In our case, several attempts failed to extract the lesion completely, and the decision was made to stop given concern for arising complications related to the extent of lung involvement beyond the visible endobronchial lesion and the nature of the procedure (flexible bronchoscopy). Bronchoscopic management of endobronchial mucormycosis or other endobronchial fungal infections is not clearly defined, and the available literature is limited to case reports and case series [13]. The data about the safety, effectiveness, and outcomes of bronchoscopic management compared to medical therapy alone or in association with surgical management is currently lacking.

Current guidelines recommend a combined medical and surgical approach to management, as anti-fungal agents may have poor penetration at the site of the infection, and the disease is rapidly progressive and associated with a bad prognosis [14]. The main reasons for delaying or refusing lung surgery with pulmonary mucormycosis are the severity of underlying diseases and high operative risk. One of the studies concluded that the overall survival rate was poor in patients with lung mucormycosis, but it was significantly higher in patients who underwent surgical resection [15]. Amphotericin B, along with surgical resection of the involved areas of the lung and treatment of the underlying disease, is the mainstay of treatment [14]. Despite its renal toxicity, Amphotericin B (>5mg/kg) has been the gold-standard antifungal agent against mucormycosis [14]. It is effective, but its use is limited by its substantial toxicity specifically in the doses and treatment duration needed for mucormycosis. Isavuconazole is a triazole antifungal drug which has also been recommended as the first line agent for mucormycosis [6]. The efficacy of isavuconazole has been shown to be similar to

amphotericin B [16]. Isavuconazole salvage treatment has been successful when the other first-line agent had failed either due to refractory mucormycosis or drug-related toxicity [17]. Oral posaconazole is also recommended for the treatment of mucormycosis [18] as well as strongly supported for salvage therapy [19]. Voriconazole is ineffective against mucormycosis [20]. The duration of therapy is unknown. In general, the treatment is continued until the immune defect has resolved and clinical and radiological improvement is achieved [6]. The mean duration of the Isavuconazole first-line or salvage treatment was found to be 84 days [16]. Surgical therapy, such as wedge resection, lobectomy, and pneumonectomy, in combination with antifungal therapy, has been associated with lower mortality rates in published series of patients with Mucor infection, particularly in patients with disease confined to one lung [21]. Surgical resection should be done as soon as feasible to prevent dissemination and erosion into the vessels, resulting in potentially fatal massive hemoptysis.

#### 4. Conclusion

Pulmonary mucormycosis is an opportunistic angio-invasive fungal infection. Diagnosis is difficult due to nonspecific presentation. Physicians must have a high level of suspicion in immunocompromised patients with fever and respiratory symptoms refractory to antibiotherapy, with a low threshold for performing an invasive diagnostic procedure. Early diagnosis and treatment, including surgery and antifungal therapy, can improve outcomes and survival.

#### Author contributions

Conceptualization - A. Bajwa, H. Youness, T. Abdo.  
 Data curation – A. Bajwa.  
 Formal analysis – A. Bajwa, T. Abdo.  
 Funding acquisition – None.  
 Investigation – A. Bajwa, T. Abdo.  
 Methodology – A. Bajwa, S. Hussain.  
 Project administration – A. Bajwa, H. Youness, T. Abdo.  
 Resources – S. Hussain, R. Sawh, L. Zhao.  
 Software – None.  
 Supervision – H. Youness, T. Abdo.  
 Validation – S. Hussain, H. Youness, T. Abdo.  
 Visualization – H. Youness, T. Abdo.  
 Writing - Original Draft – A. Bajwa.  
 Writing – Review & Editing – S. Hussain, H. Youness, T. Abdo.

#### Declaration of competing interest

Authors have no conflicts of interest to declare.

#### Acknowledgment

This research did not receive any specific grant from funding agencies in the public, commercial, or not-for-profit sectors. We would like to thank our patient who consented to have his case discussed for educational purposes.

#### References

- [1] G. Petrikos, A. Skiada, O. Lortholary, E. Roilides, T.J. Walsh, D.P. Kontoyiannis, Epidemiology and clinical manifestations of mucormycosis, *Clin. Infect. Dis.* 54 (suppl\_1) (2012 Feb 1) S23–S34, <https://doi.org/10.1093/cid/cir866>.
- [2] D. Garg, V. Muthu, I.S. Sehgal, R. Ramachandran, H. Kaur, A. Bhalla, G.D. Puri, A. Chakrabarti, R. Agarwal, Coronavirus disease (Covid-19) associated mucormycosis (CAM): case report and systematic review of literature, *Mycopathologia* 186 (2) (2021 May) 289–298, <https://doi.org/10.1007/s11046-021-00528-2>.
- [3] B. Hanley, K.N. Naresh, C. Roufosse, A.G. Nicholson, J. Weir, G.S. Cooke, M. Thursz, P. Manousou, R. Corbett, R. Goldin, S. Al-Sarraj, Histopathological findings and viral tropism in UK patients with severe fatal COVID-19: a post-mortem study, *Lancet Microbe* 1 (6) (2020 Oct 1) e245–e253, [https://doi.org/10.1016/S2666-5247\(20\)30115-4](https://doi.org/10.1016/S2666-5247(20)30115-4).
- [4] W. Jeong, C. Keighley, S. Chen, *The Epidemiology, Management and Outcomes of Invasive Mucormycosis in the 21st Century: a Systematic Review*, ECCMID, 2017. P1445.
- [5] A. Skiada, L.I. Pagano, A. Groll, S. Zimmerli, B. Dupont, K. Lagrou, C. Lass-Flörl, E. Bouza, N. Klimko, P. Gaustad, M. Richardson, Zygomycosis in Europe: analysis of 230 cases accrued by the registry of the European confederation of medical mycology (ECMM) working Group on zygomycosis between 2005 and 2007, *Clin. Microbiol. Infect.* 17 (12) (2011 Dec 1) 1859–1867, <https://doi.org/10.1111/j.1469-0691.2010.03456.x>.
- [6] O.A. Cornely, A. Alastruey-Izquierdo, D. Arenz, S.C. Chen, E. Dannaoui, B. Hochhegger, M. Hoenigl, H.E. Jensen, K. Lagrou, R.E. Lewis, S.C. Mellinghoff, Global guideline for the diagnosis and management of mucormycosis: an initiative of the European confederation of medical mycology in cooperation with the mycoses study Group education and research consortium, *Lancet Infect. Dis.* 19 (12) (2019 Dec 1) e405–e421, [https://doi.org/10.1016/S1473-3099\(19\)30312-3](https://doi.org/10.1016/S1473-3099(19)30312-3).
- [7] F.Y. Lee, S.B. Mossad, K.A. Adal, Pulmonary mucormycosis: the last 30 years, *Arch. Intern. Med.* 159 (12) (1999 Jun 28) 1301–1309, <https://doi.org/10.1001/archinte.159.12.1301>.
- [8] A.W. Husari, W.A. Jensen, C.M. Kirsch, A.C. Campagna, F.T. Kagawa, K.A. Hamed, D.A. Stevens, Pulmonary mucormycosis presenting as an endobronchial lesion, *Chest* 106 (6) (1994) 1889–1891, <https://doi.org/10.1378/chest.106.6.1889>.
- [9] J.F. Donohue, Endobronchial mucormycosis, *Chest* 83 (3) (1983 Mar 1) 585, <https://doi.org/10.1378/chest.83.3.585b>.
- [10] P. Di Carlo, D. Cabibi, A.M. La Rocca, D. De Luca, F. La Licata, E. Sacco, Post-bronchoscopy fatal endobronchial hemorrhage in a woman with bronchopulmonary mucormycosis: a case report, *J. Med. Case Rep.* 4 (1) (2010 Dec) 1–4, <https://doi.org/10.1186/1752-1947-4-398>.

- [11] M. Zuñil, F. Villegas, J. Jareño, J. Martos-Peregrin, N. Llobregat, F.J. Terreros, L.M. Callol, Cryotherapy in the diagnosis of endobronchial mucormycosis, *J. Bronchol. Intervent. Pulmonol.* 8 (2) (2001 Apr 1) 107–109.
- [12] Y.H. Choe, Y.C. Lee, S.R. Kim, Endobronchial mucormycosis successfully treated with flexible bronchoscopic cryotherapy, *Am. J. Respir. Crit. Care Med.* 198 (3) (2018) 387–389, <https://doi.org/10.1164/rccm.201708-1581IM>.
- [13] S. Keshishyan, L. DeLorenzo, K. Hammoud, A. Avagyan, H. Assallum, K. Harris, Infections causing central airway obstruction: role of bronchoscopy in diagnosis and management, *J. Thorac. Dis.* 9 (6) (2017 Jun) 1707, <https://doi.org/10.21037/jtd.2017.06.31>.
- [14] K. Brunet, B. Rammaert, Mucormycosis treatment: recommendations, latest advances, and perspectives, *J. Mycol. Med.* 30 (3) (2020 Sep 1), 101007, <https://doi.org/10.1016/j.mycmed.2020.101007>.
- [15] O. Cornely, S.E. Arikan-Akdagli, E. Dannaoui, A.H. Groll, K. Lagrou, A. Chakrabarti, F. Lanternier, L.I. Pagano, A. Skiada, M. Akova, M.C. Arendrup, ESCMID and ECMM joint clinical guidelines for the diagnosis and management of mucormycosis 2013, *Clin. Microbiol. Infect.* 20 (2014 Apr) 5–26, <https://doi.org/10.1111/1469-0691.12371>.
- [16] F.M. Marty, L. Ostrosky-Zeichner, O.A. Cornely, K.M. Mullane, J.R. Perfect, G.R. Thompson III, G.J. Alangaden, J.M. Brown, D.N. Fredricks, W.J. Heinz, R. Herbrecht, Isavuconazole treatment for mucormycosis: a single-arm open-label trial and case-control analysis, *Lancet Infect. Dis.* 16 (7) (2016 Jul 1) 828–837, [https://doi.org/10.1016/S1473-3099\(16\)00071-2](https://doi.org/10.1016/S1473-3099(16)00071-2).
- [17] F.M. Marty, O.A. Cornely, K.M. Mullane, L. Ostrosky-Zeichner, R.M. Maher, R. Croos-Dabrera, Q. Lu, C. Lademacher, I. Oren, A.H. Schmitt-Hoffmann, M. Giladi, Isavuconazole for treatment of invasive fungal diseases caused by more than one fungal species, *Mycoses* 61 (7) (2018 Jul) 485–497, <https://doi.org/10.1111/myc.12777>.
- [18] A. Skiada, L.I. Pagano, A. Groll, S. Zimmerli, B. Dupont, K. Lagrou, C. Lass-Flörl, E. Bouza, N. Klimko, P. Gaustad, M. Richardson, Zygomycosis in Europe: analysis of 230 cases accrued by the registry of the European confederation of medical mycology (ECMM) working Group on zygomycosis between 2005 and 2007, *Clin. Microbiol. Infect.* 17 (12) (2011 Dec 1) 1859–1867, <https://doi.org/10.1111/j.1469-0691.2010.03456.x>.
- [19] R.N. Greenberg, K. Mullane, J.A. Van Burik, I. Raad, M.J. Abzug, G. Anstead, R. Herbrecht, A. Langston, K.A. Marr, G. Schiller, M. Schuster, Posaconazole as salvage therapy for zygomycosis, *Antimicrob. Agents Chemother.* 50 (1) (2006 Jan) 126–133, <https://doi.org/10.1128/AAC.50.1.126-133.2006>.
- [20] R. Fanci, P. Pecile, S. Di Lollo, C. Dini, A. Bosi, Pulmonary mucormycosis with cervical lymph node involvement in a patient with acute myeloid leukaemia: a case report, *Mycoses* 51 (4) (2008 Jul) 354–356, <https://doi.org/10.1111/j.1439-0507.2008.01494.x>.
- [21] B. Serio, R. Rosamilio, V. Giudice, P. Zeppa, S. Esposito, R. Fontana, S. Annunziata, C. Selleri, Successful management of pulmonary mucormycosis with liposomal amphotericin B and surgery treatment: a case report, *Inf. Med.* 20 (Suppl 2) (2012 Jan 1) S43–S47. PMID: 23042005.