

Anatomical and functional outcomes one year after vitrectomy and retinal massage for large macular holes

Debdulal Chakraborty, Sabyasachi Sengupta¹, Angshuman Mukherjee, Saptorshi Majumdar

Purpose: The aim of this study was to report results of macular hole closure, visual benefit and longitudinal changes in foveal architecture over 1 year following macular hole surgery with retinal massage. **Methods:** Records of patients with full thickness macular hole (FTMH) with minimum basal diameter of 550 μ who underwent vitrectomy, internal limiting membrane (ILM) peeling and retinal massage were drawn up. Retinal massage was performed after dye assisted ILM peeling, using a 27G flute needle with a long and soft silicone tip under air in a centripetal direction around the FTMH. At the end, 10% C₃F₈ gas was used as tamponade. The foveal contour at 1 year follow up was recorded based on its cross sectional appearance on OCT and was classified into U, V and irregular types of closure as previously described. **Results:** Forty-one eyes of 41 patients with a mean age of 70.4 \pm 6.9 years were included. The mean preoperative vision was 0.99 \pm 0.07 logMAR and mean maximum basal diameter of the FTMH was 835 \pm 208 μ . Macular hole closure was seen in all patients at 1-month follow up. The BCVA improved to 0.5 \pm 0.1 log MAR at 6 months ($P < 0.001$) and then stabilized. The U shaped closure was the commonest pattern ($n = 22$, 54%), followed by V-shaped closure ($n = 16$, 39%) while irregular closure was seen in 3 eyes (7%). **Conclusion:** Retinal massage after ILM peeling is a very simple, and as yet under-utilized manoeuvre that may improve hole closure rates and lead to potentially greater improvement in vision compared to existing techniques for large holes.

Key words: Internal limiting membrane peeling, macular hole, retinal massage

The surgical management of full-thickness macular holes has evolved considerably over the past 2 decades with current hole closure rates approaching more than 95%.^[1] Antero-posterior and tangential tractional forces involved in the pathogenesis^[2] of macular holes are eliminated during surgery with the induction of posterior vitreous detachment (PVD) and internal limiting membrane (ILM) peeling respectively. The role of ILM peeling in improving hole closure rates has been clearly shown with large randomized clinical trials.^[3-5] Despite a better understanding of the disease pathogenesis and surgical advances with small gauge vitrectomy, managing larger macular holes with a basal diameter of >400 microns is still challenging. Though some studies show good closure rates in holes <650 microns,^[6] the overall perception is that larger holes show lower closure rates and are associated with lesser visual gain.

The inverted flap technique has been shown to further enhance hole closure rates and is currently the technique of choice while dealing with larger holes >400 microns in size.^[7-10] Several modifications of this technique such as use of a temporal inverted flap,^[11] free ILM flap insertion,^[12] and others such as retinal expansion techniques,^[13] and use of autologous

blood,^[14] retinal graft^[15] and amniotic membrane^[16] as macular plugs have been described for surgical management of large macular holes. All these techniques employ the same principle of positioning of tissue such as ILM, retinal grafts and amniotic membrane within the macular hole which are postulated to act as a scaffold for glial proliferation over the tissue defect, ultimately leading to macular hole closure. However, visual improvement is only modest with these techniques.^[17]

Several different approaches have been described for treating large, persistent and recurrent macular holes which do not depend upon stuffing the macular hole with any material. The technique of "retinal massage" for closure of macular holes was first described by Alpatov more than a decade ago.^[18] More recently, Mohammed and Pai have induced serous macular detachment around the macular hole followed by parafoveal retinal massage to bring edges closer, gas tamponade, and face down positioning with good results.^[19] In view of these, retinal massage appears to be a promising alternative technique for surgical management of large macular holes. However, there are not enough studies that explore the role of this simple technique and report closure rates in large macular holes. In this paper, we report our results of macular hole closure,

Video Available on:
www.ijo.in

Access this article online

Website:
www.ijo.in

DOI:
10.4103/ijo.IJO_1680_20

Quick Response Code:



Vitreoretina Services, Disha Eye Hospitals, Kolkata, West Bengal, ¹Consultant Vitreoretinal Surgeon, Future Vision Eye Care and Research Centre, Mumbai, India

Correspondence to: Dr. Debdulal Chakraborty, Department of Vitreoretina Services, Disha Eye Hospitals, Ghosh Para Road, Barrackpore, Kolkata - 700 120, West Bengal, India. E-mail: devdc@rediffmail.com

Received: 13-Apr-2020
Accepted: 14-Sep-2020

Revision: 22-Jul-2020
Published: 16-Mar-2021

This is an open access journal, and articles are distributed under the terms of the Creative Commons Attribution-NonCommercial-ShareAlike 4.0 License, which allows others to remix, tweak, and build upon the work non-commercially, as long as appropriate credit is given and the new creations are licensed under the identical terms.

For reprints contact: WKHLRPMedknow_reprints@wolterskluwer.com

Cite this article as: Chakraborty D, Sengupta S, Mukherjee A, Majumdar S. Anatomical and functional outcomes one year after vitrectomy and retinal massage for large macular holes. Indian J Ophthalmol 2021;69:895-9.

visual benefit and longitudinal changes in foveal architecture over 1 year following vitrectomy, ILM peeling and retinal massage for large macular holes from an Indian population.

Methods

This was a retrospective study conducted at a tertiary eye care facility in eastern India from July 2017 to May 2018. The study was approved by the institutional ethics committee and was conducted as per the tenets of the declaration of Helsinki. Informed consent was obtained from all patients before commencement of surgery.

Adult patients presenting with large full-thickness macular hole defined as having minimum basal diameter of 550 microns (average of horizontal and vertical scan) without any coexistent ocular morbidity were offered surgery with vitrectomy, ILM peeling and retinal massage. Eyes with macular holes secondary to trauma, high myopia (axial length >26 mm), associated with retinal detachment or other retinal surgeries, and recurrent or persistent macular holes were excluded. Data of consecutive patients meeting inclusion criteria with a minimum of 1-year follow up were drawn up from a computerized database. Patient demographics such as age, gender, baseline best-corrected visual acuity (BCVA), duration of vision loss, axial length and maximum basal diameter on spectral-domain OCT scans (OptoVue Inc, Fremont, CA, USA) were recorded before macular hole surgery. On each of the visits at postoperative months 1, 3, 6 and 12, the BCVA, presence of ellipsoid zone defect and external limiting membrane defect on OCT scans were recorded. The foveal contour at 1 year follow up was recorded based on its cross-sectional appearance on OCT and was classified into U, V and irregular types of closure as previously described by Michalewska *et al.*^[11]

Surgical technique

All surgeries were performed under peribulbar anaesthesia using 25 G vitrectomy systems (Constellation, Alcon, USA) by three fellowship trained vitreoretinal (VR) surgeons. After making 3 pars plana vitrectomy ports, a core vitrectomy was completed and posterior vitreous detachment (PVD) was induced from the optic disc using diluted triamcinolone acetonide when required to visualize the posterior vitreous cortex. After completion of vitrectomy, the ILM was stained using brilliant blue dye (Auroblue BBG, Aurolab, Madurai, India) and ILM peeling was initiated in the peripapillary region using specialized ILM grasping forceps (Greishhaber, Alcon, USA). A large area of ILM was peeled measuring at least 2 disc diameters around the fovea [Video 1]. The ILM was peeled across the edges of the macular hole to ensure release of all tangential traction. After satisfactory peeling, a fluid gas exchange was performed and using a 27G flute needle with a long and soft silicone tip, the retina was massaged under air in a centripetal direction i.e., radially from periphery to centre around the macular hole, sparing the papillo-macular bundle in order to try and approximate the edges of the hole. This manoeuvre did not cause any significant petechial haemorrhage – as is often noted during ILM peeling in macular hole surgery. This was followed by aspiration of residual fluid from the centre of the hole using the same 27G soft-tipped cannula. Finally, the air was replaced with 10% C₃F₈ gas and the cannulas were removed and intraocular pressure checked. Patients were advised to maintain face-down position for

7 days after surgery and prescribed tapering topical steroids for 1 month.

Statistical analysis

All continuous variables were expressed as means with standard deviation or median with interquartile range (IQR) and categorical variables were expressed as proportions (*n*, %). Groups differences in continuous variables between two groups were analysed using the Student's *t* test or Wilcoxon's rank sum test and the analysis of variance (ANOVA) or Kruskal–Wallis test was used when comparing across more than two groups. The Chi-square or the Fischer's exact test was used to analyse group differences between categorical variables. Differences between continuous variables over time were analysed using the paired *t* test with Bonferroni's adjustments. All data were recorded using Microsoft Excel and analysed using STATA 12.1 I/c (Stata Corp, Fort Worth, Texas, USA). All *P* values below 0.05 were considered statistically significant.

Results

Forty-one eyes of 41 patients fulfilling the inclusion criteria were included in the study. The mean age of patients was 70.4 ± 6.9 years and 28 (68%) were women. The mean presenting visual acuity was 0.99 ± 0.07 logMAR units and the median duration of visual loss was 8 months (IQR = 6-9 months). The mean maximum basal diameter of the macular holes was 835 ± 208 μ (median = 869 μ, IQR = 670-892 μ). A positive correlation was noted between duration of symptoms and hole diameter [Fig. 1]. All patients were pseudophakic and the median axial length was 24.1 mm (IQR = 23.7-24.6 mm).

Macular hole closure was seen in all patients at 1-month follow up. The BCVA improved from 0.99 ± 0.07 logMAR to 0.87 ± 0.08 logMAR at 1 month follow up (*P* = 0.03). At three months follow up, there was further improvement to 0.6 logMAR units (*P* < 0.001) and this improved by one more line at 6 months [Table 1], The vision did not improve further at the 12-month time point. By six months however, vision had improved in all eyes.

The proportion of eyes with persistent ellipsoid zone defect reduced gradually from 80% at 1 month to 41% at 6 months follow up [Table 1] and then stabilized with 36% eyes still

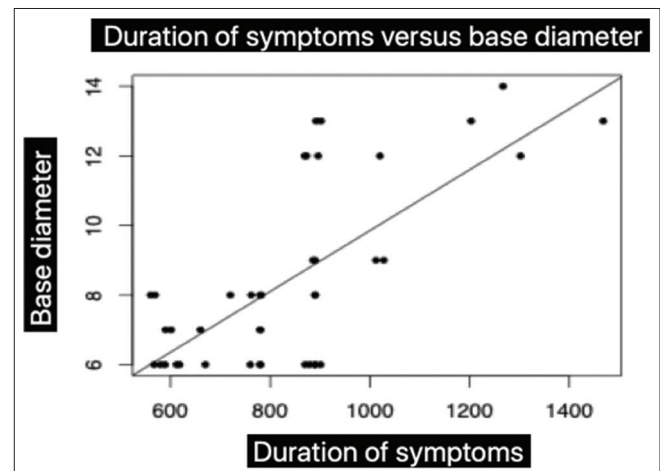


Figure 1: Duration of symptoms versus base diameter

Table 1: Comparison of BCVA, Ellipsoid zone defect and ELM defects over time

Variable	1 month	3 months	6 months	12 months
BCVA	0.87 ± 0.08	0.61 ± 0.11**	0.50 ± 0.11**	0.47 ± 0.13
Ellipsoid zone defect	33 (80%)	27 (66%)**	17 (41%)**	15 (36%)
ELM defect	25 (61%)	12 (29%)**	7 (17%)**	6 (15%)

P < 0.005 compared to previous time point of the same row

showing ellipsoid zone defect at 12 months [Fig. 2]. Similar trends were seen with ELM defect with gradually reducing proportion of eyes between 1 month and 6 months. At 12 months, 17% eyes still demonstrated an ELM defect [Table 1].

In terms of closure type, the U shaped closure was the commonest pattern (*n* = 22, 54%), followed by V-shaped closure (*n* = 16, 39%) while irregular closure was seen in 3 eyes (7%). Table 2 shows a comparison of demographics and various clinical parameters between eyes with U, V and irregular closure at different time points. Those with U shaped closure had slightly better vision, smaller basal diameter and shorter duration of vision loss compared to those with V-shaped and irregular pattern of closure. There was no difference in BCVA in these groups at 1 and 3 months, but at 6 months and 1 year, eyes with U closure had significantly better vision. Similarly, U closure eyes had significantly smaller proportion of eyes with persistent ellipsoid zone and ELM defects at every time point.

Discussion

We found that vitrectomy with ILM peeling, retinal massage under air, drying the hole and gas tamponade with face down positioning lead to closure in 100% eyes. Visual improvement continued to occur over 6 months after surgery after which the vision stabilized. Eyes with shorter duration of vision loss and relatively smaller holes with the basal diameter in the region of 750 microns experienced U-shaped hole closure which was in turn, associated with much better visual recovery. Eyes with V-shaped closure had persistent ellipsoid zone defect in majority of eyes which lead to BCVA of nearly 2 lines lower than those with U shaped closure.

The use of retinal massage has been described in the past to improve hole closure rates. Alpatov *et al.*^[18] described this procedure in 25 eyes where, after vitrectomy and ILM peeling, a blunt vitreoretinal spatula was used to flatten the macula from periphery to centre. Once the hole became slit-like, a vitreoretinal forceps was used to mechanically approximate the edges of the hole. Authors describe a hole closure rate of 92%, with 84% showing excellent tissue approximation at the fovea. Majority eyes showed sizeable improvement in vision by 3 months after surgery. Our technique appears to be similar to this, but much less traumatic since we use 25G transconjunctival sutureless ports as opposed to 20G instrumentation at the time of the series published by Alpatov (i.e. 2007), use of a 27G soft silicone tip as opposed to a spatula to perform the retinal massage and lack of tissue approximation using forceps as described by Alpatov.^[18] A blunt retinal massager has also been advocated for massaging the retina by others.^[20] We however found the soft-tipped cannula very handy in massaging the retina without causing significant trauma.

Mohammed *et al.* very recently (2017) described retinal massage after inducing serous retinal detachment using a 41

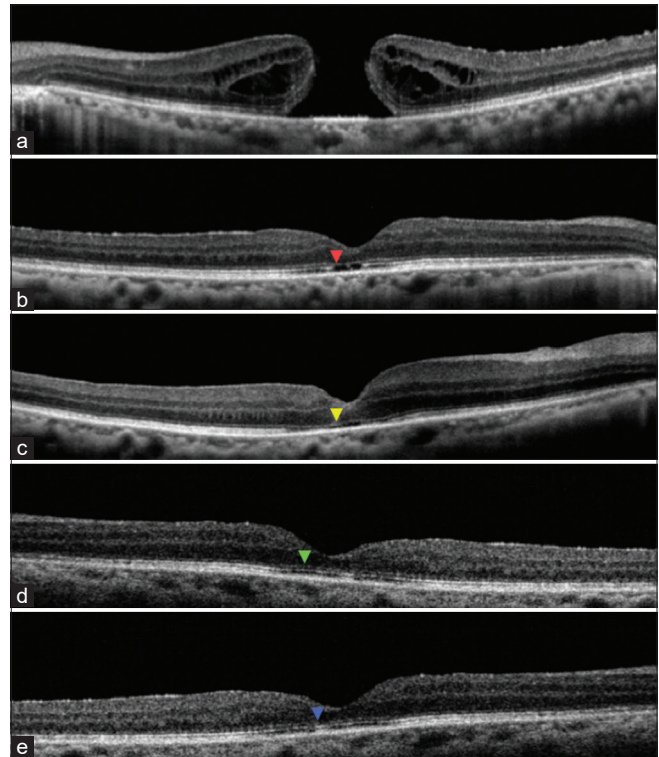


Figure 2: OCT scans preoperatively [Figure 1a] and at 1 month [Figure 1b], 3 months [Figure 1c], 6 Months [Figure 1d] and 12 months [Figure 1e] postoperatively with coloured arrowheads showing ellipsoid zone defects gradually reducing

gauge needle at three locations near the macular hole.^[19] Once the serous detachment was produced, a diamond-dusted scraper was used to massage the macula from periphery to centre to convert the round hole into a horizontally oriented transverse slit. Then, an end gripping forceps was used to pinch the temporal edges of MH once so that its edges come closer. Later, fluid-air-exchange was carried out with gas tamponade and facedown positioning for 1 week. Authors report 100% hole closure in all the 4 eyes with significant visual improvement, similar to our results. This technique appears to be very similar to the one described by Alpatov, with the addition of inducing further trauma in the form of localized retinal detachment. We did not feel the need to inject fluid under the retina to mobilize it before the massage.

In our opinion, glial proliferation over a scaffold, as occurs with the inverted flap and other material used as macular plugs, leads to anatomical closure but due to lack of differentiation into photoreceptors, this tissue is unable to perceive light and hence vision improvement is not gratifying.^[7] The approximation of photoreceptors without glial tissue has the potential to have greater vision improvement since glial tissue is not formed.

Table 2: Comparison of baseline and follow up characteristics between eyes with different type of hole closure pattern over time

Variable	Type U closure	Type V Closure	Irregular closure	P value
Number of eyes	22 (54%)	16 (39%)	3 (7%)	
Baseline characteristics				
Age	71.1 ± 6.8	67.8 ± 6.4	78.3 ± 4.5	0.04
Gender (% Female)	18 (82%)	8 (50%)	2 (67%)	0.11
BCVA	0.97 ± 0.07	1.0 ± 0.1	1.13 ± 0.11	0.055
Maximum basal diameter μ	746 ± 132	961 ± 234	820 ± 238	0.009
Duration of vision loss	6.8 ± 0.9	10.3 ± 2.9	9.6 ± 2.1	0.001
Axial length	24 ± 0.6	24.2 ± 0.5	24.5 ± 0.1	0.18
1 month				
BCVA	0.85 ± 0.07	0.91 ± 0.08	0.9 ± 0.1	0.14
Ellipsoid zone defect	14 (64%)	16 (100%)	3 (100%)	0.01
ELM defect	9 (41%)	13 (81%)	3 (100%)	0.015
3 months				
BCVA	0.58 ± 0.09	0.65 ± 0.11	0.63 ± 0.15	0.21
Ellipsoid zone defect	8 (36%)	16 (100%)	3 (100%)	<0.001
ELM defect	3 (14%)	6 (37%)	3 (100%)	0.006
6 months				
BCVA	0.43 ± 0.12	0.58 ± 0.04	0.60 ± 0	<0.001
Ellipsoid zone defect	3 (14%)	11 (69%)	3 (100%)	<0.001
ELM defect	1 (5%)	3 (19%)	3 (100%)	<0.001
12 months				
BCVA	0.38 ± 0.09	0.56 ± 0.07	0.60 ± 0	<0.001
Ellipsoid zone defect	2 (9%)	10 (63%)	3 (100%)	<0.001
ELM defect	1 (5%)	2 (12%)	3 (100%)	<0.001

Retinal massage or any another technique that can bring about photoreceptor approximation will therefore be more visually rewarding. We feel that using a long and soft silicone tipped cannula under air tamponade is the least traumatic way to perform retinal massage. We observed shrinkage of the round hole into a slit-like defect during surgery, exactly as described by Alpatov and Mohammed *et al.* despite using a soft-tipped silicone cannula, thereby obviating the need for massage with a spatula or inducing serous detachment. This may be because release of the tangential traction after ILM peeling makes the previously stiff retina relatively more mobile and amenable to re-approximation. The slit-like reduction of the hole was taken as the end point in our surgery, without trying to further approximate the edges with forceps. We believe that drying the hole thoroughly by performing fluid air exchange from the edges of the hole using the same atraumatic soft-tipped silicone needle has the same effect of further approximating the photoreceptors as attempted with forceps by the previous authors, with the current technique having the advantage of being less traumatic. The use of intraoperative OCT will help us assess this assumption in future studies.

We observed U shaped foveal morphology in eyes with holes of relatively smaller basal diameter (approximately 750 microns) and shorter duration and not surprisingly, these lead to the best improvement in vision. The size and duration of the macular hole have been well established as the prognostic factors influencing hole closure rates and vision improvement.^[5,12]

The advantages of our study are the relatively large sample of eyes operated by this lesser-known technique and follow up to a minimum of 1 year to see longitudinal OCT changes after surgery. However, our study being retrospective does have its limitations and drawbacks. One of the drawbacks was the lack of intraoperative OCT monitoring and the lack of a control group using more accepted surgical techniques for large macular holes. Retinal nerve fibre layer OCT was not evaluated and also microperimetry could not be performed. However, in their series, Mohan *et al.* found microperimetry did not show any adverse effects following retinal massage in large macular holes.^[20]

Conclusion

In conclusion, we believe that retinal massage after ILM peeling along with, drying the hole and gas tamponade is a very simple, and as yet under-utilized, and certainly under-reported manoeuvre, that will improve hole closure rates and lead to greater improvement in vision compared to existing techniques such as inverted flap and macular plugs. Head to head comparative studies, preferably using a randomized study design, and follow up of at least 6 months is required to assess whether retinal massage is as good as or better than inverted flap technique for closure of large macular holes.

Financial support and sponsorship

Nil.

Conflicts of interest

There are no conflicts of interest.

References

- Parravano M, Giansanti F, Eandi CM, Yap YC, Rizzo S, Virgili G. Vitrectomy for idiopathic macular hole. *Cochrane Database Syst Rev* 2015;CD009080.
- Bikbova G, Oshitari T, Baba T, Yamamoto S, Mori K. Pathogenesis and management of macular hole: Review of current advances. *J Ophthalmol* 2019;2019:3467381.
- Spiteri Cornish K, Lois N, Scott NW, Burr J, Cook J, Boachie C, *et al.* Vitrectomy with internal limiting membrane peeling versus no peeling for idiopathic full-thickness macular hole. *Ophthalmology* 2014;121:649-55.
- Chatziralli IP, Theodossiadi PG, Steel DHW. Internal limiting membrane peeling in macular hole surgery; why, when, and how? *Retina (Philadelphia, Pa)* 2018;38:870-82.
- Morescalchi F, Costagliola C, Gambicorti E, Duse S, Romano MR, Semeraro F. Controversies over the role of internal limiting membrane peeling during vitrectomy in macular hole surgery. *Surv Ophthalmol* 2017;62:58-69.
- Ch'ng SW, Patton N, Ahmed M, Ivanova T, Baumann C, Charles S, *et al.* The Manchester large macular hole study: Is it time to reclassify large macular holes? *Am J Ophthalmol* 2018;195:36-42.
- Gu C, Qiu Q. Inverted internal limiting membrane flap technique for large macular holes: A systematic review and single-arm meta-analysis. *Graefes Arch Clin Exp Ophthalmol* 2018;256:1041-9.
- Casini G, Mura M, Figus M, Loiudice P, Peiretti E, De Cillà S, *et al.* Inverted internal limiting membrane flap technique for macular hole surgery without extra manipulation of the flap. *Retina* 2017;37:2138-44.
- Rizzo S, Tartaro R, Barca F, Caporossi T, Bacherini D, Giansanti F. Internal limiting membrane peeling versus inverted flap technique for treatment of full-thickness macular holes: A comparative study in a large series of patients. *Retina* 2018;38(Suppl 1):S73-8.
- Yuan J, Zhang L-L, Lu Y-J, Han M-Y, Yu A-H, Cai X-J. Vitrectomy with internal limiting membrane peeling versus inverted internal limiting membrane flap technique for macular hole-induced retinal detachment: A systematic review of literature and meta-analysis. *BMC Ophthalmol* 2017;17:219.
- Michalewska Z, Michalewski J, Dulciewska-Cichecka K, Adelman RA, Nawrocki J. Temporal inverted internal limiting membrane flap technique versus classic inverted internal limiting membrane flap technique: A comparative study. *Retina* 2015;35:1844-50.
- Park JH, Lee SM, Park SW, Lee JE, Byon IS. Comparative analysis of large macular hole surgery using an internal limiting membrane insertion versus inverted flap technique. *Br J Ophthalmol* 2019;103:245-50.
- Chantarasom Y, Thamsriswadi P. Closure of large chronic macular hole by scleral imbrication and retinal expansion. *Ophthalmic Surg Lasers Imaging Retina* 2018;49:e57-64.
- Chakrabarti M, Benjamin P, Chakrabarti K, Chakrabarti A. Closing macular holes with "macular plug" without gas tamponade and postoperative posturing. *Retina* 2017;37:451-9.
- Wu A-L, Chuang L-H, Wang N-K, Chen K-J, Liu L, Yeung L, *et al.* Refractory macular hole repaired by autologous retinal graft and blood clot. *BMC Ophthalmol* 2018;18:213.
- Florent C, Coupier L, Mérité P-Y, Meyer F, Guigou S. Human amniotic membrane plug technique for macular hole surgery: A case report. *J Fr Ophtalmol* 2020;43:e151-2.
- Haritoglou C, Wolf A, Wachtlin J. Surgery of large and persistent macular holes. *Ophthalmologie* 2019;116:1011-9.
- Alpatov S, Shchuko A, Malyshev V. A new method of treating macular holes. *Eur J Ophthalmol* 2007;17:246-52.
- Mohammed OA, Pai A. New surgical technique for management of recurrent macular hole. *Middle East Afr J Ophthalmol* 2017;24:61-3.
- Mohan G, Nagpal M. Retinal massager: A new multifunctional tool for vitrectomy AIOS 2020; Innovation Session; Think under the apple tree; Feb 2020: AIOC 2020 proceedings. Available at <https://www.aios.org/aios-proceedings-1.php>. [Last accessed on 2020 Jul 28].