

Case Report

Desmoid Fibromatosis of the Abdominal Wall: Surgical Resection and Reconstruction with Biological Matrix Egis®

Saveria Tropea^a Simone Mocellin^a Roberto Stramare^b
Maria Giuseppina Bonavina^c Carlo Riccardo Rossi^a Marco Rastrelli^a

^aSurgical Oncology Unit, Veneto Institute of Oncology, IOV-IRCCS, Padua, Italy; ^bRadiology Unit, University of Padova, Padua, Italy; ^cMedical Direction Unit, Veneto Institute of Oncology, IOV-IRCCS, Padua, Italy

Keywords

Fibromatosis · Abdominal wall · Acellular dermis · Regeneration

Abstract

Desmoid tumor is a rare monoclonal fibroblast proliferation that is regarded as benign. The clinical management of desmoid tumors is very complex and requires a multidisciplinary approach because of the unpredictable disease course. For those cases localized in the anterior abdominal wall, symptomatic and unresponsive to medical treatment, radical resection and reconstruction with a prosthetic device are indicated. We present here a case of desmoid fibromatosis of the left anterolateral abdominal wall with a marked increase of the mass that required a large excision followed by reconstruction with biological matrix. The fact that it can be incorporated in patient tissue without a fibrotic response and that it can resist future infections, together with a very competitive price, made the new collagen matrix Egis® our first choice.

© 2017 The Author(s)
Published by S. Karger AG, Basel

Introduction

Desmoid tumors (DTs), also called aggressive fibromatosis, are very rare with an estimated incidence of 2–5 cases per million of inhabitants in European countries [1, 2]. DTs lack the capacity to metastasize but may behave in a locally aggressive fashion and possess a high risk of local recurrence despite adequate surgical resection with negative margins [1, 3]. DTs can develop in any musculoaponeurotic structure and they may be located at virtually any anatomical site. The principal sites of involvement for extra-abdominal fibromatosis are the shoulder, chest wall and back, thigh and head and neck region. Intra-abdominal fibromatosis arises in the mesentery or pelvis while abdominal tumors arise from musculoaponeurotic structures of the abdominal wall, especially the rectus and internal oblique muscles and their fascial coverings [4, 5].

In the surgically treated patients who experience recurrence of DT (local recurrence rates are about 25–65%) a wide excision is needed in some cases [6]. Synthetic meshes often used in extensive abdominal wall reconstruction may present with complications, including infection, bowel adhesion, extrusion, and fistula according to the prosthetic material used [7]. A prosthetic material with more favorable properties than traditional mesh could have a major effect on surgical practice and patient outcomes, avoiding chronic inflammation and resisting infection after implantation [8]. Considering Baumann's description of the ideal biomaterial for abdominal wall repair, our choice was directed towards a not cross-linked acellular dermal matrix (ADM) which remodels into host tissue. The matrix serves as a scaffold and becomes rapidly revascularized and infiltrated with host cells, avoiding fibrotic reaction and encapsulation as well as seroma formation. The revascularization of biological matrices is thought to promote access of host immune cells as well, thereby providing further resistance to future infections.

This is the first report about the use of the not cross-linked dermal matrix Egis® in a case of abdominal wall reconstruction after extensive DT resection.

Case Presentation

In 2008, a 37-year-old woman underwent, in a different hospital, exeresis of a neofor- mation in the epigastric region of the abdominal wall and reinforcement with small prosthet- ic mesh. The histopathological examination confirmed the diagnosis of desmoid-type fibro- matosis. In her history she reported an appendectomy, two pregnancies with cesarean births and a voluntary interruption of pregnancy.

In 2014, a recurrence occurred in the context of the rectus abdominis in the left iliac fos- sa.

The patient therefore underwent tamoxifen therapy for 1 year followed by 3 months of neoadjuvant chemotherapy for progressive disease. In September 2015, magnetic resonance imaging (MRI) was performed for tumor staging (Fig. 1a, c, e), which revealed a marked pro- gression of the disease (calculated size 18 × 10 × 6.4 cm). After discussions at our Multidisci- plinary Sarcoma Meeting, the group decision was to treat the patient surgically. One month later, the woman had a surgical resection through a suprapubic transverse incision. The ab- dominal flap was cranially detached; the neofor- mation invaded completely the left ab- dominal rectus muscle and partially oblique muscles with an extension of approximately 30 × 20 cm (Fig. 1a, 2a). The rectus muscle and a large portion of the oblique and transverse muscles were removed “en bloc” with 1 cm of healthy margin from the mass (Fig. 2b, c). In-

traperitoneal drainage was placed, and a wide continuous solution was adopted in the left abdomen. The not cross-linked porcine dermal matrix Egis® (Decomed, Venice, Italy) 30 × 20 cm, 1.5 mm thick, was hydrated for 10 min in sterile saline solution and then secured with interrupted absorbable suture (Vicryl 2/0) to the fascia and abdominal wall muscles (Fig. 2d, e); another two drains were placed over the matrix. We performed caudal mobilization of the abdominal flap and then dermolipectomy of the superfluous integument. The navel was positioned 10 cm from the suprapubic incision.

The postoperative course was uneventful and the patient was discharged on the 8th postoperative day. There was no evidence of recurrence of the tumor or incisional hernia at 12 months of follow-up (Fig. 1b, d, f) and the membrane turned out to be completely incorporated with the surrounding tissues.

Histological examination of the resected specimen (17 × 10 × 6 cm) revealed tumor-free margins and a whitish lesion with increased thickness and fibrous appearance, which had almost completely invaded the abdominal muscle. The diagnosis was confirmed by the presence of spindle-cellular tumors which had immigrated through muscle tissues as shown by nuclear β-catenin staining.

Discussion

DFs are neoplasms with infiltrating growth and with a tendency toward local recurrences; nevertheless, they lack metastatic potential. Although the morphologies of these tumors have been well characterized, their nature and pathogenesis have remained obscure for many years [6, 9]. According to the literature, the median age at the diagnosis of DFs is about 35 years, and the majority of patients are women [10]. In particular, patients between puberty and the fourth decade of life tend to be female, and in these patients the abdominal wall is the preferred site of involvement [4]. Supposed risk factors of desmoids are previous surgical interventions, pregnancy, and hormonal treatment with estrogens [6].

Because the tumor biology is notoriously unpredictable, periods of rapid tumor growth can be followed by stability or even regression [11]. The treatment with tamoxifen, as well as chemotherapy and radiation, is controversial, since the long-term clinical improvement is minimal, while surgical excision should be performed only when absolutely necessary [6].

A wide disease-free margin is crucial for reducing the recurrence rate. Abdominal wall integrity after full-thickness surgery can be restored with direct suture, but the occurrence of postoperative incisional hernia is highly reported. For this reason one-stage reconstruction with prosthetic abdominal wall reinforcement increases the chance of definitive cure, enhancing the patient's perceived quality of treatment [12]. Indeed, Luijendijk et al. [13] in a multicenter, randomized controlled trial observed a double rate of hernia recurrence in the primary suture group compared with the mesh reinforcement group.

The meshes used are classified according to their gap size which defines the porosity of the mesh and consequently the behavior with surrounding tissue, but a common tendency to develop postoperative complications was reported with all these devices [12].

Synthetic meshes are usually associated with an increased risk of extrusion, adhesion, and following obstruction and enterocutaneous fistula formation, especially when placed in an overlay fashion [12]. Moreover, patients who have had radiation to the abdominal wall prior to reconstruction are at increased risk for wound healing complications and subsequent mesh exposure. For that reason, Butler et al. [14] recommend avoiding synthetic meshes in patients with radiated abdominal walls.

The advent of biological matrices has added a valuable option to the field of abdominal wall reconstruction. The inherent ability of biological matrix to turn into patient self-tissue, and therefore resist infection, allows to implant it in direct contact with the bowel, resulting in fewer adhesions than prosthetic mesh [8, 12]. These bioprosthetic devices, deriving from human or animal dermis, are chemically and enzymatically cleaned to remove all cellular components while maintaining the extracellular matrix, which can be cross-linked or not. It is hypothesized that cross-linking treatment adds strength to the matrix, theoretically resulting in lower rates of hernia recurrence as compared to non-cross-linked products. In contrast Butler et al. [14] in a comparative study had not appreciated any mechanical differences between cross-linked and non-cross-linked matrices. Moreover cross-linked matrices revealed delayed revascularization and higher percentage of adhesions resulting in poor integration regarding non-cross-linked ADMs.

Despite the great advantages reported about the biological matrices, the high price that distinguishes them, ranging from USD 8.60/cm² to USD 22.00/cm², remains a high deterrent to their use [15].

One variation of the biological materials, Egis®, has not been described yet in the literature for abdominal wall reconstruction after tumor excision. Egis® (Decomed, Venice, Italy) is a dry porcine ADM, non-cross-linked, without any chemical preservative; its very competitive price, about half of the aforementioned costs, allows us to choose the benefits of a biological matrix with the advantage of controlled expense.

We report for the first time the successful use of Egis® in a complex abdominal wall reconstruction following the resection of a large DT. The matrix was well accepted without any postoperative complications and no evidence of recurrence of the tumor or incisional hernia has been reported 12 months later.

In conclusion, this single-case experience makes us to consider the biological matrix Egis®, as well as other ADMs, an ideal alternative to synthetic mesh, mainly in cases with a potential risk of infection. ADM graft could be a useful addition to minimize morbidity and recurrence.

Statement of Ethics

The protocol for data collection of this case has been approved by the institute's committee and complies with the Helsinki guidelines for human studies. We gave all the information to the patient and obtained signed informed consent.

Disclosure Statement

No funding was provided for the preparation of this paper. The authors have no relevant conflicts of interest or financial disclosures.

References

- 1 Penel N, Coindre JM, Bonvalot S, Italiano A, Neuville A, Le Cesne A, Terrier P, Ray-Coquard I, Ranchere-Vince D, Robin YM, Isambert N, Ferron G, Duffaud F, Bertucci F, Rios M, Stoeckle E, Le Pechoux C, Guillemet C, Courreges JB, Blay JY: Management of desmoid tumours: a nationwide survey of labelled reference centre networks in France. *Eur J Cancer* 2016;58:90–96.

- 2 Rastrelli M, Tropea S, Basso U, Roma A, Maruzzo M, Rossi CR: Soft tissue limb and trunk sarcomas: diagnosis, treatment and follow-up. *Anticancer Res* 2014;34:5251–5262.
- 3 Colombo C, Miceli R, Lazar AJ, Perrone F, Pollock RE, Le Cesne A, Hartgrink HH, Cleton-Jansen AM, Domont J, Bovée JV, Bonvalot S, Lev D, Gronchi A: CTNNB1 45F mutation is a molecular prognosticator of increased postoperative primary desmoid tumor recurrence: an independent, multicenter validation study. *Cancer* 2013;119:3696–3702.
- 4 Fletcher CDM, Bridge JA, Hogendoorn PCW, Mertens F (eds): *WHO Classification of Tumours of Soft Tissue and Bone. Pathology and Genetics of Tumours of Soft Tissue and Bone*, ed 4. Lyon, IARC Press, 2013.
- 5 Kasper B, Baumgarten C, Bonvalot S, Haas R, Haller F, Hohenberger P, Moreau G, van der Graaf WT, Gronchi A; Desmoid Working Group: Management of sporadic desmoid-type fibromatosis: a European consensus approach based on patients' and professionals' expertise – a sarcoma patients EuroNet and European Organisation for Research and Treatment of Cancer/Soft Tissue and Bone Sarcoma Group initiative. *Eur J Cancer* 2015;51:127–136.
- 6 Bonvalot S, Desai A, Coppola S, Le Péchoux C, Terrier P, Dômont J, Le Cesne A: The treatment of desmoid tumors: a stepwise clinical approach. *Ann Oncol* 2012;23(suppl 10):x158–x166.
- 7 Brown GL, Richardson JD, Malangoni MA, Tobin GR, Ackerman D, Polk HC Jr: Comparison of prosthetic materials for abdominal wall reconstruction in the presence of contamination and infection. *Ann Surg* 1985;201:705–711.
- 8 Baumann DP, Butler CE: Bioprosthetic mesh in abdominal wall reconstruction. *Semin Plast Surg* 2012;26:18–24.
- 9 Meneghello C, Ousghir B, Rastrelli M, Anesi L, Sommariva A, Montesco MC, Rossi CR, Hladnik U, Segat D: Nuclear GSK-3 β segregation in desmoid-type fibromatosis. *Histopathology* 2013;62:1098–1108.
- 10 Van Broekhoven DL, Grünhagen DJ, den Bakker MA, van Dalen T, Verhoef C: Time trends in the incidence and treatment of extra-abdominal and abdominal aggressive fibromatosis: a population-based study. *Ann Surg Oncol* 2015;22:2817e23.
- 11 Enzo MV, Rastrelli M, Rossi CR, Hladnik U, Segat D: The Wnt/ β -catenin pathway in human fibrotic-like diseases and its eligibility as a therapeutic target. *Mol Cell Ther* 2015;3:1.
- 12 Khansa I, Janis JE: Modern reconstructive techniques for abdominal wall defects after oncologic resection. *J Surg Oncol* 2015;111:587–598.
- 13 Luijendijk RW, Hop WC, van den Tol MP, de Lange DC, Braaksma MM, IJzermans JN, Boelhouwer RU, de Vries BC, Salu MK, Wereldsma JC, Bruijninx CM, Jeekel J: A comparison of suture repair with mesh repair for incisional hernia. *N Engl J Med* 2000;343:392–398.
- 14 Butler CE, Burns NK, Campbell KT, Mathur AB, Jaffari MV, Rios CN: Comparison of cross-linked and non-cross-linked porcine acellular dermal matrices for ventral hernia repair. *J Am Coll Surg* 2010;211:368–376.
- 15 Shankaran V, Weber DJ, Reed RL 2nd, Luchette FA: A review of available prosthetics for ventral hernia repair. *Ann Surg* 2011;253:16–26.

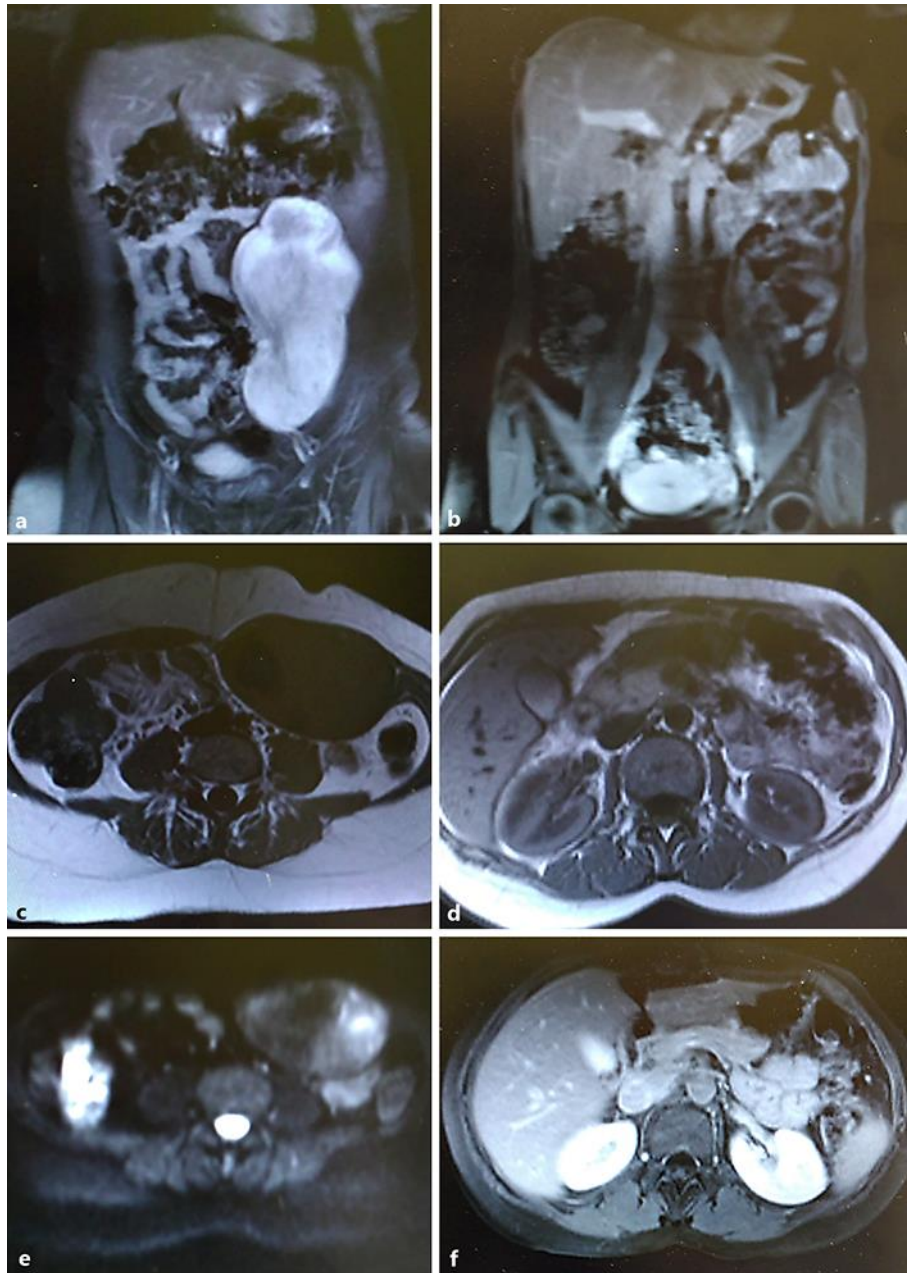


Fig. 1. Preoperative body imaging study with MRI confirms the presence of a solid mass of about $18 \times 10 \times 6.4$ cm on the left abdominal wall: frontal section (a) and transverse plane (c, e). 12-month postoperative MRI shows no evidence of recurrence of the tumor or incisional hernia: frontal section (b) and transverse plane (d, f).

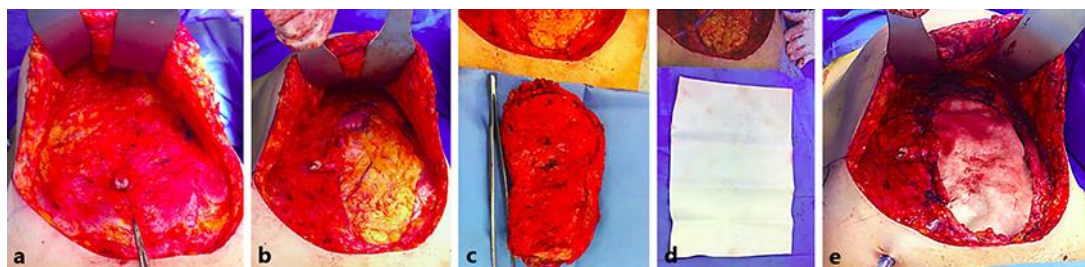


Fig. 2. **a** Intraoperative view of the mass before resection. **b** Size of the defect created in the abdominal wall after the resection. **c** Size of the resected tumor. **d** Egis® membrane 30 × 20 cm used to cover the defect. **e** The membrane is sutured to the abdominal wall to reconstruct it.