

A Rare Endoscopic Finding – Swiss Cheese Esophagus

Inês Simão Rui Mendo Pedro C. Figueiredo

Department of Gastroenterology, Centro Hospitalar de Lisboa Ocidental, Lisbon, Portugal

Keywords

Dysphagia · Esophageal pseudodiverticulosis · Esophageal stricture

Pseudodiverticulose esofágica – um queijo suíço

Palavras Chave

Disfagia · Pseudodiverticulose esofágica · Estenose esofágica

© 2023 The Author(s).
Published by S. Karger AG, Basel

A 54-year-old male was referred to a gastroenterology appointment with a 15-year history of dysphagia. He had a medical history of metastatic lung adenocarcinoma and is currently under pembrolizumab treatment. He was an active smoker (63 pack-years) and drank 10 alcohol units a day. He presented with progressive dysphagia to solids and, in the last 4 years, intermittent for liquids, with progressive weight loss (10% of body weight loss in the past 6 months) with a body mass index of 16.8 kg/m². He was previously assessed in different hospitals and performed numerous exams, including upper endoscopy showing a sloughing esophageal mucosa with signs of candida infection and narrowing of the distal esophagus. Histopathology was compatible with esophageal candidiasis with unspecific chronic inflammation. He

underwent several endoscopic dilations, the last one roughly 12 years before, with later symptom recurrence and was lost to follow-up. An upper endoscopy performed in our center displayed esophageal pseudodiverticulosis (EP) with distal strictures with underlying regular mucosa that were not transposable by the endoscope (Fig. 1). Esophageal biopsies excluded eosinophilic esophagitis. The patient was advised for lifestyle changes, including smoking cessation and alcohol abstinence. He underwent endoscopic dilation of two distal esophageal strictures using a through-the-scope balloon, with prior intralesional steroid injection (2 mg of dexamethasone into each quadrant), up to 15 mm diameter (shown in Fig. 2), with initial dysphagia improvement and weight gain. Afterward, a proton pump inhibitor was initiated in order to reduce stricture recurrence. At 3-month follow-up, the patient had symptom relapse, namely, dysphagia for solids, and was proposed to an additional endoscopic dilation.

EP is a rare condition characterized by multiple out-pouching lesions of the esophageal wall, representing dilated ducts of submucosal glands [1]. Inflammation and increased intramural pressure are thought to be the main mechanisms behind these false diverticula [2]. Distribution can be segmental or diffuse [2]. Etiology is still unclear, but tobacco smoking and alcohol consumption appear to be risk factors [1, 3]. Other associations include candida infection, caustic ingestion, gastroesophageal reflux disease, or diabetes mellitus [1, 2]. The most typical

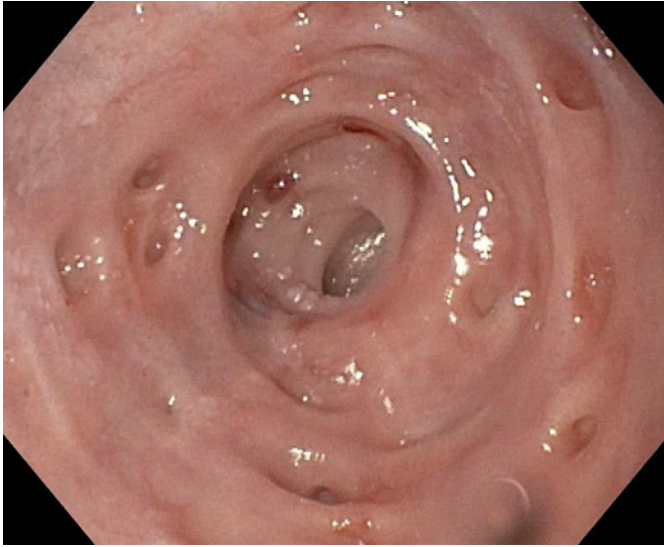


Fig. 1. Distal esophagus with pseudodiverticulosis and a regular esophageal stricture.

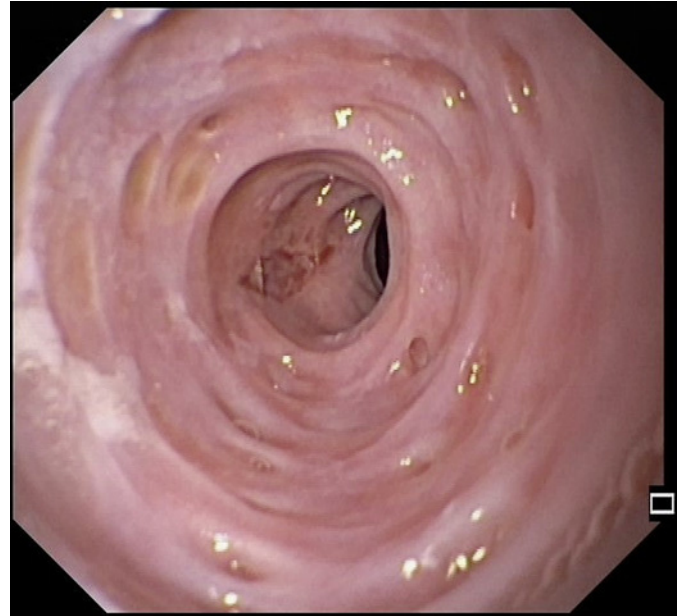


Fig. 2. Post-dilation stricture.

symptom is chronic dysphagia, which can be constant, intermittent, or progressive, classically for solids, and can persist for years [2, 3]. This symptom is usually associated with other conditions, such as esophageal stricture or candidiasis, rather than attributable to the EP [1, 2]. In the present case, a distal stenosis causing an increased intraluminal pressure is a possible mechanism for this endoscopic finding, as the outpouchings were not previously described and appeared over the course of a long-standing stricture. Endoscopy is significant for excluding coexisting disorders, especially in a patient presenting with dysphagia; however, barium studies are more sensible in diagnosing EP [2, 4]. Treatment is mainly supportive and should be directed at the underlying condition, with elimination of risk factors and control of associated comorbidities [1, 2]. In the presence of an esophageal stricture, dilation has been reported to be an effective and safe procedure, providing symptomatic improvement, with up to 57% requiring multiple procedures [2, 4].

Statement of Ethics

Ethical approval was not required for this study in accordance with local/national guidelines. Written informed consent was obtained from the patient for publication of this case report and any accompanying images.

Conflict of Interest Statement

The authors have no conflicts of interest to declare.

Funding Sources

The authors have no funding sources to declare.

Author Contributions

Inês Simão, Rui Mendo, and Pedro C. Figueiredo contributed to manuscript concept and design; Inês Simão drafted the manuscript; Rui Mendo and Pedro C. Figueiredo performed a critical revision of the manuscript for important intellectual content.

Data Availability Statement

All data generated or analyzed during this study are included in this article. Further inquiries can be directed to the corresponding author.

References

- 1 Halm U, Lamberts R, Knigge I, Mössner J, Zachäus M. Esophageal intramural pseudo-diverticulosis: endoscopic diagnosis and therapy. *Dis Esophagus*. 2014 Apr;27(3):230–4.
- 2 Naqvi H, Yousaf M, Sandhu G, Bhansali D, Farooqi R. Recurrent dysphagia associated with esophageal intramural pseudodiverticulosis. *Case Rep Gastroenterol*. 2021;15(2):551–6.
- 3 Hentschel F, Lüth S. Clinical and endoscopic characteristics of diffuse esophageal intramural pseudo-diverticulosis. *Esophagus*. 2020 Oct;17(4):492–501.
- 4 Ali O, Asumu H, Kaur T, Mathew A, Kim R. A rare cause of dysphagia due to esophageal intramural pseudodiverticulosis: a case report and review of literature. *BMC Gastroenterol*. 2020;20(1):72.