



Contents lists available at ScienceDirect

Molecular Genetics and Metabolism Reports

journal homepage: <http://www.journals.elsevier.com/molecular-genetics-and-metabolism-reports/>



Medium-chain triglyceride supplementation under a low-carbohydrate formula is a promising therapy for adult-onset type II citrullinemia[☆]

Kiyoshi Hayasaka^{a,*}, Chikahiko Numakura^a, Kentaro Toyota^a, Satoru Kakizaki^b, Hisayoshi Watanabe^c, Hiroaki Haga^c, Hiroshi Takahashi^d, Yoshimi Takahashi^e, Mieko Kaneko^b, Mitsunori Yamakawa^f, Hiroyuki Nunoi^g, Takeo Kato^e, Yoshiyuki Ueno^c, Masatomo Mori^b

^a Dept. of Pediatrics, Yamagata University School of Medicine, Yamagata, Japan

^b Dept. of Medicine and Molecular Science, Gunma University Graduate School of Medicine, Maebashi, Gunma, Japan

^c Dept. of Gastroenterology, Yamagata University School of Medicine, Yamagata, Japan

^d Dept. of Internal Medicine, Prefectural Ninohe Hospital, Iwate, Japan

^e Dept. of Neurology, Hematology, Metabolism, Endocrinology, and Diabetology, Yamagata University School of Medicine, Yamagata, Japan

^f Dept. of Pathological Diagnostics, Yamagata University School of Medicine, Yamagata, Japan

^g Division of Pediatrics, Dept. of Reproductive and Developmental Medicine, University of Miyazaki, Miyazaki, Japan

ARTICLE INFO

Article history:

Received 13 December 2013

Accepted 13 December 2013

Available online 14 January 2014

Keywords:

Neonatal intrahepatic cholestasis (NICCD)

Adult-onset type II citrullinemia (CTLN2)

Citrin deficiency

Medium-chain triglycerides (MCT)

SLC25A13

Malate-aspartate shuttle

ABSTRACT

Background: Citrin, encoded by *SLC25A13*, is a component of the malate-aspartate shuttle, which is the main NADH-transporting system in the liver. Citrin deficiency causes neonatal intrahepatic cholestasis (NICCD), which usually resolves within the first year of life. However, small numbers of adults with citrin deficiency develop hyperammonemic encephalopathy, adult-onset type II citrullinemia (CTLN2), which leads to death due to cerebral edema. Liver transplantation is the only definitive therapy for patients with CTLN2. We previously reported that a lactose (galactose)-restricted and medium-chain triglyceride (MCT)-supplemented formula is notably

Abbreviations: NICCD, neonatal intrahepatic cholestasis; CTLN2, adult-onset type II citrullinemia; MCT, medium-chain triglycerides; ASS1, arginosuccinate synthetase 1; ALT, alanine aminotransferase; γ -GTP, gamma-glutamyl transpeptidase; PSTI, pancreatic secretory trypsin inhibitor; AST, aspartate aminotransferase; LDH, lactate dehydrogenase; ChE, cholinesterase; ALP, serum alkali phosphatase; TIBC, total iron-binding capacity; UIBC, unsaturated iron-binding capacity; BMI, body mass index; MCFA, medium-chain free fatty acids; PPAR, peroxisome proliferator-activated receptor.

[☆] This is an open-access article distributed under the terms of the Creative Commons Attribution-NonCommercial-No Derivative Works License, which permits non-commercial use, distribution, and reproduction in any medium, provided the original author and source are credited.

* Corresponding author at: Dept. of Pediatrics, Yamagata University School of Medicine, 2-2-2 Iida-nishi, Yamagata 990-9585, Japan. Fax: +81 23 628 5332.

E-mail address: hayasaka@med.id.yamagata-u.ac.jp (K. Hayasaka).

effective for patients with NICCD. Citrin deficiency may impair the glycolysis in hepatocytes because of an increase in the cytosolic NADH/NAD⁺ ratio, leading to an energy shortage. MCT administration can provide energy to hepatocytes and was expected to have a good effect on CTLN2.

Methods: An MCT supplementation therapy under a low-carbohydrate formula was administered to five patients with CTLN2. Four of the patients had episodes of hyperammonemic encephalopathy, and one patient had postprandial hyperammonemia with no symptoms.

Results: One of the patients displaying hyperammonemic encephalopathy completely recovered with all normal laboratory findings. Others notably improved in terms of clinical and or laboratory findings with no hyperammonemic symptoms; however, the patients displayed persistent mild citrullinemia and occasionally had postprandial mild hyperammonemia most likely due to an irreversible change in the liver.

Conclusions: An MCT supplement can provide energy to hepatocytes and promote hepatic lipogenesis, leading to a reduction in the cytosolic NADH/NAD⁺ ratio. MCT supplementation under a low-carbohydrate formula could be a promising therapy for CTLN2 and should also be used to prevent CTLN2 to avoid irreversible liver damage.

© 2013 The Authors. Published by Elsevier Inc. All rights reserved.

1. Introduction

Citrin, encoded by *SLC25A13*, is a mitochondrial inner membrane aspartate-glutamate carrier that transfers a cytosolic NADH-reducing equivalent into the mitochondria as part of the malate-aspartate shuttle in the liver [0,1]. Citrin deficiency causes neonatal intrahepatic cholestasis (NICCD: OMIM 603471) and adult-onset type II citrullinemia (CTLN2: OMIM 605814). Nearly all patients with NICCD resolve the symptoms within the first year of life; however, small numbers of individuals with citrin deficiency develop hyperammonemic encephalopathy, usually between 20 and 40 years of age [2] and die within a few years, most often from cerebral edema. Liver transplantation is the only definitive therapy for patients with CTLN2.

We previously reported that a lactose (galactose)-restricted and medium-chain triglyceride (MCT)-supplemented formula is notably effective for patients with NICCD [3]. Citrin deficiency may impair glycolysis in the liver due to an increase in the cytosolic NADH/NAD⁺ ratio, leading to an energy shortage of hepatocytes. MCT supplementation can provide energy to hepatocytes. An increase in the cytosolic NADH would impair galactose metabolism at the UDP-galactose-4-prime-epimerase (EC 5.1.3.2) step, leading to an accumulation of liver toxic metabolites. Lactose (galactose) restriction can avoid any further increase in the cytosolic NADH/NAD⁺ ratio and toxic metabolites.

Considering energy shortage in the liver as the major pathogenic mechanism of citrin deficiency, we extended an MCT supplement therapy for CTLN2 and, in this study, present its effectiveness in five patients, including two siblings.

2. Materials and methods

2.1. Medium-chain triglyceride

Macton oil (Kissei pharmaceutical Co., LTD. Matsumoto, Japan), a product of medium-chain triglycerides (MCT), was a generous gift from Kissei pharmaceutical Co., LTD. Macton oil is composed of 85% MCT and 15% long-chain triglycerides and has a 0.94 g/mL specific gravity.

2.2. SLC25A13 analysis and immunohistochemical staining

Molecular analysis of *SLC25A13* was performed as previously described [4]. Immunohistochemical staining was conducted using anti-human argininosuccinate synthetase 1 (ASS1) antibody (Abcam PLC, Cambridge, UK) essentially as described previously [5].

2.3. Patients

2.3.1. Case 1

The patient was a 53-year-old man who developed flapping tremors, paresthesia and lethargy due to hyperammonemia over the preceding two months. His elder brother died of CTLN2 at 53 years of age. The patient took mercazole (5 mg/day) to treat hyperthyroidism after age 40. On admission, he had a weight of 54.0 kg and a height of 1.708 m with a body mass index (BMI) of 18.5 kg/m². He was exhausted, but he was alert with no abnormal physical and neurological findings. He presented with postprandial hyperammonemia (Table 1, Supplementary Fig. 1) and other abnormal laboratory data as follows: serum alanine aminotransferase (ALT) level of 47 IU/L (normal range (n) 8–42), gamma-glutamyl transpeptidase (γ -GTP) level of 84 IU/L (n 10–47), pancreatic secretory trypsin inhibitor (PSTI) level of 56.5 ng/mL (n 4.6–20.0), citrulline level of 102.9 μ mol/L (n 17.1–42.6) and a Fischer ratio of 2.08 (n 2.43–4.40) (Table 1). No abnormal data were obtained for the following: serum aspartate aminotransferase

Table 1

Summary of laboratory data of patients with CTLN2.

Patient	Case 1		Case 2		Case 3		Case 4		Case 5			
Days after therapy	0	120	0	170	0	208	0	160	281	0	95	
Body Weight (kg)	54.0	59.6	45.2	53.6	45.0	47.0	53.3	57.1	58.0	52.0	52.0	
Formula												
Macton (mL/day)	0	45	0	45	0	30	0	45	45	0	45	
Protein (g/day)	60.0–90.0 ^a	88.0	65.2	68.9	88.0	106.0	80.0	70.0	84.8	83.0	–	83.9
Carbohydrate (g/day)	330.0–420.0 ^a	286.0	231.2	315.4	264.0	280.0	259.0	300.0	243.7	250.0	–	235
Fat (g/day)	55.0–70.0 ^a	73.0	131.7	36.5	88.0	90.0	79.0	40.0	78.3	97.0	–	50.0
Energy (kcal/day)	2,300–2,500 ^a	2,153	2,371	1,866	2,200	2,354	2,067	1,900	2,019	2,200	–	1,676
Laboratory data	reference ranges											
Citrulline (μ mol/L)	17.1–42.6	102.9	45.7	131.4	33.3	74.9	60.2	462.0	504.1	178.7	451.4	133.2
Glutamic acid (μ mol/L)	12.6–62.5	42.3	48.8	61.0	34.6	92.5	75.6	78.0	75.8	62.6	32.8	43.7
Glutamine (μ mol/L)	422.1–703.8	679.4	711.1	360.6	558	387.7	472.9	450.7	428.2	508.6	570.9	551.6
Fischer ratio	2.43–4.40	2.08	2.59	2.08	2.64	1.47	2.53	2.90	2.40	2.86	2.22	2.49
Albumin (g/dL)	3.8–5.3	4.4	4.6	3.4	4.3	4.2	4.5	3.9	4.6	4.4	3.8	4.5
T. Bil (mg/dL)	0.2–1.3	1.3	0.7	1.2	1.0	0.5	0.6	0.5	0.5	0.3	1.4	1.1
AST (IU/L)	13–33	33	23	50	23	20	23	19	24	20	27	34
ALT (IU/L)	8–42	47	27	55	22	17	25	22	23	32	32	25
LDH (IU/L)	119–229	200	189	203	186	191	214	162	165	159	160	193
ALP (IU/L)	115–359	235	178	367	254	343	295	181	170	197	513	576
γ -GTP (IU/L)	10–47	84	58	96	48	36	42	41	50	93	87	75
ChE (IU/L)	185–501	324	346	156	271	211	231	210	211	253	192	188
T. Chol (mg/dL)	130–219	191	211	139	220	209	231	170	189	199	201	223
TG (mg/dL)	30–149	114	226	300	102	–	–	56	67	82	56	39
Ammonia (μ g/dL) ^b	40–80	215	53	100	26	104	59	222	173	90	121	23
Urea N (g/dL)	8–20	17	13	20	19	18.2	15.7	12	12	16	22	21
PSTI (ng/mL)	4.6–20.0	56.5	13.2	243.1	41.6	36	41	97	56	–	–	–
Iron (μ g/dL)	54–181	149	–	183	123	–	–	113	157	126	140	124
TIBC (μ g/dL)	231–385	361	–	194	348	–	–	370	384	338	338	364
Hyaluronic acid (μ g/L)	<50	16.6	–	279	58.4 ^c	–	–	–	84.2	240.3	46.8	84.7
Prognosis		fair		fair		good		good		good		

T. Bil, total bilirubin; AST, aspartate transaminase; ALT, alanine transaminase; LDH, lactate dehydrogenase; ALP, alkali phosphatase; γ -GTP, γ -glutamyltranspeptidase; ChE, Cholinesterase; T. Chol, total cholesterol; TG, triglycerides; PSTI, pancreatic secretory trypsin inhibitor; TIBC, and total iron binding capacity.

^a Standard nutrition of Japanese male adults.

^b Blood was sampled at 2 h after breakfast.

^c Blood was sampled at 35 days after therapy.

(AST), serum lactate dehydrogenase (LDH), serum cholinesterase (ChE), serum alkali phosphatase (ALP), urea N, creatinine, triglyceride, total cholesterol, coagulation tests, and complete blood cell counts. A fatty liver was demonstrated by abdominal ultrasonography, and steatosis was observed in liver biopsy specimens. The patient was a compound heterozygote with p.M285Pfs*2 (c.851_854del) and p.R605* (c.1813C>T) mutations in *SLC25A13*.

The patient was treated with a supplement of 45 mL of Macton oil under a low-carbohydrate formula (2,371 kcal a day; protein: fat: carbohydrate ratio 11: 50: 39). He improved in his general fatigue within a week and had no recurrent episode of encephalopathy. The levels of postprandial blood ammonia, plasma citrulline, Fischer ratio, ALT, γ -GTP and PSTI were steadily improved by the therapy (Supplementary Figs. 1 & 2, Fig. 1, Table 1). After 10 months of therapy, his body weight increased to 60 kg, and the amount of Macton oil was decreased to 30 mL/day. Then, the levels of plasma citrulline and the Fischer ratio mildly deteriorated, and these parameters recovered with an increase in Macton oil to 45 mL/day. The patient had mild citrullinemia, and sometimes had postprandial mild hyperammonemia with no apparent symptoms. No signs of fatty liver were observed on an abdominal ultrasonography after 41 months of therapy.

2.3.2. Case 2

A 62-year-old Japanese male suddenly experienced bouts of lost consciousness and abnormal behavior over the previous four weeks. He had no family history of metabolic disorders. On admission, he was lethargic and disoriented with flapping tremors. He had a weight of 45.2 kg and a length of 1.636 m with a BMI of 17.5 kg/m². He had postprandial hyperammonemia (Supplementary Fig. 3) and other abnormal laboratory data as follows: albumin 3.4 g/dL (n 3.8–5.3), AST 50 IU/L (n 13–33), ALT 55 IU/L (n 8–42), ALP 367 IU/L (n 115–359), γ -GTP 96 IU/L, ChE 156 IU/L (n 185–501), triglyceride 300 mg/dL (30–149), PSTI 243.1 ng/mL, serum iron 183 μ g/dL (n 54–181), total iron-binding capacity (TIBC) 194 μ g/dL (n 231–385), unsaturated iron-binding capacity (UIBC) 11 μ g/dL (n 111–255), ferritin 1124 μ g/L (n 15–400), hyaluronic acid 279 ng/mL (n <50), collagen IV 154 ng/mL (n <150), plasma citrulline 131.4 μ mol/L, threonine 237.1 μ mol/L (n 66.5–188.9), glutamine 360.6 μ mol/L (n 422.1–703.8) and Fischer ratio 2.08 (Table 1). He displayed 8–9 Hz alpha waves on electroencephalography with no epileptic discharges. Magnetic resonance imaging of the liver demonstrated hepatic iron deposition. A fatty liver was demonstrated by abdominal ultrasonography, and steatosis was observed in liver biopsy specimens. He was a compound heterozygote with p.D493G (c.1478 A>G) and p.S225* (c.674C>A) mutations in *SLC25A13*.

The patient was treated with a supplement of 45 mL of Macton oil under a low-carbohydrate formula (2220 kcal a day; protein: fat: carbohydrate ratio was 16: 36: 48). The patient's condition improved, and

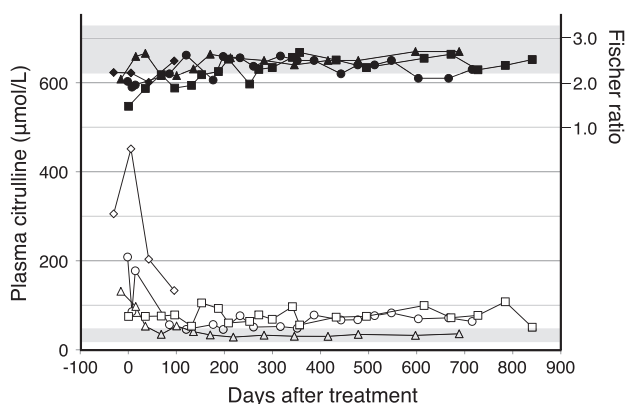


Fig. 1. Changes in the levels of plasma citrulline and Fischer ratio in Cases 1, 2, 3 and 5. Open symbols show the changes in the level of plasma citrulline and closed symbols are changes in the Fischer ratio. The circles, triangles, squares, and diamonds represent Cases 1, 2, 3 and 5, respectively.

there were no more episodes of encephalopathy. All abnormal biochemical findings, including postprandial hyperammonemia, were nearly normalized within seven months of treatment (Fig. 1, Supplementary Figs. 3 & 4, and Table 1). He had no deterioration even after a reduction of Macton oil to 30 mL/day at 10 months of the therapy. No signs of fatty liver were observed using abdominal ultrasonography after 26 months of therapy.

2.3.3. Case 3

A 53-year-old Japanese man had an episode of hyperammonemic encephalopathy at age 37. He was a compound heterozygote with S225* (c.674C>A) and c.1311 + 1G>A mutations in the SLC25A13 gene and was reported as a case of NASH due to CTLN2 [5]. He was treated with sodium benzoate (15 g/day) under a low-carbohydrate formula (2350 kcal a day; PFC ratio was 18: 34: 48) and had no episodes of hyperammonemic encephalopathy. At age 53, he weighed 42.0 kg and was 1.60 m tall. His BMI was 16.2 kg/m². He had no abnormal physical and neurological findings. However, he complained of fatigability, difficulty with calculations in the evening and recurrent watery diarrhea. Abnormal laboratory data were as follows: postprandial blood ammonia 104 µg/dL (n 40–80), PSTI 36.0 ng/mL, plasma citrulline 74.9 µmol/L, glutamic acid 92.5 µmol/L (n 12.6–62.5), glutamine 387.7 µmol/L (n 422.1–703.8) and Fischer ratio 1.47 (Table 1).

The patient was treated with a supplement of 30 mL of Macton oil under a low-carbohydrate formula. The fatigability and watery diarrhea disappeared within a month of therapy. He initially improved in the levels of postprandial blood ammonia, plasma glutamine and Fischer ratio. As shown in Fig. 1 and Supplementary Fig. 5, he did not display any further improvement from 90 to 280 days of therapy because of an insufficient intake of Macton oil. He then took it regularly and displayed an improved Fischer ratio. After 11 months of treatment, his body weight increased to 50 kg. He had no apparent symptoms, but he had persistent mild citrullinemia.

2.3.4. Case 4

A 38-year-old Japanese man was born as a second child to healthy unrelated parents. Case 5 was his elder brother. From 25 to 32 years old, he had four episodes of abnormal behaviors (excited, wandering) and unconsciousness. He displayed hyperammonemia and citrullinemia (326.7, 755.3 and 493.5 µmol/L) and was diagnosed with CTLN2 at 32 years old. He was a compound heterozygote with p. S225* (c.674C>A) and p.Q549* (c.1645C>T) mutations in SLC25A13. He was treated with arginine hydrochloride (3 g/day), sodium pyruvate (9 g/day), lactulose (90 mL/day), ursodeoxycholic acid (300 mg/day) and

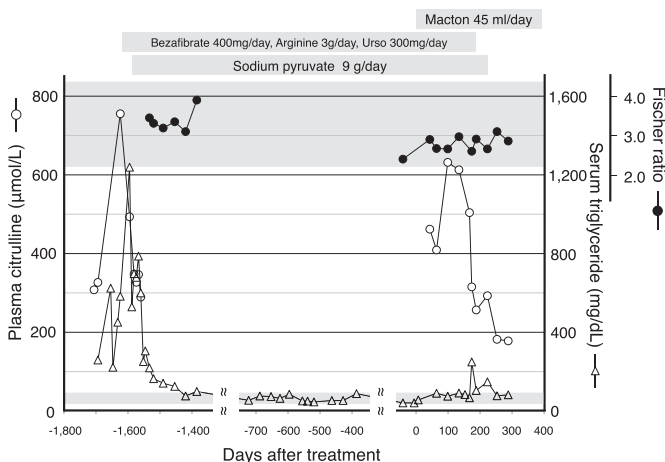


Fig. 2. Changes in the levels of plasma citrulline, Fischer ratio and serum triglycerides in Case 4. The open circles, closed circles, and open triangles indicate changes in the level of plasma citrulline, the Fischer ratio and serum triglycerides, respectively.

psychoactive drugs under a low-carbohydrate diet. Next, he developed hypertriglyceridemia (1239 mg/dL) and was treated with bezafibrate (400 mg/day). His levels of triglyceride were reduced, but plasma citrulline levels were not significantly changed (Fig. 2). He had several manic episodes, most likely because of bipolar disorder continuing for several weeks until age 38. Little data were available from 32 to 38 years of age.

At age 38, he weighed 53.2 kg and was 1.64 m tall. His BMI was 19.8 kg/m². He complained of fatigability but had no abnormal physical and neurological findings. Abnormal laboratory data were as follows: postprandial blood ammonia 222 µg/dL (n 40–80), plasma citrulline 462.0 µmol/L, glutamic acid 78.0 µmol/L, and arginine 311.3 µmol/L (n 53.6–133.6). A fatty liver was demonstrated by abdominal ultrasonography and steatosis was observed in liver biopsy specimens. Then, he received a supplement of Macton oil (45 mL/day) under a low-carbohydrate formula (2200 kcal a day; protein: fat: carbohydrate ratio was 15: 40: 45), for 4 months; however, he did not improve in terms of lethargy and plasma citrulline level (Fig. 2, Table 1). An MCT supplement is expected to provide energy to hepatocytes and stimulate lipogenesis. Bezafibrate is known to suppress lipogenesis and stimulate lipolysis in the liver. Bezafibrate was suspected to have counteracted the effect of MCT and was discontinued. In addition, arginine hydrochloride, sodium pyruvate, and ursodeoxycholic acid were also discontinued. As shown in Fig. 2 and Table 1, the levels of plasma citrulline, postprandial blood ammonia and ChE started to improve 4 months after cessation of bezafibrate. He improved in his fatigability and displayed no encephalopathy, but he had mild increases in the levels of plasma citrulline, γ -GTP and hyaluronic acid and occasionally had postprandial hyperammonemia. Subsequently, he suffered a manic episode, most likely due to bipolar disorder, and was hospitalized, and no further information was available.

2.3.5. Case 5

A 41-year-old Japanese man was an elder brother of case 4. He had a history of NICCD, a preference for protein- and fat-rich food, and compound heterozygous mutations of *SLC25A13*. He did not have any serious complaints but received a check-up at 41 years of age. He weighed 52.0 kg and was 161 cm tall. His body mass index was 20.1 kg/m². He did not display any abnormal signs and symptoms but had abnormal results in the following examinations: postprandial blood ammonias 121–355 µg/dL, serum ALP 513 IU/L (n 112–334), γ -GTP 87 IU/L, urea N 22 mg/dL (n 8.0–20.0), citrulline 451.4 µmol/L, arginine 229.6 µmol/L and Fischer ratio 2.22. He was treated with a supplement of Macton oil (45 mL/day) under a low-carbohydrate formula (1676 kcal a day; protein: fat: carbohydrate ratio was 20: 56: 24) and improved in the levels of blood ammonia 27 µg/dL, plasma citrulline 133.2 µmol/L, arginine 143.4 µmol/L and the Fischer ratio 2.49 (Fig. 1, Table 1). He sometimes had postprandial mild hyperammonemia.

2.3.6. Summary of the effects of therapy

An MCT supplement therapy under a low-carbohydrate formula steadily improved clinical and/or laboratory findings in Cases 1, 2, 3 and 5. Case 4 started to improve after cessation of bezafibrate. Blood ammonia levels fluctuated widely in the patients (Supplementary Figs. 1 & 3), and fasting blood ammonia level was not a reliable indicator of treatment effect. The plasma citrulline level appeared to be a definite indicator of treatment effect, and a steady decrease in plasma citrulline level was observed in all our patients. Case 2 had normalized plasma citrulline levels and did not present postprandial hyperammonemia. Conversely, plasma citrulline level decreased in Cases 1, 3, 4 and 5 but was slightly higher than the reference levels. Those patients sometimes had postprandial hyperammonemia with no apparent symptoms. The ASS1 immunohistochemical staining revealed the homogenous ASS1 distribution in the liver of Case 2 was the same as in control liver and ASS1-negative hepatocytes in the livers from Cases 1, 3 and 4: 10% in Case 1, 30% in Case 3 and 25% in Case 4 (Supplementary Fig. 6). The patients with a lower percentage of ASS1-negative hepatocytes displayed a good response to the therapy. Improvement of fatty liver in Cases 1 and 2 was confirmed by abdominal ultrasonography as long-term effects.

3. Discussion

We previously reported that a lactose (galactose)-restricted and MCT-supplemented formula is very effective in the treatment of NICCD [3]. Based on the hypothesis that energy shortage in the liver is a major pathogenic mechanism of citrin deficiency, we treated five *CTLN2* patients with an MCT supplement under

a low-carbohydrate formula. One of the patients completely recovered with normal laboratory findings, and the others notably improved in clinical and or laboratory findings but displayed persistent mild citrullinemia and occasionally had mild postprandial hyperammonemia with no symptoms.

Citrin deficiency likely results in impairment of glycolysis due to an increased NADH/NAD⁺ ratio in cytosol (Fig. 3a). At a normal circumstance, the liver takes up a relatively fixed amount of fatty acids regardless of dietary intake and uses as a major energy source. Glucose uptake by hepatocytes is most likely limited to the postprandial period because of the low affinity of glucose transporter 2 and glucokinase for glucose. Glucose is not a major energy source for hepatocytes but is used for lipogenesis for generating ATP, acetyl-CoA and NADPH. Thus, the patients with citrin deficiency most likely have impairments in hepatic lipogenesis and cannot export and reserve fatty acids in their tissues. Characteristic low BMI in patients with CTLN2 may reflect these metabolic impairments [1].

MCT is quickly hydrolyzed and is absorbed mainly as medium-chain free fatty acids (MCFA). MCFA are transported to the liver via the portal vein and are metabolized by beta-oxidation to produce ATP [7]. MCT administration is known to stimulate de novo hepatic lipogenesis [8,9]. It is important to note that cytosolic NAD⁺ is generated in the process of lipogenesis mainly at the malate dehydrogenase step and partly at the glycerol 3-phosphate dehydrogenase step (Fig. 3b). MCT administration can provide energy to hepatocytes and promote lipogenesis, leading to a decrease in the cytosolic NADH/NAD⁺ ratio. Effects of treatment with MCT in citrin deficiency were also suggested in the experiments using the mouse model by Saheki et al. [10]. Microvesicular fatty liver in citrin deficiency is a characteristic feature of Reye's syndrome or hepatic mitochondrial DNA depletion syndrome [11–13], suggesting a low-energy state of liver. Cases 1 and 2 improved the fatty liver after a long-term treatment, which supports the hypothesis that the major pathogenic mechanism of citrin deficiency is an energy shortage of liver.

It is interesting to note that the effect of MCT supplement was not initially observed in Case 4 and became apparent after the influence of bezafibrate likely disappeared. Nakajima et al. [14] demonstrated that bezafibrate exerts a triglyceride-lowering effect not by peroxisome proliferator-activated receptor (PPAR) activation but via the suppression of the SREBP-1c-regulated pathway. Bezafibrate may counteract the effect of MCT by impairment of hepatic lipogenesis and triglyceride secretion. In addition, bezafibrate may induce uncoupling proteins, which inhibit ATP synthesis from MCT oxidation [15]. Case 4 had been treated with sodium pyruvate for nearly five years; however, he did not improve in terms of lethargy and plasma citrulline level (Fig. 2). Mutoh et al. [16] reported the effectiveness of sodium pyruvate in a patient in the early stages of CTLN2. The effect of sodium pyruvate on CTLN2 may depend on the condition of the patients.

Plasma citrulline level decreased but was slightly higher than the reference level in all patients except Case 2, who sometimes had postprandial mild hyperammonemia. Saheki et al. [17] reported that the amount of ASS1 protein is reduced in the livers of patients with CTLN2. Yagi et al. [5] reported that the distribution of ASS1-producing hepatocytes in CTLN2 was divided into two types: one was homogeneous distribution of the enzyme-producing hepatocytes in the liver from patients with a favorable prognosis, as in the control livers, and the other presented with the clustered distribution of the enzyme-producing hepatocytes in the liver from patients with a less favorable prognosis. Our data confirmed their observation and suggested that rearrangements of hepatocytes occurred in the patients with a less favorable prognosis. Recovery of ASS1 activity can be estimated from the decrease in plasma citrulline level and persistent citrullinemia even after the treatment suggests that the rearrangement of hepatocytes occurred in the preceding periods. To prevent irreversible damage of the liver, preclinical and or early treatment is recommended.

Case 2 displayed an elevation in serum ferritin with hemosiderin deposits in the liver. Kimura et al. [12] reported elevated serum ferritin levels and hemosiderin deposits in liver specimens from approximately 60% of patients with NICCD. An increase in the level of serum ferritin is known in patients with non-alcoholic fatty liver disease, non-alcoholic steatohepatitis, and chronic hepatitis C. The association of cytokines and oxidative stress is well known in impaired iron metabolism and also fibrosis in these conditions [18,19]. Cytokines and/or oxidative stress may be involved in the pathogenesis of CTLN2.

Kikuchi et al. [20] estimated the frequency of patients with citrin deficiency as 1/7100 in Japan and speculated about the existence of asymptomatic individuals with a risk for CTLN2 development. Considering the disease frequency and the effectiveness of MCT therapy, citrin deficiency should be included in the mass screening system in Japan. We need more information about signs or changes at an early stage of CTLN2 and should start an intervention trial of MCT supplementation for post-NICCD children.

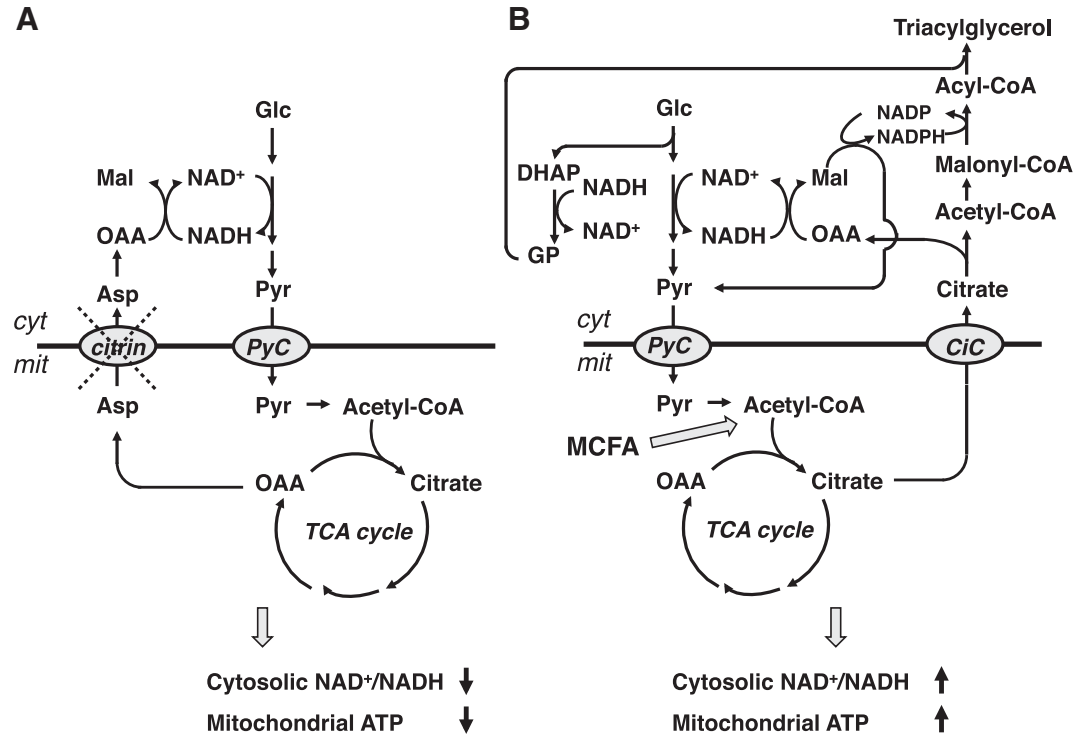


Fig. 3. a: Glucose metabolism in citrin deficiency. b: Treatment with medium-chain triglycerides and hepatic lipogenesis. Abbreviations: Asp, aspartate; Cic, citrate carrier; cyt, cytosol; DHAP, dihydroxyacetone phosphate; Glc, glucose; GP, glycerol 3-phosphate; Mal, malate; mit, mitochondria; MCFA, medium-chain free fatty acid; NAD⁺, nicotinamide adenine dinucleotide; NADH, reduced nicotinamide adenine dinucleotide; NADP, nicotinamide adenine dinucleotide phosphate; NADPH, reduced nicotinamide adenine dinucleotide phosphate; OAA, oxaloacetate; PyC, pyruvate carrier; and Pyr, pyruvate.

4. Conclusions

MCT supplementation under a low-carbohydrate formula could be a promising therapy for CTLN2 and should also be used to prevent CTLN2 to avoid irreversible liver damage.

Supplementary data to this article can be found online at <http://dx.doi.org/10.1016/j.ymgmr.2013.12.002>.

Conflict of interest

The authors had no potential conflicts of interest (COI) associated with this work.

Acknowledgments

We thank Mr. Toshiyuki Yamauchi for advice on formula. This work was supported in part by a grant from the Ministry of Health, Labor and Welfare in Japan. The Ethics Committee of the Yamagata University School of Medicine approved a molecular analysis of *SLC25A13* and our clinical trials of MCT therapy. Written informed consent for molecular analysis and involvement in the MCT clinical trials was obtained from all patients.

References

- [1] K. Kobayashi, D.S. Sinasac, M. Iijima, A.P. Boright, L. Begum, J.R. Lee, T. Yasuda, S. Ikeda, R. Hirano, H. Terazono, M.A. Crackower, I. Kondo, L.C. Tsui, S.W. Scherer, T. Saheki, The gene mutated in adult-onset type II citrullinaemia encodes a putative mitochondrial carrier protein, *Nat. Genet.* 22 (1999) 159–163.
- [2] T. Saheki, K. Inoue, A. Tushima, K. Mutoh, K. Kobayashi, Citrin deficiency and current treatment concepts, *Mol. Genet. Metab.* 100 (Suppl.1) (2010) S59–S64.
- [3] T. Yasuda, N. Yamaguchi, K. Kobayashi, I. Nishi, H. Horinouchi, MA. Jalil, MX. Li, M. Ushikai, M. Iijima, I. Kondo, T. Saheki, Identification of two novel mutations in the *SLC25A13* gene and detection of seven mutations in 102 patients with adult-onset type II citrullinemia, *Hum. Genet.* 107 (2000) 537–545.
- [4] K. Hayasaka, C. Numakura, K. Toyota, T. Kimura, Treatment with lactose (galactose)-restricted and medium-chain triglyceride-supplemented formula for neonatal intrahepatic cholestasis caused by citrin deficiency, *JIMD Rep.* 2 (2012) 37–44.
- [5] D. Dimmock, B. Maranda, C. Dionisi-Vici, J. Wang, S. Kleppe, G. Fiermonte, R. Bai, B. Hainline, A. Hamosh, W.E. O'Brien, F. Scaglia, L.J. Wong, Citrin deficiency, a perplexing global disorder, *Mol. Genet. Metab.* 96 (2009) 44–49.
- [6] Y. Yagi, T. Saheki, Y. Imamura, K. Kobayashi, M. Sase, K. Nakano, S. Matuo, I. Inoue, S. Hagihara, T. Noda, The heterogeneous distribution of argininosuccinate synthetase in the liver of type II citrullinemic patients. Its specificity and possible clinical implications, *Am. J. Clin. Pathol.* 89 (1988) 735–741.
- [7] A.C. Bach, V.K. Babayan, Medium-chain triglycerides: an update, *Am. J. Clin. Nutr.* 36 (1982) 950–962.
- [8] F. Foufelle, D. Perdereau, B. Gouhot, P. Ferre, J. Girard, Effect of diets rich in medium-chain and long-chain triglycerides on lipogenic-enzyme gene expression in liver and adipose tissue of the weaned rat, *Eur. J. Biochem.* 208 (1992) 381–387.
- [9] M.J. Geelen, Medium-chain fatty acids as short-term regulators of hepatic lipogenesis, *Biochem. J.* 302 (Pt 1) (1994) 141–146.
- [10] T. Saheki, K. Inoue, H. Ono, N. Katsura, M. Yokogawa, Y. Yoshidumi, S. Furuie, E. Kuroda, M. Ushikai, A. Asakawa, A. Inui, K. Eto, T. Kadowaki, D.S. Sinasac, K. Yamamura, K. Kobayashi, Effects of supplementation on food intake, body weight and hepatic metabolites in the citrin/mitochondrial glycerol-3-phosphate dehydrogenase double-knockout mouse model of human citrin deficiency, *Mol. Genet. Metab.* 107 (2012) 322–329.
- [11] D.M. Becroft, Syndrome of encephalopathy and fatty degeneration of viscera in New Zealand children, *Br. Med. J.* 2 (1966) 135–140.
- [12] H. Mandel, C. Hartman, D. Berkowitz, O.N. Elpeleg, I. Manov, T.C. Iancu, The hepatic mitochondrial DNA depletion syndrome: ultrastructural changes in liver biopsies, *Hepatology* 34 (2001) 776–784.
- [13] A. Kimura, M. Kage, I. Nagata, S. Mushiake, T. Ohura, Y. Tazawa, S. Maisawa, T. Tomomasa, D. Abukawa, Y. Okano, R. Sumazaki, M. Takayanagi, A. Tamamori, T. Yorifuji, Y. Yamato, K. Maeda, M. Matsushita, T. Matsuishi, K. Tanikawa, K. Kobayashi, T. Saheki, Histological findings in the livers of patients with neonatal intrahepatic cholestasis caused by citrin deficiency, *Hepatol. Res.* 40 (2010) 295–303.
- [14] T. Nakajima, N. Tanaka, H. Kanbe, A. Hara, Y. Kamiji, X. Zhang, F.J. Gonzalez, T. Aoyama, Bezafibrate at clinically relevant doses decreases serum/liver triglycerides via down-regulation of sterol regulatory element-binding protein-1c in mice: a novel peroxisome proliferator-activated receptor alpha-independent mechanism, *Mol. Pharmacol.* 75 (2009) 782–792.
- [15] F. Villarroya, R. Iglesias, M. Giralt, PPARs in the control of uncoupling proteins gene expression, *PPAR Res.* 2007 (2007) 74364.
- [16] K. Mutoh, K. Kurokawa, K. Kobayashi, T. Saheki, Treatment of a citrin-deficient patient at the early stage of adult-onset type II citrullinaemia with arginine and sodium pyruvate, *J. Inher. Metab. Dis.* 31 (Suppl. 2) (2008) S343–S347.
- [17] T. Saheki, K. Kobayashi, I. Inoue, Hereditary disorders of the urea cycle in man: biochemical and molecular approaches, *Rev. Physiol. Biochem. Pharmacol.* 108 (1987) 21–68.
- [18] E. Aigner, I. Theurl, M. Theurl, D. Lederer, H. Haufe, O. Dietze, M. Strasser, C. Datz, G. Weiss, Pathways underlying iron accumulation in human nonalcoholic fatty liver disease, *Am. J. Clin. Nutr.* 87 (2008) 1374–1383.
- [19] T.M. Leung, N. Nieto, CYP2E1 and oxidant stress in alcoholic and non-alcoholic fatty liver disease, *J. Hepatol.* 58 (2013) 395–398.
- [20] A. Kikuchi, N. Arai-Ichinoi, O. Sakamoto, Y. Matsubara, T. Saheki, K. Kobayashi, T. Ohura, S. Kure, Simple and rapid genetic testing for citrin deficiency by screening 11 prevalent mutations in *SLC25A13*, *Mol. Genet. Metab.* 105 (2012) 553–558.