

Available online at www.sciencedirect.com

ScienceDirect

journal homepage: www.elsevier.com/locate/radcr

Case Report

Concomitant acute myopericarditis and multiple systemic arteriovenous thrombosis as a rare manifestation of post-COVID-19 syndrome^{☆,☆☆}

Lamyae Zinoune^{a,b,*}, Ichraq Bourouis^{a,b}, Maryem Assamti^{a,b}, Amal Mojahid^{a,c},
Siham Nasri^{a,c}, Imane Skiker^{a,c}, Noha El ouafi^{a,b,d}, Zakaria Bazid^{a,b,d}

^a Faculty of Medicine and Pharmacy, Mohammed Ist University, Oujda, Morocco

^b Department of Cardiology, Mohammed VI University Hospital/Mohammed I University Oujda Morocco

^c Department of Radiology, Mohammed VI University Hospital/Mohammed I University Oujda Morocco

^d Laboratory of Epidemiology, Clinical Research and Public Health, Faculty of Medicine and Pharmacy, Oujda, Morocco

ARTICLE INFO

Article history:

Received 9 April 2022

Revised 25 April 2022

Accepted 28 April 2022

Available online 2 June 2022

Keywords:

Coronavirus

Post COVID syndrome

Cardiovascular system

Myopericarditis

Systemic thrombosis

ABSTRACT

Initially recognized as a respiratory system disease, COVID-19 has been found to be more of a systemic illness with multiorgan involvement. Recently, there are increasing reports of persistent and prolonged effects after acute COVID-19 infection, mainly on the cardiovascular system. Here, we report the case of a young man with myopericarditis and multiple systemic arteriovenous thrombosis developing several weeks after flu-like symptoms, with antigens indicating a past COVID-19 infection. This case highlights the multisystemic involvement of SARS-CoV-2, raising the possibility of concomitant myopericarditis and multiple systemic thrombosis after a COVID-19 non-severe infection. To our knowledge, there are no previous reports of such a case.

© 2022 The Authors. Published by Elsevier Inc. on behalf of University of Washington.

This is an open access article under the CC BY-NC-ND license

(<http://creativecommons.org/licenses/by-nc-nd/4.0/>)

Introduction

Since March 2020, we have been facing a pandemic due to the COVID-19 viral infection caused by severe acute respiratory syndrome coronavirus 2 (SARS-Cov-2), whose initial cases emerged in the city of Wuhan, China [1]. Cardiovascular manifestations beyond respiratory failure have been well de-

scribed mainly in severe cases [2]. Complications include myocardial infarction, macro and microvascular thrombosis, arrhythmias, heart failure, cardiomyopathy, pericarditis and myocarditis [3]. Since the beginning of the worldwide outbreak, many cases have been described during the acute phase of the disease, but not as long-term complications. The persistence of symptoms and/or delayed complications beyond 4 weeks from the onset of an acute process of probable or confirmed

[☆] Competing Interest: The authors declare no conflicts of interest.

^{☆☆} Acknowledgments: We would like to thank the team of cardiology and radiology of university hospital for their management and availability.

* Corresponding author.

E-mail address: zinoune.lamiae@gmail.com (L. Zinoune).

<https://doi.org/10.1016/j.radcr.2022.04.057>

1930-0433/© 2022 The Authors. Published by Elsevier Inc. on behalf of University of Washington. This is an open access article under the CC BY-NC-ND license (<http://creativecommons.org/licenses/by-nc-nd/4.0/>)

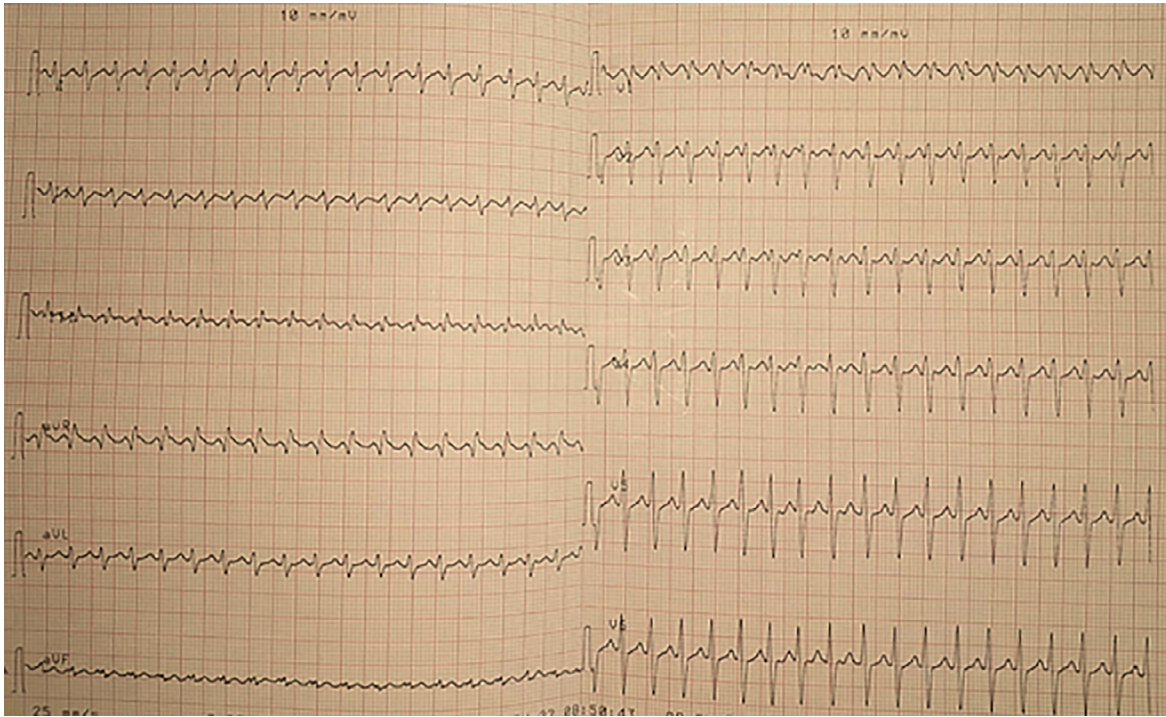


Fig. 1 – ECG showing an atrial flutter with a heart rate of 220 bpm.

SARS-CoV-2 infection, that cannot be explained by an alternative diagnosis, are denoted within the term post COVID-19 syndrome [4].

Case presentation

A 29-year-old male patient with no past medical history, presented to our department with a chest pain worsening by deep breathing and movement, hemoptysis and intermittent palpitations that persisted for more than 3 hours. He reported a headache, fatigue and fever that resolved spontaneously approximately 1 month prior to admission. He was a never-smoker, denied alcohol or drug abuse, and worked as a truck driver. He was fully vaccinated for COVID-19 (second dose received 5 months earlier).

On initial assessment, the vital signs were within normal limits except for heart rate fluctuating between 160 and 220 bpm. Heart sounds were normal without any audible murmurs, rubs or gallops. No signs of arthritis, lymphadenopathy or rash were observed and the remainder of the examination was normal.

Electrocardiogram showed an atrial flutter (heart rate of 220 bpm) with no ST segment changes (Fig. 1).

A subsequent transthoracic echocardiogram revealed a significant biventricular enlargement with diffuse hypokinesis and markedly depressed left ventricular ejection fraction (LVEF = 23%). A small pericardial effusion was noted, as well as intracardiac thrombi within the left and right ventricles. No significant valvular stenosis or regurgitation was observed (Fig. 2).

Laboratory studies showed a raised high sensitivity troponin at >13 000 ng/L (normal <4 ng/L), brain natriuretic pep-

ptide (BNP) at 1294 pg/mL, inflammatory markers including ferritin at 460 μ g/mL, C-reactive protein (CRP) at 127 mg/L, and procalcitonin (PCT) at 0.92 ng/ml.

In addition, blood samples showed increased aminotransferase (AST) at 5813 UI/L, alanine aminotransferase (ALT) at 4295 UI/L combined with low TP at 38% and factor V 58%, indicating deranged liver function.

At this stage, the diagnosis of myopericarditis was made. Cardiac magnetic resonance imaging were not performed at the time because it would not affect management, but considered as potential procedure if he continued to worsen.

Computed tomography pulmonary angiography (CTPA) revealed bilateral ground-glass opacities and condensations with multifocal distribution on both lungs, bilateral pulmonary embolism into segmental branches of the lower lobes and multiple thrombosis in the right and left ventricles, left superior pulmonary vein and right internal jugular vein (Fig. 3).

In the scenario of multiple systemic thrombosis, further investigation with computed tomography angiography of the abdomen and the brain was indicated, revealing right transverse sinus thrombosis (Fig. 4). Doppler ultrasonographic evaluation of lower limbs deep-vein showed left popliteal vein thrombosis.

There was a high index of suspicion towards a COVID-19 infection; however, SARS-CoV-2 presence could not be demonstrated using PCR on a nasal swab sample. Serological testing was consistent with a past infection with SARS-CoV-2 (IgM was negative but IgG was strongly positive). EBV, CMV, HIV, hepatitis viral panel, thrombophilia, antinuclear, and antiphospholipid antibodies were also performed in the meantime, and were all negative.

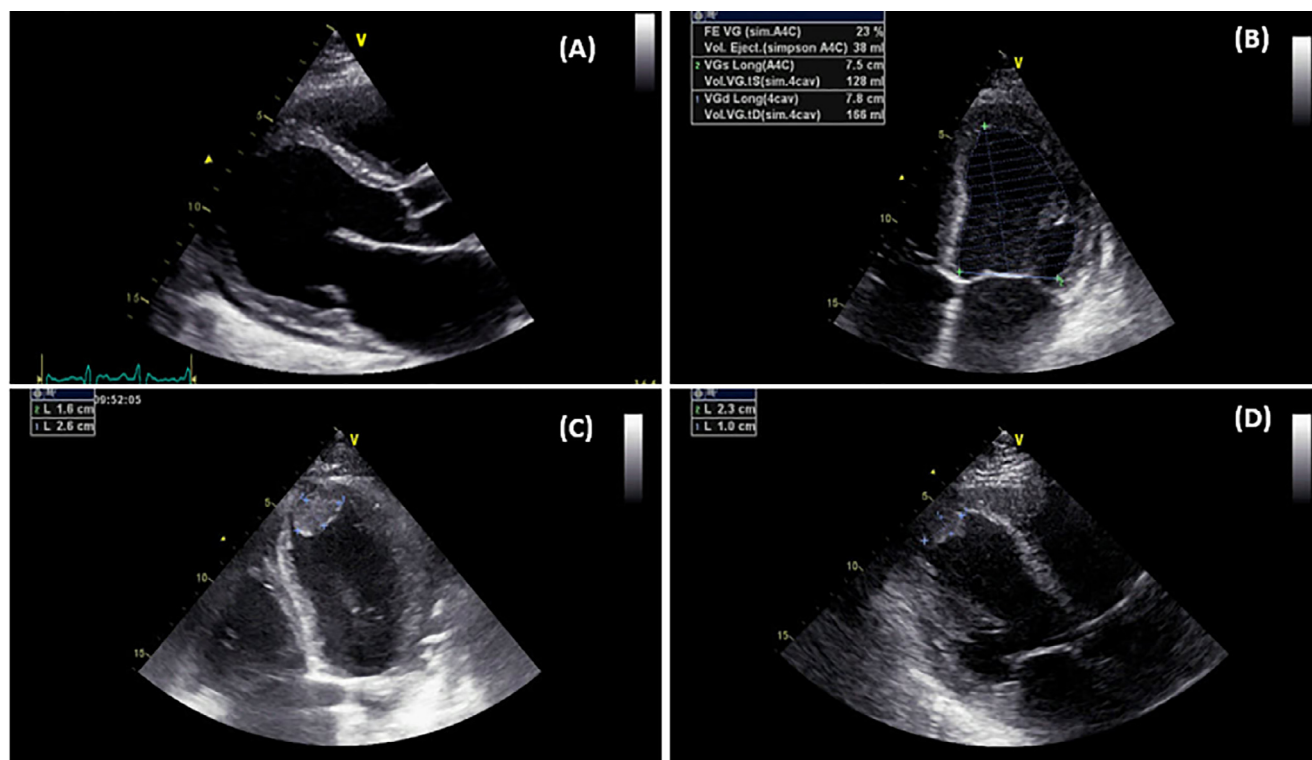


Fig. 2 – Echocardiogram showing (A) Small pericardial effusion with a significant biventricular enlargement (B) Markedly depressed left ventricular ejection fraction 23% (C) Left ventricular thrombus (D) Right ventricular thrombus.

Given his inflammatory markers, he was started on Azithromycin 500 mg and Methylprednisolone 30 mg daily and considered for tocilizumab if there was no improvement. He was also started on aspirin 75 mg per day, curative dose of low-molecular-weight-heparin, heart failure therapy (diuretics, angiotensin-converting enzyme inhibitor and aldosterone receptor antagonists) and antiarrhythmic medication (metoprolol and digoxin). The patient showed increasing improvement of clinical symptoms and progressively normal laboratory tests. Repeated echocardiography on day 20 showed mild improvement in cardiac function (LVEF = 35%).

He was discharged after 3 weeks and was continued on low-dose aspirin, angiotensin-receptor blocker, beta-blocker, and vitamin K antagonist treatment. Repeat echocardiogram at 3 months was ordered for the patient, but has not yet been performed at the time of writing.

Discussion

As the population of patients recovering from COVID-19 grows, our understanding of this disease continues to evolve. Early reports have shown that cardiovascular complications are not uncommon, occurring mainly in the acute phase and in critically ill patients. However, there are some reports that symptoms may appear or persist after weeks, which is known as post COVID-19 syndrome [2].

In the acute phase of the disease, the virus enters cells by endocytosis through angiotensin-converting enzyme 2 (ACE2)

receptors, which are present in the myocardium and endothelial cells, leading to cellular damage and therefore to myocarditis, endotheliitis and endothelial dysfunction [5]. However, after the acute phase, the mechanism seems to be related to an inadequate or excessive immune response driven by T and B cells. This inadequate immune response result in the production of autoantibodies against cardiac proteins, leading to a sustained inflammation, effusion and cardiac remodeling [6]. In addition to a cytokine-mediated activation of platelets and the coagulation cascade causing coagulopathy and therefore thrombosis [7].

Only two cases of myopericarditis related to post COVID-19 syndrome in young patients has been reported [8,9]. Post-COVID myocarditis manifest itself in two main clinical forms: isolated arrhythmias and systolic dysfunction [10]. Our patient presented both.

The diagnosis is given when there is evidence of pericarditis along with myocardial damage suspected by ECG changes (ST elevation or ST-T wave changes), elevation of cardiac enzymes or suggestive imaging [11–13]. Several imaging modalities can be helpful in the diagnosis, including echocardiography which can detect left ventricular dilation, systolic and/or diastolic dysfunction and regional wall motion abnormalities [12], and cardiac magnetic resonance (CMR) detecting myocardial edema [14]. CMR, however, is not accepted by a proportion of patients due to the considerable expense. Finally, the definitive diagnosis is made by myocardial biopsy, but is not a routine diagnostic method since it lacks sensitivity and specificity and it is an invasive approach [15].

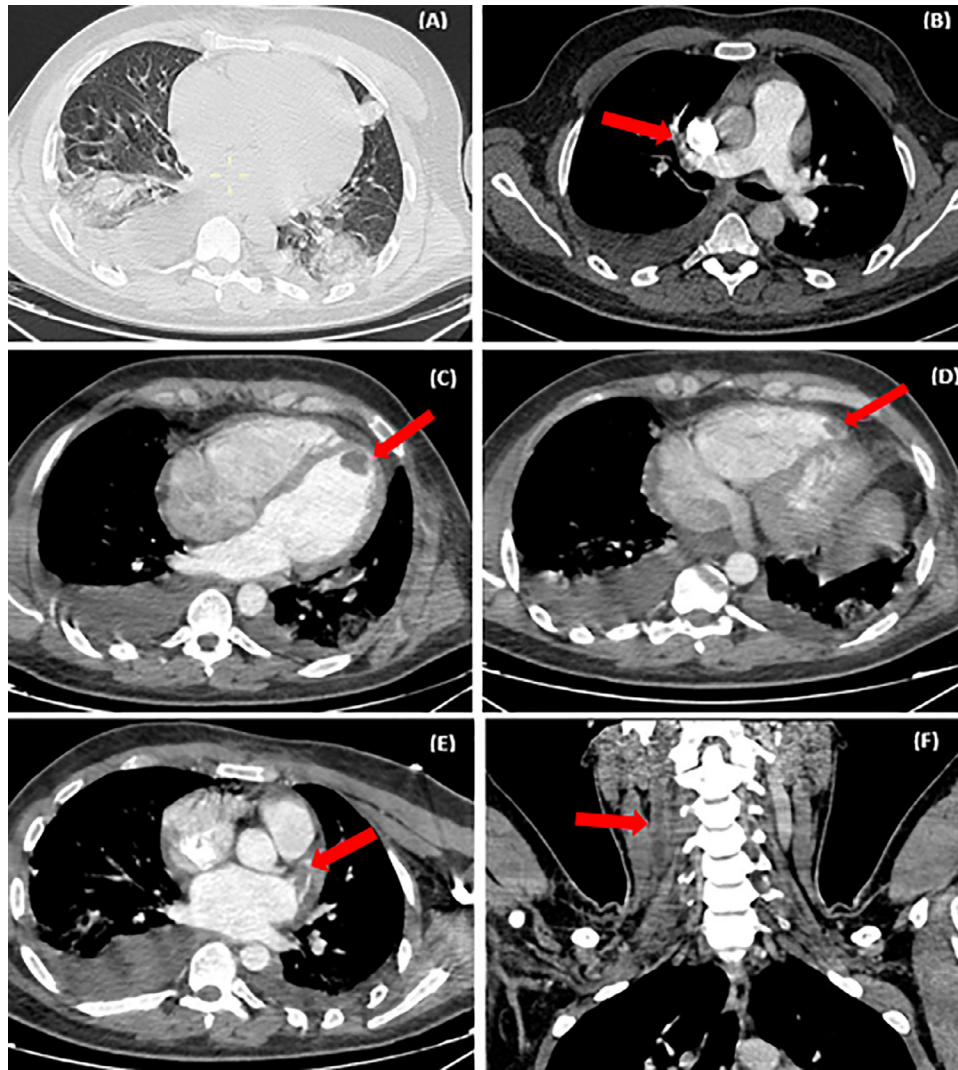


Fig. 3 – CTPA showing (A) bilateral ground-glass opacities and condensations, with multifocal distribution on both lungs (B) Bilateral pulmonary embolism into segmental branches of the lower lobes (C) Left ventricular thrombus (D) Right ventricular thrombus (E) thrombus in the left superior pulmonary vein (F) thrombus in the right internal jugular vein.

The most likely differential diagnosis of myocarditis is myocardial infarction, in our patient, the pretest probability of coronary artery disease was very low as the patient is 29 years old, lacked any significant comorbidities, was a lifelong non-smoker and denied any family history of premature coronary artery disease. Furthermore, extensive laboratory testing for other viruses, thrombophilia and immunologic disorders was negative, excluding other causes of myopericarditis. Thus, the treating team considered this presentation as a case of post COVID-19 syndrome. Causation was not definitively demonstrated but was considered likely due to the clinical improvement, the lack of early recurrence following treatment and the extensive workup that was unremarkable except for evidence of recently recovered COVID-19 infection from serum antibodies testing, results of CT scan and retrospective history.

Treatment approaches for post COVID-19 cardiovascular manifestations require more investigation. Studies have shown that corticosteroids are an interesting therapeutic option and seems to have a range of anti-inflammatory and im-

munosuppressive effects including attenuating the function of immune cells, particularly T cells, but its role in controlling COVID-19 immunothrombosis is unclear [16]. Left ventricular dysfunction and heart failure can be managed according to standard guidelines [17]. As to thrombosis, CHEST guidelines recommend anticoagulation therapy for a minimum duration of 3 months [18].

Conclusion

In the scenario of cardiovascular manifestations in young people with no medical history, it is important to consider the hypothesis of a viral etiology including the SARS-CoV-2 infection, especially in the post-viral infection period. Since there are few cases reported of myopericarditis as a presentation of post COVID-19 syndrome, the prognosis is still

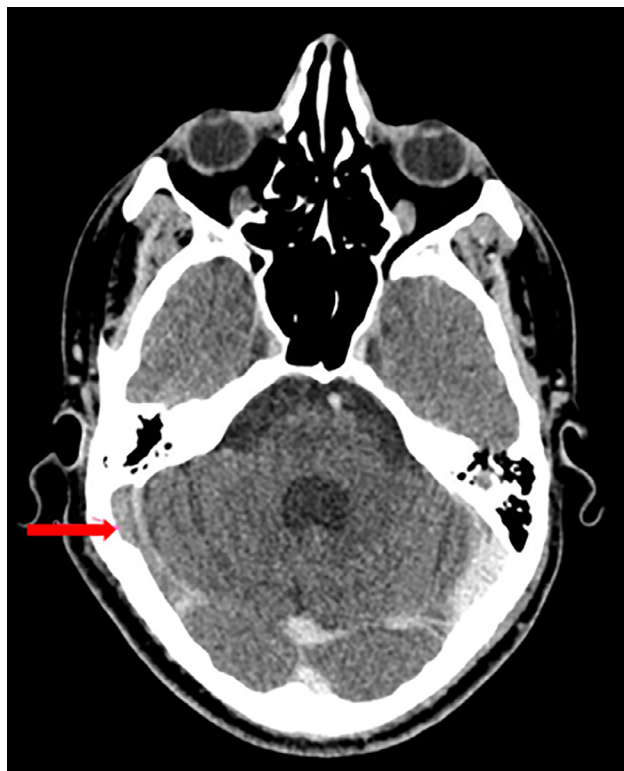

Fig. 4 – Brain CTA showing thrombosis of the right transverse sinus.

unclear. Nevertheless, this patient has been well responding to treatment with steroids.

Patient consent

The patient gave his informed consent for this case report to be published.

Funding

This research did not receive any specific grant from funding agencies in the public, commercial, or not-for-profit sectors

REFERENCE

- [1] Marco Cascella, Michael Rajnik, Abdul Aleem, Scott C. Dulebohn RDN. Features, evaluation, and treatment of Coronavirus (COVID-19). 2020.
- [2] Rente A, Junior DU, Margareth K, Uezato K. Case report coronavirus and the heart|A case report on the evolution of COVID-19 associated with cardiological evolution. *Arq Bras Cardiol* 2020;114(5):839–42.
- [3] Altamimi H, Abid AR, Othman FPA. Cardiovascular Manifestations of COVID-19. *Hear Views* 2020;21(3):171–86.
- [4] Nalbandian A, Sehgal K, Gupta A, Madhavan MV, Mcgroder C, Stevens JS, et al. Post-acute COVID-19 syndrome. *Nat Med* 2021;27(April):601–15.
- [5] Hamming I, Timens W, Bulthuis MLC, Lely AT, Navis GJ, Van Goor H. Tissue distribution of ACE2 protein, the functional receptor for SARS coronavirus . A first step in understanding SARS pathogenesis. *J Pathol* 2004;203:631–7.
- [6] Vabret N, Britton GJ, Gruber C, Hegde S, Kim J, Kuksin M, et al. Immunology of COVID-19 : current state of the science. *Immunity* 2020;52(January):910–41.
- [7] Varga Z, Flammer AJ, Steiger P, Haberecker M, Andermatt RZAS. Endothelial cell infection and endotheliitis in covid 19. *Lancet* 2020;395(January):1417–18.
- [8] Rivera-Morales MD, Pell R, Rubero J, Ganti L. Acute myopericarditis in the post COVID-19 recovery phase. *Cureus* 2020;12(10):11–15.
- [9] Vera-Lastra O, Lucas-Hernández A, Ruiz-Montiel JE, Gonzalez-Rodriguez VR, Pineda-Galindo LF. Myopericarditis as a manifestation of long COVID Syndrome. *Cureus* 2021;13(11):1–5.
- [10] Blagova O, Ainetdinova DH, Lutokhina YUA, Novosadov VM, Rud RS, Zaitsev AYU, et al. Post-COVID myocarditis diagnosed by endomyocardial biopsy and /or magnetic resonance imaging 2–9 months after acute COVID-19. *Eur Heart J* 2021;42(1):27–30.
- [11] Caforio ALP, Pankuweit S, Arbustini E, Basso C, Gimeno-Blanes J, Felix SB, et al. Current state of knowledge on aetiology, diagnosis, management, and therapy of myocarditis: A position statement of the European Society of Cardiology Working Group on Myocardial and Pericardial Diseases. *Eur Heart J* 2013;34(33):2636–48.
- [12] Felker GM, Boehmer JP, Hruban RH, Hutchins GM, Kasper EK, Baughman KL, et al. Echocardiographic findings in fulminant and acute myocarditis. *J Am Coll Cardiol* 2000;36(1):227–32.
- [13] Morgera T, Lenarda D, Dreass L, Pinamonti B. Electrocardiography of myocarditis revisited : clinical and prognostic significance of electrocardiographic changes. *Am Heart J* 1992;124(2):455–67.
- [14] Mahrholdt H, Goedecke C, Wagner A, Meinhardt G, Athanasiadis A, Vogelsberg H, et al. Cardiovascular magnetic resonance assessment of human myocarditis: a comparison to histology and molecular pathology. *J Am Heart Assoc* 2004;109(10):1250–8.
- [15] Butler J, Casey DE, Drazner MH, Fonarow GC, Geraci SA, Horwich T, et al. ACCF/AHA guideline for the management of heart failure. *J Am Coll Cardiol* 2013;62(16):e147–239 2013.
- [16] Horby P, Lim WS, RECOVERY Collaborative Group, et al. Dexamethasone in hospitalized patients with Covid-19 - preliminary report. *N Engl J Med* 2020:1–11.
- [17] Heidenreich PA, Bozkurt B, Aguilar D, Allen LA, Byun JJ, Colvin MM, et al. AHA/ACC/HFSA Guideline for the Management of Heart Failure. *J Am Coll Cardiol* 2022;79(17) 2022.
- [18] Moores Lisa K, Tritschler Tobias, Brosnahan Shari, Carrier Marc, Collen Jacob F, Doerschug Kevin, Holley Aaron B, et al. Prevention, diagnosis, and treatment of VTE in patients with Coronavirus Disease 2019. *CHEST Guidel Expert Panel Rep* 2020 (January).