

Early Masseter to Facial Nerve Transfer May Improve Smile Excursion in Facial Paralysis

Shuhao Zhang, MD*
Austin Hembd, MD*
Christina W. Ching, MD†
Philip Tolley, MS‡
Shai M. Rozen, MD*

Background: Masseter-to-facial nerve transfer has been shown to be an effective and safe treatment option in patients with acute and subacute facial palsy. The present article aims to characterize whether there is a benefit in early nerve transfers while minimizing other confounding variables; we present a study that consist of only patients with complete facial nerve paralysis resulting from intratemporal facial nerve resections.

Methods: Between 2012 and 2016, 7 masseter-to-facial nerve transfers were performed for complete facial nerve palsy after intratemporal proximal nerve resections. Pre- and postoperative photographic and video evaluations were performed using both the Sunnybrook facial grading scale and the MEEI FACE-gram software for more objective metric measurements. Statistical analysis was performed to determine which patient and surgical variables had significant effects on outcome.

Results: Mean 14-month follow-up revealed that patients who underwent nerve transfer prior to 6 months' denervation achieved postoperative oral commissural excursion of 11.1 mm versus 6.5 mm in patients who underwent nerve transfer after 6 months ($P = 0.003$). Performing masseter-to-facial nerve transfer to the main facial nerve trunk resulted in a significantly higher improvement in the modiolus-philtral ratio (31.6% versus 6.1%) than selective transfer in patients ($P = 0.01$) at the latest follow-up.

Conclusions: Early masseter-to-facial nerve transfers, before 6 months of palsy duration, can potentially improve smile excursion and symmetry of open mouth smile. Additionally, truncal coaptations may provide improved tone over coapting to selective facial nerve branches. These findings necessitate larger studies regarding the importance of denervation time with fifth-to-seventh nerve transfers. (*Plast Reconstr Surg Glob Open* 2018;6:e2023; doi: 10.1097/GOX.0000000000002023; Published online 15 November 2018.)

INTRODUCTION

Treatment of facial nerve paralysis not amenable to primary repair nor interpositional grafting is often dictated by the duration of palsy. Shorter durations allow salvaging neuromuscular junctions via nerve transfers, as opposed to long-standing facial paralysis, which requires recruitment of new neuromuscular units with local or free tissue transfer.

The masseteric branch of cranial nerve 5 (CNV) has become a popular donor for nerve transfer or to provide innervation to a free muscle transfer.¹⁻⁶ The masseter-to-facial nerve transfer has been shown to improve dynamic motion in acute and subacute facial palsy with results comparable to or better than other donor nerves.^{4,7-9} However, it remains unclear which specific patient and surgical variables are most predictive of outcomes after masseter-to-facial nerve transfers. This is particularly true with the duration of a patient's palsy, with a wide range of timing after initial paralysis for which the nerve transfer could be done.¹⁰⁻¹⁴

In aims to characterize whether there is a benefit in early nerve transfers while minimizing other confounding variables, we present an analysis of a retrospective cohort that consist of only patients with complete facial nerve paralysis resulting from intratemporal facial nerve resections. Due to the proximity of facial nerve resections in

From the *Department of Plastic Surgery, University of Texas Southwestern Medical Center, Dallas, Tex.; †Department of Pediatrics, University of Texas Southwestern Medical Center, Dallas, Tex.; and ‡University of Texas Southwestern Medical Center, Dallas, Tex.

Received for publication June 27, 2018; accepted September 20, 2018.

Copyright © 2018 The Authors. Published by Wolters Kluwer Health, Inc. on behalf of The American Society of Plastic Surgeons. This is an open-access article distributed under the terms of the Creative Commons Attribution-Non Commercial-No Derivatives License 4.0 (CCBY-NC-ND), where it is permissible to download and share the work provided it is properly cited. The work cannot be changed in any way or used commercially without permission from the journal. DOI: 10.1097/GOX.0000000000002023

Disclosure: The authors have no financial interest to declare in relation to the content of this article. The Article Processing Charge was paid for by the authors.

Supplemental digital content is available for this article. Clickable URL citations appear in the text.

this group, any recovery from intratemporal nerve grafting during the time of extirpation or contributions from a cross-facial nerve graft (CFNG) placed at the time of the fifth-to-seventh cranial nerve transfer were unlikely to affect outcomes within the first 6 months after the initial reanimation. This enabled early postoperative evaluations that decreased the confounding effects of a CFNG or intratemporal nerve graft, and therefore allowed characterization of whether duration of palsy had an effect on nerve transfer outcomes.

METHODS AND SURGICAL TECHNIQUE

Institutional review board approval was obtained to review medical records of all patients who underwent masseter-to-facial nerve transfers for facial palsy. All patients included in the study had complete paralysis due to resections of intratemporal tumors. Patients who had undergone nerve transfers for other etiologies underwent concomitant static procedures, or had partial paralysis, were excluded to maintain the same degree of initial paralysis and well-defined duration of palsy. These patients were not all referred for facial reanimation before their tumor resection from the same surgeons. Therefore, there was variability in whether or not an intratemporal nerve graft was placed at the time of resection.

End-to-end masseter-to-facial nerve transfer was performed in all patients as previously described by the senior author.¹⁵ Nerve transfer was performed either to the main facial nerve trunk and therefore before branching, or selectively to a more distal zygomatic or buccal branch innervating the zygomaticus major muscle or midface musculature (Fig. 1). If no intracranial graft was placed, then we performed a truncal coaptation with the nerve transfer to reinnervate as much of the mimetic muscular

as possible. If an intratemporal graft was placed at the time of resection, then the selective, more distal coaptation was performed to not disturb possible future contributions from the proximal intratemporal facial nerve¹⁶ while still providing additional axonal input to the mimetic musculature responsible for smile excursion.

In patients less than 40 years old, simultaneous, multiple CFNG were utilized from redundant healthy side buccal and zygomatic branches coapted to branches innervating the orbicularis oculi and zygomaticus major muscles on the paralyzed side (Fig. 2). Since the end of this study period and due to our changing expectations of the CFNG to provide tone and potentially synchronicity instead of excursion, we have expanded our current protocol to include performing a CFNG in patients up to 60 years old. There were no changes to surgical protocol or technique during the study period itself, however. The technique for CFNG coaptation to paralyzed side facial nerve branches is macroscopically end-to-side. However, before coaptation, a sharp division through one-third of the axons in the recipient branch is performed, hence making this truly a partial end-to-end coaptation. This is done to provide a more robust supply of donor CNVII input while maintaining contributions from a more proximal nerve transfer or intratemporal nerve graft.

Patient characteristics, surgical timing, technique, and time to movement after reanimation return were carefully recorded. Pre- and postoperative photographs and videos that were taken prospectively over time using the same photographer and equipment with a standardized protocol were examined and analyzed. If patients underwent additional static procedures after the nerve transfer was performed, only photographs from the last follow-up before those adjunct procedures were used.

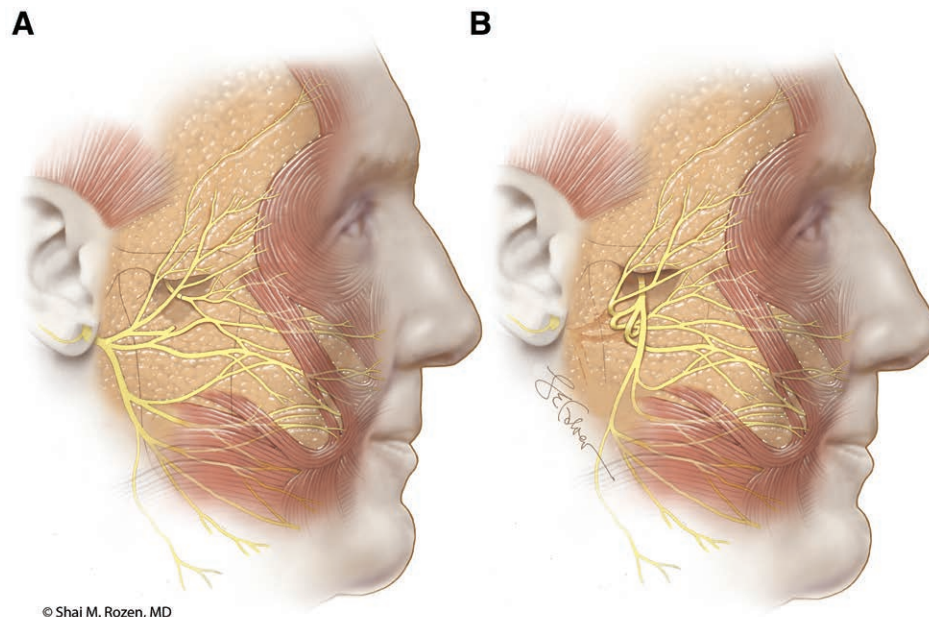


Fig. 1. Schematic of masseter-to-facial nerve transfer. A, Masseter nerve selectively coapted to zygomatic branch. B, Masseter nerve coapted to main facial nerve trunk.

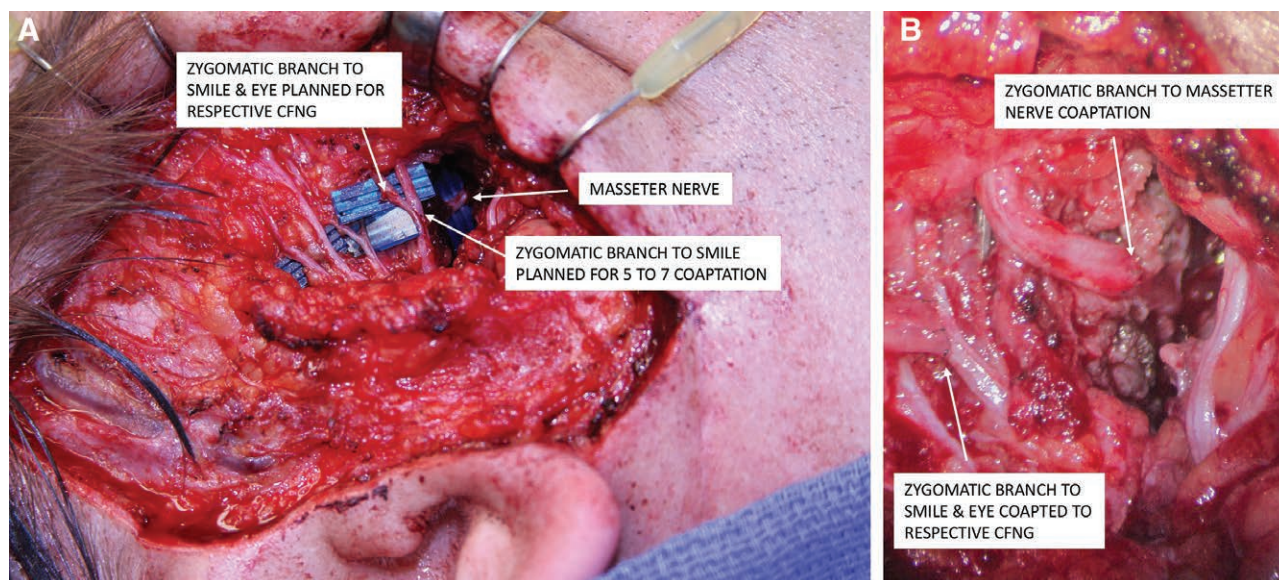


Fig. 2. Intraoperative photograph of a selective masseter-to-facial nerve transfer to zygomatic branch with concomitant CFNG (patient in Fig. 3). A, facial nerve dissection before CFNG and masseter nerve transfer. B, After end-to-end masseter nerve transfer and end-to-side CFNG coaptations.

Measurements of the modiolus-philtral (MP) distances in repose were performed on the paralyzed and unparalyzed sides. Philtral deviation in repose and maximal oral commissure excursion were measured using FACE-Gram software (MEEI, Boston, Mass.).¹⁷ Furthermore, the Sunnybrook Facial Grading scale was used to measure facial resting symmetry, symmetry of voluntary movement, and synkinesis.

Statistical analysis was performed using SAS software. Either two-tailed Student's *t* test or Wilcoxon Rank-Sum tests were performed to discern any difference in outcomes between age groups, presence of a CFNG, presence of intratemporal nerve graft, location of nerve transfer (coaptation to the facial nerve trunk or distal midface branches), and denervation duration before nerve transfer.

RESULTS

Patient Demographics and Operative Characteristics

Seven patients between 2012 and 2016 underwent masseter-to-facial nerve transfers due to previous proximal intratemporal facial nerve resections that resulted in

complete unilateral facial nerve palsy (Table 1). Mean age at nerve transfer was 36 years old (11–64). Mean duration of follow-up was 424 days (190–647). Mean denervation duration was 190 days (0–613). All patients had House-Brackmann score of 6 before nerve transfer. Selective CFNG was performed in addition to the masseter-to-facial nerve transfer in 5 cases. Intratemporal nerve grafting was performed at the time of primary tumor resection in 4 cases and therefore had masseter-to-facial nerve transfers to more selective, distal midface branches as described above. The remaining 3 patients, who did not have intratemporal nerve grafting, received masseter-to-facial nerve transfers with the coaptation at the level of the facial nerve main trunk or pes anserinus. Of the group who had intracranial nerve grafting, 2 had the nerve grafting procedure over a year prior but still had pre-nerve transfer House-Brackmann Scores of 6 with no movement and significant rest asymmetry. The other 2 had intratemporal grafting 2 months before the nerve transfer procedure.

Interval to Return of Motion

Mean interval between nerve transfer and mimetic muscle motion by clinical examination or patient report

Table 1. Patient Demographics, Etiologies of Palsy, and Reanimation Techniques Utilized

Patient	Age at the Time of V to VII Transfer	Sex	Etiology of Facial Nerve Palsy	Denervation Duration (d)	Preoperative House Brackmann	Recipient Facial Nerve Location	Intratemporal Nerve Grafting	CFNG
1	30	M	Neurofibroma	77	VI	Trunk	No	No
2	26	M	Schwannoma	613	VI	Branch	Yes	Yes
3	53	F	Acoustic neuroma	61	VI	Branch	Yes	Yes
4	35	M	Acoustic neuroma	75	VI	Branch	Yes	Yes
5	11	M	Recurrent mucoepidermoid carcinoma	0	VI	Trunk	No	Yes
6	36	F	Intratemporal hemangioma	448	VI	Branch	Yes	Yes
7	64	M	Schwannoma	53	VI	Trunk	No	No

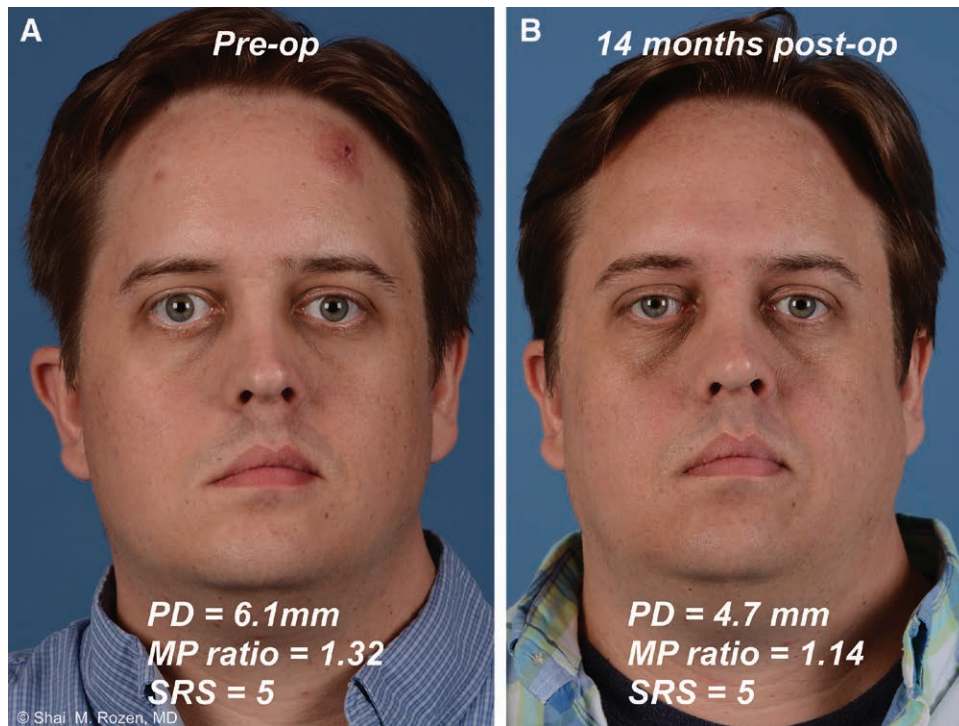


Fig. 3. Measurements in repose—acute presentation. Thirty-five-year-old man who underwent selective right masseter-to-facial nerve transfer 75 days after acoustic neuroma resection. A, Photograph and measurements prenerve transfer. B, Photograph and measurements 14 months postnerve transfer. MP ratio, modiolus-philtrum ratio; PD, philtral deviation. SRS score, Sunnybrook resting symmetry score.

was 131 days (89–157). This was not affected by patient age, duration of denervation, nerve transfer location, or presence of CFNG.

Resting Symmetry

Based on the Resting Symmetry section of the Sunnybrook Facial Grading System, a resting symmetry score was calculated for each patient pre- and postreanimation. This score averaged 8.6 for all patients before masseter-to-facial nerve transfer (range, 0–15) and did not statistically significantly change after nerve transfer (Figs. 3, 4). Postoperative averages are shown in Table 2. Other patient or surgical factors did not affect the resting facial symmetry score.

Based on objective measurements, MP distances in repose were measured and expressed as a ratio of paralyzed to normal side. A ratio greater than 1 indicates a longer MP distance and suggested decreased orbicularis oris tone on the paralyzed side. Improvements in this ratio over time were analyzed. Preoperative ratios averaged 1.58 (1.18–2.85). Average MP ratio decreased to 1.39 (9.1% improvement) at the earliest return of motion (131 days posttransfer) and 1.29 (14.6% improvement) at the latest follow-up (420 days posttransfer). This improvement was not affected by age, duration of denervation, or presence of a CFNG. However, performing masseter-to-facial nerve transfer to the main facial nerve trunk resulted in a significantly higher improvement in the MP ratio (31.6% versus 6.1%) than selective transfer in patients ($P = 0.01$) at the latest follow-up.

Preoperative philtral deviation was on average 5 mm (3.1–6.1 mm) toward the unparalyzed side before nerve transfer. Postoperatively, philtral deviation decreased to a mean of 4 mm (2.8–5.2 mm) on day of initial return of motion, and to a mean of 3.5 mm (1.8–5 mm) at the latest follow-up. Philtral deviation improved by 31% at 14 months postnerve transfer. Although philtral deviation showed continuous improvement over time, this improvement was not affected by any of the patient or surgical factors examined.

Symmetry of Voluntary Movement

Symmetry of voluntary movement was calculated using the Sunnybrook Facial Grading System (Table 2). Forehead motion (1.2) and snarl (2.2) had the poorest symmetry, while gentle eye closure (3.6), open mouth smile (3.9), and lip pucker (4.1) had the best. The specific score for symmetry of open mouth smile was worse in patients who had denervation duration of greater than 6 months (4.2 versus 3; $P = 0.007$; Figs. 5, 6; see video, Supplemental Digital Content 1, which displays a side-by-side video comparison of restoration of dynamic smile in a 35-year-old male who underwent selective right masseter-to-facial nerve transfer 75 days after acoustic neuroma resection, <http://links.lww.com/PRSGO/A922>; see video, Supplemental Digital Content 2, which displays a side by side video comparison of restoration of dynamic smile in a 36-year-old female who underwent selective left masseter-to-facial nerve transfer 448 days after resection of intratemporal hemangioma, <http://links.lww.com/PRSGO/A923>).

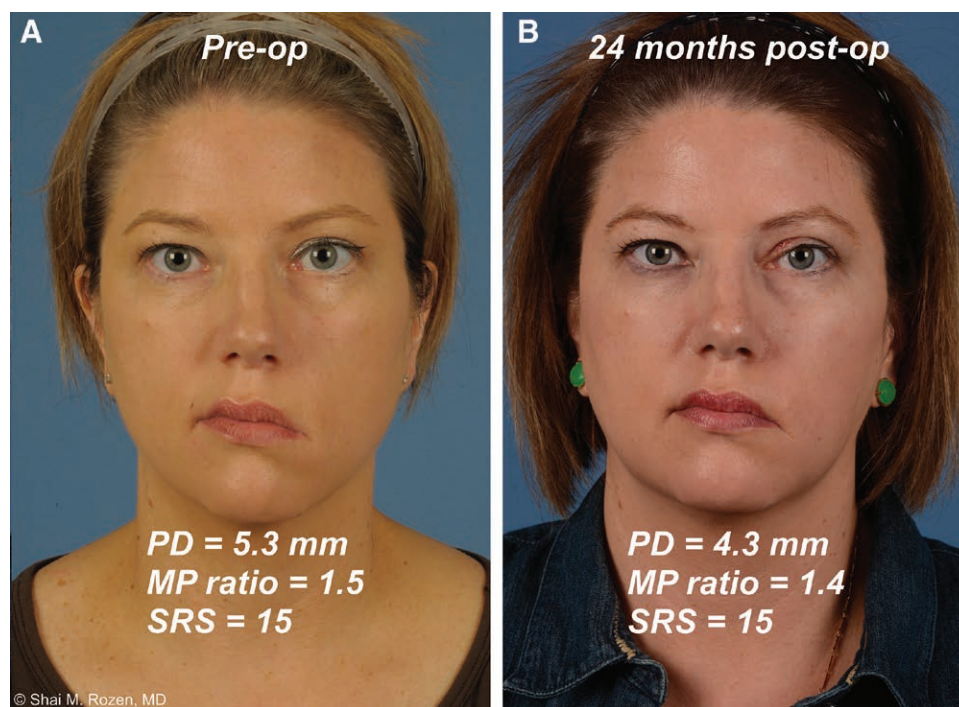

Fig. 4. Measurements in repose—subacute presentation. Thirty-six-year-old woman who underwent selective left masseter-to-facial nerve transfer 448 days after resection of intratemporal hemangioma. A, Photograph and measurements prenerve transfer. B, Photograph and measurements 24 months postnerve transfer. MP ratio, modiolus-philtrum ratio; PD, philtral deviation; SRS score, Sunnybrook resting symmetry score.

Table 2. Average Sunnybrook Facial Grading System Scores Postoperatively at 12 Months

Resting Symmetry (0, Normal; 1–2, Asymmetric)	Value
Eye (0–1)	0.6
Cheek/NLF (0–2)	0.7
Mouth (0–1)	0.4
Total resting symmetry score (0–20)	8.6
Symmetry of voluntary movement (1–5)	
Brow lift	1.3
Gentle eyelid closure	3.6
Open mouth smile	3.9
Snarl	2.2
Lip pucker	4.1
Total voluntary movement score (20–100)	60.2
Synkinesis (0, none; 1, mild; 2, moderate; and 3, severe)	
Brow lift	0
Gentle eyelid closure	0
Open mouth smile	0.7
Snarl	0
Lip pucker	0
Total synkinesis score (0–15)	0.7
Total composite score (20–135)	47.4

NLF, nasolabial fold.

Synkinesis scores from the Sunnybrook Facial Grading System averaged 0.7 (0–1) in all patients at the latest follow-up and was not affected by timing of transfer, location of transfer, or presence of intratemporal nerve grafting.

Objectively measured oral commissural excursions at the earliest date of documented return of motion was similar to that measured at the latest follow-up (9.8 mm; range, 6.4–12.6 mm). Patients who underwent nerve transfer before 6 months' denervation achieved postoperative

oral commissural excursion of 11.1 mm, versus 6.5 mm in patients who underwent nerve transfer after 6 months ($P = 0.003$). Oral commissural excursion recovery was otherwise not affected by age, location of transfer, or presence of CFNG.

DISCUSSION

When feasible, immediate intratemporal facial nerve grafting performed during tumor extirpation may partially restore facial tone, especially in the periorbital, oral, and buccinator regions, yet dynamic restoration is suboptimal especially in the brow, midface and perioral regions.¹⁶ Attempts at reinnervation solely with CFNG procedures theoretically achieve spontaneous motion, but reliably achieving symmetrical excursion is variable, particularly in the older patient.^{6,18–20}

Nerve transfers utilizing nonfacial donor nerves can be performed with or without CFNG as a single-stage operation.^{7,21,22} The masseter nerve has become a popular donor nerve due to its consistent anatomy, high axonal count, and potential synergy with the facial nerve during smiling.^{1–6} Furthermore, masseteric nerve transfers result in better oral commissural excursion than hypoglossal nerve transfers, and comparable oral commissural excursion to the contralateral, normal side.^{4,8,9,14} Similarly, free functional muscle flaps innervated by the masseteric nerve also results in improved excursion over a CFNG.^{23,24}

Previous data suggest that performing intratemporal or CFNG procedures before prolonged denervation times

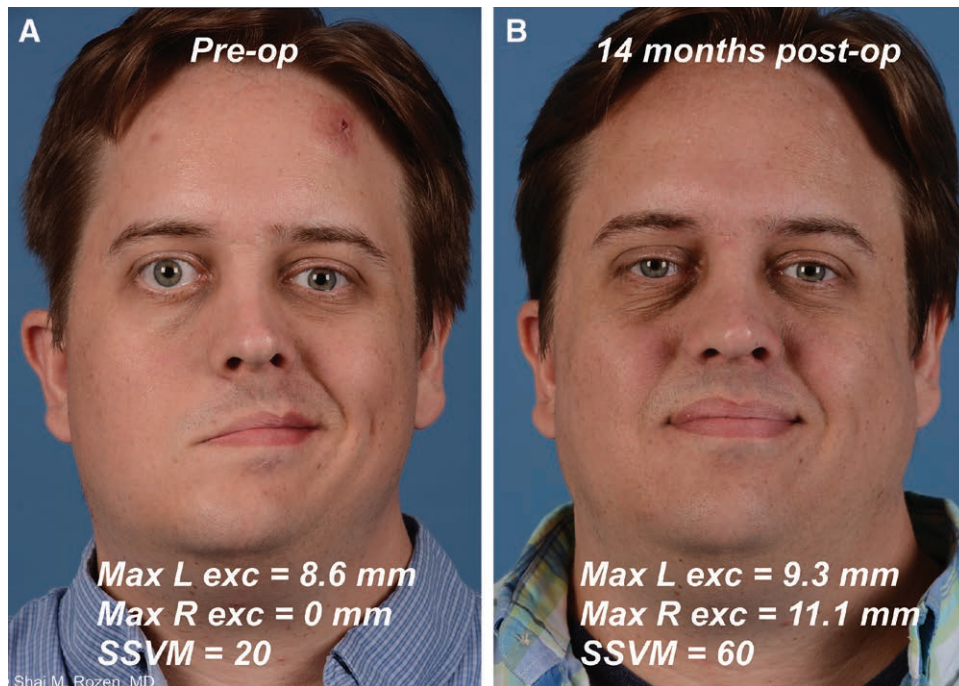


Fig. 5. Measurements in motion—acute presentation. Patient from Figure 3 on activation of bilateral smile. A, Photograph and measurements prenerve transfer. B, Photograph and measurements 14 months postnerve transfer. Exc, excursion; SSVM, Sunnybrook score in voluntary movement.

can improve reanimation outcomes.^{20,25} However, it remains unclear what role the duration of palsy in masseter-to-facial nerve transfers plays in ultimate outcomes. A study evaluating outcomes after selective fifth-to-seventh

cranial nerve transfer to zygomatic and buccal facial nerve branches found no difference in improvement in smile function between different denervation durations.⁵ However, that study did not employ objective measurements to

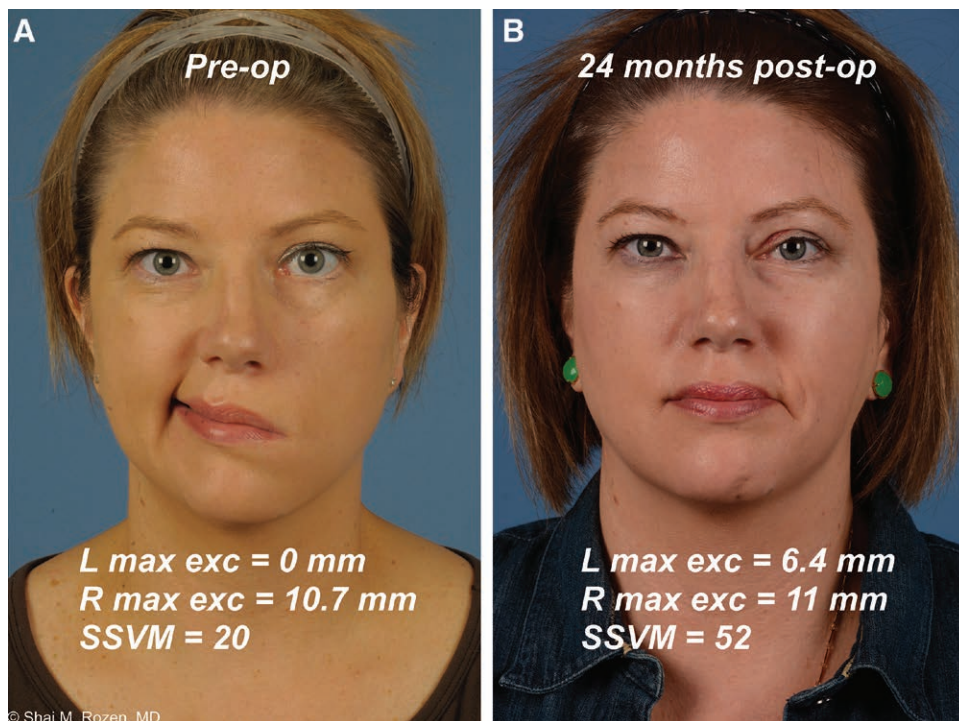
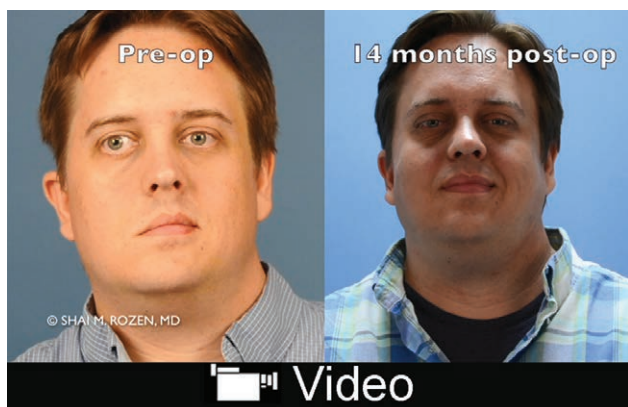
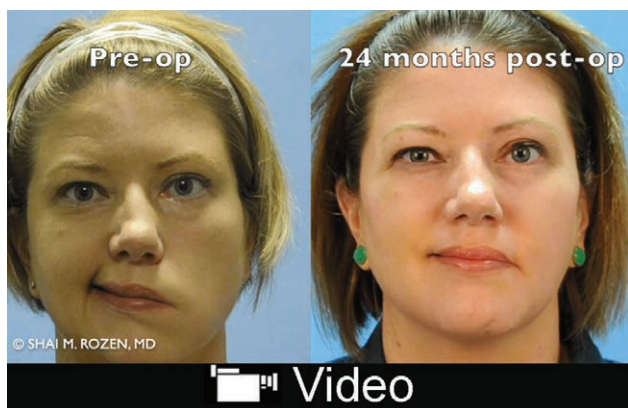Fig. 6. Measurements in motion—subacute presentation. Patient from Figure 4 on activation of bilateral smile. A, Photograph and measurements prenerve transfer. B, Photograph and measurements 14 months postnerve transfer. Exc, excursion; SSVM, Sunnybrook score in voluntary movement.



Video Graphic 1. See video, Supplemental Digital Content 1, which displays a side-by-side video comparison of restoration of dynamic smile in a 35-year-old man who underwent selective right masseter-to-facial nerve transfer 75 days after acoustic neuroma resection, <http://links.lww.com/PRSGO/A922>.



Video Graphic 2. See video, Supplemental Digital Content 2, which displays a side-by-side video comparison of restoration of dynamic smile in a 36-year-old woman who underwent selective left masseter-to-facial nerve transfer 448 days after resection of intratemporal hemangioma, <http://links.lww.com/PRSGO/A923>.

quantify results, did not note the degree of preoperative paralysis, nor comment on the continuity of facial nerve.

In our series, 7 patients had complete preoperative facial nerve palsy before fifth-to-seventh cranial nerve transfer resulting from intratemporal facial nerve resection. We utilized a combination of objective measures for postoperative analysis to characterize whether the timing of nerve transfers had an effect on outcomes.

Symmetry of Voluntary Movement

The Sunnybrook Facial Grading System was used to calculate scores for symmetry of voluntary movement and synkinesis. Synkinesis was not affected by the truncal or more proximal coaptation for the nerve transfer.

Symmetry of voluntary movement scores specifically for open-mouth smile and objective oral commissure excursion were significantly better in those patients undergoing nerve transfer with less than 6 months of paralysis. These results were not skewed by the postoperative results

of patient 5 (Table 1). Although he was 11 years old and received an immediate nerve transfer, his postoperative smile excursion at 1-year of 10.36mm was the second lowest of the early transfer cohort. Patient 3 (Table 1) was 53 year old with 61 days of denervation had a 1-year smile excursion of 11.18mm, by comparison. Moreover, the 2 patients with greater than 6 months of denervation time were only 26 and 36 years old. Therefore, we believe the poor excursion results in these patients can be attributed to denervation time and not age. And although excursion is also affected by donor nerve axon load,^{24,26} motor endplate degeneration or fibrosis is likely important, thus this finding supports the concept that ultimate mimetic muscle recovery after nerve transfer can be time-dependent.^{6,20,25}

Although we attempted to decrease the potential confounding variables by not including partial palsy patients, there is heterogeneity in the cohort with regard to intratemporal nerve grafting and the presence of a CFNG. However, what makes this small cohort analysis valuable is the time periods in which our measurements were made with respect to the both of these procedures. Four of 7 patients underwent intratemporal nerve grafting. Of those with intratemporal nerve grafts, 2 had the nerve grafting procedure over a year prior but still had prenerve transfer House-Brackmann Score of 6 with no movement and the highest scores on the Sunnybrook System for asymmetry.

The other 2 had intratemporal grafting 2 months before the nerve transfer, yet excursion or dynamic motion first occurred in these patients only 4 months postoperatively. These nerve grafts average 6–8 cm long from the proximal nerve stump with another 4–5 cm of nerve regeneration then required to even the most proximal branches innervating the mimetic musculature. Thus, the total distance required for nerve regeneration in these 2 patients is similar to the lengths of our typical CFNG grafts, which often take up to 9–12 months for nerve growth to the contralateral face.^{6,12,13,20}

Therefore, to see significant contribution from these grafts on animation, which was first seen at 6 months after the intratemporal nerve grafts were done in these 2 patients, would be unlikely. Previous data on cable grafting have shown average first documented motion beyond 6 months even with including data from more distal and extracranial nerve coaptations.²⁷

Moreover, our previous work has shown that even with 50 months of follow-up after intratemporal nerve grafting, the primary benefit was for tone or resting symmetry and there was minimal to no effect on dynamic motion.¹⁶

The motion we saw at 4 months postnerve transfer was 9.8mm, which was unchanged at follow-up at a year. If continued nerve regeneration from the CFNG or the intratemporal nerve graft contributed to excursion, then it would have increasingly improved excursion distances over time to and at the 1-year follow-up. This is when these grafts would be expected to start having more contributions due to the required regeneration distances from the motor endplates.¹⁰

Given that intratemporal nerve grafting has little effect on dynamic motion¹⁶ coupled with the time with which

we saw motion after the nerve transfer, it is possible that the contribution in improving excursion and symmetry with the open mouth Sunnybrook scores is from the early CNV-to-CNVII transfer before 6 months of denervation. This finding, novel in masseter-to-facial nerve transfers, could further support the concept that earlier reinnervation improves outcomes.^{20,25} Given the small sample size of this study, however, larger studies are required before the common teaching that the reconstructive surgeon has up 18 months to provide new neural input to mimetic motor endplates can be adequately challenged.^{10–14}

Resting Symmetry

Resting symmetry scores by the Sunnybrook Facial Grading system were significantly worse in patients who underwent nerve transfer after paralysis of greater than 6 months. Interestingly, these scores did not improve after nerve transfer in our study. This is possibly because the CNV to CNVII transfer does not adequately provide resting tone, as the masseter muscle is not chronically contracting at baseline. However, this cannot be definitely concluded due to the fact that our follow-up time of 1 year may not have been sufficient to see sufficient changes in resting symmetry on the Sunnybrook System, particularly in the cases where a concomitant CFNG was performed.^{10,25,27}

The paralyzed side MP distances when compared with the normal side significantly improved in the nonselective truncal transfers only. This finding might be explained by the reinnervation of a higher number of branches, axons, and therefore neuromuscular units in the more proximal truncal transfers versus selective branches.²⁸

We additionally found that philtral correction was improved by 21% at 135 days after nerve transfer and improved by another 10% at a 1-year follow up. Thus, it is possible the intratemporal-nerve grafting and CFNG started contributing at this later follow-up time. Given that intratemporal nerve grafting indeed has an effect on resting tone, we cannot definitively conclude that the nerve transfer alone changed resting symmetry.¹⁶

Limitations

The limitations of this study include the small sample size and retrospective nature of the study, which has inherent limitations. We attempted to improve the cohort by limiting it to only include patients with complete facial palsy resulting from transection of the facial nerve to minimize the confounding effect of partial palsy. Additionally, there was heterogeneity in terms of the presence of a CFNG and intratemporal nerve grafts.

Although this is a small cohort, our finding regarding improvement in modiolus excursion and open mouth smile scores for symmetry of voluntary motion after nerve transfers performed before 6 months of denervation was statistically significant. If one considers the careful timing when our postoperative measurements were performed, as described above, the heterogeneity in nerve grafting is additionally mitigated. Despite this, admittedly the study is imperfect and we understand this is not the ultimate solution to improving outcomes with nerve transfers. Our

aim is that some of these data can shed light on where we should be heading, and with time and increasing knowledge of the entire community interested in this field, we will make progress.

CONCLUSIONS

A close analysis of the postoperative outcomes suggests that performing masseter-to-facial nerve transfers before 6 months of facial palsy duration may potentially improve smile excursion and open mouth smile symmetry. Because of the small sample size and heterogeneity in this cohort, we hope these early findings encourage further research regarding the importance of denervation time with fifth-to-seventh nerve transfers.

Shai Rozen, MD

Department of Plastic Surgery
University of Texas Southwestern Medical Center
1800 Inwood Road
Dallas, TX 75390
E-mail: Shai.Rozen@utsouthwestern.edu

REFERENCES

- Coombs CJ, Ek EW, Wu T, et al. Masseteric-facial nerve coaptation—an alternative technique for facial nerve reinnervation. *J Plast Reconstr Aesthet Surg*. 2009;62:1580–1588.
- Borschel GH, Kawamura DH, Kasukurthi R, et al. The motor nerve to the masseter muscle: an anatomic and histomorphometric study to facilitate its use in facial reanimation. *J Plast Reconstr Aesthet Surg*. 2012;65:363–366.
- Eisenhardt S. *Facial Reanimation*. In Waikoloa, Hawaii: American Society of Reconstructive Microsurgery; 2017.
- Klebuc MJ. Facial reanimation using the masseter-to-facial nerve transfer. *Plast Reconstr Surg*. 2011;127:1909–1915.
- Wang W, Yang C, Li Q, et al. Masseter-to-facial nerve transfer: a highly effective technique for facial reanimation after acoustic neuroma resection. *Ann Plast Surg*. 2014;73:S63–S69.
- Garcia RM, Hadlock TA, Klebuc MJ, et al. Contemporary solutions for the treatment of facial nerve paralysis. *Plast Reconstr Surg*. 2015;135:1025e–1046e.
- Bianchi B, Ferri A, Ferrari S, et al. Cross-facial nerve graft and masseteric nerve coaptation for one-stage facial reanimation: principles, indications, and surgical procedure. *Head Neck*. 2014;36:235–240.
- Biglioli F, Frigerio A, Colombo V, et al. Masseteric-facial nerve anastomosis for early facial reanimation. *J Craniomaxillofac Surg*. 2012;40:149–155.
- Hontanilla B, Marré D. Comparison of hemihypoglossal nerve versus masseteric nerve transpositions in the rehabilitation of short-term facial paralysis using the Facial Clima evaluating system. *Plast Reconstr Surg*. 2012;130:662e–672e.
- Humphrey CD, Kriet JD. Nerve repair and cable grafting for facial paralysis. *Facial Plast Surg*. 2008;24:170–176.
- Kim L, Byrne PJ. Controversies in contemporary facial reanimation. *Facial Plast Surg Clin North Am*. 2016;24:275–297.
- Chan JY, Byrne PJ. Management of facial paralysis in the 21st century. *Facial Plast Surg*. 2011;27:346–357.
- Greywoode JD, Ho HH, Artz GJ, et al. Management of traumatic facial nerve injuries. *Facial Plast Surg*. 2010;26:511–518.
- Hontanilla B, Marre D, Cabello A. Masseteric nerve for reanimation of the smile in short-term facial paralysis. *Br J Oral Maxillofac Surg*. 2014;52:118–123.
- Rozen SM. Facial reanimation: basic surgical tools and creation of an effective toolbox for treating patients with facial paralysis: Part

- B. Nerve transfer combined with cross-facial nerve grafting in the acute facial palsy patient. *Plast Reconstr Surg*. 2017;139:725–727.
16. Rozen SM, Harrison BL, Isaacson B, et al. Intracranial facial nerve grafting in the setting of skull base tumors: global and regional facial function analysis and possible implications for facial reanimation surgery. *Plast Reconstr Surg*. 2016;137:267–278.
 17. Hadlock TA, Urban LS. Toward a universal, automated facial measurement tool in facial reanimation. *Arch Facial Plast Surg*. 2012;14:277–282.
 18. Lee EI, Hurvitz KA, Evans GR, et al. Cross-facial nerve graft: past and present. *J Plast Reconstr Aesthet Surg*. 2008;61:250–256.
 19. Scaramella LF. Cross-face facial nerve anastomosis: historical notes. *Ear Nose Throat J*. 1996;75:343, 347–52, 354.
 20. Terzis JK, Konofaos P. Experience with 60 adult patients with facial paralysis secondary to tumor extirpation. *Plast Reconstr Surg*. 2012;130:51e–66e.
 21. Terzis JK, Tzafetta K. The “babysitter” procedure: minihypoglossal to facial nerve transfer and cross-facial nerve grafting. *Plast Reconstr Surg*. 2009;123:865–876.
 22. Faria JC, Scopel GP, Ferreira MC. Facial reanimation with masseteric nerve: babysitter or permanent procedure? Preliminary results. *Ann Plast Surg*. 2010;64:31–34.
 23. Bae YC, Zuker RM, Manktelow RT, et al. A comparison of commissure excursion following gracilis muscle transplantation for facial paralysis using a cross-face nerve graft versus the motor nerve to the masseter nerve. *Plast Reconstr Surg*. 2006;117:2407–2413.
 24. Snyder-Warwick AK, Fattah AY, Zive L, et al. The degree of facial movement following microvascular muscle transfer in pediatric facial reanimation depends on donor motor nerve axonal density. *Plast Reconstr Surg*. 2015;135:370e–381e.
 25. Ozmen OA, Falcioni M, Lauda L, et al. Outcomes of facial nerve grafting in 155 cases: predictive value of history and preoperative function. *Otol Neurotol*. 2011;32:1341–1346.
 26. Terzis JK, Wang W, Zhao Y. Effect of axonal load on the functional and aesthetic outcomes of the cross-facial nerve graft procedure for facial reanimation. *Plast Reconstr Surg*. 2009;124:1499–1512.
 27. Eaton DA, Hirsch BE, Mansour OI. Recovery of facial nerve function after repair or grafting: our experience with 24 patients. *Am J Otolaryngol*. 2007;28:37–41.
 28. Murphey AW, Clinkscales WB, Oyer SL. Masseteric nerve transfer for facial nerve paralysis: a systematic review and meta-analysis. *JAMA Facial Plast Surg*. 2018;20:104–110.