



# A Rare Case of Cardiogenic Shock Following Severe Multivessel Coronary Vasospasm

Reza Rahmani, MD\*, Amirfarhang Zand Parsa, MD, Alborz Sherafati, MD, Rouzbeh Kosari, MD, Vahid Mohhamadi, MD, Rizan Mohhamadi, MD

Imam Khomeini Hospital Complex, Tehran University of Medical Sciences, Tehran, Iran.

Received 16 June 2017; Accepted 23 May 2018

## Abstract

*Prinzmetal's angina occurs following spasms in a single or multiple vascular beds, resulting in a typical chest pain and an ST-segment elevation in electrocardiography (ECG). It can lead to life-threatening arrhythmias and sudden cardiac death. We describe a 37-year-old woman who was admitted with a typical chest pain and hypotension. Her initial ECG showed an ST-segment elevation in the inferior and precordial leads. She was transferred to the catheterization unit, where coronary angiography illustrated multivessel spasms. The spasms were relieved with a nitroglycerin injection. She was discharged with stable hemodynamics 7 days later, and at 1 month's follow-up, no recurrent attack was detected.*

*J Teh Univ Heart Ctr 2019;14(1):28-32*

**This paper should be cited as:** Rahmani R, Zand Parsa A, Sherafati A, Kosari R, Mohhamadi V, Mohhamadi R. A Rare Case of Cardiogenic Shock Following Severe Multivessel Coronary Vasospasm. *J Teh Univ Heart Ctr 2019;14(1):28-32.*

**Keywords:** Angina pectoris, variant; Coronary vasospasm; Shock, cardiogenic

## Introduction

Coronary artery spasms are considered the most important underlying cause of variant angina. Coronary spasms most often occur in a single vessel,<sup>1</sup> and they are generally associated with a good prognosis. We recently observed a case of spontaneous, diffuse triple-vessel coronary spasms on coronary angiography in a female patient who presented with cardiogenic shock. She had a history of an aborted sudden cardiac death 3 months previously, for which she underwent implantable cardioverter-defibrillator (ICD) implantation at the time.

## Case Report

A 37-year-old woman was admitted to the emergency

department with a severe chest pain of 30 minutes' duration. Her chest pain was retrosternal with no radiation and persisted continuously throughout the admission time. She described the pain as heaviness in her chest. The pain had no relation to exertion and was not relieved with rest. Additionally, it was neither positional nor pleuritic. There were no other accompanying symptoms. In her past medical history, she had an episode of cardiac arrest 3 months earlier, following an episode of a chest pain similar to her current pain. On that occasion, cardiopulmonary resuscitation was successful, coronary angiography was normal, and an ICD was implanted. She had no history of any previous medical disease, allergy, atherosclerosis risk factors, or smoking, and nor did she consume any drugs. She had a low socioeconomic status. During her physical examination, the patient was agitated and diaphoretic. She had a blood pressure of 80/50 mmHg,

\*Corresponding Author: Reza Rahmani, Assistant Professor of Interventional Cardiology, Department of Cardiology, Imam Khomeini Hospital Complex, Keshavarz Blvd., Tehran, Iran. 1419733141. Tel: +98 21 61192647. Fax: +98 21 66581615. E-mail: r\_rahmani@tums.ac.ir



a heart rate of 70 bpm, an elevated jugular venous pulse, and normal breath sounds. No murmur was heard on heart auscultation, and the radial pulses were narrow and weak. Her electrocardiography revealed a normal sinus rhythm with an ST-segment elevation in the inferior leads, leads  $V_3$ - $V_5$ , and

leads  $V_3R$ - $V_5R$ , along with an ST-segment depression in leads I and aVL (Figure 1).

During the patient's initial monitoring in the cardiopulmonary resuscitation unit in the emergency department, her systolic blood pressure and heart rate dropped to 50 mmHg and 45

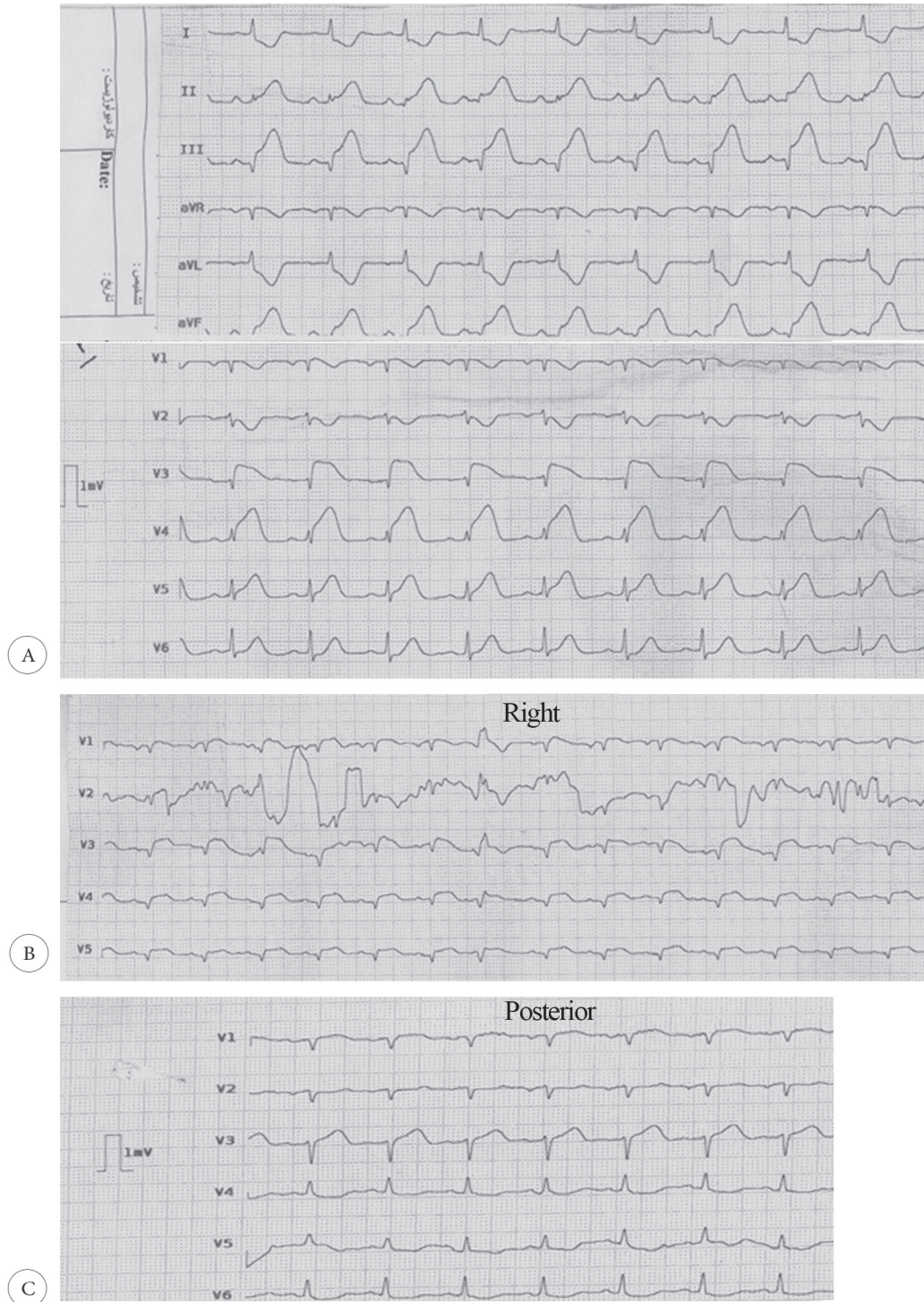


Figure 1. A) Standard 12-lead electrocardiogram (ECG) at initial presentation, showing an ST-segment elevation in the inferior leads (II, III, and aVF) and leads  $V_3$  -  $V_5$ , along with an ST-segment depression in leads I and aVL. B) Right precordial lead ECG at initial presentation, revealing an ST-segment elevation in leads  $V_3R$ - $V_5R$ . C) Posterior precordial leads at initial presentation, showing no significant ST deviation in leads  $V_7$  -  $V_9$ .

bpm, respectively. Bedside echocardiography showed a left ventricular ejection fraction of 20%, with no pericardial effusion or mechanical complication. Intravenous atropine (0.5 mg) along with intravenous saline was administered. Due to profound hemodynamic instability, the patient was immediately transferred to the cardiac catheterization unit, where urgent coronary angiography revealed diffuse and severe stenoses in the entire coronary artery tree (Figure 2.

A & B). The left coronary artery was selected with an extra backup (EBU) guiding catheter and after the administration of 7500 units of intravenous heparin, a 0.014-inch floppy guide wire was inserted in the left anterior descending (LAD) artery. Next, 100  $\mu$ g of intracoronary nitroglycerine was injected through the catheter. Control images illustrated near-normal left coronary arteries (Figure 2. C & D).

The right coronary artery (RCA) was intubated with a

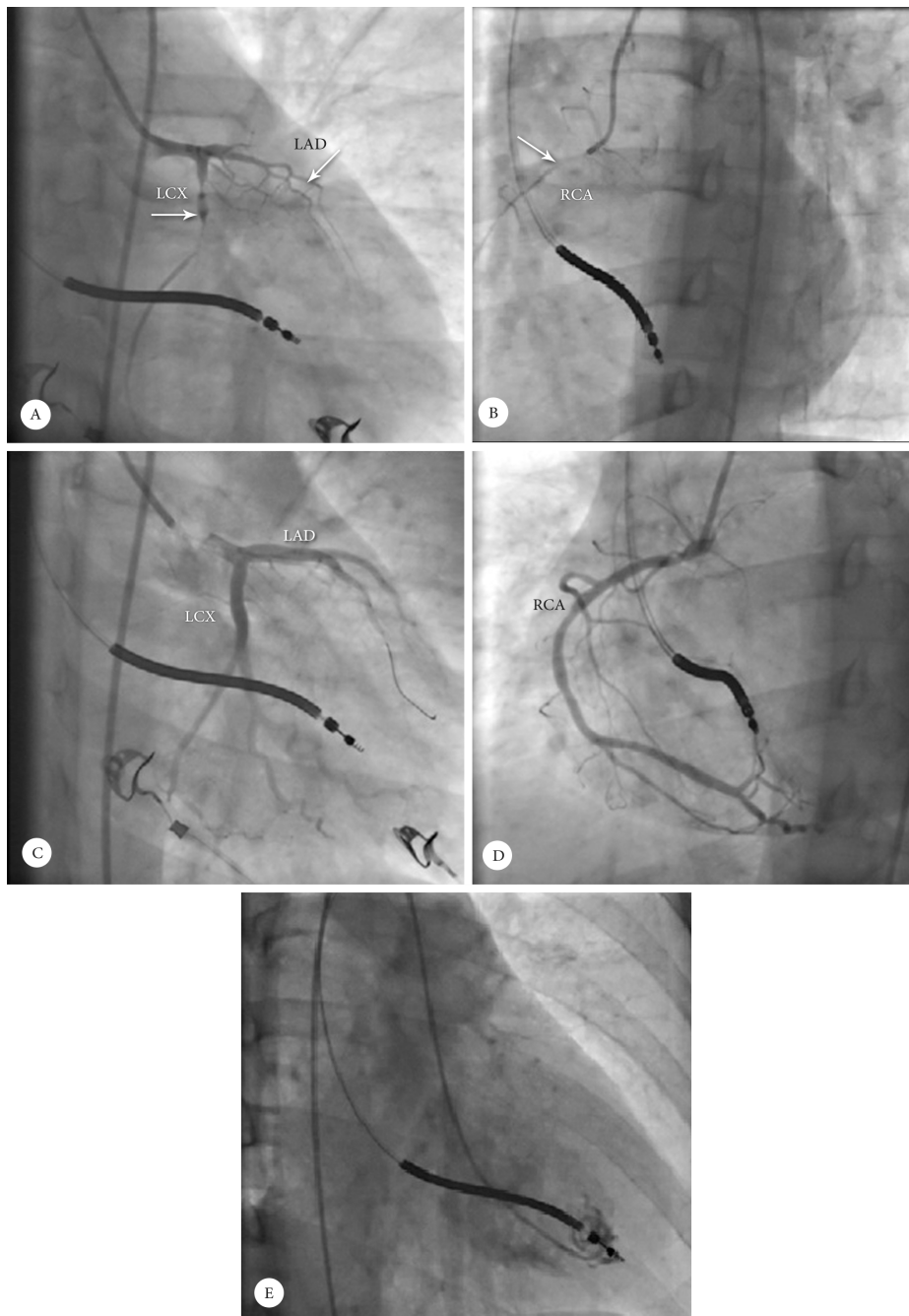


Figure 2. Coronary angiograms of the patient: Diffuse critical stenoses (arrows) are seen in the left anterior descending (and the left circumflex arteries in the right anterior oblique (RAO) caudal view (A) and in the right coronary artery (RCA) in the left anterior oblique (LAO) view (B). Noncritical coronary plaques after the intracoronary nitroglycerine injection are seen in the coronary arteries in the RAO views of coronary angiography (C and D). Left ventriculography in the RAO view shows a good left ventricular size and function (E).



right Judkins guiding catheter, and images were obtained. An intracoronary injection of 25 µg of nitroglycerine was performed in the next step. In the control images of the right coronary artery (RCA) the coronary lumen was near normal. The patient's hemodynamics improved dramatically following the intracoronary nitroglycerine injection, and her chest pain vanished suddenly and completely.

Left ventriculography revealed a good left ventricular size and systolic function without regional wall-motion abnormalities (Figure 2E). The patient was transferred to the coronary care unit. Her cardiac troponin I level was reported to be 15 ng/L. Oral diltiazem 30 mg q.i.d. (and oral nitroglycerin 6.4 mg t.i.d.) were administered. The patient had no episodes of recurrent angina or arrhythmias during hospitalization. On the second day following admission, echocardiography was performed and it showed a left ventricular ejection fraction of 45% with no regional wall-motion abnormalities. The patient was discharged 7 days later and on her evaluation a month subsequently, she had no symptoms or complications and an analysis of her ICD revealed no episode of arrhythmias.

## Discussion

Vasospastic angina or Prinzmetal's variant angina is caused by focal or diffuse spasms in a major coronary artery, resulting in a high-grade obstruction. Patients with vasospastic angina are often young and exhibit few classic cardiovascular risk factors except for cigarette smoking.<sup>1</sup> Endothelial dysfunction, high levels of C-reactive protein, oxidative stress, and magnesium deficiency (in 45% of the patients) are also related to vasospastic angina.<sup>2</sup> Hyperthyroidism is another precipitating factor mentioned in recent studies.<sup>3</sup>

The differential diagnosis of vasospastic angina is acute ST-elevation myocardial infarction, acute pericarditis, stress-induced cardiomyopathy, and noncardiac chest pains associated with early repolarization. Parikh et al.<sup>4</sup> described a 43-year-old man, who had multiple coronary risk factors including hypertension and dyslipidemia and complained of chest pains. The authors reported that the patient had a positive stress test and significantly stenotic left main and proximal RCA on coronary angiography, both of which were relieved with an intracoronary nitroglycerin injection. Coronary spasms must, therefore, always be in the differential diagnosis of atherosclerotic coronary artery stenosis.

In our patient, we established the diagnosis of vasospastic angina after observing multivessel high-grade coronary obstructions on coronary angiography. The pain was relieved with the injection of intracoronary nitroglycerine. Provocation tests can also be used in selected cases such as those with a history of syncope and nondiagnostic coronary

angiography. Sueda et al.<sup>5</sup> investigated patients with a history of syncope who underwent coronary angiography. They observed coronary vasospasm, based on a positive pharmacologic provocation test, in 75% of the patients with a history of syncope. Only 62.9% of these patients had a history of a chest pain before syncope.

Myocardial infarction and life-threatening arrhythmias may occur in approximately 25% of untreated patients with vasospastic angina.<sup>6, 7</sup> Nearly 10% of patients with vasospastic angina present with sudden cardiac death. Our patient presented with cardiogenic shock because of myocardial stunning caused by severe multivessel coronary vasospasms.

Medical treatment with calcium-channel blockers (CCBs) and oral long-acting nitrates for the alleviation of symptoms appears to be able to decrease the frequency of life-threatening events.<sup>2</sup> Continuing CCBs is important in multivessel spasms, even in asymptomatic patients, due to the risk of lethal arrhythmias.<sup>2</sup> Investigations also suggest the implantation of an ICD<sup>6</sup> in patients with an aborted cardiac arrest as the presentation of vasospastic angina. However, ICD implantation may not improve patients' survival.<sup>8</sup> The endothelin receptor antagonist, bosentan, has shown promising results in some cases of vasospastic angina.<sup>9</sup>

Other drugs have been suggested for vasospastic angina. Nicorandil is effective in relieving coronary spasms.<sup>2</sup> Magnesium supplements, angiotensin-converting enzyme inhibitors, angiotensin-receptor blockers, statins, vitamin C, and vitamin E may have beneficial effects in preventing subsequent episodes of coronary vasospasms.<sup>2</sup>

Our patient had survived an episode of cardiac arrest 3 months earlier, for which she underwent ICD implantation apparently after evaluations for reversible causes. It must be kept in mind that a considerable number of the survivors of sudden cardiac arrest show evidence of coronary spasms. Consequently, an evaluation for coronary vasospasms may be mandatory if no other cause for cardiac arrest is found.<sup>10</sup> CCBs and long-acting oral nitrates can reduce the likelihood of the future episodes of recurrent spasms in these patients and can be lifesaving.

Intervention in the form of percutaneous coronary intervention may be helpful in vasospastic angina if significant obstructive coronary disease is present.<sup>2, 11</sup> Because our patient did not have any obstructive coronary disease and presented with only severe coronary spasm, we decided that the placement of an intracoronary stent was not necessary.

The long-term prognosis of vasospastic angina, particularly in patients receiving medical therapy, is good.<sup>2</sup> However, our patient had experienced multivessel spasms and an aborted sudden cardiac arrest previously, which are 2 indicators of a poor prognosis.<sup>8, 12</sup>

## Conclusion

Coronary vasospasms constitute a differential diagnosis of chest pains accompanied by ST-segment elevations, especially in young patients with no obvious atherosclerotic risk factors. Coronary vasospasms can lead to cardiac arrest or cardiogenic shock and even death. The administration of intravenous nitrates at presentation and urgent coronary angiography can be lifesaving in such cases.

## References

1. Sugiishi M, Takatsu F. Cigarette smoking is a major risk factor for coronary spasm. *Circulation* 1993;87:76-79.
2. Yasue H, Nakagawa H, Itoh T, Harada E, Mizuno Y. Coronary artery spasm--clinical features, diagnosis, pathogenesis, and treatment. *J Cardiol* 2008;51:2-17.
3. Menichetti F, Orsini E, Delle Donne MG, Dini FL, Marzilli M. ST-segment elevation acute myocardial infarction associated with hyperthyroidism: beware of coronary spasm! *J Cardiovasc Med (Hagerstown)* 2017;18:798-799.
4. Parikh A, Vacek TP. Spontaneous left main and right coronary artery spasm in a patient with vasospastic angina. *J Investig Med High Impact Case Rep* 2017;5:2324709617732796.
5. Sueda S, Kohno H, Fukuda H, Ochi N, Kawada H, Hayashi Y, Uraoka T. Clinical impact of selective spasm provocation tests: comparisons between acetylcholine and ergonovine in 1508 examinations. *Coron Artery Dis* 2004;15:491-497.
6. Matsue Y, Suzuki M, Nishizaki M, Hojo R, Hashimoto Y, Sakurada H. Clinical implications of an implantable cardioverter-defibrillator in patients with vasospastic angina and lethal ventricular arrhythmia. *J Am Coll Cardiol* 2012;60:908-913.
7. Bory M, Pierron F, Panagides D, Bonnet JL, Yvorra S, Desfossez L. Coronary artery spasm in patients with normal or near normal coronary arteries. Long-term follow-up of 277 patients. *Eur Heart J* 1996;17:1015-1021.
8. Ahn JM, Lee KH, Yoo SY, Cho YR, Suh J, Shin ES, Lee JH, Shin DI, Kim SH, Baik SH, Seung KB, Nam CW, Jin ES, Lee SW, Oh JH, Jang JH, Park HW, Yoon NS, Cho JG, Lee CH, Park DW, Kang SJ, Lee SW, Kim J, Kim YH, Nam KB, Lee CW, Choi KJ, Song JK, Kim YH, Park SW, Park SJ. Prognosis of variant angina manifesting as aborted sudden cardiac death. *J Am Coll Cardiol* 2016;68:137-145.
9. Gül I, Aykan AC, Gökdeniz T, Celik S. A new hope in the treatment of coronary vasospasm: Bosentan. *Turk Kardiyol Dern Ars* 2013;41:633-637.
10. Kim NH, Ko JS. Can documented coronary vasospasm be the smoking gun in settling the etiology of sudden cardiac death? *Korean J Intern Med* 2017;32:816-818.
11. Gaspardone A, Tomai F, Versaci F, Ghini AS, Polisca P, Crea F, Chiariello L, Gioffrè PA. Coronary artery stent placement in patients with variant angina refractory to medical treatment. *Am J Cardiol* 1999;84:96-98, A8.
12. Ong P, Athanasiadis A, Borgulya G, Voehringer M, Sechtem U. 3-year follow-up of patients with coronary artery spasm as cause of acute coronary syndrome: the CASPAR (coronary artery spasm in patients with acute coronary syndrome) study follow-up. *J Am Coll Cardiol* 2011;57:147-152.