

## Brief Communication

# Optimal timing of tracheostomy in patients on veno-venous extracorporeal membrane oxygenation for coronavirus 2019: a case series

Takeo Matsuyoshi,<sup>1</sup> Keiki Shimizu, Hitoshi Kaneko, Daiyu Kohsen, Hiroaki Suzuki, Yuichi Sato, and Jun Hamaguchi

Department of Critical Care and Emergency Medicine, Tokyo Metropolitan Tama Medical Center, Fuchu, Tokyo, Japan

**Aim:** An early tracheostomy is often considered for patients with veno-venous extracorporeal membrane oxygenation (VV-ECMO). However, there is no consensus on the timing of a tracheostomy in patients on VV-ECMO for coronavirus disease 2019 (COVID-19). The present report described the optimal timing of tracheostomy for these patients.

**Method:** The present study was a single-center case series. We retrospectively reviewed the medical records of nine consecutive patients who underwent tracheostomy either during or after VV-ECMO treatment in our center between January 1, 2020 and December 31, 2020.

**Results:** All the patients received a percutaneous dilatational tracheostomy, which was performed during VV-ECMO in four patients. Three of these patients experienced hemorrhagic complications, and the remaining patient required a circuit change on the day after the operation. Heparin was discontinued 8 h preoperatively and resumed 1–14 h later. The platelet count was below normal in two patients, but no transfusion was performed. APTT was almost normal, and D-dimer was elevated postoperatively. The remaining five patients received a tracheostomy after weaning off VV-ECMO, and no complication was observed. Eight patients were deeply sedated during VV-ECMO to prioritize lung rest and prevent infecting the healthcare workers.

**Conclusion:** In the present study, patients who underwent a tracheostomy during VV-ECMO tended to have more hemorrhagic complications. Because an early tracheostomy during ECMO has little benefit for patients with COVID-19, it should be performed after weaning off VV-ECMO to protect the safety of the healthcare workers concerned.

**Key words:** hemorrhagic complications, heparin, lung rest, percutaneous dilatational tracheostomy

## INTRODUCTION

A TRACHEOSTOMY IS often considered in patients with severe respiratory failure who undergo veno-venous extracorporeal membrane oxygenation (VV-ECMO) because it allows the dosage of sedatives to be reduced, facilitates confirmation of neurological findings, and expedites respiratory rehabilitation. The Extracorporeal Life Support Organization (ELSO) guidelines also state that an early tracheostomy should be considered in patients 5 years of age or older.<sup>1</sup>

In the United States (US), a tracheostomy is recommended for patients with coronavirus disease 2019 (COVID-19) after PCR confirmation of negativity; however, in Europe it is not recommended within 14 days of COVID-19 onset to avoid increasing healthcare workers' risk of infection.<sup>2</sup> There is still no consensus on the timing of a tracheostomy in patients with VV-ECMO for COVID-19.

The present report described the clinical features and courses of COVID-19 in nine patients treated in our intensive care unit (ICU) and proposed a strategy for airway management of patients with VV-ECMO for COVID-19.

## METHODS

THE PRESENT STUDY was a single-center case series. We retrospectively reviewed the medical records of nine consecutive patients who underwent tracheostomy either

**Corresponding:** Takeo Matsuyoshi, MD, Department of Critical Care and Emergency Medicine, Tokyo Metropolitan Tama Medical Center, Fuchu, Tokyo 183-8524, Japan. E-mail: takeomtkc@yahoo.co.jp

Received 16 Feb, 2021; accepted 15 Apr, 2021

during or after VV-ECMO treatment in our center between January 1, 2020 and December 31, 2020. Data about the patient characteristics, clinical courses (initiation of mechanical ventilation, initiation of VV-ECMO, timing of the tracheostomy, and prone positioning), heparin discontinuation/resumption time before/after the tracheostomy, typical laboratory findings, and complications were extracted from the medical records. A hemorrhagic complication was defined as a hemorrhage requiring any kind of hemostatic procedure, such as compression or surgery. This study was approved by the hospital's institutional review board (No. 150), and written informed consent was obtained from the patients or their family.

In our hospital, VV-ECMO is established by dual cannulation (drainage: right internal jugular vein; return: right femoral vein). CARDIOHELP is used as the extracorporeal rotor/oxygenator device (Getinge, Tokyo, Japan). Heparin is used as the anticoagulant, and the target APPT value is 1.5–2 times the normal value. The indication for tracheostomy is considered in the early phase on VV-ECMO, and a percutaneous dilatational tracheostomy (PDT) is usually performed. The Ciaglia Blue Rhino method and bronchoscopy are used for all patients under general anesthesia with a muscle relaxant. The ventilator is not stopped during surgery. Postoperatively, patients are managed with minimal sedation to expedite respiratory rehabilitation.

## RESULTS

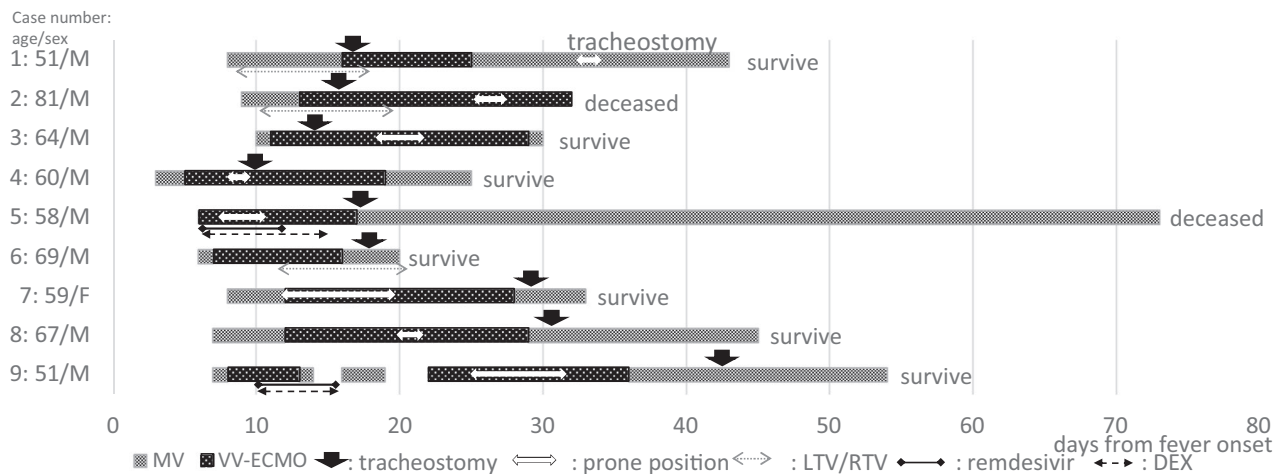
**FIGURE 1** SUMMARIZES THE patient characteristics and clinical courses. The median age was 62 years of age (range: 51–81 years of age), and only one patient was

female. Seven patients recovered, and their median duration of VV-ECMO use was 14.5 days (range: 9–19 days).

All the patients received a PDT by using the same method as for non-COVID-19 patients. The operation was performed in an individual negative-pressure room in the ICU. Four patients underwent the operation while still on VV-ECMO (1–5 days after initiation; the on-ECMO group), and five patients had already been weaned off VV-ECMO (2–6 days after weaning; the off-ECMO group). Prone positioning was applied during VV-ECMO in seven patients. In two of these patients, prone positioning was applied following the tracheostomy more than 7 days after the initiation of VV-ECMO.

Table 1 summarizes the heparin discontinuation/resumption time, laboratory data, and complications. Heparin was discontinued 8 h before the tracheostomy in all the patients and resumed 1–14 h postoperatively. The platelet count was less than  $10 \times 10^4/\mu\text{L}$  in two patients, but no blood transfusion was performed. The APTT immediately before the operation was normal in all but one patient. D-dimer was elevated after the tracheostomy in all the patients in the on-ECMO group. Hemorrhagic complications (stoma site bleeding) were observed in three patients in the on-ECMO group, with two treated with local compression and one requiring oral intubation and surgical hemostasis. Another patient in the on-ECMO group required a circuit change on the day after the operation; later it was found that the patient had heparin-induced thrombocytopenia (HIT). There were no complications in the off-ECMO group.

Although all the patients were deeply sedated after their tracheostomy (Richmond Agitation Sedation Scale [RASS] –4 to –5), only one patient (Table 1, case 3) achieved



**Fig. 1.** Clinical course of nine patients who underwent VV-ECMO and performed tracheostomy. MV, mechanical ventilation; VV-ECMO, veno-venous membrane oxygenation; LTV/RTV, lopinavir/ritonavir; DEX, dexamethasone.

**Table 1.** Heparin management and typical laboratory data before and after tracheostomy

| Case number | Heparin discontinuation (h) | Heparin resumption (h) | Platelet ( $\times 10^4$ ) | APTT (s) | D-dimer before ( $\mu\text{g/dL}$ ) | D-dimer after ( $\mu\text{g/dL}$ ) | Complications  |
|-------------|-----------------------------|------------------------|----------------------------|----------|-------------------------------------|------------------------------------|--|
| 1           | 8                           | 14                     | 26.6                       | 33.3     | 4.4                                 | 8.8                                | Stoma site bleeding  |
| 2           | 8                           | 1                      | 5.9                        | 35.5     | 11.5                                | 23.2                               | Stoma site bleeding  |
| 3           | 8                           | 8                      | 7.9                        | 43       | 13.7                                | 14.1                               | Circuit change on the next day                                 |
| 4           | 8                           | 1                      | 16.6                       | 24.5     | 6.4                                 | 36.7                               | Stoma site bleeding needed surgical hemostasis on the next day |
| 5           | N/A                         | N/A                    | 12.1                       | 22.8     | 19.5                                | 6.9                                | None   |
| 6           | N/A                         | N/A                    | 10.1                       | 23.4     | Unknown <sup>†</sup>                | Unknown <sup>†</sup>               | None   |
| 7           | N/A                         | N/A                    | 18.7                       | 20.2     | 27.7                                | 16.8                               | None   |
| 8           | 8                           | 20                     | 28.9                       | 23.8     | 3.7                                 | 8.5                                | None   |
| 9           | N/A                         | N/A                    | 47.2                       | 26.4     | 3.2                                 | 2.3                                | None   |

N/A, not applicable.

<sup>†</sup>No data.

management with RASS 0 in 2 days before weaning off VV-ECMO.

## DISCUSSION

**T**HE PRESENT STUDY found some negative aspects of an early tracheostomy during VV-ECMO use in patients with severe COVID-19. Bleeding complications were generally more common in patients who received a tracheostomy while on VV-ECMO. The hypercoagulable state in COVID-19 after discontinuation of anticoagulant administration raised concerns about the possibility of ECMO circuit malfunction. None of the patients were able to be awakened even after the tracheostomy. Prone positioning was not implemented or delayed in the on-ECMO group. Finally, some measures (e.g., using enough muscle relaxant to prevent coughing, stopping the ventilator if possible, avoiding periods of high viral load, etc.) were required to minimize the risk of infection among the healthcare workers during the procedures.

It is unclear why hemorrhagic complications were more common among the patients in the on-ECMO group. Although some institutions may prefer a surgical tracheostomy, PDT during VV-ECMO is reportedly safe,<sup>3,4</sup> and the procedure is currently being performed in non-COVID-19 patients during VV-ECMO use at our center. Heparin discontinuation/resumption and the platelet transfusion threshold accorded with the local protocol, and there was no difference between the findings of previous studies<sup>3,4</sup> and our own protocol (heparin was discontinued 8 h before,

resumed 1 h after tracheostomy at the earliest, and platelet transfusion was performed when the platelet count was  $5 \times 10^4/\mu\text{L}$  or less).

Coagulation disorder and thrombosis have been reported in patients with COVID-19.<sup>5</sup> Viscoelasticity tests, such as thromboelastography and rotational thermo-electrometry, have indicated hypercoagulability rather than consumptive coagulopathy.<sup>6</sup> In the on-ECMO group, in the present report, D-dimer was elevated postoperatively in all the patients, presumably because of microthrombus formation in the circuit resulting from heparin discontinuation. It may be speculated that in patients with COVID-19, heparin discontinuation during VV-ECMO may promote disseminated intravascular coagulation because of microthrombi formation, resulting in consumptive coagulopathy. Although only one patient (with HIT) required a circuit change after the tracheostomy, physicians should generally be aware of the possibility of circuit-related problems during heparin discontinuation. Valchanov et al.<sup>7</sup> reported that 39% of patients who underwent a tracheostomy during VV-ECMO did not discontinue heparin because of concerns about the hypercoagulable state in COVID-19. Whether or not heparin should be continued in patients with VV-ECMO for COVID-19 requires further study of hypercoagulability using viscoelasticity tests.

Deep sedation management was maintained in all the present patients after their tracheostomy because their breathing effort was strong even after the initiation of VV-ECMO, and lung rest was prioritized to prevent self-inflicted lung injuries. Moreover, healthcare workers were required to wear

personal protective equipment when treating patients with COVID-19, and because all the patients were housed in an individual negative-pressure room, the nursing staff was unable to respond immediately even when a patient was awake and exhibiting disturbing behavior. Therefore, deep sedation management also facilitated safe patient care.

Prone positioning is recommended for patients with COVID-19 requiring mechanical ventilation and is applied at our hospital even during VV-ECMO use.<sup>8</sup> However, prone positioning was not applied in the early phase in the on-ECMO group because of concerns about hemorrhaging at the tracheostomy site and dislodgement of the tracheostomy tube. Although a tracheostomy is not contraindicated for prone positioning, oral intubation may be preferable because there is no need for concern about bleeding at the stoma site. Deep sedation is essential for performing prone positioning, and concomitant use of a muscle relaxant may be considered.

The risk of infection among healthcare workers is one of the most serious concerns in the context of the current pandemic. Zou *et al.*<sup>9</sup> reported that viral loads from nasal and throat swabs were highest in the early phase of the disease, with clearance occurring on days 9 to 15. Although no healthcare workers were infected in the present study, it is important to bear in mind that a tracheostomy at an early stage of VV-ECMO initiation may coincide with the period of highest infection risk. Japan ECMOnet for COVID-19 reported an ECMO duration of 15.9 days for survivors and 24.2 days for non-survivors,<sup>10</sup> in line with the findings of the present study on survivors, demonstrating that 16.5 days were required from the start of mechanical ventilation to weaning off VV-ECMO, and that a tracheostomy may have been unnecessary in this period.

## CONCLUSION

**I**N NINE PATIENTS with VV-ECMO for COVID-19 who underwent a tracheostomy, those who underwent a tracheostomy while on VV-ECMO tended to have more hemorrhagic complications. Because an early tracheostomy during ECMO has little benefit for patients with COVID-19, it should be performed after weaning off VV-ECMO to protect the safety of the healthcare workers concerned.

## DISCLOSURES

Approval of the Research Protocol: This study was approved by the hospital's institutional review board.

Informed Consent: Written informed consent was obtained from the patients or their family.

Registry of the study/trial: N/A.

Animal Studies: N/A.

Conflict of Interest: None declared.

## REFERENCES

- 1 ELSO.org[homepage on the internet]. Michigan: Extracorporeal Life Support Organization; [updated Aug 2017]. Available from <http://www.else.org/Resources/Guidelines.aspx/>.
- 2 Takhar A, Walker A, Tricklebank S, *et al.* Recommendation of a practical guideline for safe tracheostomy during the COVID-19 pandemic. *Eur. Arch. Otorhinolaryngol.* 2020; 277: 2173–84.
- 3 Braune S, Kienast S, Hadem J, *et al.* Safety of percutaneous dilatational tracheostomy in patients on extracorporeal lung support. *Intensive Care Med.* 2013; 39: 1792–9.
- 4 Kruit N, Valchanov K, Blanduszyn G, Fowles JA, Vuylsteke A. Bleeding complications associated with percutaneous tracheostomy insertion in patients supported with venovenous extracorporeal membrane oxygen support: a 10-year institutional experience. *J. Cardiothorac. Vasc. Anesth.* 2018; 32: 1162–6.
- 5 Levi M, Thachil J, Iba T, Levy JH. Coagulation abnormalities and thrombosis in patients with COVID-19. *Lancet Haematol.* 2020; 7: e438–e440.
- 6 Spiezia L, Boscolo A, Poletto F, *et al.* COVID-19-related severe hypercoagulability in patients admitted to intensive care unit for acute respiratory failure. *Thromb haemost.* 2020; 120: 998–1000.
- 7 Valchanov K, Salaunkey K, Prmar J. Percutaneous dilatational tracheostomy in coronavirus disease 2019 extracorporeal membrane oxygenation patients: a case series. *J. Cardiothorac. Vasc. Anesth.* 2021; 35: 348–50.
- 8 Qadri SK, Ng P, Toh TSW, *et al.* Critically ill patients with COVID-19: a narrative review on prone position. *Pulm. Ther.* 2020; 6: 233–46.
- 9 Zou L, Ruan F, Huang M, *et al.* SARS-CoV-2 viral load in upper respiratory specimens of infected patients. *N. Engl. J. Med.* 2020; 382: 1177–9.
- 10 Japan ECMOnet for COVID-19[homepage on the internet]. Tokyo: Survey of critically ill COVID-19 patients in Japan, managed by the Japan ECMOnet for COVID-19. [updated Jan 1 2021]. Available from: <http://www.crisis.ecmonet.jp/>.