



# A Review of the Gillquist Maneuver: Modifications for a Safer and Easily Reproducible Approach for Knee Transintercondylar Notch Posterior Compartment Arthroscopy

Jia Ying Lee, M.B.B.S., M.R.C.S.,  
Zi Yang Chia, M.B.B.S., M.R.C.S., M.Med., F.R.C.S., F.A.M.S., Lei Jiang, M.B.B.S., M.R.C.S.,  
Benjamin Ang, M.B.B.S., M.R.C.S., M.Med., F.R.C.S., F.A.M.S., and  
Paul Chang, M.B.B.S., F.R.C.S. (Edin.), F.A.M.S.

**Abstract:** The original Gillquist maneuver is done by passing the arthroscope through a portal in the patella tendon between the medial femoral condyle and posterior cruciate ligament to enter the posterior compartment. This is done blind and has been documented to result in broken cameras and damaged equipment. It is also necessary to do a notchplasty to aid the advancement of the camera in patients. In our paper, we have made modifications to allow the Gillquist maneuver to be done safely under direct visualization, with just the aid of a simple switching stick. Our technique starts with the arthroscope in the anteromedial portal. We insert a long, cannulated switching stick through the anterolateral portal and pass it between the medial femoral condyle and the posterior cruciate ligament. The switching stick, being tapered and narrow, is able to traverse the transcondylar notch with minimal trauma. Once the switching stick enters the posterior compartment, the camera and trocar are removed and the trocar sleeve is guided over the switching stick past the intercondylar notch gently. The switching stick is then replaced by the arthroscope, which is advanced through the trocar sleeve and into the posterior compartment.

## Introduction (With Video Illustration)

Gillquist was one of the pioneers of knee arthroscopy, so important that a memorial was written in arthroscopic journals when he passed.<sup>1,2</sup> In 1979, he was the first to publish a technique to access the posterior compartment of the knee. He described introducing a 5-mm Storz arthroscope (30° viewing angle) through the patellar tendon in the mid-line 1 cm below the apex of the patella, passing it between the medial

femoral condyle and the posterior cruciate ligament (PCL) to enter the posterior compartment. Thereafter, the 30° angled telescope is replaced by a 70° instrument for greater field of view.<sup>3</sup> This provides visualization of the meniscus, its posterior horn and meniscocapsular junction, the PCL, and any loose bodies in the posterior compartment. The modified Gillquist maneuver uses the anterolateral or anteromedial portal for arthroscope introduction instead of the transpatella tendon portal for transcondylar posterior compartment visualization.

Transcondylar insertion of the arthroscope is not always easy, especially in knees with intact cruciate ligaments and osteoarthritis. There is often scar tissue and adhesions, and the space can be tight and difficult to penetrate (Video 1). This is evident by the fact that McGinnis et al.<sup>4</sup> reported his preference of doing an inferior notchplasty at the lateral aspect of the medial femoral condyle to aid the advancement of his arthroscope. Furthermore, directly inserting a transcondylar arthroscope results in camera breakage or bending.<sup>5</sup> In the study of Lubowitz et al.,<sup>5</sup> they abandoned transcondylar arthroscope advancement due to damage to the arthroscope, replacing the arthroscope within the

From Singapore General Hospital (J.Y.L., Z.Y.C., L.J., B.A., P.C.); and Duke-NUS Graduate Medical School (L.J., P.C.), Singapore.

The authors report that they have no conflicts of interest in the authorship and publication of this article. Full ICMJE author disclosure forms are available for this article online, as [supplementary material](#).

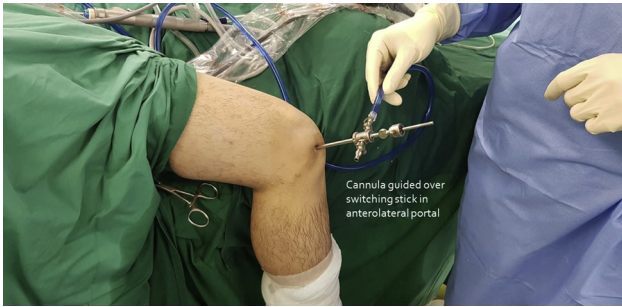Received September 20, 2019; accepted November 19, 2019.

Address correspondence to Jia Ying Lee, M.B.B.S., M.R.C.S., Singapore General Hospital, 20 College Rd, Singapore 169856. E-mail: [Jiaying.lee@mohh.com.sg](mailto:Jiaying.lee@mohh.com.sg)

© 2019 by the Arthroscopy Association of North America. Published by Elsevier. This is an open access article under the CC BY-NC-ND license (<http://creativecommons.org/licenses/by-nc-nd/4.0/>).

2212-6287/191150

<https://doi.org/10.1016/j.eats.2019.11.014>

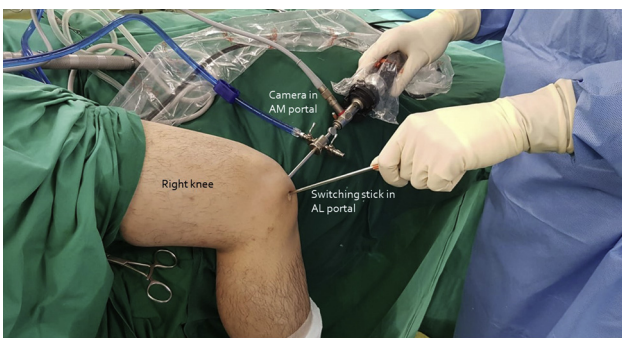


**Fig 1.** The trocar sleeve is introduced over the switching stick in the anterolateral portal of the right knee to enter the posterior compartment.

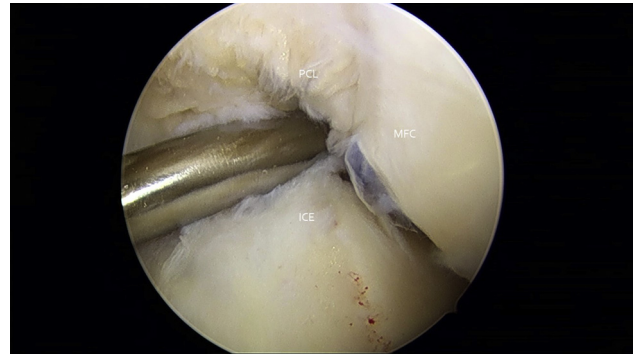
arthroscopic cannula with a blunt obturator instead. Kramer et al.<sup>6</sup> described this very technique, which involves the placement of a blunt obturator through the anterolateral portal. This is done blind, by palpating the nonarticular anterolateral wall of the medial femoral condyle and following the lateral border of the medial femoral condyle until there is a give through the interval between the posterior cruciate ligament and the medial femoral condyle. The obturator is then replaced with the arthroscope to achieve visualization of the posteromedial compartment. Ahn and Ha<sup>7</sup> also reported a similar technique passing a trocar together with its cannula through the transcondylar notch to the posteromedial compartment while feeling for its passage.

However, these techniques, because they are performed blind, can cause trauma to the PCL, meniscus, and articular cartilage while the cannula is being advanced. They have been reported to cause mild damage in 22% of knees and severe damage in 3% of knees, and entry into the posterior compartment of the knee fails 3% of the time.<sup>5</sup> Furthermore, since the popliteal artery is a mere 14 mm away from the posterior tibial cortex in 90° of flexion, there is also a definite risk, although rare, of damaging the popliteal artery.<sup>8-10</sup>

In 1991, Schreiber<sup>11</sup> described a way to minimize the risk of blind advancement of the cannula. He kept a cannula in each portal, interchanging instruments and the arthroscope within the cannulas. To access the



**Fig 2.** External view of scope placement during right knee arthroscopy. (AL, anterolateral; AM, anteromedial.)

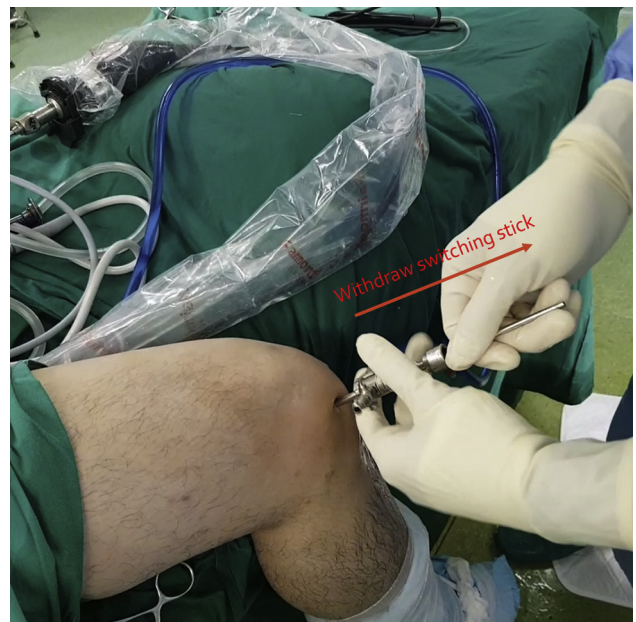

**Fig 3.** Right knee arthroscopy with camera inserted in anteromedial portal with the switching stick in the anterolateral portal. Trajectory and direction of switching stick demonstrated. (ICE, intercondylar notch; MFC, medial femoral condyle; PCL, posterior cruciate ligament.)

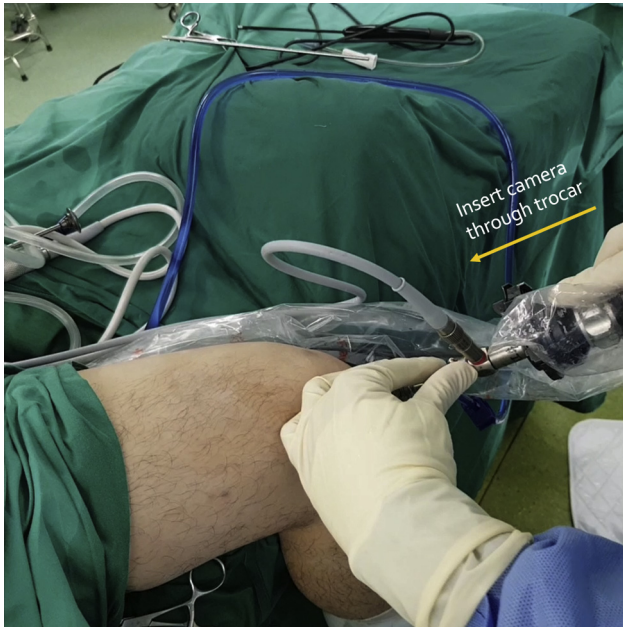posteromedial compartment, the obturator is inserted from the anterolateral portal into the posteromedial compartment. The arthroscope is then switched over to be passed through the cannula that has accessed the posterior compartment. The advantage of this technique is that the obturator can be inserted under direct vision; however, the disadvantage is the obturator, being nontapered, still can cause trauma while it is passed through a tight notch. Furthermore, there is a need for additional obturators and sets.

### Surgical Technique: Use of the Switching Stick to Guide Cannula Insertion

Because of the large diameter of the cannula that still can cause damage to the surrounding structures, we



**Fig 4.** Right knee, the switching stick is removed from the anterolateral portal.



**Fig 5.** Right knee, the camera is inserted through the trocar in the anterolateral portal.

have developed another method for passing the arthroscope to the posterior compartment. Our simple technique involves using a long, cannulated switching stick (switching stick, 4.5 mm × 340 mm; Smith & Nephew, Andover, MA) with a narrower diameter than our trocar sleeve, passing it through the anterolateral portal between the lateral border of the medial femoral condyle and the medial border of the PCL. This is done under direct visualization with the arthroscope in the anteromedial portal. The switching stick, being tapered and narrow, is able to traverse the transcondylar notch with minimal trauma. Once the switching stick enters the posteromedial compartment, the camera and trocar are removed from the anteromedial portal and

separated. The trocar sleeve is then introduced over the switching stick in the anterolateral portal and guided through and past the intercondylar notch gently into the posterior compartment (Fig 1). The switching stick is then replaced by the arthroscope, which is then advanced through the trocar sleeve and into the posterior compartment of the knee (Video 1).

The entire sequence of events is a 6-step process and is as follows: Step 1: Start with the knee at 90° of flexion. Insert the arthroscope in the anteromedial portal to visualize the intercondylar notch (Fig 2). Step 2: Insert the switching stick into the anterolateral portal and pass it between the lateral border of the medial femoral condyle and the medial border of the PCL. Continue advancing the switching stick until it enters the posteromedial compartment (Fig 3). Step 3: Remove the camera and trocar from the anteromedial portal and separate the components. Step 4: Introduce the trocar sleeve over the switching stick in the anterolateral portal and guide it gently through and past the intercondylar notch into the posterior compartment (Fig 1). Step 5: Withdraw the switching stick but maintain the position of the trocar sleeve (Fig 4). Step 6: Insert the camera through the trocar sleeve in the anterolateral portal to visualize the posterior compartment (Fig 5).

## Discussion

This simple technique of using the switching stick as a guide to aid the entry of the cannula to the posterior compartment is a safe and easy method to follow. It minimizes trauma to the surrounding structures and can be done under direct visualization. There is minimal risk of this procedure other than potential breakage of the switching stick while in the notch. The authors recommend using it for all surgeons performing transcondylar notch visualization arthroscopy (Tables 1 and 2).

**Table 1.** Pearls and Pitfalls

Pearls	Pitfalls
The synovium and prominent osteophytes at the notch should be adequately cleared.	Incisions placed too far from the midline will lead to a more angulated entry into the posterior compartment, and the view might be limited.
Hold the switching stick close to the incision and apply light medial force on the switching stick can be applied to “feel” the stick around the medial femoral condyle. Stop advancing when the curvature sharply increases.	Failure to anchor the hand steady or stay close to bone may increase the risk of advancing too fast into the posterior compartment and damaging structures.
Aim the switching stick low at the angle formed by the PCL and the tibial plateau.	
Modify the trajectory of the switching stick by modifying the degree of flexion or exerting a varus or valgus force on the knee.	

PCL, posterior cruciate ligament.

**Table 2.** Advantages of Traditional and Modified Gillquist Maneuver

Advantages	Advantages
Standard portals for arthroscope entry	Visualized entry into posterior compartment
One-step procedure, no change of portals	Switching stick can be directed into clear passage
	Tapered switching stick to minimize chondral damage and trauma to bone and soft tissue
	Decreased risk of overpenetration
	Cheap instrument and low-cost technique

## References

1. Lysholm J, Henriksson M, Tegner Y. In memoriam Jan Gillquist 1934–2016. *Knee Surg Sport Traumatol Arthrosc* 2016;24:2719-2720.
2. Johnson L. In Memoriam. *Rech Amerindien Que* 2016;45:190.
3. Gillquist J, Hagberg G, Oretorp N. Arthroscopic examination of the posteromedial compartment of the knee joint. *Int Orthop* 1979;3:13-18.
4. McGinnis MD IV, Gonzalez R, Nyland J, Caborn DNM. The posteromedial knee arthroscopy portal: A cadaveric study defining a safety zone for portal placement. *Arthroscopy* 2011;27:1090-1095.
5. Lubowitz JH, Rossi MJ, Baker BS, Guttman D. Arthroscopic visualization of the posterior compartments of the knee. *Arthroscopy* 2004;20:675-680.
6. Kramer DE, Bahk MS, Cascio BM, Cosgarea AJ. Posterior knee arthroscopy: Anatomy, technique, application. *J Bone Joint Surg Am* 2006;88:110-121 (suppl 4).
7. Ahn JH, Ha CW. Posterior trans-septal portal for arthroscopic surgery of the knee joint. *Arthroscopy* 2000;16:774-779.
8. Neagoe RM, Bancu S, Muresan M, Sala D. Major vascular injuries complicating knee arthroscopy. *Wideochir Inne Tech Maloinwazyjne* 2015;2:266-274.
9. Potter D, Morris-Jones W. Popliteal artery injury complicating arthroscopic meniscectomy. *Arthrosc J Arthrosc Relat Surg* 1995;11:723-726.
10. Bernhoff K, Björck M. Iatrogenic popliteal artery injury in non arthroplasty knee surgery. *Bone Joint J* 2015;97-B:192-196.
11. Schreiber SN. Arthroscopy update #9. Posterior compartment observation and instrumentation in the knee using anteromedial and anterolateral portals and an interchangeable cannula system. *Orthop Rev* 1991;20:1991.