

## Delay Posttraumatic Paradoxical Cerebrospinal Fluid Leak with Recurrent Meningitis

### Abstract

Cerebrospinal fluid (CSF) rhinorrhea complicates 2% of all head traumas, and 12%–30% of all basilar skull fractures. Posttraumatic CSF rhinorrhea usually occurs within the first 48 h, and majority of them occur in the first 3 months, whereas delayed CSF leak beyond 3 months is rare. On the other hand, CSF usually leaks through dural tearing associated with fracture of the anterior skull base. CSF leak through fractures of middle cranial fossa to the nose through the eustachian tube is very rare. We present a 52-year-old woman with delayed posttraumatic paradoxical CSF rhinorrhea and recurrent meningitis.

**Keywords:** Basilar skull fractures, cerebrospinal fluid meningitis, leak, rhinorrhea

### Introduction

Cerebrospinal fluid (CSF) rhinorrhea is not an unusual complication of head trauma which occur in 2% of patients with head trauma.<sup>[1]</sup> It usually occurs through dural tear and associated anterior skull base fracture. Rarely fracture of temporal bone occurs and fluid leak through middle fossa defect through eustachian tube to the nasopharynx results in paradoxical CSF rhinorrhea.<sup>[2]</sup>

### Case Report

A 53-year-old woman referred to our department with the complaint of clear watery discharge from the right nostril. She gave a history of head trauma due to car accident 6 years ago that underwent surgery for the evacuation of right temporal intraparenchymal hematoma.

She suffered from intermittent rhinorrhea starting 5 years after trauma which had lasted for 1 year and had been continuous for the previous 3 months. She had two bouts of meningitis after rhinorrhea that was treated conservatively in a different hospital.

She had no anosmia, and other neurological examinations were normal.

Routine biochemical and hematological investigations were within the normal range.

This is an open access journal, and articles are distributed under the terms of the Creative Commons Attribution-NonCommercial-ShareAlike 4.0 License, which allows others to remix, tweak, and build upon the work non-commercially, as long as appropriate credit is given and the new creations are licensed under the identical terms.

For reprints contact: reprints@medknow.com

The image findings of axial brain and coronal sinus computed tomography (CT) scans were evidence of previous right temporal craniotomy and adjacent parenchymal changes. CT cisternography, after intrathecal injection of 20cc Visipaque (VISIPAQUE Injection 270 mgI/ml, 20 ml, GE Healthcare, Norway), did not show bony defect on the anterior cranial fossa or detectable contrast leakage into the paranasal sinuses and nasal cavity (not shown).

Beside the mentioned findings, coronal T2-weighted magnetic resonance images depicted the high signal intensity area in favor of encephalomalacia in the left inferior temporal region associated with fluid signal in the left tympanic cavity and mastoid air cells [Figure 1]. It was the only clue to reassess the axial brain CT scan which revealed partial opacity of left mastoid air cells [Figure 2], and further evaluation with coronal images of the petrous bone which depicted large bony defect of the left tegmen tympani, tegmen mastoideum associated with opacity in the middle ear cavity, and lateral displacement of the ossicles [Figure 3].

The patient suspected to have paradoxical CSF rhinorrhea through eustachian tube from the defect of left temporal bone.

For further documentation, she underwent endoscopic transnasal examination after

**How to cite this article:** Sharifi G, Mousavinejad SA, Bahrami-Motlagh H, Eftekharian A, Samadian M, Ebrahimzadeh K, *et al.* Delay posttraumatic paradoxical cerebrospinal fluid leak with recurrent meningitis. *Asian J Neurosurg* 2019;14:964-6.

**Guive Sharifi,  
Seyed Ali  
Mousavinejad,  
Hooman  
Bahrami-Motlagh<sup>1</sup>,  
Ali Eftekharian<sup>2</sup>,  
Mohammad  
Samadian,  
Kaveh  
Ebrahimzadeh,  
Omidvar Rezaei**

*Departments of Neurosurgery,*

<sup>1</sup>*Radiology and* <sup>2</sup>*ENT, Skull  
Base Research Center; Loghman  
Hospital, Shahid Beheshti  
University of Medical Sciences,  
Tehran, Iran*

### Address for correspondence:

*Dr. Seyed Ali Mousavinejad,  
Department of Neurosurgery,  
Loghman Hospital, Shahid  
Beheshti University of Medical  
Sciences, Tehran, Iran.  
E-mail: alimousavi65@yahoo.  
com*

### Access this article online

**Website:** www.asianjns.org

**DOI:** 10.4103/ajns.AJNS\_95\_18

### Quick Response Code:



intrathecal injection of fluorescein dyes, which showed leakage of fluorescein, from left eustachian tube to the nasopharynx.

The patient underwent surgical repair of leakage through transmastoid approach.

The patient is placed in a lateral decubitus position, and a curve line incision behind the mastoid was performed. A wide mastoidectomy is performed and repair of the floor of middle fossa with fascia and autograft bone, and eustachian tube closure was done extradural.

### Discussion

A total of 17 cases of delayed posttraumatic CSF rhinorrhea including the present case are described in Table 1.

CSF leaks most commonly result from nonsurgical trauma (80%–90% of cases), 16% from surgical procedures and the remaining 4% are nontraumatic.<sup>[3,6,14,17-20]</sup>

It complicates 12%–30% of all basilar skull fractures.<sup>[1]</sup>

Moreover, it is associated with about a 10% risk of developing meningitis per year.<sup>[1,12,15,17,18,21-23]</sup> Traumatic CSF rhinorrhea is classified as immediate (within 48 h) or delayed.

More than 50% of traumatic CSF rhinorrhea occurred within the first 48 h and almost all present within the first 3 months,<sup>[19]</sup> delayed CSF leak beyond 3 months seen in the 5% of patients, whereas delay beyond a year is very rare.<sup>[24]</sup> However, prolonged delay of up to 44 years has been reported.<sup>[14]</sup>

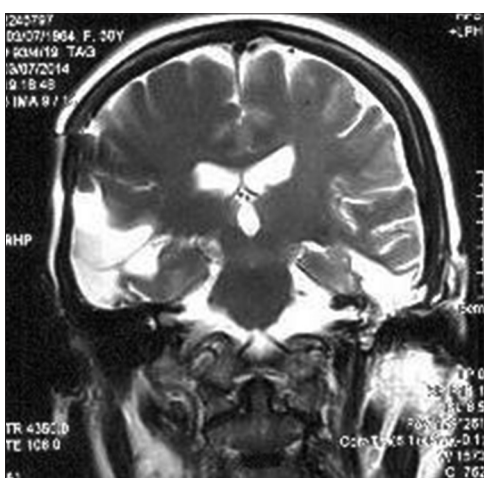


Figure 1: Coronal T2-weighted image depicts encephalomalacic changes in both temporal lobes. Increased signal is also present in the left middle ear which was the clue to the presence of cerebrospinal fluid leak

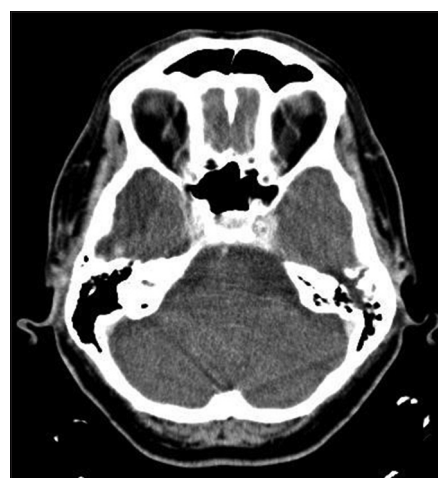
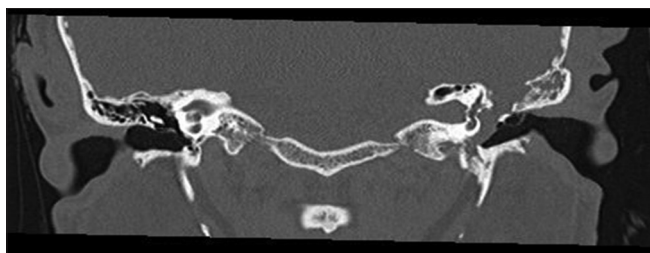


Figure 2: Axial computed tomography scan of the brain depicts partial opacity of the left mastoid air cells

**Table 1: Cases of delay post traumatic cerebrospinal fluid leak**

Author (year)	Age	Trauma	Interval from trauma to CSF leak (year)	Meningitis	Operative approach
Linell and Robinson 1941 <sup>[3]</sup>	-	Unknown	14	Yes	Unknown
Schneider and Thompson 1957 <sup>[4]</sup>	37	Traffic	Unknown	Yes	Unknown
	33	Gun shot	9	Yes	
Uemura and Makino 1972 <sup>[5]</sup>	-	Unknown	unknown	Yes	Unknown
Kamerer and Caparosa 1981 <sup>[6]</sup>	-	Unknown	17	-	Unknown
Merelli et al., 1982 <sup>[7]</sup>	35	Traffic accident	12	No	Intradural
Russell and Cummins 1984 <sup>[8]</sup>	43	Falling down	34	No	Intradural
Okada et al., 1991 <sup>[9]</sup>	44	Traffic accident	13	Yes	Intradural
	52	Head trauma	30	Yes	Intradural
Pandya and Keogh 1991 <sup>[10]</sup>	58	Traffic accident	35	Yes	Unknown
Stewart and kaye 1992 <sup>[11]</sup>	38	Traffic accident	14	Yes	Intrajadural
Crawford et al., 1994 <sup>[12]</sup>	40	Traffic accident	35	Yes	Unknown
Salca and Danaila 1997 <sup>[13]</sup>	54	Traffic accident	27	No	Extradural
Rao et al., 2010 <sup>[14]</sup>	57	Falling down	44	No	Intradural
Kamochi et al., 2013 <sup>[15]</sup>	66	Traffic accident	20	Yes	Intradural
	62	Traffic accident	5	No	Intradural
Guyer and Turner 2015 <sup>[16]</sup>	61	Traffic accident	12	No	Intradural

CSF – Cerebrospinal fluid



**Figure 3: Coronal reformat of petrous temporal computed tomography scan depicts bony defect in left tegmen tympani associated with opacity in the middle ear and lateral displacement of ossicles**

The mechanisms of delayed CSF leak are the resolution of edema, absorption of blood clot, contracture of scar, and necrosis of soft tissues or bone.<sup>[1]</sup>

Usually, fluid leaking through dural tearing and associated fracture of anterior cranial fossa involving cribriform plate and posterior wall of the frontal sinus and sphenoid sinus.

Rarely, paradoxical CSF rhinorrhea could be occurred.<sup>[2]</sup>

Paradoxical rhinorrhea is rhinorrhea from the naris contralateral to the site of CSF leakage which can occur with displaced fractures of the midline structures, the crista galli and vomer, or in the setting of mucocele formation obstructing the ipsilateral naris.

Paradoxical rhinorrhea also could be seen after temporal bone fractures when the fluid leak from tearing of the temporal dura and travels down to the nasopharynx through the eustachian tube.<sup>[22]</sup>

Paradoxical CSF rhinorrhea usually manages conservatively with good success in the acute setting, but in the cases of recurrent meningitis or delay CSF rhinorrhea, it seems that surgical repair associated with the best outcome.<sup>[23]</sup>

#### Declaration of patient consent

The authors certify that they have obtained all appropriate patient consent forms. In the form the patient(s) has/have given his/her/their consent for his/her/their images and other clinical information to be reported in the journal. The patients understand that their names and initials will not be published and due efforts will be made to conceal their identity, but anonymity cannot be guaranteed.

#### Financial support and sponsorship

Nil.

#### Conflicts of interest

There are no conflicts of interest.

#### References

- Friedman JA, Ebersold MJ, Quast LM. Post-traumatic cerebrospinal fluid leakage. *World J Surg* 2001;25:1062-6.
- Banks CA, Palmer JN, Chiu AG, O'Malley BW Jr, Woodworth BA, Kennedy DW, *et al.* Endoscopic closure of CSF rhinorrhea: 193 cases over 21 years. *Otolaryngol Head Neck Surg* 2009;140:826-33.
- Linell EA, Robinson WL. Head injuries and meningitis. *J Neurol Neurosurg Psychiatry* 1941;4:23.
- Kamerer DB, Caparosa RJ. Temporal bone encephalocele – Diagnosis and treatment. *Laryngoscope* 1981;92:878-82.
- Rao K, Shukla D, Indira Devi B. Unusually delayed posttraumatic CSF rhinorrhea. *Indian J Neurotrauma* 2010;7:171-2.
- Iffenecker C, Benoudiba F, Parker F, Fuerxer F, David P, Tadié M, *et al.* The place of MRI in the study of cerebrospinal fluid fistulas. *J Radiol* 1999;80:37-43.
- Jones NS, Becker DG. Advances in the management of CSF leaks. *BMJ* 2001;322:122.
- Kerman M, Cirak B, Dagtekin A. Management of skull base fractures. *Neurosurg Q* 2001;12:23-41.
- Lopatin AS, Kapitanov DN, Potapov AA. Endonasal endoscopic repair of spontaneous cerebrospinal fluid leaks. *Arch Otolaryngol Head Neck Surg* 2003;129:859-63.
- Bernal-Sprekelsen M, Alobid I, MULLOL J, Trobat F, Tomás-Barberán M. Closure of cerebrospinal fluid leaks prevents ascending bacterial meningitis. *Rhinology* 2005;43:277.
- Bhalodiya NH, Joseph ST. Cerebrospinal fluid rhinorrhea: Endoscopic repair based on a combined diagnostic approach. *Indian J Otolaryngol Head Neck Surg* 2009;61:120-6.
- Dalgiç A, Seçer M, Ergüngör MF, Okay HO, Uçkun O, Yıldırım AE. Traumatic posterior fossa epidural hematomas and their complications *J Neurol Sci (Turkish)* 2007;24:280-6.
- Talamonti G, Fontana RA, Versari PP, Villa F, D'Aliberti GA, Car P, *et al.* Delayed complications of ethmoid fractures: A “growing fracture” phenomenon. *Acta Neurochir (Wien)* 1995;137:164-73.
- Schneider RC, Thompson JM. Chronic and delayed traumatic cerebrospinal rhinorrhea as a source of recurrent attacks of meningitis. *Ann Surg* 1957;145:517.
- Uemura K, Makino H. Operative indication and operative method of frontal base skull fracture. Lewin's intradural patch. *Shuju* 1972;26:733-42.
- Merelli E, Merli GA, Sola P. An unusual method for diagnosing spinal fluid rhinorrhea in a case of delayed post-traumatic fistula. *Ital J Neurol Sci* 1982;3:249-50.
- Russell T, Cummins BH. Cerebrospinal fluid rhinorrhea 34 years after trauma: A case report and review of the literature. *Neurosurgery* 1984;15:705-6.
- Okada J, Tsuda T, Takasugi S, Nishida K, Tóth Z, Matsumoto K, *et al.* Unusually late onset of cerebrospinal fluid rhinorrhea after head trauma. *Surg Neurol* 1991;35:213-7.
- Pandya PM, Keogh AJ. Traumatic cerebrospinal fluid rhinorrhoea: A timely reminder. *Injury* 1991;22:492.
- Stewart BT, Kaye AH. Delayed cerebrospinal fluid rhinorrhoea: A case report. *Aust N Z J Surg* 1992;62:818-20.
- Crawford C, Kennedy N, Weir WR. Cerebrospinal fluid rhinorrhoea and haemophilus influenzae meningitis 37 years after a head injury. *J Infect* 1994;28:93-7.
- Salca HC, Danaïla L. Onset of uncomplicated cerebrospinal fluid fistula 27 years after head injury: Case report. *Surg Neurol* 1997;47:132-3.
- Kamochi H, Kusaka G, Ishikawa M, Ishikawa S, Tanaka Y. Late onset cerebrospinal fluid leakage associated with past head injury. *Neurol Med Chir (Tokyo)* 2013;53:217-20.
- Guyer RA, Turner JH. Delayed presentation of traumatic cerebrospinal fluid rhinorrhea: Case report and literature review. *Allergy Rhinol (Providence)* 2015;6:188-90.