



Microsurgical procedures during COVID-19 pandemic: the VITOM® 3D-HD exoscopic system as alternative to the operating microscope to properly use personal protective equipment (PPE)

Andrea Luigi Camillo Carobbio^{1,2} · Marta Filauro^{1,2,3} · Giampiero Parrinello^{1,2} · Francesco Missale^{1,4} · Giorgio Peretti^{1,2}

Received: 23 April 2020 / Accepted: 22 July 2020 / Published online: 29 July 2020
© Springer-Verlag GmbH Germany, part of Springer Nature 2020

Abstract

Purpose In the field of microsurgery, the use of conventional operating microscope, adopted in several disciplines, is not suitable with the full adoption of appropriate personal protective equipment (PPE), as goggles and face shields, needing the eyes to be at close contact with oculars.

Methods Herein we present an exoscopic surgical setup, implemented for transoral laser microsurgery, by the VITOM® 3D-HD system.

Results Our proposed exoscopic setting overcomes safety limits of the conventional operating microscope, being suitable with the adoption of full PPE necessary facing with suspected or confirmed positive SARS-CoV-2 patients needing urgent microsurgical procedures.

Conclusion The use of protocols to reduce the virus spreading is mandatory to safely treat also patients potentially SARS-CoV-2 infected. The described surgical setup is advisable to manage urgent microsurgical procedures along the duration of the COVID-19 pandemic, being applicable PPE necessary to treat potentially or confirmed SARS-CoV-2-infected patients.

Keywords VITOM · Microscope · COVID-19 · Exoscope · PPE · Laryngeal cancer

Background

The novel coronavirus disease 2019 (COVID-19) is a highly contagious zoonosis, caused by the severe acute respiratory syndrome coronavirus 2 (SARS-CoV-2) that, despite its low case fatality rate (1.4%) [1], for its highly infectiousness and rapid spreading is ravaging several health systems worldwide [2]. To date (14th April 2020), 1,844,863 cases are registered worldwide, being 159,516 of these reported in Italy

(8.6%). The whole number of registered deaths are 117,021, of which 20,465 are recorded in Italy (17.5%) [3]. The quick spreading of this disease, defined a pandemic since 11th March, is ascribable also to the evidence of infectiousness during pre-clinical period or among asymptomatic patients [4].

Human coronaviruses are transmitted mainly by the respiratory route by droplets or via contact with infected secretions [5]. To date, there is a significant risk of dissemination among healthcare workers, as 20% of these are being affected by COVID-19 infection in Italy [6], and healthcare workers represent 3.8% of whole infected cases in Wuhan (China) [2].

In the specific Otorhinolaryngology and Head and Neck surgery field, several clinical and surgical maneuvers are at high risk of transmission of the infection, as even for the clinical inspection of upper aerodigestive tract it is necessary to remove the patients' face mask. Furthermore, diagnostic instrumental procedures, as flexible laryngeal endoscopy or rigid nasal endoscopy, can induce cough and sneezing with huge amount of aerosol generation: for any care or

✉ Francesco Missale
missale.francesco@gmail.com

¹ IRCCS Ospedale Policlinico San Martino, Largo Rosanna Benzi, 10, 16132 Genoa, Italy
² Department of Surgical Sciences and Integrated Diagnostics (DISC), University of Genoa, Genoa, Italy
³ Department of Experimental Medicine (DIMES), University of Genoa, Genoa, Italy
⁴ Department of Molecular and Translational Medicine, University of Brescia, Brescia, Italy

intervention, otolaryngologists and head and neck surgeons must wear the personal protective equipment (PPE), such as N95, FFP3, or FFP2 masks, gown, cap, eye protections (goggles and face shields), and gloves [7].

Furthermore, in several microsurgical procedures for diseases of the upper aerodigestive tract, where the use of the microscope is mandatory, the correct use of PPE can be tough: the operating microscope, in fact, requires surgeons to keep the eyes directly on the microscope eyepieces. Cumbersome ocular PPEs as goggles or the face mask may worsen the view of the surgical field, needing to be removed. Consequently, a group of senior European Otolaryngologists and Head and Neck surgeons [2] recommended to avoid all elective intervention that have a potential to aerosolize aerodigestive secretions, and the treatment of time-sensitive cases, as cancer patients, should be discussed on a case-by-case basis minimizing the risks of contamination.

Howbeit, the need to perform some urgent procedures, such as not deferrable transoral oncologic surgeries or otologic interventions, such as mastoidectomy for otologic meningitis in suspicious or confirmed COVID-19 patients, must not preclude the correct use of all appropriate PPE, possibly adopting specific protocols, including the change of specific surgical devices.

To possibly solve the incompatibility between operating microscope and the need for PPE, an innovative

three-dimensional exoscopic surgical setting is proposed as a feasible and already tested alternative to the traditional microsurgical setup.

The VITOM® 3D-HD exoscopic system

In this new setting, the operating microscope is replaced by the exoscope VITOM® 3D-HD (Karl Storz SE & Co. KG, Tuttlingen, Germany) that we have already applied to perform transoral laser microsurgical procedures. Such system has been used in our institution as an alternative to the standard setting since October 2018. Differently from a traditional setting with an operating microscope, using such exoscopic system of vision the surgeon does not need to take protective visor or glasses off; in fact, the same 3D-HD image quality and depth perception are achieved by looking at a monitor with passive 3D polarization glasses (Fig. 1a, b). No contact between the surgeon's eyes and the microscope ocular is needed; instead, the 3D glasses can easily be worn underneath the protective visor by each component of the surgical team. Such solution results in improved involvement of the entire group, who can follow the procedure viewing the same 3D-HD images as the surgeon, with consequent higher awareness and safety (Fig. 1c, d). A previous study also showed a fast

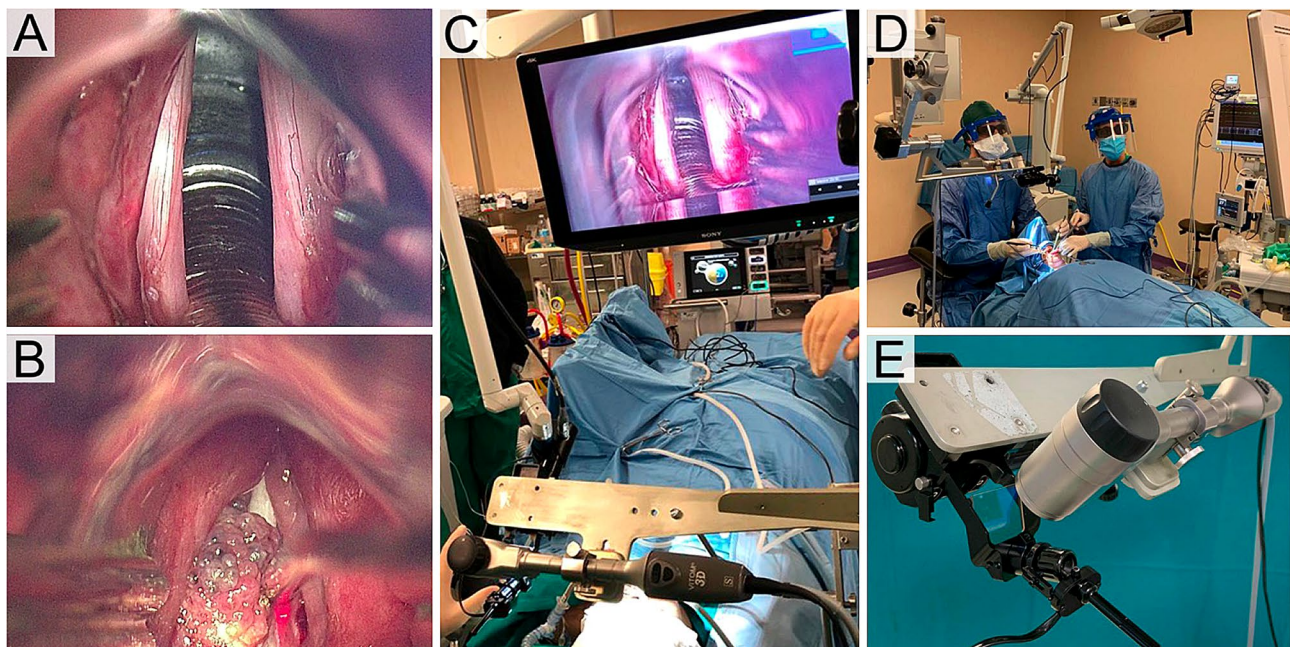


Fig. 1 Intraoperative view of the glottis by the VITOM® 3D-HD exoscope (**a**) and of a glottic left vocal cord tumor treated by a VITOM® 3D-HD-assisted transmuscular cordectomy with CO₂ free-beam laser (**b**); original intraoperative view is seen in three dimensions on a 3D-HD screen. Pictures of a surgical transoral laryngeal

(**c**) and oropharyngeal (**d**) surgery setup, showing the comfortable ergonomic, suitable with full personal protective equipment (PPE). A detail of the system to couple the VITOM® 3D-HD with the free-beam CO₂ laser micromanipulator (**e**)

learning curve for the comfort improvement using exoscopic systems for microneurosurgery, not dependent from the previous experience of the surgeon [8].

The main novelty of our specific setting is the design and application of a coupling system (model TH004 Micromanipulator Interface VITOM, installation of CO₂ laser micromanipulators on VITOM 3; Karl Storz SE & Co. KG, Tuttlingen, Germany) allowing the use of the VITOM® 3D-HD viewing platform together with the free-beam CO₂ laser micromanipulator, which is usually fixed to the microscope: the CO₂ laser is crucial, as cutting device, for a successful transoral laser microsurgery for laryngeal tumors (Fig. 1e). This support system was developed in collaboration with Italian Institute of Technology to optimize the connection between the VITOM® 3D-HD and the laser micromanipulator in a robust and stable structure. The designed system replaces the microscope head with a new adaptor piece that positions the VITOM® 3D-HD horizontally, clearing the field of view in front of the surgeon.

A magnified view of the surgical field is obtained by the 3D-HD exoscope and displayed at a 32" 3D monitor (model TM330, Karl Storz SE & Co. KG, Tuttlingen, Germany), which requires the use of passive 3D polarization glasses, while standard surgical instrumentation is employed. In this scenario, the chief surgeon takes place at the head of the patient's bed, sitting in a straight and free line of sight to the 3D-HD screen, which is positioned over the patient's legs. The exposure of the surgical target is granted by a suspension system placed over the patient's chest, connected to the most appropriate laryngoscope, depending on the target itself. An assistant surgeon helps the first operator by standing on the left of the patient's head, as usual. From this position, he is able to constantly adjust the framing and the focusing of the image, thanks to the IMAGE1 PILOT control joystick, by looking to the same 3D-HD screen; in the same time, the assistant surgeon can hold the suction or other surgical instruments and can make external counterpressure on the larynx, if needed.

When the 3D-HD system of vision is employed in particular settings, as for oral cavity or oropharyngeal lesions [9], or reconstructive surgery [10], or otoneurosurgery [11], where micromanipulator for the CO₂ laser is not needed, traditional cold instruments, monopolar scalpels, or fiber lasers can be employed as cutting devices. The disposition of the nurse's master table and secondary table, as well as the anesthesia device or other surgical devices in the operatory room, is not further influenced by the application of this setting and is totally similar to a traditional procedure. Furthermore, for surgeons with experience on microscopic procedures only, shifting to an exoscopic system, which allows the employment of both hands during surgical procedures, could be easier compared to a pure endoscopic setting.

Perspectives

The quick dissemination worldwide of the COVID-19 pandemic and its evolution, suggesting a long-lasting permanence in the community, needs the application of several efforts to prevent its spreading among healthcare workers, being these both a strong potential source for further propagation of the disease and a crucial and not replaceable resource during such pandemic [2].

In the field of microsurgery, the use of conventional operating microscope, adopted in several disciplines as neurosurgery, otoneurosurgery, laryngology, reconstructive surgery, orthopedics, and ophthalmology, is not suitable with the full adoption of appropriate PPE, being the eye protection goggles or face shields the main reason for that needing the eyes to be at close contact with oculars. Full HD or 4 K cameras couplable with microscope's ocular can just partially solve this issue, losing the depth of field of binocular view and not providing in most of the cases a clear and surgically safe view. The need of performing safe microsurgical urgent procedures, referred in Otolaryngology field as time-sensitive oncologic procedures as transoral laser microsurgery, or transoral resection of critical laryngotracheal stenosis, or basic otologic surgical procedures, such as mastoidectomy for otologic meningitis in suspected or confirmed COVID-19 patients, can be answered with the above-mentioned VITOM® 3D-HD exoscopic system. If the use of laser cannot be replaced by cold knife cutting devices, the use of proper smoke suction systems and PPEs are highly recommended knowing the risk of viral particles carried in smoke aerosols [12].

In our previous experience with this setting, we analyzed a series of 17 patients affected by pharyngo-laryngeal early-intermediate stage tumors and successfully treated by transoral laser VITOM® 3D-HD exoscopic surgery, achieving a safe control of the margins and with surgical procedures' duration statistically comparable to conventional microsurgery (unpublished data, presented at 7th World Congress of the International Academy of Oral Oncology, Rome, 2019) [13]. For these reasons, it is advisable to recommend the use of such device for microsurgical procedures along the duration of COVID-19 pandemic.

This system is broad suitable also for otoneurosurgical, [11,14], neurosurgical [15] and reconstructive procedures [10], being its unique limit the coupling with the CO₂ laser micromanipulator, required for transoral laser microsurgery, that we managed with the above-mentioned coupling system.

Furthermore, whereas nowadays elective surgery, including a fraction of oncologic surgery, is postponed in countries facing COVID-19, soon and before the ending of

the pandemic these procedures probably will start again; in this future scenario, the adoption of safe protocols [2], including the possibility to use all advisable PPE also during microsurgery, will still be recommended.

Funding None of the authors have any commercial interest in the subject of this study or received any financial or material support for this study.

Compliance with ethical standard

Conflicts of interest The authors certify that they have no affiliation with or involvement in any organization or entity with any financial interest.

References

- Guan W, Ni Z, Hu Y et al (2020) Clinical Characteristics of Coronavirus Disease 2019 in China. *N Engl J Med*. <https://doi.org/10.1056/nejmoa2002032>
- Kowalski LP, Sanabria A, Ridge JA et al (2020) COVID-19 pandemic: effects and evidence-based recommendations for otolaryngology and head and neck surgery practice. *Head Neck*. <https://doi.org/10.1002/hed.26164>
- Practice BB (2020) Coronavirus disease 2019 (COVID-19) Situation Report – 85. *World Heal Organ*. <https://doi.org/10.1001/jama.2020.2633>
- Wei WE, Li Z, Chiew CJ et al (2020) Presymptomatic Transmission of SARS-CoV-2-Singapore. *Morb Mortal Wkly Rep* 69:411–415
- Lake MA (2020) What we know so far: COVID-19 current clinical knowledge and research. *Clin Med* 20:124–127. <https://doi.org/10.7861/clinmed.2019-coron>
- Remuzzi A, Remuzzi G (2020) COVID-19 and Italy: what next? *Lancet* 2:10–13. [https://doi.org/10.1016/S0140-6736\(20\)30627-9](https://doi.org/10.1016/S0140-6736(20)30627-9)
- Torretta S, Gaini LM, Pignataro L (2020) Why Italian ENT physicians should be aware of SARS-CoV-2. *Acta Otorhinolaryngol Ital* <https://doi.org/10.14639/0392-100X-N0738>
- Takahashi S, Toda M, Nishimoto M et al (2018) Pros and cons of using ORBEYE™ for microneurosurgery. *Clin Neurol Neurosurg* 174:57–62. <https://doi.org/10.1016/j.clineuro.2018.09.010>
- Crosetti E, Arrigoni G, Manca A et al (2020) 3D Exoscopic Surgery (3Des) for Transoral Oropharyngectomy. *Front Oncol* 10:1–8. <https://doi.org/10.3389/fonc.2020.00016>
- De Virgilio A, Iocca O, Di Maio P et al (2020) Free flap microvascular anastomosis in head and neck reconstruction using a 4K three-dimensional exoscope system (VITOM 3D). *Int J Oral Maxillofac Surg*. <https://doi.org/10.1016/j.ijom.2020.01.022>
- Rubini A, Di Gioia S, Marchioni D (2019) 3D exoscopic surgery of lateral skull base. *Eur Arch Oto-Rhino-Laryngology* 277:687–694. <https://doi.org/10.1007/s00405-019-05736-7>
- Thamboo A, Lea J, Sommer DD, et al (2020) Clinical evidence based review and recommendations of aerosol generating medical procedures in otolaryngology - head and neck surgery during the COVID-19 pandemic. *J Otolaryngol - head neck Surg = Le J d'oto-rhino-laryngologie Chir cervico-faciale* <https://doi.org/10.1186/s40463-020-00425-6>
- Carobbio ALC, Parrinello G, Canevari FRM, Peretti G (2019) Potential role of the 3D-HD exoscopic system in transoral surgical treatment of oro-hypopharyngeal tumors as a feasible alternative to TORS - 7th world congress of the International Academy of Oral Oncology, Rome (Italy) 31 Aug–3 Sep 2019
- Smith S, Kozin ED, Kanumuri VV et al (2019) Initial experience with 3-dimensional exoscope-assisted transmastoid and lateral skull base surgery. *Otolaryngol Head Neck Surg (United States)* 160:364–367. <https://doi.org/10.1177/0194599818816965>
- Oertel JM, Burkhardt BW (2017) Vitom-3D for Exoscopic Neurosurgery: Initial Experience in Cranial and Spinal Procedures. *World Neurosurg* 105:153–162. <https://doi.org/10.1016/j.wneu.2017.05.109>

Publisher's Note Springer Nature remains neutral with regard to jurisdictional claims in published maps and institutional affiliations.