


Home treatment of single cutaneous warts combining face-to-face and teledermatology consultation: A new perspective

Giuseppe Micali  | Federica Dall'Oglio | Anna Elisa Verzì | Helga Platania |
Francesco Lacarrubba

Dermatology Clinic, University of Catania,
Catania

Correspondence

Giuseppe Micali, Dermatology Clinic,
University of Catania, Via S. Sofia 78, 95123
Catania, Italy.
Email: cldermct@gmail.com

Abstract

During the COVID-19 pandemic, teledermatology services were set up and enhanced to take care of those benign conditions like cutaneous warts (CWs) which, if undiagnosed or treated with delay, could have worsened, enlarged, and potentially spread to the community. The aim of this hybrid exploratory trial was to combine face-to-face clinical and dermoscopic evaluation with teledermatology follow-up in the management of CWs with a cryogenic pen based on nitrous oxide for home treatment. Twelve adult patients affected by CWs were enrolled. During the first face-to-face visit, single CWs were selected for the study by clinical and dermoscopic evaluation. The home schedule consisted of one application to be repeated after 2 weeks, when signs of CWs were still evident. Patients were also asked to send a clinical photo of the treated lesion at weekly intervals. A final face-to-face evaluation was scheduled to verify the response to home treatment by clinical and dermoscopy evaluation. A total of 20 CWs located on the trunk and the extremities were treated: a complete clinical and dermoscopic resolution was observed in 16 out of 20 lesions (80%), and a partial response in two cases. The adverse events observed during treatment were comparable to those normally observed with cryotherapy of CWs. In conclusion, home treatment of CWs with the cryogenic pen, that should be always preceded by dermatologist diagnosis and prescription, is safe and effective, especially if combined with face-to-face and teledermatology consultations, pointing out its important role during pandemic times or in any other environmental limitations that may impair the access to medical care services. The combination of face-to-face consultations for initial and final visits and teledermatology during the treatment phase could represent a model for other dermatologic conditions as well (e.g., acne, rosacea, psoriasis, atopic eczema etc.).

KEYWORDS

cryotherapy, cutaneous wart, dermoscopy, teledermatology

This is an open access article under the terms of the [Creative Commons Attribution-NonCommercial-NoDerivs](https://creativecommons.org/licenses/by-nc-nd/4.0/) License, which permits use and distribution in any medium, provided the original work is properly cited, the use is non-commercial and no modifications or adaptations are made.

© 2022 The Authors. *Dermatologic Therapy* published by Wiley Periodicals LLC.

1 | INTRODUCTION

In the past 2 years, because of COVID-19 pandemic, public dermatologic units underwent several restrictions by the Italian government and local hospital management. One of the most critical issues was the decrease in number of permissible daily consultations to avoid overcrowded waiting rooms. Another one was the suggested booking priority for chronic skin disorder or life-threatening conditions (melanoma, etc.). Based on this, teledermatology services were set up and enhanced to take care of chronic skin diseases¹ and those benign conditions like cutaneous warts (CWs) which, if undiagnosed or treated with delay, could have worsened, enlarged, and potentially spread to the community.

The aim of this hybrid exploratory trial was to combine face-to-face clinical and dermoscopic evaluation with teledermatology follow-up in the management of CWs with a cryogenic device designed for home treatment.

2 | MATERIALS AND METHODS

Adult patients presenting with single or multiple, untreated CWs located on the trunk or the extremities were enrolled. Exclusion criteria were: age <18 years, pregnancy, immunosuppression, CWs >6 mm, facial, filiform, and/or clustered lesions. Informed consent from all participants was obtained.

During the first face-to-face visit, single CWs were selected for the study by clinical and dermoscopic evaluation. Each patient was then instructed to treat the lesions using a prescription-free cryogenic pen based on nitrous oxide for home treatment of common or plantar warts (EndWarts Freeze[®]). Activation of the device delivers a dose of nitrous oxide liquid into a polyurethane foam nib that is frozen

(−80°C) and applied according to the instructions for use: 15 s (40 s on feet).

Before the procedure, patients were advised about the expected appearance of frostbite in the application area that would be followed by a blister in the following hours, and then by a crust. The therapeutic plan consisted of one application (up to a maximum of three) to be repeated after 2 weeks, when the crust from the previous session was off and signs of CWs were still evident (Figure 1). Patients were also asked to send a clinical photo of the treated lesion at weekly intervals via WhatsApp or email in order to decide whether or not to continue the treatment session.

A final face-to-face evaluation was scheduled to verify the response to home treatment by clinical and dermoscopy evaluation. Informed consent from all participants was obtained.

3 | RESULTS

This evaluation has taken place at the Dermatology Clinic of the University of Catania, Italy, during pandemic period, from August to November 2021. Twelve adult patients (7M/5F, mean age 35 years, range: 18–58 years) were enrolled and a total of 20 CWs (size ranging between 2 and 6 mm) located on the trunk and the extremities were treated (Table 1).

All patients were able to perform the home treatment and to send adequate images of their lesions during the follow-up. At the end of the treatment, a complete clinical and dermoscopic resolution was observed in 16 out of 20 lesions (80%) after an average of 1.2 applications/lesion (range 1–2) (Figures 2 and 3). A partial response, with reduction of CW size, was detected in two cases. Two patients with one treated lesion each were lost to follow-up (drop out). Following wart freezing, all patients reported a blister formation which resulted

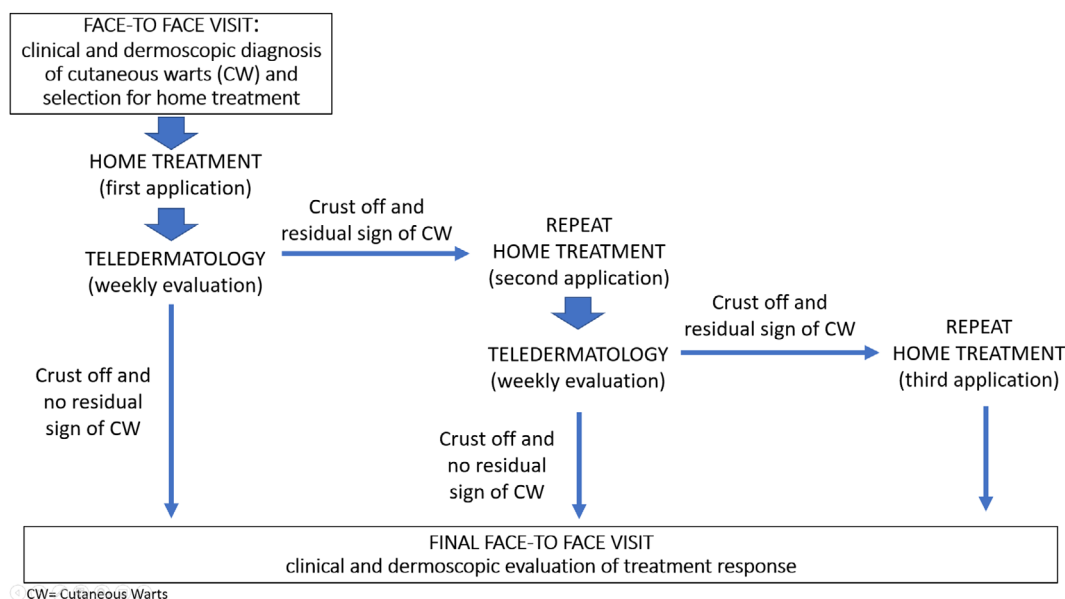


FIGURE 1 Treatment flow-chart

TABLE 1 Patients/CWs characteristics and results

Patient	Age	Sex	Type of CW	CW location	CW size (mm)	Result (clinical and dermoscopic)	Number of treatments	Crust duration (days from each treatment)
1	32	M	Common	trunk	4	Complete clearance	1	10
			Common	trunk	3	Complete clearance	1	9
2	29	M	Palmar	hand	5	Complete clearance	1	18
3	18	F	Common	foot	4	Complete clearance	2	13, 12
			Common	leg	5	Complete clearance	1	17
4	35	F	Common	leg	6	Complete clearance	1	18
5	28	M	Common	forearm	3	Complete clearance	1	16
			Common	forearm	6	Partial response	3	17, 13, 15
			Common	finger	4	Complete clearance	2	13, 11
6	41	M	Common	hand	5	Drop out	-	-
7	58	F	Plantar	foot	3	Complete clearance	1	16
8	44	M	Plantar	foot	4	Complete clearance	1	15
9	42	M	Palmar	hand	5	Complete clearance	1	19
			Common	finger	2	Complete clearance	1	16
10	53	F	Common	hand	4	Partial response	3	16, 17, 15
			Palmar	hand	3	Complete clearance	1	15
11	45	M	Common	hand	3	Complete clearance	1	14
			Common	hand	3	Complete clearance	1	14
			Common	hand	3	Complete clearance	1	15
12	19	F	Plantar	foot	3	Drop out		

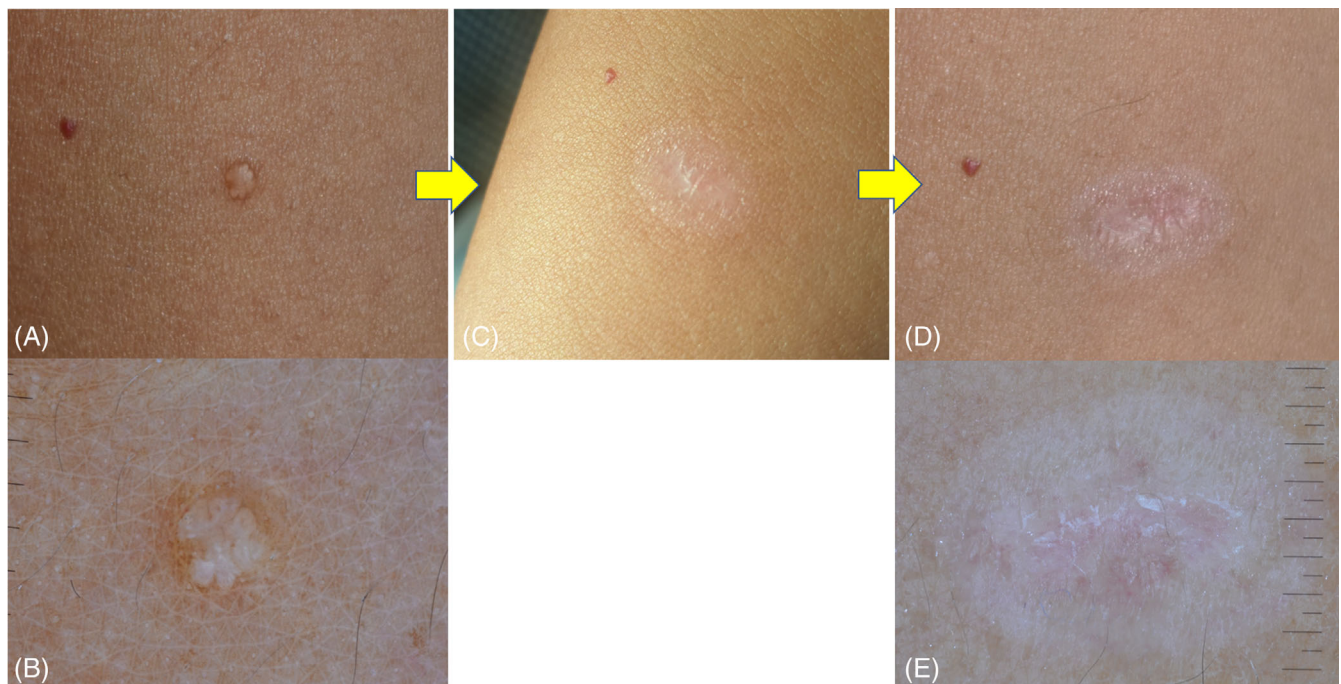


FIGURE 2 Patient 4: common cutaneous wart of the leg treated with one application of the prescription-free cryogenic pen. (A, B) Baseline face-to-face visit; clinical (A) and dermoscopic (B) aspect. (C) Clinical photo sent by the patient via WhatsApp after 3 weeks showing complete clearing. (D, E) Final face-to-face visit after 4 weeks from baseline showing both clinical (D) and dermoscopic (E) clearing, with residual post-inflammatory hypopigmentation.

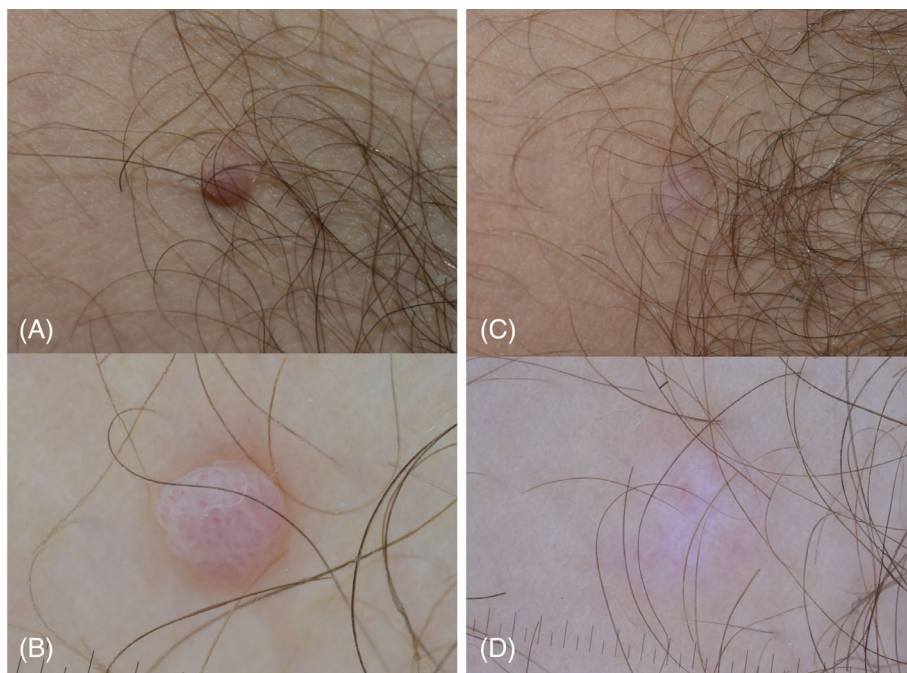


FIGURE 3 Patient 1: common cutaneous wart of the trunk treated with one application of the prescription-free cryogenic pen. (A, B) baseline face-to-face visit; clinical (A) and dermoscopic (B) aspect. (C, D) final face-to-face visit after 2 weeks showing clinical (C) and dermoscopic (D) clearing.

in the formation of a crust that fell on average after 14.5 days (range: 9–18).

As regards to adverse events, all patients reported superficial pain during the sessions and blistering and burning sensation in the few days following treatment. Residual erythema was observed in 12 lesions and transitory postinflammatory hypopigmentation in 6.

All patients reported that the device was simple to use and were satisfied with the treatment schedule.

4 | DISCUSSION

Teledermatology uses telecommunication to transmit medical information to a dermatologist by different modalities, including photographic images or live video conferencing.² During the present COVID-19 pandemic, teledermatology has demonstrated to be a safe and effective substitute to face-to-face visit for the remote assessment and management of many office dermatoses, including follow-up.¹⁻⁵

Cryotherapy represents one of the most common treatments for CWs.⁶ As very low surface temperatures are generally obtained with common devices (-196°C for liquid nitrogen), it is traditionally performed by clinicians. Some prescription-free cryogenic devices for home treatment, that do not allow very low temperatures, are available for patient's self-use.⁷ The device used in the present trial is based on the use of nitrous oxide liquid that allows a temperature of -80°C at the level of the applicator tip composed of polyurethane foam. In a previous study evaluating this device in which the applications were performed by the physicians, a total clearance was observed in 70.7% of 58 subjects with common (n. 29) or plantar (n. 29) warts after 1 (29.3%), 2 (24.1%), or 3 (17.2%) applications.⁷

In this study, complete clinical and dermoscopic clearance was obtained in 80% of lesions. Compared to the previous study, a higher percentage of clearance was seen, probably due to the lower number of plantar warts (25% vs. 50%), that are traditionally more difficult and resistant to treat. Moreover, in our experience, 1 application was effective in 70% of cases. The adverse events observed during treatment were comparable to those normally observed with cryotherapy of CWs.

From our results some considerations can be made: although limited to 20 CWs, the home device has demonstrated to be safe and effective. Initial face-to-face consultation was important for several reasons: to confirm the diagnosis using dermoscopy⁸⁻⁹ by excluding similar skin growth which show a distinct pattern (i.e., molluscum contagiosum, xanthogranuloma, skin tag, milium, callus, dermal nevus, seborrheic keratosis, and basal cell carcinoma); to establish the eligibility for home treatment by excluding other types of warts (plane, digitate, etc.) or anatomical site for which the treatment is not recommended; to discuss with the patient the most practical photo exchange modality. Importantly, home treatment and teledermatology follow up was able to limit the face-to-face consultations to baseline (for diagnosis confirmation), and to study end (for clinical and dermoscopic verification of CWS complete clearing).

In our opinion, home treatment of CWs is an interesting approach that deserves attention especially in modern times as it may reduce the number of visits being cost effective and well received by the patients also in terms of workday loss and adjunctive costs. However, the face-to-face visit we suggest to be performed by a skin specialist either to avoid inappropriate treatment or undesired side effects from unnecessary prolonged use, whereas the final check may be averted if the teledermatology images sent are enough convincing for disease clearing. Future studies on larger number of patients are advisable in order to provide additional information regarding the higher rate of

treatment response in term of type of warts (common, palmar, or plantar) and/or localization.

In conclusion, home treatment of CWs with the cryogenic pen, that should be always preceded by dermatologist diagnosis and prescription, is safe and effective, especially if combined with face-to-face and teledermatology consultations, pointing out its important role during pandemic times or in any other environmental limitations that may impair the access to medical care services. The combination of face-to-face consultations for initial and final visits and teledermatology during the treatment phase could represent a model for other dermatologic conditions as well (e.g. acne, rosacea, psoriasis, atopic eczema etc.).

ACKNOWLEDGMENT

Open Access Funding provided by Università degli Studi di Catania within the CRUI-CARE Agreement. [Correction added on May 20, 2022, after first online publication: CRUI funding statement has been added.]

CONFLICT OF INTEREST

The author declares that there is no conflict of interest.

AUTHOR CONTRIBUTIONS

The following authors have made substantial contributions to: *Conception and design, acquisition, analysis, and interpretation of data*: Giuseppe Micali, Federica Dall'Oglio, Anna Elisa Verzi, Helga Platania, Francesco Lacarrubba. *Manuscript drafting and revising*: Giuseppe Micali, Federica Dall'Oglio, Anna Elisa Verzi, Helga Platania, Francesco Lacarrubba. *Final approval of the version to be published*: Giuseppe Micali, Federica Dall'Oglio, Anna Elisa Verzi, Helga Platania, Francesco Lacarrubba.

DATA AVAILABILITY STATEMENT

The data that support the findings of this study are available from the corresponding author upon reasonable request.

ORCID

Giuseppe Micali  <https://orcid.org/0000-0002-5157-3939>

REFERENCES

1. Villani A, Megna M, Scalvenzi M, Fabbrocini G, Ruggiero A. Tele-dermatology and chronic skin diseases: real life experience in a Southern Italian Dermatologic Centre. *Dermatol Ther*. 2020;33(6):e13839.
2. Mostafa PIN, Hegazy AA. Dermatological consultations in the COVID-19 era: is teledermatology the key to social distancing? An Egyptian experience. *J Dermatolog Treat*. 2020;7:1-6.
3. Loh CH, Chong Tam SY, Oh CC. Teledermatology in the COVID-19 pandemic: a systematic review. *JAAD Int*. 2021;5:54-64.
4. Villani A, Scalvenzi M, Fabbrocini G. Teledermatology: a useful tool to fight COVID-19. *J Dermatolog Treat*. 2020;31(4):325.
5. Pahalyants V, Murphy WS, Gunasekera NS, Das S, Hawryluk EB, Kroshinsky D. Evaluation of electronic consults for outpatient pediatric patients with dermatologic complaints. *Pediatr Dermatol*. 2021;38(5):1210-1218.
6. Micali G, Dall'Oglio F, Nasca MR, Tedeschi A. management of cutaneous warts: an evidence-based approach. *Am J Clin Dermatol*. 2004;5:311-317.
7. Walczuk I, Eertmans F, Rossel B, et al. Efficacy and safety of three cryotherapy devices for wart treatment: a randomized, controlled, investigator-blinded, comparative study. *Dermatol Ther (Heidelb)*. 2018;8(2):203-216.
8. Lacarrubba F, Verzi AE, Dinotta F, Scavo S, Micali G. Dermatoscopy in inflammatory and infectious skin disorders. *G Ital Dermatol Venereol*. 2015;150(5):521-531.
9. Verzi AE, Lacarrubba F, Dinotta F, Micali G. Dermatoscopy of parasitic and infectious disorders. *Dermatol Clin*. 2018;36(4):349-358.

How to cite this article: Micali G, Dall'Oglio F, Verzi AE, Platania H, Lacarrubba F. Home treatment of single cutaneous warts combining face-to-face and teledermatology consultation: A new perspective. *Dermatologic Therapy*. 2022; 35(7):e15528. doi:10.1111/dth.15528