

# Intraoperative Magnetic Resonance Imaging for Cranial and Spinal Cases Using Preexisting “C” Shaped Three Side Open 0.2 Tesla Magnetic Resonance Imaging

## Abstract

**Background:** The existing Intraoperative MRI (IMRI) of developed countries is too costly to be affordable in any developing country and out of the reach of common and poor people of developing country at remote areas. We have used the pre-existing (refurbished) 3 side open “C” shaped 0.2 Tesla MRI for IMRI in a very remote area. **Materials and Methods:** In this technique the 0.2 Tesla MRI and the operating theatre were merged. MRI table was used as an operation table. We have operated 36 cases via IMRI from November 2005 to till date. First case operated was on 13<sup>th</sup> nov 2005. **Results:** Low (0.2) Tesla open setup costs very low (around Rs 40 lakhs) so highly affordable to management and thus to patients, used for diagnostic and therapeutic purposes both, the equipments like Nitrous, oxygen and suction is outside the MRI room so no noise inside operative room, positioning the patient didn't take much time due to manual adjustments, no special training to nurses and technicians required because of low (0.2) Tesla power of magnet and same instruments and techniques, sequencing took only 1.31 mints per sequence and re registration is not required since we always note down the two orthogonal axis in x and y axis in preoperative imaging and we were able to operate on posterior fossa tumors as well because of no head fixation except with leucoplast strap. Moreover the images we got intraoperative are highly acceptable. **Conclusion:** Three side open 0.2 Tesla MRI system, if used for intraoperative guidance, is highly affordable and overcomes the limitations of western setup of IMRI. Postoperative MRI images were highly acceptable and also highly affordable too.

**Keywords:** *Intraoperative magnetic resonance imaging, neuronavigation, three side open 0.2 Tesla magnetic resonance imaging system*

## Introduction

Understanding of operative gliomas has undergone a giant stride in past decades, so as the treatment from simple unaided naked eye resection to intraoperative magnetic resonance imaging (IMRI), intraoperative radiotherapy in glioblastoma multiforme,<sup>[1]</sup> or Advanced Multimodality Image Guided Operating suite, or the use of Raman effect<sup>[2]</sup> for brain gliomas resection. This can only be eulogized and pertinent, if the postoperative magnetic resonance imaging (MRI) shows very minimal margin of glioma tissue which can be safely destroyed by radiotherapy with no neurological deficit so that the therapeutic advantage is maximized. The existing IMRI of developed countries is too costly to be affordable in any developing country. The use of the first IMRI 1.5 Tesla started in 1995<sup>[3]</sup> with the so-called “double

doughnut” design, which was dedicated to use in the operating room but costly and out of the reach of common and poor people of developing country at remote areas.

We have used the preexisting (refurbished) three side open “C” shaped 0.2 Tesla MRI for IMRI in a very remote area (at rural areas of the India). In this technique, the MRI and the operating theater were merged. MRI table was used as an operation table. With this technique, the confidence of the neurosurgeon was greatly raised, so the time of operation is reduced. As a result, the surgical goal of complete or optimal resection can be achieved without any guesswork. Ultimately, what this means for the glioma patient is increased likelihood of longer survival brought about by a more thorough tumor resection in an affordable manner.

This is an open access article distributed under the terms of the Creative Commons Attribution-NonCommercial-ShareAlike 3.0 License, which allows others to remix, tweak, and build upon the work non-commercially, as long as the author is credited and the new creations are licensed under the identical terms.

For reprints contact: reprints@medknow.com

**How to cite this article:** Tewari VK, Tripathi R, Aggarwal S, Hussain M, Das Gupta HK. Intraoperative magnetic resonance imaging for cranial and spinal cases using preexisting “C” shaped three side open 0.2 tesla magnetic resonance imaging. *Asian J Neurosurg* 2017;12:691-4.

**Vinod Kumar  
Tewari,  
Ravindra Tripathi<sup>1</sup>,  
Subodh Aggarwal<sup>2</sup>,  
Mazhar Hussain<sup>3</sup>,  
Hari Kishan Das  
Gupta<sup>4</sup>**

*Departments of Neurosurgery,  
<sup>4</sup>Urology, Neuro Center,  
<sup>1</sup>Radiodiagnosis, MVT  
Diagnostics, <sup>2</sup>Anesthesia,  
Vivekanand Hospital,  
<sup>3</sup>Neurosurgery, Sahara Hospital,  
Lucknow, Uttar Pradesh, India*

**Address for correspondence:**  
Dr. Vinod Kumar Tewari,  
Neuro Center, PSS Complex,  
Vishal Khand 3,  
Gomti Nagar,  
Lucknow - 226 010,  
Uttar Pradesh, India.  
E-mail: drvinodtewari@gmail.  
com

### Access this article online

**Website:** www.asianjns.org

**DOI:** 10.4103/1793-5482.181144

### Quick Response Code:



## Materials and Methods

This IMRI system is a refurbished three side open “C” shaped 0.2 Tesla (SIEMENS MAGNETOM). Furthermore, increasing demand for more Tesla MRI (in the metropolitan cities of India and developed countries at abroad) for diagnostic use made 0.2 Tesla open MRI available with the dealers in a very low cost. Furthermore, this MRI can be used as diagnostic and therapeutic way according to our need. One door is attached to standard operation theater for the operation purpose (for brain and spine cases both), and the other door is attached to the diagnostic gallery from where the patients can enter for routine diagnostic study [Figure 1].

This IMRI was sterilized in the same way as the normal neurosurgical operation theater with formalin the night before surgery. The head coil was sterilized by using formalin tablets.

The table of MRI is used as an operating table along with two orthogonal axes. The echo planar imaging (EPI) center is the center point where the magnetic effect is maximum under the magnet. A patient was taken the P3 level (farthest) and as and when we require MRI to be done; then, the table can slide to P1 level (nearest). The oxygen and nitrous cylinder with suction machine were kept outside the MRI room in the adjacent operation theater room, and their connecting tubes were taken in MRI cabinet room via a vent. The small handy portable Boyle’s anesthesia trolley was taken inside the MRI room with a small monitor. Handy portable pulse oximeter and BP instrument are used separately. Anesthesia was given in the MRI room on the MRI table.

Operative instruments were the same as for nonIMRI cases. Thus, 0.2 Tesla IMRI is beneficial as compared to 3.0 Tesla IMRI.

Scout MRI with contrast was done at P1 level preoperatively. We noted X and Y co-ordinates of MRI table during the scout film, which is always used in every re-examination, to avoid doing scout films again and again and thus decreasing the time of operation.

General anesthesia was given at P3 level, and skin marking was given with the help of MRI contrast guidance. Craniotomy flap or the laminectomy was done, and the dura opened in the similar fashion by the same instruments as for the nonIMRI case. Rubber bands made from the gloves were used, where ever retraction was needed and stitched to draping. Corticectomy is planned after the T1 contrast image to localize and minimize the cortical resection. From P3 to P1 and vice versa, the patient was taken in multiple session to excise the tumor to around 0.5 mm of margin for radiotherapy<sup>[1]</sup> according to T1 contrast axial, coronal, and sagittal views, so that the resection is optimized and maximized. Immediate preclosure hematoma and edemas can be differentiated and cared for it.

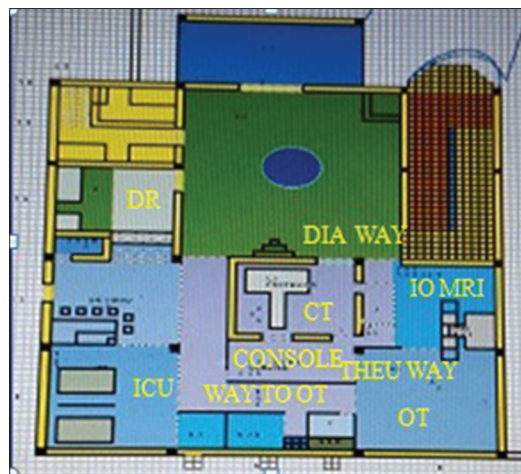

Figure 1: Setup of intraoperative magnetic resonance imaging, operation theater, computed tomography scan, and Intensive Care Unit

Neuronavigation system, 5-aminolevulinic acid, or microscope have not been used because we were confident enough after seeing the initial results of final closure of MRI. The patients head were not fixed by any device except fixed at the ends of MRI table itself in the desired position by simple leucoplast tape.

## Results

We have operated 36 cases via IMRI from November 2005 to until date. The first case operated was on the 13<sup>th</sup> November, 2005 [Figure 2].

### Surgery for cranial lesions

Brain tumors = 22 cases (left frontal glioblastoma multiforme [GBM] = 5 cases [Figure 3], right frontal convexity GBM = 3 cases, right parietal anaplastic astrocytoma Grade II = 5 cases, left parietal GBM = 5 cases, cerebellar astrocytoma = 4 cases), and ventricular peritoneal shunt placement = 1 case.

### Surgery for spinal lesions

Sacral spinal tumor = 1 case, spinal syringomyelia = 1 case, spinal conus ependymoma = 1 case, and thoracic intramedullary tumor = 10 cases.

## Discussion

The disadvantage of 1.5 Tesla IMRI mainly was economically unaffordable to the general public, and also the setup is unaffordable to the neurosurgeon and management of the hospital. Hence in developing countries such as India, the scientific research is not in the reach of poor people or in general public sector hospitals where money is the main hindrance. Furthermore, the brunt of incompleteness of surgery due to unavailability of IMRI falls on the shoulder of a neurosurgeon. Taking all these factors, it was decided to use the refurbished three sided open “C” shaped 0.2 Tesla MR system which can be used both as a diagnostic

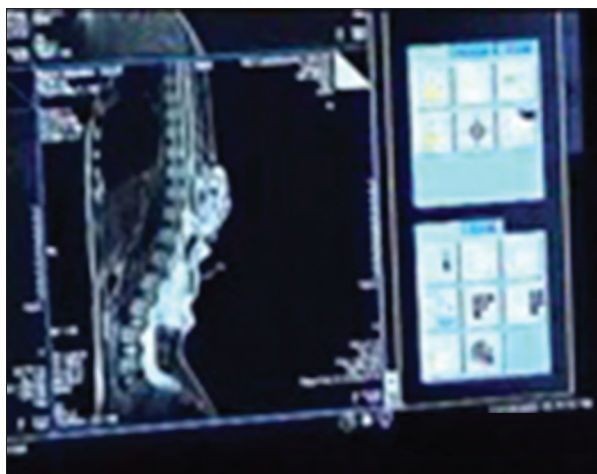


Figure 2: The first operation done on the 13<sup>th</sup> November, 2005

and therapeutic purpose in a cost-effective manner. Furthermore, anesthesia monitoring of the patient from inside the operating room should be very convenient to anesthetist and neurosurgeon. The position of the patient did not take much time as the area was open and not producing many restrictions even when in the EPI center in MRI. The nursing staff and technicians had not to be trained much on the initial equipment being used because the instruments and the techniques were the same. Subsequent imaging in intraoperative duration was facilitated because we noted the two orthogonal axes that are X and Y axis of the table while doing scout films, so it just took average 1.31 min. Furthermore, if we want to take more images, then the other sequences were performed saving the intraoperative time. We specifically fixed to T1 contrast images for the completion of surgery, since we have seen that the information we gather from these T1 contrast suffices in most cases. All other sequences were completed at the time of closure. Since we did not use any frame for head fixation, we were able to operate on posterior fossa tumors as well. The sitting position is not possible. The various brain and spinal cases were operated via this arrangement with great ease. Furthermore from patients' affordability point of view, we charge only Rs, 5000.00 extra to other operative expenses. The various postoperative T1 contrast MRI final closure images shown here were very acceptable to such an extent that there is hardly any residual tumor left.

Advantages over western setups:

- Low (0.2) Tesla open setup costs very low (around Rs. 40 lakhs) so highly affordable to management and thus to patients as compared to 1.5 or 3.0 Tesla IMRI setup (Rs. 15 crores)
- Low (0.2) Tesla open setup was used for diagnostic and therapeutic purposes both whereas 1.5 or 3.0 Tesla IMRI is mostly used for therapeutic purposes only

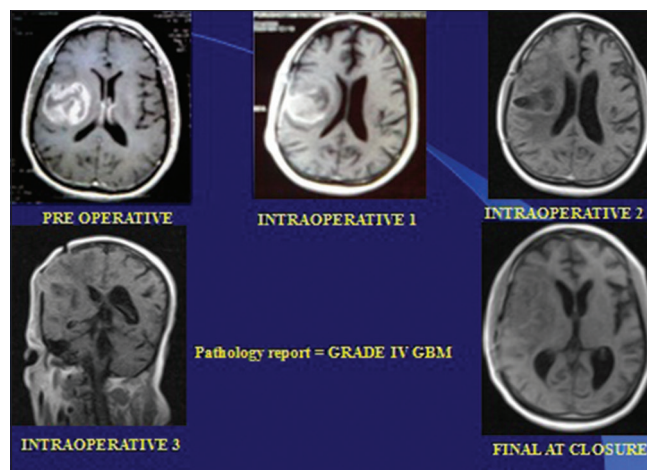


Figure 3: Brain first case (left frontal glioblastoma multiforme)

- Low operative costs (around Rs. 5000) so highly affordable to poor people
- Anesthesia is given within the MRI room on MRI table which is manually adjusted from P1 to P3 level so saving much operative time
- Portable Boyle's trolley is very cheap (around Rs. 10,000)
- All the equipment such as nitrous, oxygen, and suction are outside the MRI room so no noise inside the operative room
- Positioning the patient, also took some time, as the area appeared to be restrictive in 1.5 or 3.0 Tesla IMRI closed type of setup<sup>[4]</sup> but in low (0.2) Tesla open setup due to open type this problem is solved to a much extent
- The nursing staff and technicians had to be trained on the initial equipment being used in 1.5 or 3.0 Tesla IMRI,<sup>[4]</sup> but in our setup no special training required because of low (0.2) Tesla power of magnet and same instruments and techniques
- Special nonmagnetic instruments required for the 1.5 or 3.0 Tesla IMRI setup,<sup>[4]</sup> but in our system same neurosurgical equipments required because of low (0.2) Tesla power, and the operation is done in P3 level where magnetic lines hardly cause any deflection of normal equipment
- 1.5 or 3.0 Tesla IMRI setup uses 5–8 min<sup>[4]</sup> in re-registering and then sequencing but in low (0.2) Tesla open setup it is just 1.31 min/sequence and re-registration is not required since we always note down the two orthogonal axes in X and Y axis in preoperative imaging
- The disadvantages with the 1.5 or 3.0 Tesla IMRI setup were that the integrated head fixation device cum MRI coil restricts all types of patient positioning, making it impossible for occipital and posterior fossa lesions<sup>[4]</sup> but with low (0.2) Tesla open setup we were able to operate on posterior fossa tumors as well because of no head fixation except with leucoplast strap.

Disadvantages specifically encountered were:

- Images are of inferior quality as compared to 1.5 or 3.0 Tesla IMRI but better than intraoperative ultrasound in taking decision for completeness of resection
- Functional MRI cannot be done due to low (0.2) Tesla
- Batteries of finger pulse oximeter and laryngoscopes were to be changed in nearly every case (may be because of the fact that the magnetic field nullifies the polarity of batteries)
- Re-registration from scout films required many a times if the co-ordinates of X and Y axis is not noted properly
- Diagnostic MRIs at that moment of time is to be postponed.

#### **Videos at YouTube URLs intraoperative magnetic resonance imaging**

- [https://www.youtube.com/watch?feature=player\\_detailpage&v=7hf74\\_GujN8](https://www.youtube.com/watch?feature=player_detailpage&v=7hf74_GujN8)
- [https://www.youtube.com/watch?feature=player\\_detailpage&v=THETr3Xnhxc](https://www.youtube.com/watch?feature=player_detailpage&v=THETr3Xnhxc)
- [https://www.youtube.com/watch?feature=player\\_detailpage&v=iIUIi9fYAHo](https://www.youtube.com/watch?feature=player_detailpage&v=iIUIi9fYAHo).

#### **Conclusion**

This preliminary data from a primary neurosurgical care center from a developing country shows that the use of 0.2 Tesla open refurbished MRI is quiet useful in brain and spinal surgeries. This IMRI system at a very remote

area is highly affordable for the neurosurgeons and for the patients too in comparison to 1.5 or 3.0 Tesla IMRI setups. Low (0.2) Tesla open IMRI setups were used as diagnostic as well as therapeutic purposes.

#### **Financial support and sponsorship**

Nil.

#### **Conflicts of interest**

There are no conflicts of interest.

#### **References**

1. Giordano FA, Brehmer S, Abo-Madyan Y, Welzel G, Sperk E, Keller A, *et al.* INTRAGO: Intraoperative radiotherapy in glioblastoma multiforme – A phase I/II dose escalation study. *BMC Cancer* 2014;14:992.
2. Karabeber H, Huang R, Iacono P, Samii JM, Pitter K, Holland EC, *et al.* Guiding brain tumor resection using surface-enhanced Raman scattering nanoparticles and a hand-held Raman scanner. *ACS Nano* 2014;8:9755-66.
3. Nimsky C, Gandslandt O, Keller VB, Anker L, Romstick J, Fahlbusch R. First clinical results of intraoperative high-field magnetic resonance imaging supported by neuronavigation. In: Lemke H, Vannier M, Inamura K, Farman A, Doi K, Reiber J, editors. *CARS Computer Assisted Radiology and Surgery – Proceedings of the 17<sup>th</sup> International Congress and Exhibition*. Amsterdam: Elsevier; 2003. p. 601-6.
4. Jha AN, Rahmathulla G, Vaishya S, Walia BS, Gupta V. Intraoperative high field magnetic resonance imaging in neurosurgery: Our initial experience with the brain suite. *Neurol India* 2007;55:169-72.