

CASE REPORT

Giant left-sided inguinoscrotal hernia containing the cecum and appendix (giant left-sided Amyand's hernia)

Kenichi Maeda, Katsuyuki Kunieda, Masahiko Kawai, Narutoshi Nagao, Chihiro Tanaka, Yasuhisa Oida, Shigeru Kiyama & Masahiro Tawada

Department of Surgery, Gifu Prefectural General Medical Center, Gifu, 500-8717, Japan

Correspondence

Kenichi Maeda, Department of Surgery, Gifu Prefectural General Medical Center, 4-6-1, Noisshiki, Gifu-shi, Gifu 500-8717 Japan. Tel: +81-58-246-1111; Fax: +81-58-248-3805; E-mail: maeken77@hotmail.com

Funding Information

No funding information provided.

Received: 20 February 2014; Revised: 3 June 2014; Accepted: 20 February 2014

Clinical Case Reports 2014; 2(6): 254–257

doi: 10.1002/ccr3.104

Key Clinical Message

The present case involved a 62-year-old male with a large left-sided inguinoscrotal hernia. A CT scan and a clinical examination led to a diagnosis of a giant left-sided Amyand's hernia. The hernia was repaired using the ULTRAPRO Hernia System (UHS), and the patient exhibited an uneventful postoperative course.

Keywords

Amyand's hernia, giant inguinoscrotal hernia, ULTRAPRO Hernia system.

Case Report

A 62-year-old male visited our hospital due to a left inguinoscrotal hernia, which had been gradually increasing in size for a few years. In addition to increasing in size, the hernia had also become incarcerated within the past 10 months, and while it was reducible it was causing the patient considerable discomfort, especially during walking and standing.

A large left-sided inguinoscrotal hernia, which extended to the midpoint of the inner thigh while the patient was standing, was detected during a clinical examination (Fig. 1). The scrotal skin did not display any signs of cellulitis or ulceration, nor did the skin over the hernia exhibit tenderness. However, bowel sounds were heard in the scrotum. A right-sided inguinal hernia, which did not extend to the scrotum, was also detected. In addition, the left testicle was not palpable.

Dislocation of the ileum, appendix, cecum, and ascending colon into the left-sided inguinoscrotal hernial sac was depicted by computed tomography (Fig. 2).

Under general endotracheal anesthesia, a medial incision was made in the lower abdomen, and the ileum, appendix, cecum, and ascending colon were reduced into

the peritoneal cavity. Then, bilateral standard oblique inguinal incisions were made, before the hernial sac was excised. Next, a large Ultrapro hernia system (UHSL) was used to reinforce the bilateral inguinal regions (Fig. 3). Finally, the abdominal incision was closed without tension (Fig. 4).

Monitoring of the patient's airway pressure determined that compartment-enlarging procedures were not necessary.

The patient exhibited an uneventful postoperative course. Specifically, he was extubated during the immediate postoperative period and did not require any mechanical ventilatory support. As a result, he was discharged on the sixth day after surgery.

Discussion

Amyand's hernia, which is a rare condition, involves the entrapment of the appendix within an inguinal hernia. The incidence of a normal appendix becoming trapped within an inguinal hernial sac is about 1% [1,2]. Amyand's hernia predominantly occurs on the right side [3]. This is probably because right-sided inguinal hernias are more common than left-sided hernias, and the appendix

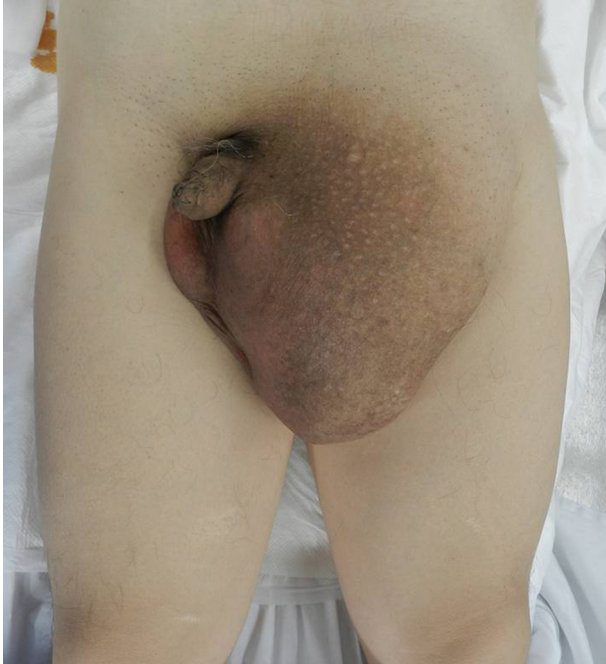

Figure 1. Preoperative image depicting a giant left-sided inguinoscrotal hernia.

is normally found on the right side. Left-sided Amyand's hernias are rare, and it has been suggested that they could be associated with a mobile cecum, situs inversus, or

intestinal malrotation [4]. The present case involved a mobile cecum, but not situs inversus or malrotation of the gut. Regarding appendectomy, the indications for the procedure in cases of Amyand's hernia depend on the mode of presentation. In cases involving patients with normal appendices, appendectomy is not necessary. On the other hand, appendectomy is required in cases involving acute appendicitis [5]. The presence of pus and perforation of the appendix are absolute contraindications for mesh-based hernia repair procedures [6]. Appendectomy was not performed in the present case because the patient's appendix was not inflamed, and the procedure could have resulted in a prosthetic infection.

Hernias that extend below the midpoint of the inner thigh while the patient is standing are known as giant inguinoscrotal hernias [7]. Such hernias are rare and are usually only seen in cases in which the patient has ignored the problem for years.

The forced reduction of hernial contents into the peritoneal cavity could affect the patient's intra-abdominal and/or intra-thoracic pressure levels (i.e., induce abdominal compartment syndrome), which might increase the risk of severe respiratory or cardiac failure and result in a worsening of morbidity and mortality rates [8]. In addition, closing the abdominal wall under tension has been linked with a greater risk of wound breakdown; i.e., 30% of patients who undergo such procedures suffer from hernia recurrence and/or wound dehiscence [9].

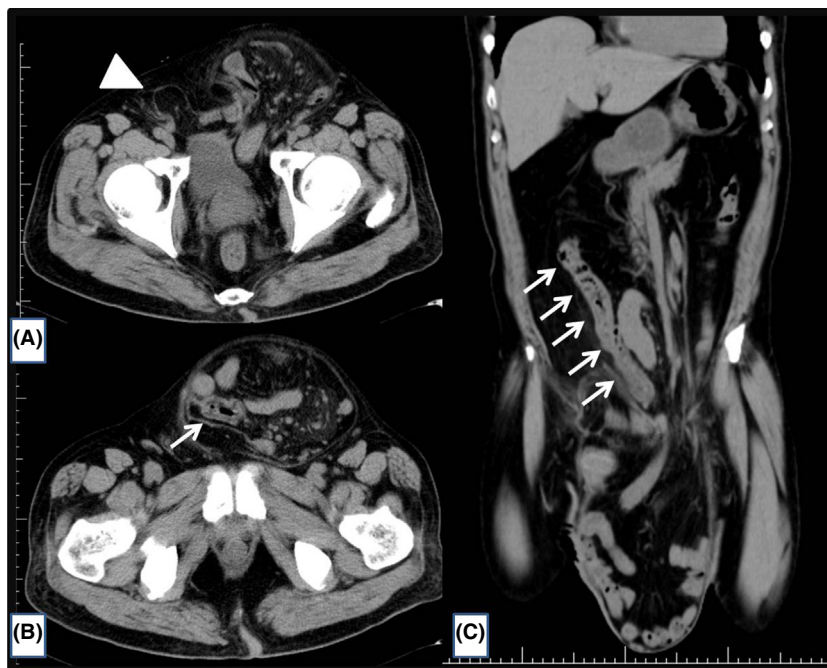


Figure 2. A computed tomography scan depicting dislocation of the ileum, appendix, cecum, and ascending colon (arrows) into a left-sided inguinoscrotal hernial sac, and a right-sided inguinal hernia (arrowhead).

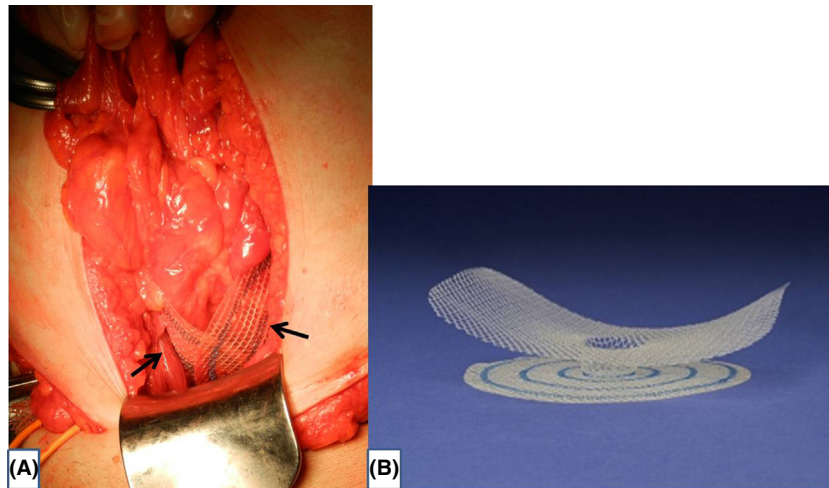


Figure 3. (A) Intraoperative image. The UHS underlays (arrows) were installed into the bilateral preperitoneal spaces and (B) UHS. UHS, Ultrapro hernia system.

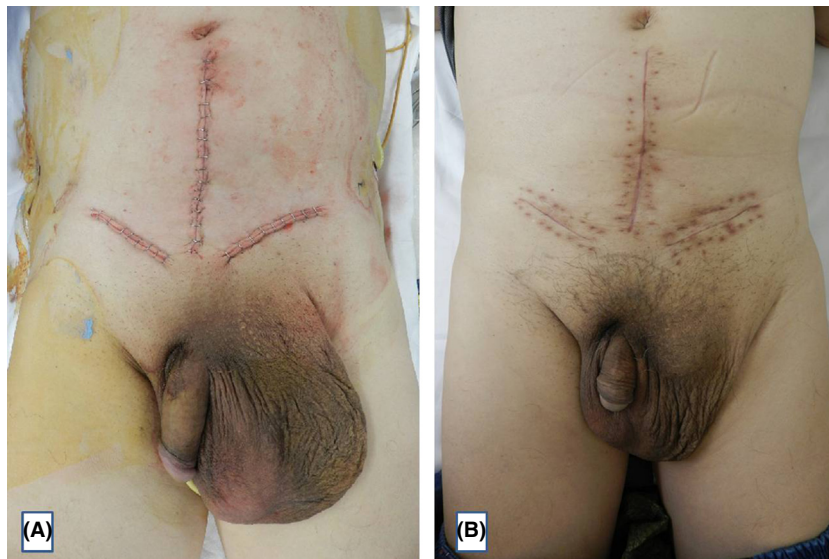

Figure 4. Photographs taken immediately (A) and 1 month (B) after surgery.

Concerning loss of domain, various methods for combatting this issue based on the debulking of the abdominal contents and the progressive distention of the abdominal wall have been described.

As for abdominal wall distention, older techniques such as phrenicectomy [10], iatrogenic incisional hernia [11], and musculoskeletal flaps [12] are no longer used [13]. Goni Moreno was the first to describe the use of preoperative pneumoperitoneum preparation (PPP) during the treatment of large ventral hernias [14], and the technique has subsequently been successfully employed to treat inguinal hernias [15]. However, it has been reported to cause thin hernial sacs (instead of the abdominal cavity)

to expand [16]. However, a number of techniques for separating the components of the abdominal wall have been reported and have produced good results [8].

Regarding the debulking of the abdominal contents, this method, which is usually applied to the small intestine, greater omentum, or colon, results in the acquisition of a sufficiently spacious abdominal cavity. However, previous studies have found that this approach is associated with a greater risk of complications, e.g., prosthetic infection or anastomotic leakage [17, 18].

In our case, monitoring of the patient's airway pressure determined that compartment-enlarging procedures were not required.

Repairing giant hernias using conventional methods is associated with a high recurrence rate [19]. Thus, we employed the UHS, which strengthens the posterior wall of the inguinal canal in two ways. Initially, the floor of the inguinal canal is supported from the posterior side by placing an underlay under the transversalis fascia, as is performed in laparoscopic repair, and then the anterior side of the canal is supported by installing an overlay, as is performed in Lichtenstein repair.

Instead of using the conventional method, giant hernias should be repaired with synthetic mesh due to the high recurrence rate associated with the former approach. Thus, appendectomy should not be performed in cases in which the appendix is not inflamed.

Conflict of Interest

None declared.

References

1. Franko, J., I. Raftopoulos, and R. Sulkowski. 2002. A rare variation of Amyand's hernia. *Am. J. Gastroenterol.* 97:2684–2685.
2. House, M. G., S. B. Goldin, and H. Chen. 2001. Perforated Amyand's hernia. *South. Med. J.* 94:496–498.
3. Pellegrino, J. M., and S. D. Feldman. 1992. Case report: acute appendicitis in an inguinal hernia. *N. J. Med.* 89:225–226.
4. Breitenstein, S., C. Eisenbach, G. Wille, and M. Decurtins. 2005. Incarcerated vermiform appendix in a left-sided inguinal hernia. *Hernia* 9:100–102.
5. Franko, J., I. Raftopoulos, and R. Sulkowski. 2002. A rare variation of Amyand's hernia. *Am. J. Gastroenterol.* 97:2684–2685.
6. Hutchinson, R. 1993. Amyand's hernia. *J. R. Soc. Med.* 86:104–105.
7. Hodgkinson, D. J., and D. C. McIlrath. 1984. Scrotal reconstruction for giant inguinal hernias. *Surg. Clin. North Am.* 64:307–313.
8. Valliattu, A. J., and A. N. Kingsnorth. 2009. Single-stage repair of giant inguinoscrotal hernias using the abdominal wall compartment separation technique. *Hernia* 12:329–330.
9. Mehendale, F. V., K. O. Taams, and A. N. Kingsnorth. 2000. Repair of a giant inguinoscrotal hernia. *Br. J. Plast. Surg.* 53:525–529.
10. Touroff, A. S. 1954. Phrenicectomy as aid to repair of large abdominal hernias. *J. Am. Med. Assoc.* 154:330–332.
11. Ziffren, S. E., and N. A. Womack. 1950. An operative approach to the treatment of giant hernias. *Surg. Gynecol. Obstet.* 91:709–710.
12. Handelsman, J. C. 1959. A technique for increasing abdominal capacity in the repair of massive ventral hernia. *Surg. Gynecol. Obstet.* 108:751–752.
13. Tahir, M., F. U. Ahmed, and V. Senu. 2008. Giant inguinoscrotal hernia: case report and management principles. *Int. J. Surg.* 6:495–497.
14. Goni Moreno, I. G. 1978. The rational treatment of hernias and voluminous chronic eventrations: preparation with progressive pneumoperitoneum. Pp. 536–560 *in* L. M. Nyhus and R. E. Condon, eds. *Hernia*. 2nd ed.. JB Lippincott, Philadelphia, PA.
15. Connolly, D. P., and F. R. Perri. 1969. Giant hernias managed by pneumoperitoneum. *J. Am. Med. Assoc.* 9:71–74.
16. Kyle, S. M., M. J. Lovie, and C. S. Dowle. 1990. Massive inguinal hernia. *Br. J. Hosp. Med.* 43:383–384.
17. Monestiroli, U. M., A. Bondurri, F. Gandini, G. Lenna, S. Vellini, and P. Danelli. 2007. Giant inguinoscrotal hernia. *Tech. Coloproctol.* 11:283–284.
18. Weiss, C. L., M. Brauckhoff, and J. Steuber. 1997. Emergency management of monstrous inguinal hernia. *Zentralbl. Chir.* 122:931–933.
19. Stoppa, R. E. 1989. The treatment of complicated groin and incisional hernias. *World J. Surg.* 13:545–554.