

Perioperative complications in patients treated with posterior cervical fusion and bilateral cages

ABSTRACT

Context: Posterior cervical cages have recently become available as an alternative to lateral mass fixation in patients undergoing cervical spine surgery.

Aims: The purpose of this study was to quantify the perioperative complications associated with cervical decompression and fusion in patients treated with a posterior cervical fusion (PCF) and bilateral cages.

Settings and Design: A retrospective, multicenter review of prospectively collected data was performed at 11 US centers.

Subjects and Methods: The charts of 89 consecutive patients with cervical radiculopathy treated surgically at one level with PCF and cages were reviewed. Three cohorts of patients were included standalone primary PCF with cages, circumferential surgery, and patients with postanterior cervical discectomy and fusion pseudarthrosis. Follow-up evaluation included clinical status and pain scale (visual analog scale).

Statistical Analysis Used: The Wilcoxon test was used to test the differences for the data. The *P* level of 0.05 was considered significant.

Results: The mean follow-up interval was 7 months (range: 62 weeks - 2 years). The overall postsurgery complication rate was 4.3%. There were two patients with neurological complications (C5 palsy, spinal cord irritation). Two patients had postoperative complications after discharge including one with atrial fibrillation and one with a parietal stroke. After accounting for relatedness to the PCF, the overall complication rate was 3.4%. The average (median) hospital stay for all three groups was 29 h.

Conclusions: The results of our study show that PCF with cages can be considered a safe alternative for patients undergoing cervical spine surgery. The procedure has a favorable overall complication profile, short length of stay, and negligible blood loss.

Keywords: Cervical cage, cervical radiculopathy, cervical spondylosis, complications, posterior cervical fusion, pseudarthrosis


INTRODUCTION

Ongoing technological developments have given the surgeon, a wide armamentarium of options to treat cervical spine diseases. Facet distraction as a treatment for cervical spondylotic radiculopathy and myelopathy was described by Goel.^[1-4] (US Patent No. 9668783 B2 - Goel - Devices and method for spondylotic disease) Posterior cervical cages (Goel facet spacers) have recently become available as an alternative to lateral mass fixation (LMF) to achieve cervical fusion by a posterior surgical approach.^[5-7] Because of the wide variety of therapeutic options, it is important to understand the burden of current surgical procedures on the health-care system in terms of perioperative complications.

KRZYSZTOF B SIEMIONOW^{1,2}, PAWEŁ GŁOWKA^{1,2}, ROBERT J. BLOK³, MARK C. GILLESPIY⁴, MUKUND I. GUNDANNA⁵, WILLIAM D. SMITH⁶, ZESHAN HYDER⁷, BRUCE M. MCCORMACK⁸

¹Department of Orthopedic, University of Illinois at Chicago, Chicago, IL, ²Department of Orthopedic, Clark Memorial Hospital, Lafayette, ⁷Department of Orthopedic Spine Surgery, IN, ⁴Halifax Health Medical Center, Daytona Beach, FL, ⁵Brazos Spine Surgery, College Station, TX, ⁶Western Regional Center For Brain and Spine, Las Vegas, NV, ⁸Department of Neurosurgery, Neurospine Institute Medical Group, San Francisco, CA, USA, ²Department of Spine Disorders and Children Orthopaedics, University of Medical Sciences, Poznan, Poland

Address for correspondence: Dr. Krzysztof B Siemionow, Department of Orthopaedics, College of Medicine, 835 South Wolcott Avenue, Room E270, Chicago, Illinois 60612, USA. E-mail: siemiok@gmail.com

Access this article online	
Website: www.jcvjs.com	Quick Response Code 
DOI: 10.4103/jcvjs.JCVJS_61_17	

This is an open access article distributed under the terms of the Creative Commons Attribution-NonCommercial-ShareAlike 3.0 License, which allows others to remix, tweak, and build upon the work non-commercially, as long as the author is credited and the new creations are licensed under the identical terms.

For reprints contact: reprints@medknow.com

How to cite this article: Siemionow KB, Glowka P, Blok RJ, Gillespy MC, Gundanna MI, Smith WD, *et al.* Perioperative complications in patients treated with posterior cervical fusion and bilateral cages. J Craniovert Jun Spine 2017;8:342-9.

The purpose of this study was to quantify the adverse events associated with cervical decompression and fusion in patients with cervical radiculopathy treated with a posterior cervical fusion (PCF) and cages.

SUBJECTS AND METHODS

A retrospective study was undertaken at 11 centers in the US. The study was deemed exempt from the Institutional Review Board (IRB) review under 45CFR46.101 by an independent central IRB (Ethical and Independent Review Services, Corte Madera, CA, Protocol Number 15146-01). The central IRB approved that no informed consent was necessary due to the nature of the study being a retrospective chart review with minimal risk to patient safety. A medical chart review was performed to review consecutive patients with cervical spine surgery. The chart's data were collected by trained personnel at each center and case forms were reviewed by each investigator. All reviewed charts contained information about clinical complaints as well as pain assessment for the arm and neck through visual analog scale (VAS) for pain.^[8] Neck and arm pain associated with cervical radiculopathy were assessed before surgery and on the subsequent control visits at 2 weeks, 6 weeks, 6 months, 12 months, and 24 months. The VAS is an 11-point scale from 0 to 10, where 0 represents the absence of pain and 10 represents the worst pain imaginable by the patient.^[8]

All patients were treated surgically with PCF at one cervical level with cages (CAVUX Cervical Cage™ and DTRAX Spinal System®, Providence Medical Technology, Inc., Walnut Creek, CA, USA). There were 89 patients split into three cohorts. Group 1 was comprised of 46 patients who had PCF as a primary standalone treatment, Group 2 was comprised of 15 patients who underwent circumferential surgery (anterior cervical discectomy and fusion [ACDF] + PCF), and Group 3 was comprised of 28 pseudarthrosis patients with a history of ACDF who were treated with PCF [Figure 1].

The makeup of the 89 patients overall included 42 males and 47 females. Average age at the time of the surgery was 58.0 ± 12.0 years (standalone 59.8 ± 12.4 ; circumferential 64.3 ± 9.9 , and pseudarthrosis 51.7 ± 9.6). Diagnoses included degenerative disc disease ($n = 32$), cervical spondylosis with radiculopathy ($n = 56$), disc herniation with radiculopathy ($n = 7$), and pseudarthrosis ($n = 28$) [Figure 2]. Surgeries were performed at levels C3-T1 with the most common treated level being C5-C6 level – 41.6% of all [Figure 3]. Out of 89 patients, 41 of them were free of comorbidities – 46.1% [Figure 4].

Perioperative complications were divided into three main groups – neurological, vascular, and other. Perioperative

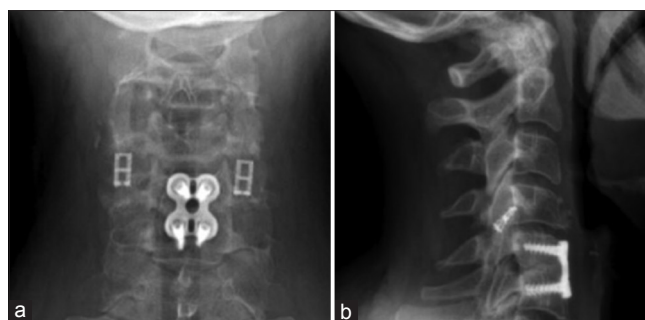


Figure 1: (a and b). Anteroposterior and lateral X-rays of a patient who underwent anterior cervical discectomy and fusion, which resulted in pseudarthrosis. The patient was revised with posterior cervical fusion with bilateral cages

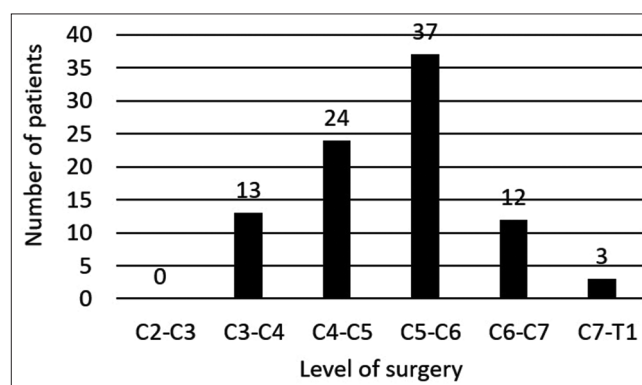


Figure 2: Level of surgery for each patient

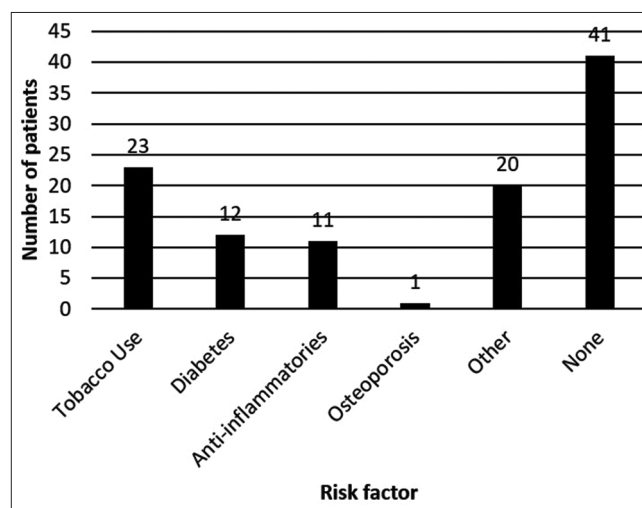


Figure 3: Comorbidities

period was defined as 30 days after surgery.^[9] Neurological complications were further subdivided as follows: dural tear, spinal cord, and peripheral nerve injury (postoperative radiculopathy).^[10] Vascular complications were divided into excessive bleeding and arterial/venous injury.^[10,11] The other complication group included epidural hematoma, dysphagia, dysphonia, wound infection, airway compromise, bone graft extrusion, and instrumentation failures.^[10] Follow-up

evaluation included clinical status and pain scale (VAS) The study protocol was approved by the scientific and ethical committees with which the authors are affiliated.

Statistical analysis

The data were analyzed using the Statistica software (StatSoft, I. N. C.). Normal distribution of data was assessed by use of the Shapiro–Wilk test. The Wilcoxon test was used to test the differences for the data. The *P* level of 0.05 was considered significant. A power of the Wilcoxon test was set at 0.95. Mean values, standard deviations, minimal and maximal values for VAS, and the difference between the VAS score at the baseline and the VAS score at subsequent visits were calculated.

Surgical technique

The procedure was performed under general anesthesia with the patient prone. The shoulders were strapped down with tape, and biplanar fluoroscopy was used to visualize the cervical spine. A Stainamnn pin was placed externally and

lateral to the patient's neck and lined up with the intended facet using lateral fluoroscopy to establish a cranial-caudal incision site and trajectory to the intended spinal level. The muscle and fascia reflected laterally off the spinous process. The instruments used for PCF were previously described by McCormack and Dhawan.^[12] The facet access tool was advanced through the incision in a slight medial-to-lateral trajectory into the intended facet joint. Blunt dissection was performed to expose the intended facet and adjacent lateral mass, which could be directly visualized. Lateral mass and medial lamina adjacent to the posterior facet were decorticated with a trephine decorticator. A guide tube was then placed to maintain facet distraction and serve as a working channel. Facet endplates were decorticated with rasps, and the implant was deployed and anchored into the facet with a bone screw.^[3,13] Local autograft bone was mixed with allograft in all cases. Bone was placed over the lateral mass decortication bed.

RESULTS

A total of 175 cervical cages were placed posteriorly in this study. The mean follow-up interval was 7 months (range: 2 weeks– 2 years) in all groups. All implants of the cervical cages were technically successful except for one surgery that had reported inability to implant a right-sided cage due to a fused facet at the C4-C5 level. There were no instrumentation malfunctions or aborted procedures. A summary of complications perioperative is reported in Table 1. There was one patient with neurological complications in the perioperative period. One patient in the pseudarthrosis group experienced spinal cord irritation from anterior approach. Symptoms resolved 6 months after surgery upon revision of the ACDF. None of the patients had vertebral artery injury or other vascular complications. There were no patients with cerebrospinal fluid leakage, wound infection, implant back-out, or reoperations during the perioperative period. The other complications reported in this study included two patients with complications in the standalone group of which one was a case of atrial fibrillation in the postanesthetic care unit and one was a

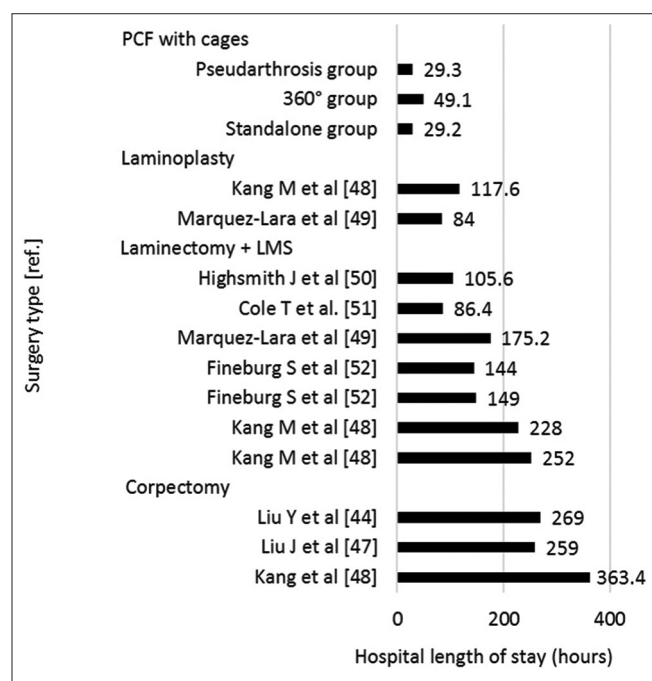


Figure 4: Length of stay

Table 1: Perioperative complications related to procedure or implanted cervical cage(s)

Complications related to procedure or implanted cervical cage(s)	Group 1: Standalone (n=46), n (%)	Group 2: Circumferential (n=15), n (%)	Group 3: Pseudarthrosis (n=28), n (%)	All Patients (n=89), n (%)
Overall complications (inclusive of ACDF and/or PCF)	3 (6.5)	0	1 (3.6)	4 (4.3)
Neurological complications	1 (2.2)	0	1 (3.6)	2 (2.2)
Vascular complications	0	0	0	0
Other complications	2 (4.3)	0	0	2 (2.2)
Overall complications related to posterior cervical fusion with cages	3 (6.5)	0	0	3 (3.4)

ACDF - Anterior cervical discectomy and fusion; PCF - Posterior cervical fusion

patient with a parietal stroke during procedure or recovery. The average (median) hospital stay for all three groups was 29 h (standalone 29.2 ± 22.2 h; circumferential 49.1 ± 33.7 h, and pseudarthrosis 29.3 ± 13.6 h).

Beyond the perioperative period, one patient in the standalone group had a C5 palsy deficit observed with symptoms 6 months after the PCF procedure at C4/C5, and one patient with pseudarthrosis was treated 12 months postoperatively for adjacent segment disease and a failed PCF. One patient in the circumferential treatment group died 3 months' postsurgery due to a pulmonary embolism. Other problems that did not have clear diagnosis during follow-up included diagnosis of carpal and cubital tunnel syndrome and degenerative disease of the shoulder.

Eighty-one patients complained on the neck pain before the surgery and identified pain on the VAS scale, 79 patients complained on the arm pain, and 68 complained on both neck and arm pain. The number of patients on the subsequent visits was different [Tables 2 and 3] in comparison to the number of patients undertaken surgery. The mean values, standard deviations, minimal and maximal values for VAS and for the deference between VAS on the baseline, and the VAS reporting on the subsequent visit were presented in Tables 2 and 3. The Wilcoxon test (with $P = 0.05$) revealed the significant difference between the VAS reported before surgery in comparison to the VAS reported on the control visit in 2 weeks, 6 weeks, 3 months, 6 months, and 12 months after surgery [Tables 4 and 5]. Twenty-four months after surgery, three patients' complaint on neck pain identified on the VAS scale at 3, 6, and 7 points. One of these patients did not feel improvement (VAS 7). Two of these patients noticed the improvement in terms of neck pain: 10 points at the beginning and 3 points at the follow-up end point, and 9 points at the beginning and 6 points at the follow-up end point. Twenty-four months after surgery, three patients' complaint on the arm pain identified on the VAS scale at 4, 5, and 6 points. One of these patients had 1-point improvement in VAS scale (6 points before surgery). Two patients had arm pain worsening: 3 and 4 points on the beginning and accordingly 4 and 6 points after 24 months.

DISCUSSION

In this retrospective multicenter study, we analyzed the perioperative clinical outcomes and complications associated with PCF with cage placement in 89 consecutive patients with cervical radiculopathy. The perioperative period, according to Campbell *et al.*, was defined as 30 days after the index surgery.^[8] The mean 7-month follow-up interval

Table 2: Calculation of the visual analog scale score for neck pain sample

VAS for neck pain	n	Mean±SD	Minimum	Maximum
BL	81	7.2±2.2	1	10
2 weeks	70	2.8±2.2	0	8
2-week ΔBL	67	-4.3±3.1	+2	-9
6 weeks	62	2.8±2.1	0	9
6-week ΔBL	59	-4.0±2.9	1	-9
3 months	57	2.1±2.1	0	10
3-month ΔBL	56	-4.7±2.9	1	-9
6 months	42	2.9±2.8	0	10
6-month ΔBL	41	-3.7±3.9	3	-10
12 months	32	1.9±2.8	0	10
12-month ΔBL	31	-5.0±3.4	2	-10
24 months	3	5.3±2.1	3	7
24-month ΔBL	3	-3.3±3.5	0	-7

BL - Baseline the day of surgery; 2 weeks - The control visit 2 weeks after index surgery; ΔBL - The difference between the VAS score at the baseline and the VAS score at subsequent visits; VAS - Visual analog scale; n - Sample size; SD - Standard deviation

Table 3: Calculation of the visual analog scale score for arm pain sample

VAS for arm pain	n	Mean±SD	Minimum	Maximum
BL	79	7.5±2.7	1	10
2 weeks	68	1.4±2.0	0	10
2-week ΔBL	66	-6.1±3.4	2	-10
6 weeks	62	1.2±2.0	0	8
6-week ΔBL	58	-6.4±3.7	2	-10
3 months	56	0.9±2.1	0	10
3-month ΔBL	55	-6.4±3.6	2	-10
6 months	41	1.6±2.8	0	9
6-month ΔBL	40	-5.8±4.4	1	-10
12 months	32	1.1±2.4	0	10
12-month ΔBL	31	-6.8±4.1	2	-10
24 months	3	5.0±1.0	4	6
24-month ΔBL	3	0.7±1.5	2	-1

BL - Baseline the day of surgery; 2 weeks - The control visit 2 weeks after index surgery; ΔBL - The difference between the VAS score at the baseline and the VAS score at subsequent visits. n - Sample size; SD - Standard deviation; VAS - Visual analog scale

was sufficient to perform the perioperative complications analysis. The overall postsurgery complication rate was found to be 4.3% (standalone 6.5%, circumferential 0.0%, and pseudarthrosis 3.4%) [Table 1]. After accounting for relatedness to the PCF aspects of the treatment, the overall complication rate was 3.4%.

Cervical spondylotic radiculopathy is commonly treated through the anterior approach to the cervical spine.^[14] Although this is widely considered to be a safe approach, the overall complication profile for ACDF/arthroplasty was reported to be 12.33% (range: 2.38%–32%).^[15-27] The majority of complications associated with anterior surgery are minor and self-limiting.^[27,28] Comparing the results from the current study

Table 4: Comparison of visual analog scale score for neck pain related to cervical radiculopathy reported by the patients before the index surgery and visual analog scale score for neck pain on the subsequent control visits

VAS for neck pain	2 weeks	6 weeks	3 months	6 months	12 months
<i>n</i>	61	58	54	38	28
Mean±SD	2.68±2.12	2.73±2.03	2.11±2.09	2.83±2.78	1.68±2.57
BL (mean±SD)	6.98±2.37	6.71±2.38	6.77±2.36	6.51±2.59	6.71±2.61
<i>P</i>	<0.0001*	<0.0001*	<0.0001*	<0.0001*	<0.0001*

**P*<0.5. *P* - Significance of the difference assessed by Wilcoxon's test; *n* - Number of valid samples; SD - Standard deviation; BL - Baseline; VAS - Visual analog scale

Table 5: Comparison of visual analog scale score for neck pain related to cervical radiculopathy reported by the patients before the index surgery and visual analog scale score for neck pain on the subsequent control visits

VAS for arm pain	2 weeks	6 weeks	3 months	6 months	12 months
<i>n</i>	61	55	53	39	31
Mean±SD	1.32±2.04	1.09±1.99	0.88±2.06	1.60±2.83	1.10±2.48
Baseline (mean±SD)	7.46±2.89	7.48±2.79	7.25±3.01	7.40±3.07	7.87±2.48
<i>P</i>	<0.0001*	<0.0001*	<0.0001*	<0.0001*	<0.0001*

**P*<0.5. *P* - Significance of the difference assessed by Wilcoxon's test. *n* - Number of valid samples; SD - Standard deviation; VAS - Visual analog scale

with data for other cervical procedures such as ACDF [Table 6] and posterior lateral mass screw (LMS) systems [Table 7] demonstrates that the use of PCF with cages in the treatment of spondylotic radiculopathy is not associated with an increase in perioperative complications of any kind. When comparing the general rate of all complications associated with PCF with bilateral cages placed between the facet joints, those reported in the literature for ACDF and PCF with cages have a more favorable complication profile (3.4% vs. 17.41%).^[15-26] Similarly, PCF with cages in all groups in this study had a favorable complication profile compared to that reported for posterior LMS systems (standalone 3.4% vs. 19.4%).^[29-41] It should be noted that the majority of lateral mass cases reported in the literature are multilevel and are performed for cervical spondylotic myelopathy. Furthermore, LMS placement requires an open posterior approach, and the procedure is usually performed in combination with a laminectomy. This prolongs surgical time, increases blood loss, and length of stay [Figures 4 and 5].

As with any technique involving instrumentation, there are a number of reasons why complications may occur. As with any new technique, there is an initial learning curve. For procedures that use a tissue-sparing approach, the learning curve can be significantly steeper than for traditional techniques.^[25] In our study, all cases were successfully completed using a tissue-sparing approach. All complications that were captured in this study were minor with full recovery. Compared to other cervical techniques, the perioperative complication profile of PCF with cages looks promising. Meta-analysis of cervical procedures reported a rate of

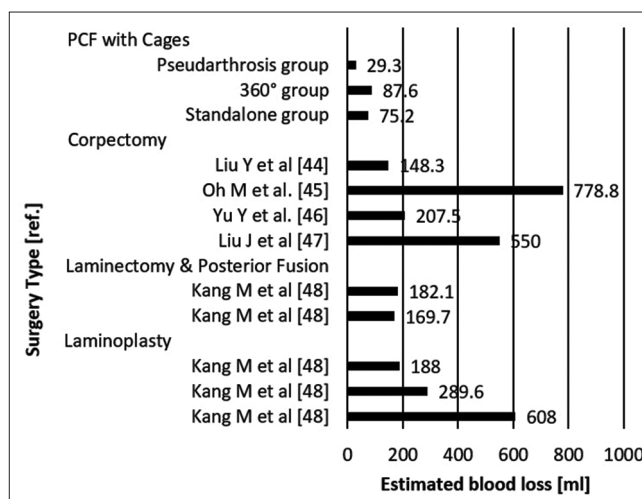


Figure 5: Estimated blood loos

4.81% of neurological complications with range of 0%–32% for ACDF technique and 9.89% with range of 0%–20.3% for posterior LMS (standalone 2.2%, circumferential 0.0%, and pseudarthrosis 3.6%).^[15-26,29-41] Modern LMS placement has not been shown to be associated with vascular complications while ACDF technique reports 0.33%–10% patients out of 2990 cases (standalone 0%, circumferential 0%, and pseudarthrosis 0%).^[15-26,29-41] Sekhon suggested that a 14-mm screw is safe and effective based on the fact that the average vertical distance between the posterior midpoint of the lateral mass and the vertebral foramen from C3 to C6 is approximately 9–12 mm.^[33] A cervical cage can be placed by a posterior approach in between a facet joint and is stopped from advancing ventrally toward the foramen transversarium by the cervical pedicle making vertebral artery injury highly unlikely. Other complications were reported to be 7.19%; 1.8%–32% for ACDF and 9.51%; 0%–17.2% for posterior LMS systems.^[15-26,29-41]

Serious adverse events associated with ACDF are rare but may include esophageal, tracheal, and carotid sheath injury. More commonly, patients experience postoperative dysphagia and subclinical vocal cord dysfunction.^[10,42] In this study, one patient was reported with C5 palsy resulting in a 1.1% rate of occurrence, which is lower than anterior and posterior techniques which have been followed by

Table 6: Comparison between posterior cervical fusion with intervertebral cages and anterior cervical discectomy and fusion technique

	Sample size	Neurological complications (%)	Vascular complications (%)	Other complications (%)
PCF with intervertebral cages	89	2.2	0	4.5
ACDF				
Guo Q <i>et al.</i> , 2011	43	0	0	8.7
Lian XF <i>et al.</i> , 2010	55	9.1	0	1.8
Uribe JS <i>et al.</i> , 2009	42	0	0	2.38
Liu P <i>et al.</i> , 2006	19	2.1	0	10.0
Nirala AP <i>et al.</i> , 2004	69	0	0	22.5
Song KJ <i>et al.</i> , 2012	25	0	0	16
Liu Y <i>et al.</i> , 2012	69	5.7	0	15.9
Lin Q <i>et al.</i> , 2012	57	8.8	0	10.5
Hwang SL <i>et al.</i> , 2007	27	0	0	32
Yonenobu K <i>et al.</i> , 1985	50	0	0	4.3
Bertalanffy <i>et al.</i> , 1989	450	6.1	0.9	1.8
Burke <i>et al.</i> , 2005	1976	N/R	0.3	N/R
Emery <i>et al.</i> , 1998	108	4.6	0	10.2

ACDF - Anterior cervical discectomy and fusion; PCF - Posterior cervical fusion; N/R - Not reported

Table 7: Comparison of complications between posterior cervical fusion with intervertebral cages and posterior screw stabilization

	Sample size	Neurological complications (%)	Vascular complications (%)	Other complications (%)
PCF with intervertebral cages	89	2.2	0	4.5
Posterior LMS				
Author, year	Sample size	Neurological complications (%)	Vascular complications (%)	Other complications (%)
Moh'd <i>et al.</i> , 2011	110	20.3	0	8.5
Gordon <i>et al.</i> , 2003	21	9.52	0	8.5
Dhruy <i>et al.</i> , 2006	98	17.2	0	23.9
Mokbel <i>et al.</i> , 2015	44	6.8	0	0
Hwang <i>et al.</i> , 2007	32	0	0	12.5
Lali <i>et al.</i> , 2005	143	2.79	0	13.2
Katonis <i>et al.</i> , 2011	225	3.5	0	0.8
Barbarawi <i>et al.</i> , 2015	430	8.14	0	3.25
Graham <i>et al.</i> , 1996	21	14	0	4.8
Abumi <i>et al.</i> , 2000	180	1.7	0.6	2.22
Fehlings <i>et al.</i> , 1994	44	0	0	27.3
Heller <i>et al.</i> , 1995	78	5.1	0	7.7
Levine <i>et al.</i> , 1992	24	25	0	29.2
Wellman <i>et al.</i> , 1998	43	0	0	9.3

PCF - Posterior cervical fusion; LMS - Lateral mass screw

3%–6% C5 palsy.^[43] It is important to note that no neurologic complications occurred in the standalone group or in the series of 52 patients who underwent PCF with cage placement published by Siemionow *et al.*^[13]

Blood loss was negligible during this study of PCF with cages. Length of stay reported at 29 h for single-level cases is favorable to ACDF and increases along with the complexity of the procedure as shown when comparing the standalone and pseudarthrosis groups to the circumferential group (standalone 29.2 ± 22.2 h, pseudarthrosis 29.3 ± 13.6 h, and circumferential 49.1 ± 33.7 h). This finding is similar to that for ACDF procedures.

The performed surgery significantly improved patients' outcomes regarding to neck and arm pain [Tables 3 and 4]. All subsequent collected data revealed the significant improvement achieved 2 weeks after surgery. The data have limitation based on the patients' control visits frequency. On the last visit (24 months after surgery), only three patients appeared. It could impact into the results. Assuming that mainly patients with discomfort appear, we can expect better results than obtained.

Overall, PCF with cages for the treatment of cervical radiculopathy and ACDF-associated pseudarthrosis is a safe and effective option with favorable complication and utility profiles.

Posterior cage fixation can achieve indirect cervical root decompression with less soft-tissue disruption than LMF.^[5] The concept of indirect neuroforaminal decompression in this spine level has been validated for cervical spondylotic radiculopathy.^[44-46] Indirect cervical nerve root decompression and fusion performed using cervical cages placed bilaterally between the facet joints by way of a posterior approach has demonstrated good clinical and radiological outcomes at 24 months.^[5,7,13] Stabilization achieved after bilateral posterior cervical cage implantation is reported to be similar to one-level ACDF and LMF in biomechanical studies.^[47,48] High fusion rate in mentioned method provides long-term spine stabilization.^[5]

CONCLUSION

The results of our study show that the PCF with cages can be considered a safe alternative for patients undergoing cervical spine surgery. The procedure has a favorable overall complication profile, short length of stay, a negligible blood loss, and significantly the neck and arm pain.

Financial support and sponsorship

The following authors received funding for medical chart review and data collection: Robert J Blok, Mark C Gillespy, Mukund I Gundanna, William D Smith, Zeshan Hyder, Bruce M McCormack.

Conflicts of interest

K. Siemionow has a financial interest in Providence Medical Technology. The following authors received funding for medical chart review and data collection: Robert J Blok, Mark C Gillespy, Mukund I Gundanna, William D Smith, Zeshan Hyder, Bruce M McCormack.

REFERENCES

- Goel A, Shah A, Patni N, Ramdasi R. Immediate postoperative reversal of disc herniation following facet distraction-fixation surgery: Report of four cases. *World Neurosurg* 2016;94:339-344.
- Goel A. Interfacetal intra-articular spacers: Emergence of a concept. *J Craniovertebr Junction Spine* 2016;7:72-4.
- Goel A. Facet distraction spacers for treatment of degenerative disease of the spine: Rationale and an alternative hypothesis of spinal degeneration. *J Craniovertebr Junction Spine*. 2010;1:65-6.
- Goel A. Facet distraction-arthrodesis technique: Can it revolutionize spinal stabilization methods? *J Craniovertebr Junction Spine* 2011;2:1-2.
- Siemionow K, Janusz P, Phillips FM, Youssef JA, Isaacs R, Tyrakowski M, *et al.* Clinical and radiographic results of indirect decompression and posterior cervical fusion for single-level cervical radiculopathy using an expandable implant with 2-year follow-up. *J Neurol Surg A Cent Eur Neurosurg* 2016;77:482-8.
- Siemionow K, Janusz P, Glowka P. Cervical cages placed bilaterally in the facet joints from a posterior approach significantly increase foraminal area. *Eur Spine J* 2016;25:2279-85.
- McCormack BM, Bundoc RC, Ver MR, Ignacio JM, Berven SH, Eyster EF. Percutaneous posterior cervical fusion with the DTRAX Facet System for single-level radiculopathy: Results in 60 patients. *J Neurosurg Spine* 2013;18:245-54.
- Mantha S, Thisted R, Foss J, Ellis JE, Roizen MF. A proposal to use confidence intervals for visual analog scale data for pain measurement to determine clinical significance. *Anesth Analg* 1993;77:1041-7.
- Campbell PG, Yadla S, Malone J, Zussman B, Maltenfort MG, Sharan AD, *et al.* Early complications related to approach in cervical spine surgery: Single-center prospective study. *World Neurosurg* 2010;74:363-8.
- Daniels AH, Riew KD, Yoo JU, Ching A, Birchard KR, Kranenburg AJ, *et al.* Adverse events associated with anterior cervical spine surgery. *J Am Acad Orthop Surg* 2008;16:729-38.
- Neo M, Fujibayashi S, Miyata M, Takemoto M, Nakamura T. Vertebral artery injury during cervical spine surgery: A survey of more than 5600 operations. *Spine (Phila Pa 1976)* 2008;33:779-85.
- McCormack BM, Dhawan R. Novel instrumentation and technique for tissue sparing posterior cervical fusion. *J Clin Neurosci* 2016;34:299-302.
- Siemionow K, Monsef JB, Janusz P. Preliminary analysis of adjacent segment degeneration in patients treated with posterior cervical cages: 2-year follow-up. *World Neurosurg* 2016;89:730.e1-7.
- Tew JM Jr., Mayfield FH. Complications of surgery of the anterior cervical spine. *Clin Neurosurg* 1976;23:424-34.
- Guo Q, Bi X, Ni B, Lu X, Chen J, Yang J, *et al.* Outcomes of three anterior decompression and fusion techniques in the treatment of three-level cervical spondylosis. *Eur Spine J* 2011;20:1539-44.
- Lian XF, Xu JG, Zeng BF, Zhou W, Kong WQ, Hou TS. Noncontiguous anterior decompression and fusion for multilevel cervical spondylotic myelopathy: A prospective randomized control clinical study. *Eur Spine J* 2010;19:713-9.
- Uribe JS, Sangala JR, Duckworth EA, Vale FL. Comparison between anterior cervical discectomy fusion and cervical corpectomy fusion using titanium cages for reconstruction: Analysis of outcome and long-term follow-up. *Eur Spine J* 2009;18:654-62.
- Nirala AP, Husain M, Vatsal DK. A retrospective study of multiple interbody grafting and long segment strut grafting following multilevel anterior cervical decompression. *Br J Neurosurg* 2004;18:227-32.
- Song KJ, Lee KB, Song JH. Efficacy of multilevel anterior cervical discectomy and fusion versus corpectomy and fusion for multilevel cervical spondylotic myelopathy: A minimum 5-year follow-up study. *Eur Spine J* 2012;21:1551-7.
- Liu Y, Hou Y, Yang L, Chen H, Wang X, Wu X, *et al.* Comparison of 3 reconstructive techniques in the surgical management of multilevel cervical spondylotic myelopathy. *Spine (Phila Pa 1976)* 2012;37:E1450-8.
- Lin Q, Zhou X, Wang X, Cao P, Tsai N, Yuan W. A comparison of anterior cervical discectomy and corpectomy in patients with multilevel cervical spondylotic myelopathy. *Eur Spine J* 2012;21:474-81.
- Hwang SL, Lee KS, Su YF, Kuo TH, Lieu AS, Lin CL, *et al.* Anterior corpectomy with iliac bone fusion or discectomy with interbody titanium cage fusion for multilevel cervical degenerated disc disease. *J Spinal Disord Tech* 2007;20:565-70.
- Yonenobu K, Fuji T, Ono K, Okada K, Yamamoto T, Harada N. Choice of surgical treatment for multilevel cervical spondylotic myelopathy. *Spine (Phila Pa 1976)* 1985;10:710-6.
- Bertalanffy H, Eggert HR. Complications of anterior cervical discectomy without fusion in 450 consecutive patients. *Acta Neurochir (Wien)* 1989;99:41-50.
- Burke JP, Gerszten PC, Welch WC. Iatrogenic vertebral artery injury during anterior cervical spine surgery. *Spine J* 2005;5:508-14.
- Emery SE, Bohlman HH, Bolesta MJ, Jones PK. Anterior cervical decompression and arthrodesis for the treatment of cervical spondylotic myelopathy. Two to seventeen-year follow-up. *J Bone Joint Surg Am* 1998;80:941-51.

27. Jamjoom ZA. Pharyngo-cutaneous fistula following anterior cervical fusion. *Br J Neurosurg* 1997;11:69-74.
28. Kuriloff DB, Blaugrund S, Ryan J, O'Leary P. Delayed neck infection following anterior spine surgery. *Laryngoscope* 1987;97:1094-8.
29. Al Barbarawi MM, Audat ZA, Obeidat MM, Qudsieh TM, Dabbas WF, Obaidat MH, *et al.* Decompressive cervical laminectomy and lateral mass screw-rod arthrodesis. Surgical analysis and outcome. *Scoliosis* 2011;6:10.
30. Deen HG, Birch BD, Wharen RE, Reimer R. Lateral mass screw-rod fixation of the cervical spine: A prospective clinical series with 1-year follow-up. *Spine J* 2003;3:489-95.
31. Pateder DB, Carbone JJ. Lateral mass screw fixation for cervical spine trauma: Associated complications and efficacy in maintaining alignment. *Spine J* 2006;6:40-3.
32. Hwang IC, Kang DH, Han JW, Park IS, Lee CH, Park SY. Clinical experiences and usefulness of cervical posterior stabilization with polyaxial screw-rod system. *J Korean Neurosurg Soc* 2007;42:311-6.
33. Sekhon LH. Posterior cervical lateral mass screw fixation: Analysis of 1026 consecutive screws in 143 patients. *J Spinal Disord Tech* 2005;18:297-303.
34. Katonis P, Papadakis SA, Galanakos S, Paskou D, Bano A, Sapkas G, *et al.* Lateral mass screw complications: Analysis of 1662 screws. *J Spinal Disord Tech* 2011;24:415-20.
35. Al Barbarawi MM, Allouh MZ. Cervical lateral mass screw-rod fixation: Surgical experience with 2500 consecutive screws, an analytical review, and long-term outcomes. *Br J Neurosurg* 2015;29:699-704.
36. Graham AW, Swank ML, Kinard RE, Lowery GL, Dials BE. Posterior cervical arthrodesis and stabilization with a lateral mass plate. Clinical and computed tomographic evaluation of lateral mass screw placement and associated complications. *Spine (Phila Pa 1976)* 1996;21:323-8.
37. Abumi K, Shono Y, Ito M, Taneichi H, Kotani Y, Kaneda K. Complications of pedicle screw fixation in reconstructive surgery of the cervical spine. *Spine (Phila Pa 1976)* 2000;25:962-9.
38. Fehlings MG, Cooper PR, Errico TJ. Posterior plates in the management of cervical instability: Long-term results in 44 patients. *J Neurosurg* 1994;81:341-9.
39. Heller JG, Silcox DH 3rd, Sutterlin CE 3rd. Complications of posterior cervical plating. *Spine (Phila Pa 1976)* 1995;20:2442-8.
40. Levine AM, Mazel C, Roy-Camille R. Management of fracture separations of the articular mass using posterior cervical plating. *Spine (Phila Pa 1976)* 1992;17 10 Suppl:S447-54.
41. Wellman BJ, Follett KA, Traynelis VC. Complications of posterior articular mass plate fixation of the subaxial cervical spine in 43 consecutive patients. *Spine (Phila Pa 1976)* 1998;23:193-200.
42. Oh MC, Zhang HY, Park JY, Kim KS. Two-level anterior cervical discectomy versus one-level corpectomy in cervical spondylotic myelopathy. *Spine (Phila Pa 1976)* 2009;34:692-6.
43. Kang MS, Choi KC, Lee CD, Shin YH, Hur SM, Lee SH. Effective cervical decompression by the posterior cervical foraminotomy without discectomy. *J Spinal Disord Tech* 2014;27:271-6.
44. Lidar Z, Salame K. Minimally invasive posterior cervical discectomy for cervical radiculopathy: Technique and clinical results. *J Spinal Disord Tech* 2011;24:521-4.
45. Witzmann A, Hejazi N, Krasznai L. Posterior cervical foraminotomy. A follow-up study of 67 surgically treated patients with compressive radiculopathy. *Neurosurg Rev* 2000;23:213-7.
46. Lawton CD, Smith ZA, Lam SK, Habib A, Wong RH, Fessler RG. Clinical outcomes of microendoscopic foraminotomy and decompression in the cervical spine. *World Neurosurg* 2014;81:422-7.
47. Voronov LI, Siemionow KB, Havey RM, Carandang G, Phillips FM, Patwardhan AG. Bilateral posterior cervical cages provide biomechanical stability: Assessment of stand-alone and supplemental fixation for anterior cervical discectomy and fusion. *Med Devices (Auckl)* 2016;9:223-30.
48. Voronov LI, Siemionow KB, Havey RM, Carandang G, Patwardhan AG. Biomechanical evaluation of DTRAX(®) posterior cervical cage stabilization with and without lateral mass fixation. *Med Devices (Auckl)* 2016;9:285-90.