

Hemichorea associated with cavernous angioma and a small errhysis

A case report and literature review

Jiqing Qiu, PhD^a, Yu Cui, MD^b, Lichao Sun, MD^c, Yunbao Guo, PhD^a, Zhanpeng Zhu, PhD^{a,*}

Abstract

Rationale: Chorea is a movement disorder characterized by randomly appearing involuntary movements of the face, neck, limbs, or trunk. Hemichorea is unilateral, involving one side of the body. Hemichorea is commonly caused by non-ketotic hyperglycemia and/or cerebrovascular injury to the contralateral basal ganglia.

Patient concerns: Here, we report the case of a patient diagnosed with hemichorea who had diabetes, cavernous angioma, and a small intracranial errhysis. Routine testing showed the patient's blood glucose level was slightly higher than the normal range.

Interventions: The errhysis was too small to be treated.

Diagnosis: Brain magnetic resonance imaging showed a cavernous angioma with a small errhysis in the right putamen.

Outcomes: Hemichorea was completely resolved after 4 months.

Lessons: If diabetes is well controlled and imaging indicates brain lesions suggestive of a recent stroke, a diagnosis of post-stroke hemichorea should be considered.

Abbreviations: DWI = diffusion-weighted imaging, FLAIR = fluid-attenuation inversion recovery, HIV = human immunodeficiency virus, MRI = magnetic resonance imaging.

Keywords: cavernous angioma, errhysis, hemichorea

1. Introduction

Chorea is a movement disorder characterized by randomly appearing involuntary movements of the face, neck, limbs, or trunk^[1] that include extension, flexion, rotation, or crossing. Hemichorea is unilateral, involving one side of the body.^[2] Hemichorea is usually associated with a contralateral lesion of the central nervous system and is caused by infection, genetic mutation, neoplasms, neurodegeneration, stroke, metabolic disease, drug-exposure, and autoimmune disease.^[2–4] In particular, hemichorea occurs in patients with non-ketotic hyperglycemia or cerebrovascular injury to the contralateral basal ganglia.^[5] Here, we report the case of a patient diagnosed with hemichorea who had diabetes, cavernous angioma, and a small

intracranial errhysis. We reviewed published literature reporting on hemichorea with cavernous angioma.

2. Case report

A 42-year-old man presented to our institution with a complaint of hemichorea in his left arm and leg for 1 week. The hemichorea appeared spontaneously. The patient's medical history included type 2 diabetes for 3 years, for which he was prescribed metformin. On admission the patient's blood glucose level was 7.1 mmol/L (normal range 3.9–6.1 mmol/L) and his hemoglobin A1C reading was 11.2% (normal range 4.27%–6.07%). The patient's neurological examination was unremarkable, his cognitive function was intact, his medical history included no brain injury or neurological diseases, and there was no family history of chorea. Rapid arrhythmic repetitive movements were noted in the left arm and leg.

Brain MRI performed 1 week after the onset of hemichorea revealed a well-defined lesion in the right putamen (Fig. 1). The etiology of the patient's chorea was discussed. Sydenham's chorea was excluded as it is a pediatric disorder. Huntington's disease was excluded as there was no family history of disease. Drug and human immunodeficiency virus (HIV) induced chorea was excluded as the patient had not been exposed to drugs and serology indicated he was HIV negative.

In this case, chorea was thought to be caused by a cavernous angioma and a small intracranial errhysis in the right putamen. The errhysis was too small to be treated; therefore, the patient was discharged. During the next month, hemichorea improved. An MRI revealed a cavernous angioma and an infarction in the right basal ganglia region (Fig. 2). No medicine was given after the MRI. The hemichorea resolved spontaneously without any

Editor: N/A.

JQ and YC contributed equally and should be co-first authors.

The authors declare no conflicts of interest.

^aDepartments of Neurosurgery, ^bDepartments of Otolaryngology, ^cDepartments of Emergency, the First Hospital of Jilin University, Changchun, Jilin, People's Republic of China.

*Correspondence: Zhanpeng Zhu, Department of Neurosurgery, the First Hospital of Jilin University, 71 Xinmin Street, Changchun, Jilin 130021, People's Republic of China (e-mail: 282324491@qq.com).

Copyright © 2018 the Author(s). Published by Wolters Kluwer Health, Inc. This is an open access article distributed under the terms of the Creative Commons Attribution-Non Commercial-No Derivatives License 4.0 (CCBY-NC-ND), where it is permissible to download and share the work provided it is properly cited. The work cannot be changed in any way or used commercially without permission from the journal.

Medicine (2018) 97:43(e12889)

Received: 27 June 2018 / Accepted: 25 September 2018

<http://dx.doi.org/10.1097/MD.00000000000012889>

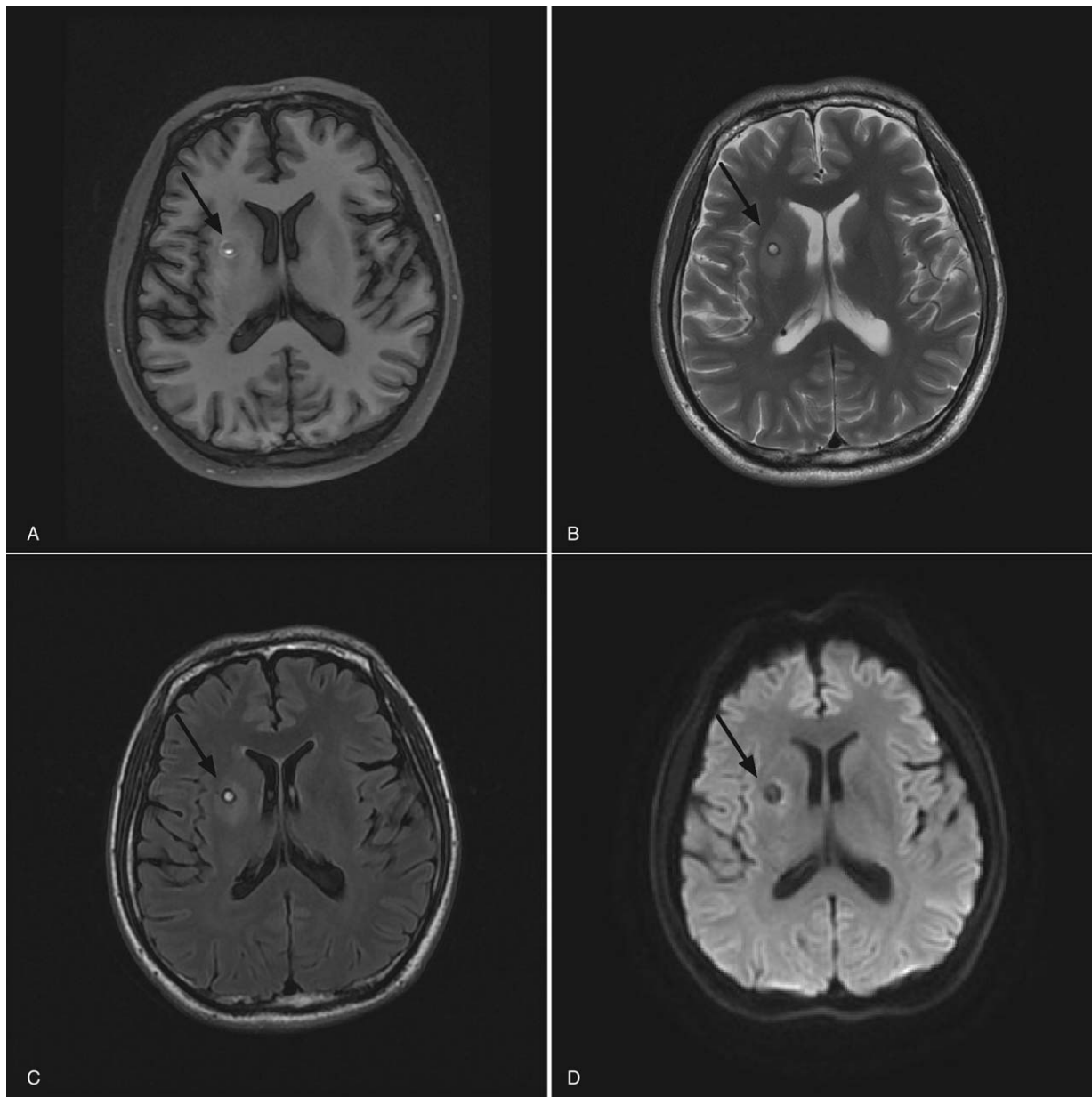


Figure 1. MRI at presentation showed a cavernous angioma and a small errhysis in the right putamen on axial T1-(A) weighted, T2-(B) weighted, and fluid-attenuation inversion recovery (FLAIR) (C) sequences. Diffusion-weighted imaging (DWI) showed no infarction (D).

sort of pharmacological intervention. Hemichorea was completely resolved after 4 months. The study was approved by the ethics committee of the First Hospital of Jilin University. Informed written consent was obtained from the patient for publication of this case report and accompanying images.

3. Discussion

In this report, we present the case of a patient diagnosed with hemichorea who had a history of type 2 diabetes; therefore, we suspected diabetic chorea. Evidence suggests that diabetes may initially manifest as hemichorea, possibly because hyperglycemia, impaired cellular function, or the dominance of anaerobic metabolism causes injury to the striatum.^[6] However, our patient was diagnosed with type 2 diabetes three years prior to the onset of hemichorea, and his blood glucose level (7.1 mmol/L) did not

approach the mean value usually reported for patients with hemichorea associated with hyperglycemia. In a previous study of 20 patients with hemichorea/hemiballism associated with hyperglycemia, the mean blood glucose level was 17.04 mmol/L.^[7]

In the current study, the patient underwent MRI, which showed cavernous angioma with a small intracranial errhysis; this indicated post-stroke hemichorea. Other causes of hemichorea, including Sydenkam's chorea (a neurological manifestation of acute rheumatic fever), Huntingdon's disease (genetic disorder), and drug (eg, oral contraceptives, carbamazepine lamotrigine),^[3] and HIV-induced chorea were excluded as the patient did not have the risk factors or clinical characteristics to suggest these etiologies.^[3] Toxicity, such as carbon monoxide poisoning causes lesions in the basal ganglia,^[8] but the patient had no history of possible toxic exposure.

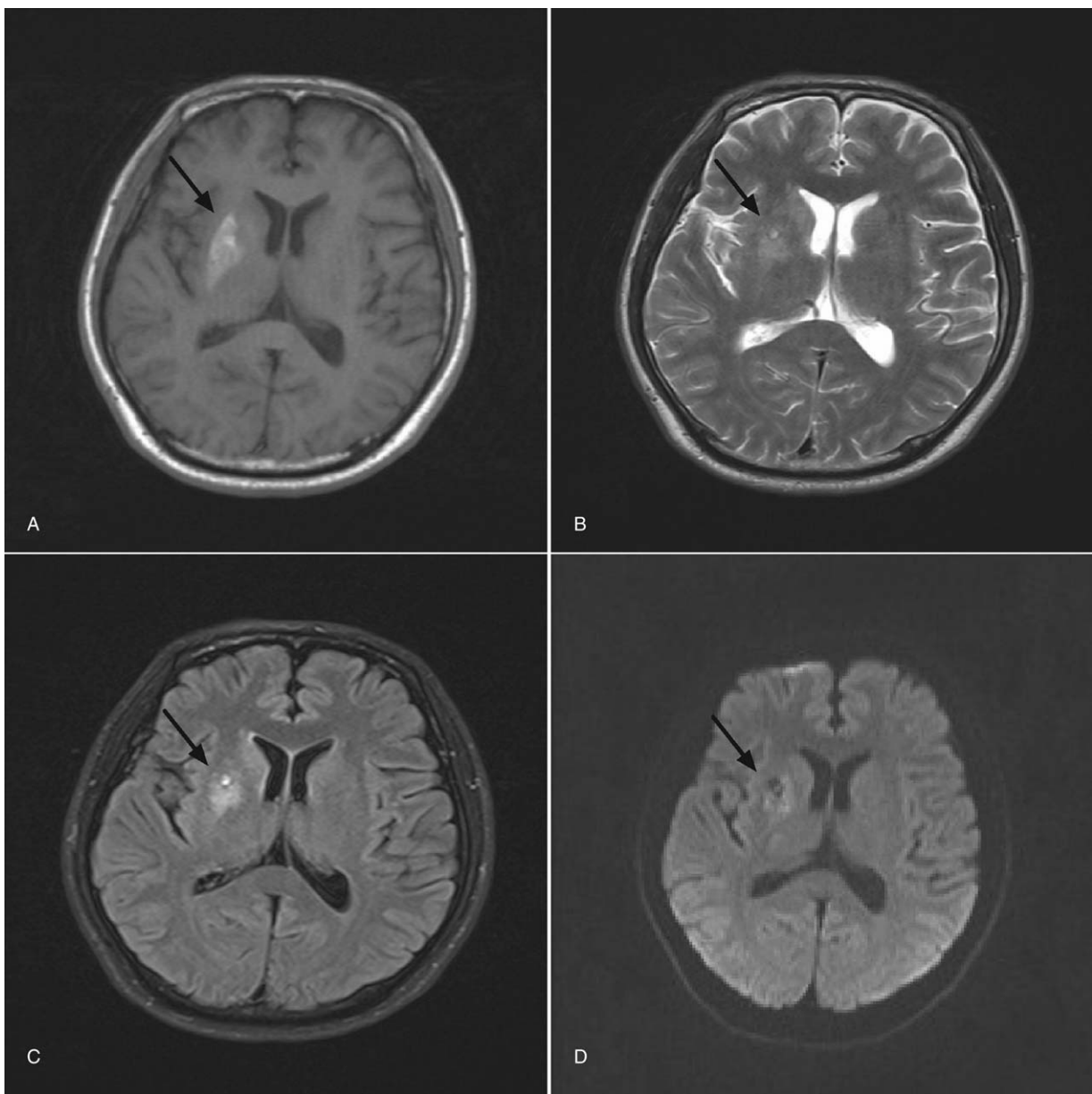


Figure 2. MRI one month after initial presentation showed a cavernous angioma and infarction in the right basal ganglia region on axial T1-(A) weighted, T2-(B) weighted, FLAIR (C) sequences, and DWI (D).

In the current study, the intracranial hemorrhage was small with no obvious clinical symptoms; therefore, the doctor did not intervene. Hemichorea was alleviated after 1 month and was resolved after 4 months. An infarction appeared after the hemorrhage. Previously, a large study investigating the clinical features of post-stroke hemichorea in 20 patients found that hemichorea appeared on the day of stroke onset or within one to five days post stroke due to stroke-induced dysfunction of the basal ganglia motor circuit; hemichorea resolved in 56% of patients over a mean follow up period of 22 months.^[9]

The pathophysiology of chorea remains to be fully elucidated, but it is thought to involve a disruption in the balance of activity in the neuronal network between the motor cortex and basal ganglia, which includes subcortical nuclei, caudate nuclei, the subthalamus and thalamus, by metabolic disturbances or structural lesions. In previous studies, typical sites of hemichorea

include the subthalamus, striatum, and the basal ganglia.^[9] Functional imaging has shown neuronal loss and dysfunction in many chorea syndromes, as well as alterations in metabolism and presymptomatic dopaminergic dysfunction.^[10]

Due to the many causes of chorea, treatment is challenging. Physicians should gather a comprehensive medical history, including a medication history of potential causative agents and recent history of streptococcal infection, and review the neurological and psychiatric systems of a patient presenting with symptoms.^[11] Neuroimaging, genetic testing, and laboratory investigations allow confirmation of a suspected diagnosis of chorea. Mild chorea may not require treatment.^[12] Primary chorea may be treated with dopaminergic antagonists, including neuroleptic medications; however, side effects include parkinsonism and tardive syndromes.^[11] Dopamine-depleting agents that inhibit presynaptic dopamine release and block postsynaptic

Table 1**Previous reports of hemichorea with cavernous angioma.**

Case	Author	Sex	Age, y	Involved body parts	Lesion locations	MRI	Treatment	Outcome of hemichorea
1	Kongsakorn et al ^[15]	F	39	Right hand and feet	Posterior limb of the left internal capsule and the lateral part of the left thalamoganglionic region	Mixed iso- and hyperintense in T1W images, and heterogeneous and hyperintense in T2W/FLAIR images	Haloperidol	Symptoms improved
2	Zabek et al ^[16]	F	58	distal parts of right hand and right leg	The left internal capsule	A central focus of reticulated high signal intensity surrounded by a rim of void signal	Operation	Disappeared
3	Kuwahara et al ^[19]	M	65	Left arm	Right putamen	Mixed signal intensity, with a central core and a peripheral rim of decreased intensity	Haloperidol, sodium valproate, and zonisamide	No improvement
4	Donmez et al ^[17]	M	63	The fingers of right hand and right leg	The anterior part of the left insula, External capsule, and lateral putamen	T1: the lesion had bright foci mounted on a hypointense to isointense background. T2: high signal intensity intermingled with millimetric hypointense foci and surrounded by a hypointense rim	Na valproate	Movements decreased
5	Yakinci et al ^[13]	M	9	Right side	Left operculoinsular and head of the Caudate nucleus	Centrally high signal intensity, representing methemoglobin on T1-weighted and T2-weighted images. The peripheral hypointense signal of the hemosiderin is demonstrated on T2-weighted images	Oral pimozide	Movements disappear
6	Carpay et al ^[18]	M	11	Right side of body (face, arm, leg)	Left caudate nucleus	A lesion in the head of the caudate nucleus	Surgery	Movements disappeared
7	Carella et al ^[14]	M	77	Left arm and foot	Right caudate nucleus	A round lesion in the head of the right caudate nucleus extending into the rostral part of the right lenticular nucleus. There was a perilesional halo and intralesional areas of absent signal. Within the lesion, areas of hyperintense T1 and T2 signal were also observed	—	—

FLAIR = fluid-attenuation inversion recovery.

dopamine receptors are effective, especially when used in combination with a dopamine antagonist.^[11] When treating secondary chorea, the primary causative factor should be addressed. In diabetic chorea, glucose control should be optimized. If chorea is induced by drugs or toxicity, the causative agent should be withdrawn. Medications used to treat primary chorea may be administered to treat the symptoms of secondary chorea.^[11] Surgical treatments like pallidotomy and deep brain stimulation may also be an option.^[12]

To further investigate hemichorea with cavernous angioma, two reviewers independently searched the PubMed and Web of Science databases from inception to January 1, 2018 using a combination of the following keywords and subject terms:

“hemichorea” and “cavernous angioma.” The search strategy revealed 7 studies (Table 1).^[13–19] In these studies, the patients were predominantly male (4/2) and aged between 9^[13] and 77^[14] years. The chorea involved the right side in 5/7^[13,15–18] patients. The lesion location was contralateral to the hemichorea in all cases and included the caudate nucleus,^[13,14,18] putamen,^[17,19] as in our case, and the internal capsule.^[15,16] Hemichorea was resolved by surgery in 2 cases^[16,18] and antipsychotic oral medication (pimozide) in one case.^[13] In two cases, oral antipsychotic (haloperidol)^[15] or anticonvulsant (sodium valproate)^[17] medication improved symptoms. In one case,^[19] a combination of antipsychotic and anticonvulsant medications showed no improvement.

4. Conclusion

We report the case of a patient diagnosed with hemichorea who had diabetes, cavernous angioma, and a small intracranial errhysis. In patients presenting with chorea, diabetes, and evidence of stroke, diabetic chorea should be suspected if blood glucose levels are high. If diabetes is well controlled and imaging indicates brain lesions suggestive of a recent stroke, a diagnosis of post-stroke hemichorea should be considered.

Acknowledgments

The authors would like to thank Medjaden Bioscience Limited for editing and proofreading the article.

Author contributions

Resources: Lichao Sun.

Supervision: Yunbao Guo.

Writing – review & editing: Zhanpeng Zhu.

Writing – original draft: Jiqing Qiu and Yu Cui.

References

- [1] Hermann A, Walker RH. Diagnosis and treatment of chorea syndromes. *Curr Neurol Neurosci Rep* 2015;15:514.
- [2] Handley A, Medcalf P, Hellier K, et al. Movement disorders after stroke. *Age Ageing* 2009;38:260–6.
- [3] Cardoso F, Seppi K, Mair KJ, et al. Seminar on choreas. *Lancet Neurol* 2006;5:589–602.
- [4] Narayanan S. Hyperglycemia-induced hemiballismus hemichorea: a case report and brief review of the literature. *J Emerg Med* 2012;43:442–4.
- [5] Al-Quliti KW, Assaedi ES. Hemichorea with unilateral MRI striatal hyperintensity in a Saudi patient with diabetes. *Neurosciences (Riyadh)* 2016;21:56–9.
- [6] Verma R, Prahara HN. Hemichorea-hemiballism as the presenting manifestation of diabetes mellitus. *BMJ Case Rep* 2013;2013:1–2.
- [7] Cosentino C, Torres L, Nunez Y, et al. Hemichorea/Hemiballism associated with hyperglycemia: report of 20 cases. *Tremor Other Hyperkinet Mov (N Y)* 2016;6:402.
- [8] Kranick SM, Price RS, Prasad S, et al. Clinical reasoning: a 52-year-old woman with subacute hemichorea. *Neurology* 2008;71:e59–62.
- [9] Chung SJ, Im JH, Lee MC, et al. Hemichorea after stroke: clinical-radiological correlation. *J Neurol* 2004;251:725–9.
- [10] Ehrlich DJ, Walker RH. Functional neuroimaging and chorea: a systematic review. *J Clin Mov Disord* 2017;4:8.
- [11] Bhidayasiri R, Truong DD. Chorea and related disorders. *Postgrad Med J* 2004;80:527–34.
- [12] Pandey S. Chorea. *J Assoc Physicians India* 2013;61:471–4.
- [13] Yakinci C, Durmaz Y, Korkut M, et al. Cavernous hemangioma in a child presenting with hemichorea: response to pimozide. *J Child Neurol* 2001;16:685–8.
- [14] Carella F, Caraceni T, Girotti F. Hemichorea due to a cavernous angioma of the caudate. Case report of an aged patient. *Ital J Neurol Sci* 1992;13:783–5.
- [15] Kongsakorn N, Maroongroge P. A case of hemichorea caused by cerebral cavernous angioma. *J Med Assoc Thai* 2015;98:S165–9.
- [16] Zabeck M, Sobstyl M, Dzierzecki S, et al. Right hemichorea treated successfully by surgical removal of a left putaminal cavernous angioma. *Clin Neurol Neurosurg* 2013;115:844–6.
- [17] Donmez B, Cakmur R, Uysal U, et al. Putaminal cavernous angioma presenting with hemichorea. *Mov Disord* 2004;19:1379–80.
- [18] Carpay HA, Arts WF, Kloet A, et al. Hemichorea reversible after operation in a boy with cavernous angioma in the head of the caudate nucleus. *J Neurol Neurosurg Psychiatry* 1994;57:1547–8.
- [19] Kuwahara H. Images in clinical medicine. Persistent hemichorea. *N Engl J Med* 2013;368:e26.