

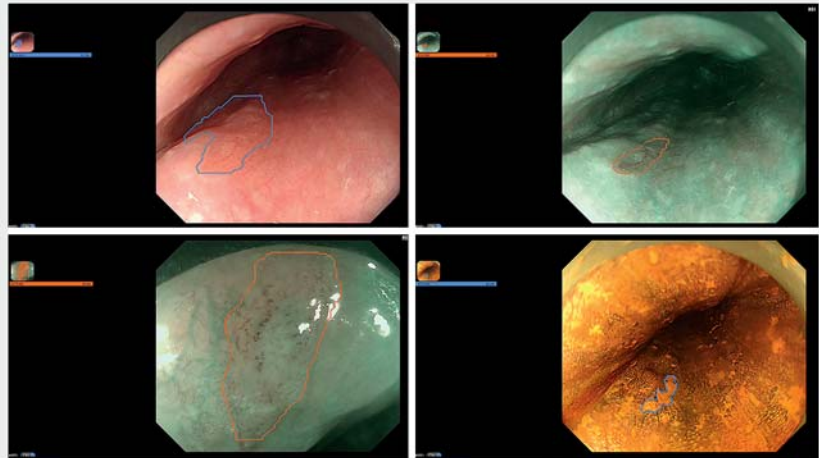
Artificial intelligence for detecting and delineating a small flat-type early esophageal squamous cell carcinoma under multimodal imaging



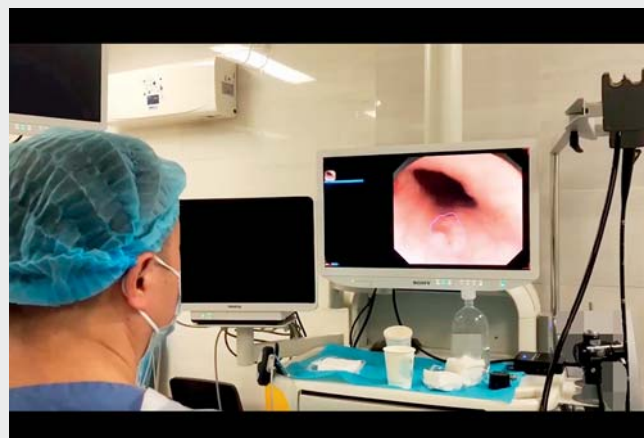Early diagnosis of esophageal squamous cell carcinoma (ESCC) is crucial for improving its prognosis. Effective endoscopic biopsy is key to ensuring no missed diagnoses or misdiagnosis of lesions occur and accurate delineation of the margins of lesions is essential for effective biopsies. Recently, the application of artificial intelligence (AI) in the endoscopic diagnosis of early ESCC has increased; however, most AI systems identified early ESCC with rough square frames [1–3]. For the purpose of precise lesion segmentation, we have developed a new AI system, based on a state-of-the-art algorithm called the YOLACT model [4], that integrates multiple endoscopic imaging modalities to detect and delineate the margins of early ESCC in real time.

The AI system was successfully integrated into the endoscopy equipment. The upper left section of the endoscopy monitor showed the current endoscopic imaging modality and the probability score of suspected early ESCC. In this video demonstration, we show that the AI system not only correctly identified each endoscopic imaging modality, but also accurately detected and delineated the margin of a flat-type mucosal cancer with a size of approximately 3 mm under white-light imaging and narrow-band imaging, with or without magnifying endoscopy and iodine staining (► **Fig. 1**; ► **Video 1**). Histopathology of the endoscopically resected specimen showed an early ESCC with invasion of the lamina propria (► **Fig. 2**).

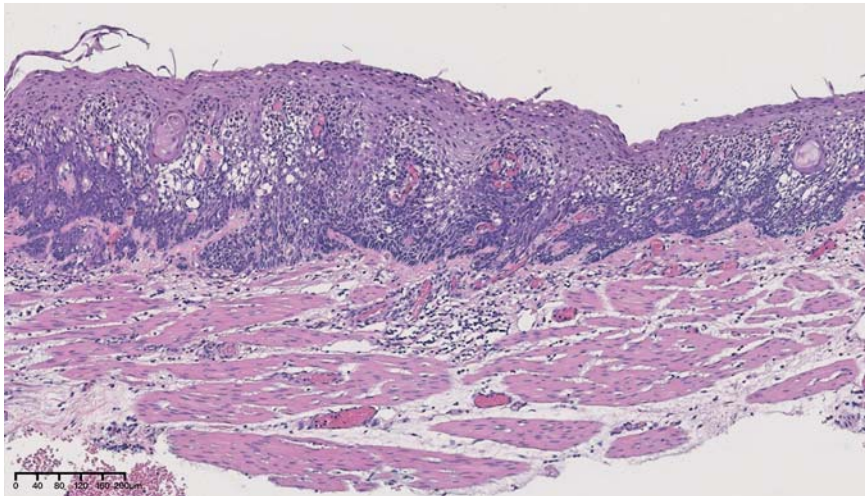
Detecting and delineating subtle early ESCC with AI systems is challenging. To our knowledge, this is the first report of the use of an AI system to detect and de-



► **Fig. 1** Example images of the artificial intelligence system accurately detecting and delineating a small flat-type mucosal cancer under four endoscopic imaging modalities. ECA-WLE, esophageal carcinoma under white-light endoscopy; ECA-NBI, esophageal carcinoma under narrow-band imaging; ECA-IOD, esophageal carcinoma following iodine staining.



► **Video 1** The artificial intelligence system is used to detect and delineate early esophageal squamous cell carcinoma in a real-life setting.



► **Fig. 2** Histopathological appearance of the specimen showing an early esophageal squamous cell carcinoma invading the lamina propria.

lineate a small flat-type early ESCC under multimodal imaging in real time during clinical endoscopy. Unlike with other previously reported AI systems, which require a separate monitor, the proposed AI system was directly connected to an endoscopy monitor commonly used by endoscopists, meaning there is no need for a change in their operating habits, so making our AI system more suitable for clinical use.

Endoscopy_UCTN_Code_CCL_1AB_2AC_3AB

Funding

1-3-5 project for disciplines of excellence, West China Hospital, Sichuan University ZYJC21011

National Natural Science Foundation of China
82170675

Competing interests

The authors declare that they have no conflict of interest.

The authors

Xianglei Yuan^{1*}, Xianhui Zeng^{1*}, Long He¹, Liansong Ye¹, Wei Liu¹, Yanxing Hu², Bing Hu¹

- 1 Department of Gastroenterology, West China Hospital, Sichuan University, Chengdu, China
- 2 Xiamen Innovision Medical Technology Co., Ltd., Xiamen, Fujian Province, China

Corresponding author

Bing Hu, MD

No. 37 Guo Xue Alley, Wu Hou District, Chengdu, Sichuan, 610041, China
hubingnj@163.com

References

- [1] Fukuda H, Ishihara R, Kato Y et al. Comparison of performances of artificial intelligence versus expert endoscopists for real-time assisted diagnosis of esophageal squamous cell carcinoma (with video). *Gastrointest Endosc* 2020; 92: 848–855
- [2] Yang XX, Li Z, Shao XJ et al. Real-time artificial intelligence for endoscopic diagnosis of

early esophageal squamous cell cancer (with video). *Dig Endosc* 2021; 33: 1075–1084

- [3] Yuan XL, Guo LJ, Liu W et al. Artificial intelligence for detecting superficial esophageal squamous cell carcinoma under multiple endoscopic imaging modalities: A multicenter study. *J Gastroenterol Hepatol* 2022; 37: 169–178
- [4] Bolya D, Zhou C, Xiao F et al. YOLACT++ Better real-time instance segmentation. *IEEE Trans Pattern Anal Mach Intell* 2022; 44: 1108–1121

Bibliography

Endoscopy 2023; 55: E141–E142

DOI 10.1055/a-1956-0569

ISSN 0013-726X

published online 28.10.2022

© 2022. The Author(s).

This is an open access article published by Thieme under the terms of the Creative Commons Attribution-NonDerivative-NonCommercial License, permitting copying and reproduction so long as the original work is given appropriate credit. Contents may not be used for commercial purposes, or adapted, remixed, transformed or built upon. (<https://creativecommons.org/licenses/by-nc-nd/4.0/>)

Georg Thieme Verlag KG, Rüdigerstraße 14, 70469 Stuttgart, Germany



ENDOSCOPY E-VIDEOS

<https://eref.thieme.de/e-videos>



Endoscopy E-Videos is an open access online section, reporting on interesting cases

and new techniques in gastroenterological endoscopy. All papers include a high quality video and all contributions are freely accessible online. Processing charges apply (currently EUR 375), discounts and waivers acc. to HINARI are available.

This section has its own submission website at

<https://mc.manuscriptcentral.com/e-videos>

* Co-first authors