



Case Report

Clin Shoulder Elbow 2020;23(4):201-204
<https://doi.org/10.5397/cise.2020.00297>

CiSE

Clinics in Shoulder and Elbow

eISSN 2288-8721

Isolated calcific tendinitis at the posterosuperior labrum: a rare case study

Dong-Hwan Suh, Jong-Hun Ji, Chang-Yeon Kim

Department of Orthopedic Surgery, Daejeon St. Mary's Hospital, College of Medicine, The Catholic University of Korea, Seoul, Korea

Calcific tendinitis of the shoulder joint, also known as chemical furuncle of the shoulder, causes intense shoulder pain and usually occurs within 1–2 cm from the insertion of the rotator cuff. We experienced a rare case of calcific tendinitis in the posterosuperior labrum of the shoulder joint in a 39-year-old male patient who presented with severe pain and weakness in the right shoulder. Radiographs and magnetic resonance imaging (MRI) findings showed calcific tendinitis in the posterosuperior labrum of the shoulder joint. A 1-week attempt at conservative treatment failed, so the calcified deposit in the posterosuperior labrum was arthroscopically removed. The patient's symptoms were completely relieved, and satisfactory clinical outcomes were achieved. Postoperative follow-up X-ray and MRI showed no recurrence of calcific tendinitis.

Keywords: Calcific tendinitis; Posterosuperior labrum; Arthroscopic removal; Calcific deposit

Calcific tendinitis of the rotator cuff is a common disease that can cause severe shoulder pain. Calcification has been rarely reported in elderly patients, and the age group with the most frequent outbreaks experience issues such as rotator cuff tears and calcific tendinitis [1]. Although other joints can be affected, calcific tendinitis occurs most often in the shoulder joint, and it frequently occurs in the supraspinatus, infraspinatus, teres minor and subscapularis tendons in descending order. Additionally, the long head of the biceps tendon is a rare location of calcific tendinitis.

Calcific tendinitis is more common in people between 30 and 60 years of age, and one report described a large number of patients who had less active occupations or were housewives, with

most cases in the right shoulder [2]. The acute symptoms subside in 1 to 2 weeks, even in the absence of treatment, and symptoms can change rapidly [3,4]. The main symptoms are acute severe shoulder pain and limited range of motion (ROM). However, in 20% of cases, it is radiologically confirmed but asymptomatic. The fate of acute calcific tendinitis is spontaneous resorption of the calcific deposit.

The natural history of calcific tendinitis is divided into three phases: the acute phase, subacute phase, and chronic phase. Uhthoff divided calcific tendinitis into three distinct stages: the pre-calcific stage, calcific stage, and post-calcific stage [5]. Furthermore, the calcific stage was subdivided into the formative, resting, and absorptive stages. Most patients report severe symp-

Received: October 27, 2020 Revised: November 13, 2020 Accepted: November 16, 2020

Correspondence to: Jong-Hun Ji

Department of Orthopedic Surgery, Daejeon St. Mary's Hospital, College of Medicine, The Catholic University of Korea, 64 Daeheung-ro, Jung-gu, Daejeon 34943, Korea

Tel: +82-42-220-9530, Fax: +82-42-221-0429, E-mail: jjjh87@gmail.com

IRB approval: Daejeon St. Mary's Hospital (No. 2020-4047-0001).

Financial support: None.

Conflict of interest: None.

Copyright© 2020 Korean Shoulder and Elbow Society. All Rights Reserved.

This is an Open Access article distributed under the terms of the Creative Commons Attribution Non-Commercial License (<http://creativecommons.org/licenses/by-nc/4.0/>) which permits unrestricted non-commercial use, distribution, and reproduction in any medium, provided the original work is properly cited.

toms during the absorptive stage. The calcific stage corresponds to a healing period during which resorption of calcified deposits takes place.

On the other hand, the fate of a calcific deposit on the labrum might be different from that of a conventional calcific deposit on the rotator cuff. During the formative phase, the area of fibrocartilage with the foci of calcification is generally devoid of vascular channels [5]. The posterosuperior labrum is also devoid of vascular channels, and the formation of a calcification on it could be different from calcific tendinitis of the rotator cuff tendons. Calcific tendinitis of the glenoid labrum is a rare disease entity. The management of calcifications in unconventional locations might be different from calcific tendinitis of the rotator cuff. Although spontaneous resorption of calcification at the long head of the biceps tendon has been reported, another reasonable treatment modality could be considered if conservative treatment is not effective [6]. We report a case of calcific tendinitis of the posterosuperior glenoid labrum in a 39-year-old man, and we also review the literature.

CASE REPORT

A 39-year-old man visited our clinic complaining of severe shoulder pain. He reported 1 week of conservative treatment that included oral medication, an injection, and physiotherapy, including extracorporeal shock wave therapy (ESWT), transcutaneous electrical nerve stimulation and cold pack massage, in a local clinic. However, the patient's symptoms had not improved. Laboratory data, including erythrocyte sedimentation rate and C-reactive protein, were normal. On physical examination, se-

vere shoulder pain and limited ROM were observed; the patient could not elevate his arm. In addition, he reported that he could not sleep comfortably.

An X-ray showed a round-shaped calcific deposit near the supraglenoid tubercle of the glenoid in the shoulder joint. Magnetic resonance imaging (MRI) revealed a calcific deposit in the posterosuperior labrum of the shoulder joint (Fig. 1). Because conservative treatment had failed, additional treatment options were discussed, and the patient elected surgical treatment and underwent arthroscopic removal of the calcific deposit in the long head of the biceps tendon.

This study was approved by Institutional Review Board of Daejeon St. Mary's Hospital and informed consent was obtained from the patient included in this study.

Arthroscopic Surgery

The patient was positioned in the lateral decubitus posture with approximately 10 lbs of lateral traction. Conventional arthroscopic evaluation was performed through the posterior portal. Because the preoperative MRI had demonstrated calcified deposits in the posterosuperior labrum, this area was carefully inspected with the probe. Arthroscopic findings showed swelling and hyperemia of the joint capsule, and the posterosuperior labrum had a strawberry-like appearance (Fig. 2A). The labrum was carefully probed and palpated with the probe. An 18-gauge needle was inserted through the port of Wilmington, and the calcific deposit was carefully approached from the anterior to the posterior labrum. Needling on the calcific deposit was repeated several times to widen the exit point of calcific deposits. Next, the sharp tip of the probe was inserted through the opening, and the calcific de-

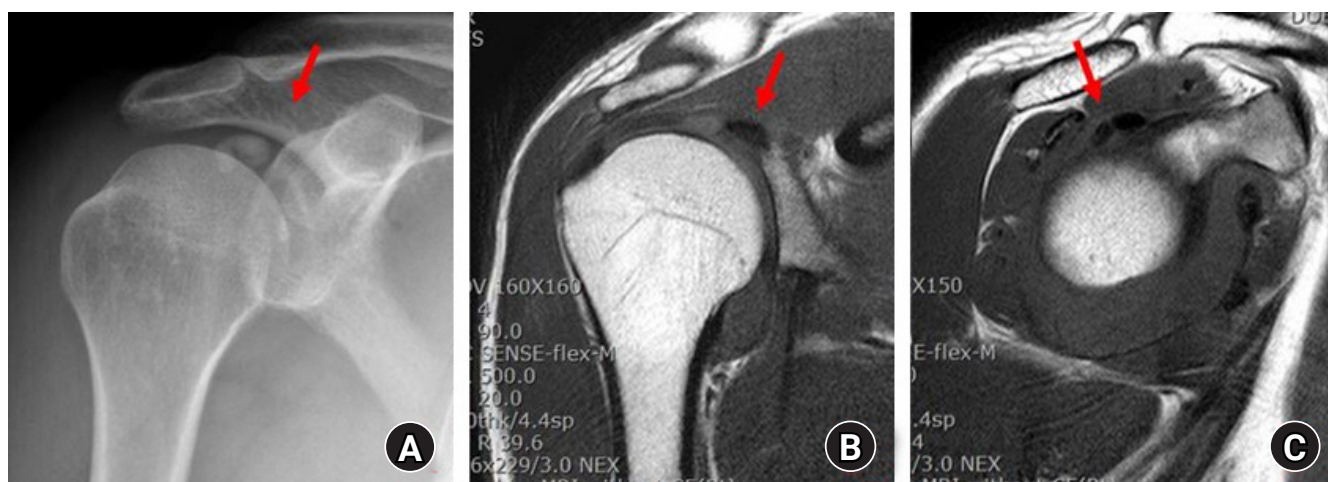


Fig. 1. Radiologic findings of isolated calcific tendinitis at the posterosuperior labrum. (A) An X-ray showed a calcified deposit (arrow) near the upraglenoid tubercle. (B, C) Magnetic resonance imaging revealed a calcified deposit (arrow) in the posterosuperior labrum of the shoulder joint.

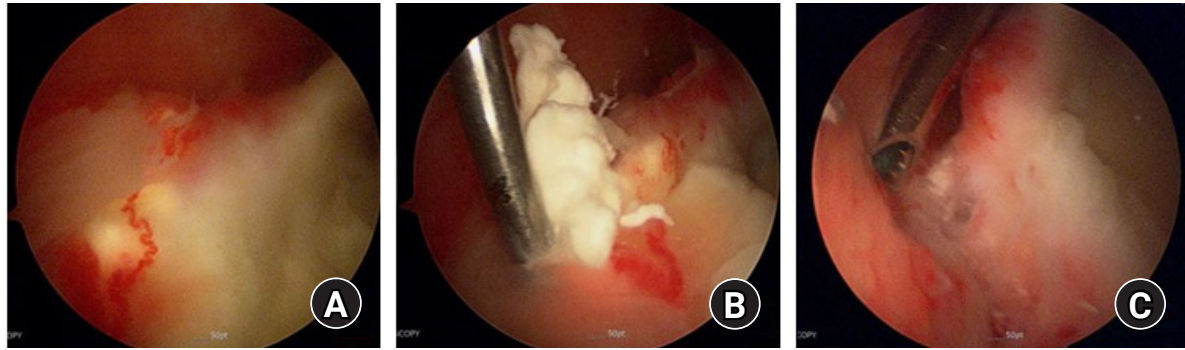


Fig. 2. Arthroscopic findings of isolated calcific tendinitis at the posterosuperior labrum. (A) Arthroscopy showed swelling and hyperemia of the capsule, and the posterosuperior labrum had a strawberry-like appearance. (B) The calcific deposit was removed with the probe tip. (C) Finally, a shaver was inserted to remove the remaining calcific deposit by performing marginal resection of the deposit and capsule.

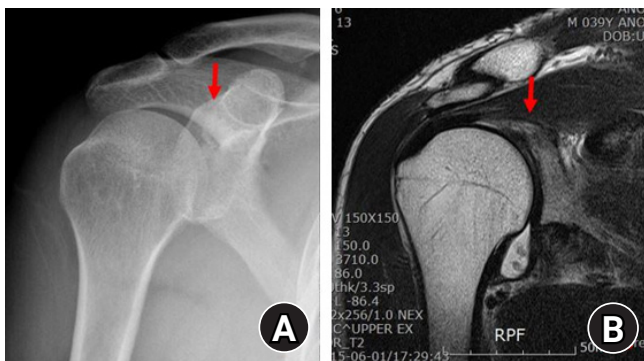


Fig. 3. Follow-up radiologic findings of isolated calcific tendinitis at the posterosuperior labrum. (A) A postoperative X-ray showed only a small trace of the calcific deposit (arrow). (B) Follow-up magnetic resonance imaging showed no evidence of the calcific deposit (arrow).

posit was removed by moving the tip of probe (Fig. 2B). A shaver was inserted for removal of the remaining calcific deposit in the labrum by marginal resection of the calcific deposit (Fig. 2C). The calcific deposit was completely removed during surgery, and 6-month follow-up radiographs and an MRI did not show any evidence of a calcific deposit in the postero-superior labrum (Fig. 3).

DISCUSSION

We experienced an isolated calcific tendinitis at the postero-superior labrum that was successfully treated by arthroscopic calcific deposit removal. After arthroscopic treatment, the patient's severe pain immediately and completely disappeared, and follow-up radiologic findings showed no recurrence of calcific tendinitis.

Typically, calcific tendinitis is described in the rotator cuff tendons and, to a lesser extent, in the long head of the biceps tendon, the pectoralis major, and the trapezius. It is commonly seen

in patients in their fourth to fifth decade, and resorption usually occurs spontaneously without any intervention. Calcific tendinitis of the long head of the biceps tendon is uncommon and rarely reported. Cho and Rhee et al. [7] reported a large calcific deposit in the superior glenoid labrum of the shoulder, and arthroscopic removal of the calcific material completely alleviated the patient's pain. Kim et al. [8] reported calcific tendinitis of the long head of the biceps brachii associated with a superior labral tear from anterior to posterior (SLAP) lesion in a 41-year-old patient. The calcium deposit was removed and the SLAP lesion was repaired with a suture anchor arthroscopically. Ji et al. [9] reported calcific tendinitis of the biceps-labral complex, which is a rare cause of shoulder pain and requires arthroscopic debridement of the calcific material for resolution of symptoms. Amri et al. [6] reported spontaneous resorption of a calcification in the long head of the biceps tendon that had been treated by a conservative approach.

The treatment of such calcific tendinitis included non-steroidal anti-inflammatory drugs (NSAIDs), ESWT, physiotherapy, needle lavage, or arthroscopic removal of the calcific deposit. Treatment of calcific tendinitis is divided into nonsurgical treatment and surgical treatment. First, conservative treatment such as NSAID, physical therapy, ultrasound and ESWT was performed. Ogon et al. [10] reported that negative prognostic factors for patients undergoing conservative treatment were bilateral occurrence of calcific tendinitis of the shoulder, localization to the anterior portion of the acromion, medial (subacromial) extension, and high volume of the calcific deposit and a calcification that is not confirmed by ultrasound.

In our clinic, we evaluate for the presence or absence of these prognostic factors, and then we consider surgical or conservative treatment. For patients in the acute phase, NSAIDs should be used for pain control, and passive ROM should be provided through physical therapy to prevent stiffness of the shoulder

joint. Local steroid injections have been reported to be effective, and they also have been reported to interfere with calcification [1] and are still controversial. In most cases, conservative treatment relieves the patient's symptoms, and Cho et al. [11] reported that symptoms improved with conservative treatment in about 72% of patients. However, the period or type of conservative treatment can vary depending on a patient's tolerance or activity. If a patient cannot tolerate severe pain and/or has no time for conservative treatment, surgical treatment can be considered.

Farin et al. [2] introduced ultrasound-assisted bursal lavage and needling therapy. Ultrasound-assisted needling is often used to treat calcific tendinitis because it can be performed at a relatively low cost under local anesthesia on an outpatient basis. One recent systematic review [12] showed that there is a large variation between studies using ultrasound-assisted needling, thus additional high-quality studies are required for low-quality evidence. ESWT has been used as a treatment for calcific tendinitis since the 1990s. Krasny et al. [13] studied the results of treatment with ESWT, ESWT and ultrasound-guided needling, and reported that combined treatment was more effective and resulted in fewer patients requiring surgical treatment.

Surgical treatment may be considered if conservative treatment fails if the symptoms persist. Although removal of calcified material using an incision is effective, arthroscopic treatment has similar results and minimizes deltoid complications. Arthroscopic treatment is becoming more popular. We described a 39-year-old male patient with calcific tendinitis of the posterosuperior labrum who was treated with arthroscopic removal of the calcific deposit after a 1-week period of failed conservative treatment. Compared to the conventional calcific tendinitis of the rotator cuff, the location of these glenoid labrum was too deep in the glenohumeral joint. In addition, the patient received injection therapy, but his pain was not relieved. Due to the deep location of the calcific deposit in the glenoid labrum, conservative treatment, including ESWT and injection, may not be effective. In this case, ultrasound-guided barbotage or arthroscopic treatment may be considered.

ORCID

Dong-Hwan Suh <https://orcid.org/0000-0003-3029-2553>

REFERENCES

1. Tillander B, Franzén LE, Karlsson MH, Norlin R. Effect of steroid injections on the rotator cuff: an experimental study in rats. *J Shoulder Elbow Surg* 1999;8:271-4.
2. Farin PU, Jaroma H, Soimakallio S. Rotator cuff calcifications: treatment with US-guided technique. *Radiology* 1995;195:841-3.
3. Simon WH. Soft tissue disorders of the shoulder: frozen shoulder, calcific tendinitis, and bicipital tendinitis. *Orthop Clin North Am* 1975;6:521-39.
4. Pendergrass EP, Hodes A Pj. Roentgen irradiation in treatment of inflammation. *Am J Roentgenol* 1941;45:74-106.
5. Calcifying tendinitis. In: Rockwood CA Jr, Matsen FA III, Wirth MA, Harryman DT, eds. *The shoulder*. 2nd ed. Philadelphia, PA: W.B. Saunders; 1998. p.1283-307.
6. Amri A, Yukata K, Nakai S, Hara M, Yamanaka I, Hamawaki J. Spontaneous resorption of calcification at the long head of the biceps tendon. *Shoulder Elbow* 2015;7:190-2.
7. Cho NS, Rhee YG. Calcification in superior glenoid labrum of the shoulder: a case report. *J Shoulder Elbow Surg* 2007;16:e35-7.
8. Kim KC, Rhee KJ, Shin HD, Kim YM. A SLAP lesion associated with calcific tendinitis of the long head of the biceps brachii at its origin. *Knee Surg Sports Traumatol Arthrosc* 2007;15:1478-81.
9. Ji JH, Shafi M, Kim WY. Calcific tendinitis of the biceps-labral complex: a rare cause of acute shoulder pain. *Acta Orthop Belg* 2008;74:401-4.
10. Ogon P, Suedkamp NP, Jaeger M, Izadpanah K, Koestler W, Maier D. Prognostic factors in nonoperative therapy for chronic symptomatic calcific tendinitis of the shoulder. *Arthritis Rheum* 2009;60:2978-84.
11. Cho NS, Lee BG, Rhee YG. Radiologic course of the calcific deposits in calcific tendinitis of the shoulder: does the initial radiologic aspect affect the final results. *J Shoulder Elbow Surg* 2010;19:267-72.
12. Verstraelen FU, Fievez E, Janssen L, Morrenhof W. Surgery for calcifying tendinitis of the shoulder: A systematic review. *World J Orthop* 2017;8:424-30.
13. Krasny C, Enenkel M, Aigner N, Wlk M, Landsiedl F. Ultrasound-guided needling combined with shock-wave therapy for the treatment of calcifying tendonitis of the shoulder. *J Bone Joint Surg Br* 2005;87:501-7.