

Extrafacial lupus miliaris disseminatus



Kathleen M. Nemer, MD,^a and Laura Y. McGirt, MD^b
St Louis, Missouri and Charlotte, North Carolina

Key words: acne agminata; facial idiopathic granulomas with regressive evolution; granulomatous-type rosacea; lupus miliaris disseminatus faciei.

INTRODUCTION

Lupus miliaris disseminatus faciei (LMDF) is an inflammatory dermatosis characterized by 1- to 3-mm red-to-yellow-brown papules on the central and lateral face, particularly on and around the eyelids. Lesions can occur singly or in crops. The discrete papules appear yellow-brown (“apple-jelly”) on diascopy and as epithelioid cell granulomas histologically, thus, resembling tuberculosis, sarcoidosis, or other granulomatous diseases.¹ LMDF classically presents on the face; however, an increasing number of cases are reported with extrafacial involvement.¹⁻⁶ We describe a unique presentation of LMDF characterized predominantly by bilateral axillae involvement.

CASE

A healthy, 48-year-old white woman presented with a persistent 2.5-month history of an asymptomatic, nonpruritic papular eruption in her bilateral axillae and a similar but less robust eruption on the lateral eyelids. She had a history of zirconium-based antiperspirant deodorant and shaving cream use but otherwise denied application of topical products to her axillae. Physical examination found numerous reddish-brown, firm, nonblanching, 2- to 3-mm papules spread throughout the left axilla (Fig 1) and right axilla. There were a few, very subtle, 2- to 3-mm skin-to-pink-colored papules around the lateral canthi of both eyes, superiorly and inferiorly. There was no appreciated lacrimal gland hypertrophy. Punch biopsies from the left superior axilla (Figs 2 and 3) and left zygoma were performed.

Histopathologic analysis found dermal aggregates of palisading epithelioid cells with occasional

Abbreviation used:

LMDF: lupus miliaris disseminatus faciei

neutrophils and fibrin deposition. Multinucleated giant cells were noted and occasionally exhibited phagocytosis of elastic fibers. Focal necrosis occurred in some of the granulomas. Staining for fungi and acid-fast bacilli was negative.

Given the granulomatous histology, the patient underwent further workup for sarcoidosis, including chest radiograph, complete blood count, comprehensive metabolic panel, and serum electrophoresis, all of which were normal. Her tuberculin skin test result was negative. She had no lymphadenopathy, hepatosplenomegaly, lacrimal enlargement, or family history of sarcoidosis. Clinicopathologic correlation led to the final diagnosis of LMDF. The patient was started on minocycline, 100 mg by mouth once daily. She noted near complete resolution of the rash 12 months after therapy.

DISCUSSION

The cause of LMDF remains unclear. In 1878, Fox⁷ reported on *disseminated follicular lupus*, and soon after in 1903 Radcliffe-Crocker designated the term *acne agminata* to describe the grouped eruptions of discrete, dull red-brown papules, which spontaneously involuted leaving pigmented scars.⁸ Initially, LMDF was considered a variant of lupus vulgaris or a tuberculid, but *Mycobacterium tuberculosis* has not been found in active lesions.⁹ LMDF was proposed to be a variant of sarcoidosis given its similar features on diascopy; however, the variably present caseous

From the Division of Dermatology, Washington University School of Medicine^a and Levine Cancer Institute, Carolinas Medical Center.^b

Funding sources: None.

Conflicts of interest: None declared.

This case was presented at the Gross & Microscopic Dermatology Symposium at the 2013 American Academy of Dermatology Meeting, Miami Beach, FL, March 1-5, 2013.

Correspondence to: Kathleen M. Nemer, MD, Division of Dermatology, Washington University School of Medicine,

660 S Euclid Ave, Campus Box 8123, St Louis, MO 63110.

E-mail: knemer@dom.wustl.edu.

JAAD Case Reports 2016;2:363-5.

2352-5126

© 2016 by the American Academy of Dermatology, Inc. Published by Elsevier, Inc. This is an open access article under the CC BY-NC-ND license (<http://creativecommons.org/licenses/by-nc-nd/4.0/>).

<http://dx.doi.org/10.1016/j.jidcr.2016.08.007>

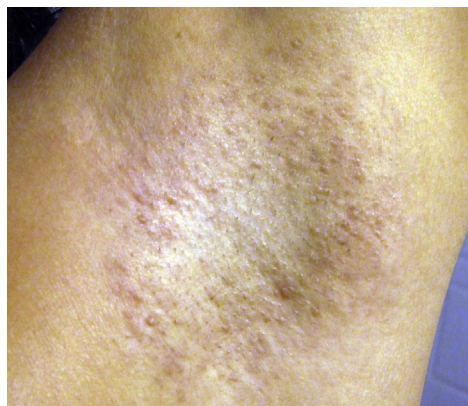

Fig 1. Diffuse red-brown 2- to 3-mm firm papules within the axillary vault.

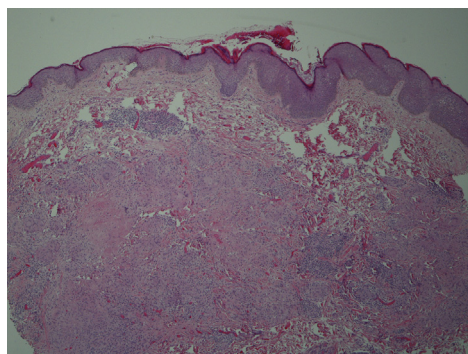


Fig 2. Histologic examination of a punch biopsy taken from the patient's left axilla shows aggregates of palisading epithelioid cells, caseation necrosis, and multinucleated giant cells. (Hematoxylin-eosin stain; original magnification: $\times 10$.)

necrosis and lack of systemic disease argue against this. Others have highlighted the clinical overlap between LMDF and granulomatous-type rosacea. Although the conditions are quite similar, patients with LMDF lack flushing and telangiectasia, have eyelid involvement, and heal with scarring. Thus, many now view LMDF as its own distinct rosacealike syndrome.¹

This patient's clinical presentation is striking given the predominate bilateral axillae involvement and the very subtle, more classic facial manifestations. Throughout the last 2 decades, there have been a number of reported cases with extra-facial LMDF, with most involving the neck, axillae, groin, or extremities.¹⁻⁶ Notably, in 2003, van de Scheur and colleagues¹ reported 3 different cases of LMDF, and, as in our case, extrafacial lesions were prominent, and a full workup for granulomatous skin diseases was negative.²

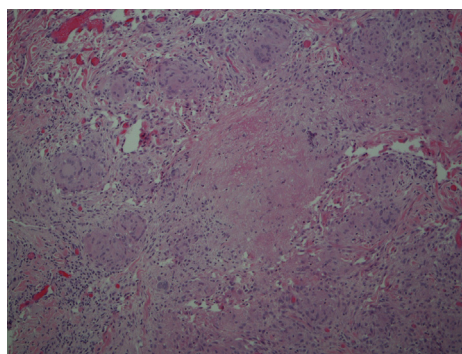


Fig 3. High-power view of multinucleated giant cells and caseation necrosis (Hematoxylin-eosin stain; original magnification: $\times 40$.)

A variety of treatments for LMDF have been attempted, but controlled studies are lacking, and clinicians often find LMDF difficult to control. Topical steroids are ineffective and are not recommended for LMDF. Other reported therapies of variable benefit include prednisone, injectable steroids, tetracyclines, erythromycin, dapsone, clofazimine, isotretinoin, and topical tacrolimus.^{3,10} Additionally, treatment-resistant LMDF responds to fractionated laser and the 1450-nm diode laser.¹¹ Active disease usually persists for 1 to 2 years and resolves spontaneously, unfortunately with the potential for disfiguring scarring.

In 2000, Skowron et al¹² proposed a name change from LMDF to FIGURE (facial idiopathic granulomas with regressive evolution). To date, it does not appear that this name change has been widely used. Given the increasingly reported appearance of LMDF in nonfacial sites, we propose that this entity would be more suitably described as *lupus miliaris disseminatus*. We are hopeful that this knowledge leads to improved diagnostic acumen and speedier identification of extrafacial lupus miliaris disseminatus.

REFERENCES

1. van de Scheur MR, van der Waal RI, Starink TM. Lupus miliaris disseminatus faciei: a distinctive rosacea-like syndrome and not a granulomatous form of rosacea. *Dermatology*. 2003;206:120-123.
2. Kim DS, Lee KY, Shin JU, Roh MR, Lee MG. Lupus miliaris disseminatus faciei without facial involvement. *Acta Derm Venereol*. 2008;88:504-505.
3. Mullan E, Green P, Pasternak S. Lupus miliaris disseminatus faciei with extrafacial involvement in a 17-year-old white girl. *J Cutan Med Surg*. 2011;15:340-343.
4. Bedlow AJ, Otter M, Marsden RA. Axillary acne agminata (lupus miliaris disseminatus faciei). *Clin Exp Dermatol*. 1998;23:125-128.
5. Farrar CW, Bell HK, Dobson CM, Sharpe GR. Facial and axillary acne agminata. *Br J Dermatol*. 2003;149:1076.

6. Hillen U, Schröter S, Denisjuk N, Jansen T, Grabbe S. Axillary acne agminata (lupus miliaris disseminatus faciei with axillary involvement). *J Dtsch Dermatol Ges*. 2006;4:858-860.
7. Fox T. Disseminated follicular lupus (simulating acne). *Lancet*. 1878;112:5-76.
8. Radcliffe-Crocker H. *Diseases of the Skin*. 3rd ed. London: Lewis; 1903.
9. Hodak E, Trattner A, Feuerman H, et al. Lupus miliaris disseminatus faciei—the DNA of *Mycobacterium tuberculosis* is not detectable in active lesions by polymerase chain reaction. *Br J Dermatol*. 1997;137:614-619.
10. Al-Mutairi N. Nosology and therapeutic options for lupus miliaris disseminatus faciei. *J Dermatol*. 2011;38:864-873.
11. Jih MH, Friedman PM, Kimyai-Asadi A, Friedman ES, Hymes SR, Goldberg LH. Lupus miliaris disseminatus faciei: Treatment with the 1450-nm diode laser. *Arch Dermatol*. 2005;141:143-145.
12. Skowron F, Causeret AS, Pabion C, Viillard AM, Balme B, Thomas L. FIGURE: facial idiopathic granulomas with regressive evolution. Is Lupus miliaris disseminatus faciei still an acceptable diagnosis in the third millennium? *Dermatology*. 2000;201:287-289.