



Review Article

# Diagnosis and Safe Excision of Lumbar Synovial Cysts and Accompanying Pathology: A Perspective

Nancy E. Epstein, M.D.

Professor of Clinical Neurosurgery, School of Medicine, State University of New York at Stony Brook, New York, United States.

E-mail: \*Nancy E. Epstein, M.D. - nancy.epsteinmd@gmail.com



**\*Corresponding author:**

Nancy E. Epstein, M.D.,  
600 Old Country Rd. Suite 226,  
Garden City, NY 11530,  
United States.

nancy.epsteinmd@gmail.com

Received : 10 February 20

Accepted : 10 February 20

Published : 28 February 20

**DOI**

10.25259/SNI\_54\_2020

**Quick Response Code:**



## ABSTRACT

**Background:** Lumbar synovial cysts are often not sufficiently diagnosed prior to spine surgery. Utilizing both MR and CT studies is critical for recognizing the full extent/severity of these lesions.

**Methods:** In patients with chronic, acute, or subacute lumbar disease, obtaining both MR and CT studies is critical to correctly diagnose; disc disease, hypertrophy/ossification of the yellow ligament (OYL), stenosis, with/without degenerative spondylolisthesis, and/or synovial cysts (SC).

**Results:** MR T2 weighted images directly demonstrate hyperintensity within a SC. They initially cause lateral recess/caudad nerve root and/foraminal compromise, with larger extrusions causing significant lateral thecal sac, and far lateral/superior cephalad root compromise. CT 2 mm cuts often better demonstrate mid-vertebral level compression of cephalad nerve roots with/without SC calcification, along with the extent of mid-vertebral stenosis, hypertrophy/OYL, and DS. When CT studies directly document SC calcification, it alerts the surgeon to the increased potential risk of creating a cerebrospinal fluid fistula with full SC excision, and should prompt the adoption of alternative measures such as decompression/partial removal. Most critically, surgery for synovial cysts often warrants a 2-level laminectomy for fuller visualization of the cephalad and caudad nerve roots, and clearer differentiation of neural tissues from the large fibrotic SC capsule, to effect safer removal.

**Conclusions:** Preoperatively, establishing the full cephalad and cauda extent of lumbar synovial cysts with both MR and CT studies is critical. Anticipation and better visualization of the foraminal/far lateral and superior extent of these lesions often warrants more extensive multilevel laminectomies for thecal sac and both cephalad and caudad root decompression.

**Keywords:** Computed tomography, Degenerative spondylolisthesis, Magnetic resonance, Multilevel laminectomy, Noninstrumented fusion, Rare instrumented fusion, Safe surgery, Synovial Cysts: Lumbar stenosis

## INTRODUCTION

Both MR and CT studies are essential to preoperatively document the full extent of lumbar stenosis, hypertrophy/ossification of the yellow ligament (OYL), with/without degenerative spondylolisthesis (DS), and synovial Cysts (SC) [Tables 1 and 2; Figures 1-16].<sup>[1-15]</sup> The smaller, more typical unilateral SC occupies not only the lateral recess where they compress the caudad nerve root, but extend significantly foraminally, far laterally, and often superiorly to the mid-pedicle level where they impinge on the ipsilateral cephalad nerve root.<sup>[2]</sup> Due to double nerve root compression (e.g. at the L4-L5 level, there is compression of the cephalad L4 and caudad L5 nerve roots), two-level lumbar

This is an open-access article distributed under the terms of the Creative Commons Attribution-Non Commercial-Share Alike 4.0 License, which allows others to remix, tweak, and build upon the work non-commercially, as long as the author is credited and the new creations are licensed under the identical terms.

©2020 Published by Scientific Scholar on behalf of Surgical Neurology International

laminectomies are often warranted to adequately/more safely excise SC. Larger/massive SC may occupy the majority/entire spinal canal, resulting in not only nerve root, but also severe cauda equina compression.<sup>[2]</sup> SC occurring alone or in combination with DS, may be managed without fusions in many patients, particularly older individuals with multiple significant comorbidities. However, for those with evidence of instability, noninstrumented vs. instrumented posterolateral fusions (PLF) vs. rarely, interbody fusions (e.g. transforaminal lumbar interbody fusions (TLIF) particularly for spondylolisthesis/lysis or full unilateral facetectomies).

### **Anatomy of Synovial Cysts and Radiological Appearance on MR**

Pathoanatomically, synovial cysts are comprised of cystic dilatations of synovial sheaths that have directly extruded from the overlying facet joints into the spinal canal due to disruption of the facet joint capsule [Table 1].<sup>[5]</sup> On T2 weighted MR images, SC frequently demonstrate a hypointense outer perimeter indicative of an enlarged/hypertrophied, and/or ossified/calcified multi-layered fibrinous capsule.<sup>[5]</sup> The centers are inhomogeneously hyperintense reflecting the variegated soft synovial tissue intermixed with hemorrhage, and/or thick crank case fluid (e.g. rarely clear) [Table 1].<sup>[2,5]</sup>

### **Radiological Diagnosis of Synovial Cysts with MR**

MR studies are usually the first and best examinations performed to identify lumbar synovial cyst extrusions in conjunction with lumbar stenosis, OYL, with/without DS (e.g. some cite a 40% incidence of DS with SC) [Figures 1,3,5,6,9,10 and 12] [Tables 1 and 2].<sup>[1,2,5,8,10,12,15]</sup> SC occur typically at L4-L5, followed by the L5-S1, L3-L4, and L2-L3 levels.<sup>[2]</sup> Lateral/foraminal/far lateral SC contribute to ipsilateral thecal sac and dual cephalad/caudad root compression, while larger central/dorsolateral lesions often fill the spinal canal resulting in cauda equina syndromes.

### **Limitations of MR**

MR axial 5 mm thick sections are focused at the disc space levels. Typically, one image is taken above, another at, and the final section just below the interspace. A limitation of axial MR studies is that they may mis/underrepresent mid-level vertebral pathology [Figures 1,5,10 and 12]. Here, sagittal/parasagittal 5 mm MR images may detect/document the missed mid-level disease [Figures 3,6 and 9].

### **Utility of CT Examinations in Diagnosing Lumbar Stenosis, OYL, DS, and SC**

However, the non-contrast CT 2 mm axial and sagittal scans may better demonstrate mid-level vertebral disease

along with stenosis, OYL, DS, spondylolisthesis/lysis, and SC, especially when considering surgery [Tables 1 and 2] [Figures 4,7,8,11,13 and 16].<sup>[1,2,5,8,10,12,15]</sup> Further, CT studies directly show ossification/calcification of SC capsules, warning of probable significant dural adherence, and prompting surgeons to consider decompression rather than full excision of SC to avoid intraoperative dural tears.

### **Case: When MR/CT Examinations are Interpreted as Disc, Missing Synovial Cyst**

A 77-year-old female presented with several weeks of increasing left lower extremity neurogenic claudication/radiculopathy accompanied by proximal left leg weakness (2/5), and numbness (pin loss L2-L3 distributions) [Table 2].<sup>[15]</sup> The preoperative MR and CT studies both “showed” L2-S1 lumbar stenosis, and a “typical” large left L2-L3 herniated disc with inferior migration to the mid-pedicle level.<sup>[15]</sup> At surgery, the “disc” proved to be a massive, extruded left L2-L3 synovial cyst. Following the L2-S1 laminectomy, no fusion was performed as there was no documented instability. Postoperatively, the patient was neurologically intact, and remained so two years later.

### **Pain Management (PM) Specialists’ Fail to Manage Lumbar Synovial Cysts**

The 2012, Epstein and Baisden reviewed the SC literature; it showed 50-100% failure rates for PM attempts at synovial cyst “rupture/aspiration” under fluoroscopic/CT-guidance while performing ESI (e.g. ESI with no documented long-term efficacy) [Table 1].<sup>[5]</sup> The PM who perform these procedures, typically including radiologists, physiatrists, and anesthesiologists, are not trained in both how to perform a neurological exam (except physiatrists), and adequately read/interpret MR/CT studies (except radiologists).<sup>[2,5]</sup> PM typically perform ESI/SC “aspiration/rupture” attempts x 3 over 3 months, thus often critically delaying necessary spine surgery. Further, they also subject patients to dural tears, contributing to the risks of; adhesive arachnoiditis, infections, spinal headaches, intracranial hypotension, and others.<sup>[5]</sup> Alternatively, the surgical resection of SC is highly effective in resolving back (91.6-92.5%), and radicular pain (91.1-91.9%).

### **Case; PM Fail to “Rupture/Aspirate” Synovial Cyst Critically Delaying Surgery**

PM followed an elderly male (e.g. >75) for over 6 months with progressive low back pain, neurogenic claudication, and radiculopathy [Table 2].<sup>[12]</sup> At 3 months, PM obtained an MR showing a massive L3-L4 synovial cyst with severe stenosis at L3-L4 and DS, and moderate L2-L3 stenosis. Despite continued clinical worsening, PM chose to perform 3 ESI with

Table 1: Synovial Cyst Articles 2004-2016.

Author Journal Year	Study Design	History Diagnostic Studies	History Diagnostic Studies	Surgery	Complications Outcomes Conclusions
Epstein Spine 2004 <sup>[1]</sup>	Lumbar Lam SC/ SS or DS Outcome Short-Form 36 Evals	45 Lam SC /SS (45 (3.8 levels) 35 Lam SC/SS/DS (3.5 levels) LBP 40 vs. 33 R 43 vs. 33 INC 41vs. 26	2 years postop: <u>SC/SS Slip</u> 5/45 Lam <u>SC/SS/DS &gt; slip</u> 2/11 (Grade II)	Good/excellent 58% (45) vs 63% (35) SF-36 <u>Improvement Physical</u> Function +45vs. +38 points Both-Moderate Improvement	Conclusion; Consider initial fusion with SC-reflect disruption of facet joints/ Degree instability
Epstein JSDT 2004 <sup>[2]</sup>	Review Diagnosis Surgery Outcomes of Lumbar SC	SC: arthritic disruption facet <u>DS 40% with SC</u> Patients age 60's LBP, R, INC	SC Levels L4-L5 L5-S1 L3-L4 L2-L3	Surgery; Laminotomy, HemiLam, Lam	Lam NI PLF vs. Instrumented Fusions
Epstein JSDT 2007 <sup>[3]</sup>	Dural Tears DT:Incidental 10/110 Geriatric Lam NI PLF	<u>Older DT:</u> 74 yo DT/69 yo No DT <u>DT &gt; Lam</u> <u>Surgery:</u> 5.5 DT vs. 5.0 No DT	<u>&gt;NI PLF Levels</u> 1.8 DT vs. 1.6 No DT	Outcomes; SF-36 Improved 4-5 Health Scales 1 <sup>st</sup> yr 3 Factors > Risk DT: 10/10 Marked OYL	3 Factors > Risk 5/10 SC/severe OYL (vs. 8/100 SC without DT) 2/10 scar DT (vs. 10% without DT)
Epstein TSJ 2008 <sup>[4]</sup>	60 Pts. Avg. 5.4 Level Lam +1-2 Level NI PLF Using Lamina Autograft Vitoss (B-TCP)	60 Patients Avg. 70 yo Outcomes Odom's Criteria SF-36 Followed 2 postop yrs	<u>Pathology 60 SS</u> 46 OYL 20 Discs <b>8 SC</b> 48 DS 2 Lysis 10 Deg. Scoliosis	9 (15%) Pseudarthrosis Odom's Criteria 28 Excellent 23 Good 5 Fair 4 Poor	SF-36 Data Improved 6/8 Health Scales in ALL patients
Epstein SNI 2012 <sup>[5]</sup>	Efficacy Surgery vs. SC Rupture/ Aspiration	Pathology: Gelatinous, Non Aspirable Crank Case Fluid/Thick Fibrous Capsule	Failed Aspiration Rates 50-100%	Surgery; Resect Lam Resolved LBP 91.6- 92.5% R pain 91-91.9%	Best Outcomes SC Surgery High Failure Rate Aspiration or Rupture
Epstein SNI 2015 <sup>[6]</sup>	Nanoss vs. Vitoss Bone Graft Expander Lam-PLF NI Pathology: SS/OYL, SC, DS, Discs	Fusion Mass Autograft Lamina+ (213) Vitoss vs. (45) Nanoss ; Both with BMA	Vitoss Lam 4.6 Levels 1.3 PLF Nanoss Lam 4.5 Levels 1.2 LPLF	Fusion Documented X-rays/2D-CT 6 mos -1 yr Near =Time Fuse <u>5.3 mos Vitoss (98.6%)</u> Pseud. 1.4% 2 Seroma 2 Infections	<u>4.8 mos Nanoss</u> <u>(100%)</u> Pseud 0% 0 Seroma and 0 Infection
Epstein SNI 2015 <sup>[7]</sup>	Rate CSF Fistulas /DT Lumbar SS Review Range 3-27%	2000-2015 Incidence DT 336 pts 4.7 Lam 1.4 NI PLF	Risk DT: 5 OYL 3 Scar (postop) 7 ESI 6 SC 3 Intradural Tumors	Repair DT: 7-0 Gore-Tex Sutures; Microdural Staples; Muscle Patch Graft; Fibrin Sealant or Glues Duragen	DT 24 (7.14%)/336 Pts. 4.2% DT when Omit ESI and Intradural Tumors
Epstein SNI 2016 <sup>[8]</sup>	Efficacy NI PLF 336 Multilevel Lam SS vs.	4.7 Level Lam 1.4 Level NonInstr. PLF	2 <sup>nd</sup> Surgery Required Avg.	Reoperations 7 DS Grade I	<u>Conclusion</u> <u>9 (2.7%) Reop NI</u> <u>PLF</u>

(Contd...)

Table 1: (Continued).

Author Journal Year	Study Design	History Diagnostic Studies	History Diagnostic Studies	Surgery	Complications Outcomes Conclusions
	Preop SS/DS 195 Grade I 67 Grade II 154 Discs 66 SC	Avg. Age 66.5 Followed mean 7.1 yrs <u>9 Reop ASD</u> Average 6.3 yrs postop	4.8 Level Lam 1.1 Level PLF	1 DS Grade II 2 Discs 1 Synovial Cyst	Other studies+ Instrumentation Reop Rates up to 80% at 5 yrs postop
Lam=Laminectomy, MR=Magnetic Resonance Image, CT=Computed Tomography, NSAID=Non-steroidal anti-inflammatories, yo=Year Old, F=Female, M=Male, LE=Lower Extremity, INC=Neurogenic Claudication, DS=Degenerative Spondylolisthesis, LS=Lumbar Stenosis, CAD Stents=Cardiac Stents, LV=Left Ventricular, FLD=Far Lateral Discs, FOR=Foraminal, IONM=Intraoperative Neural Monitoring, ESI=Epidural Steroid Injections, NSGY=Neurosurgery, LAM=Laminectomy, SC=Synovial cyst, OYL=Ossification Yellow Ligament, instrumented PLF=Posterolateral fusion, TLIF=Transforaminal Lumbar interbody Fusion BMA=Bone Marrow Aspirate, NI=Noninstrumented, SS=Spinal Stenosis Avg.=Average, Reop=Reoperation, B-TCP=Beta TriCalcium Phosphate, LBP=Low Back Pain, R=Radiculopathy, SF-36=Short Form-36, yo=Years Old, mos=Months, Pts.=Patients, SNI=Surgical Neurology International, TSJ=-The Spine Journal, JSDT=Journal Spinal Disorders Techniques, yrs=Year(s)					

3 failed attempts at SC “rupture/aspiration” over these final 3 months [Table 2].<sup>[12]</sup> When ultimately seen by neurosurgery, the patient had a cauda equina syndrome with repeat MR and a new CT study confirming the prior findings without a documented decrease in the size of the SC. Following a L2-L4 laminectomy, the patient fully recovered without further sequelae.

#### More Extensive “Open” Surgery for Safe Synovial Cyst Excision

A 2-level decompression simultaneously provides safe excision of SC, along with decompression of bilateral stenosis/OYL with/without DS. This is typically warranted due to SC’ foraminal, far lateral, and superior extension [Tables 1 and 2].<sup>[1-15]</sup> The decompression, therefore, initiated at the superior level, allows for full visualization/decompression of the cephalad nerve root, while the inferior extension of the laminectomy facilitates decompression of the lateral thecal sac and inferiorly exiting nerve root.

#### Undercutting Laminectomy/Decompression of Stenosis/OYL with/without DS/SC

Using an angled Kerrison rongeur, performing an undercutting laminectomy for SC/stenosis/OYL/DS decompression/excision involves working under an operating microscope from the opposite side of the table; further the patient is rotated/angled away from the surgeon. This technique largely provides adequate exposure while facilitating preservation of the overlying laminae/facets, use; maintaining stability, and averting fusion. It is essential to attain sufficient exposure to avoid the minimally invasive (MI) (e.g. including TLIF) increased complications that too often include; inadvertent neural/dural injury, and incomplete cyst removal.

#### Documentation of Location/Level of Synovial Cyst Removal with 2 X-rays

When opening at the level of a SC, the lesion may not be readily apparent. It is imperative to obtain two intraoperative radiographs to confirm the correct level; first, a cross table lateral X-ray with a clamp on the correct interspinous ligament, and second, placing a Penfield elevator in the correct disc interspace (e.g. not just in the canal). This is how to both confirm the level of the SC extrusion, as well as to avoid wrong-level surgery.

#### Surgery for Multilevel Stenosis/OYL, Synovial Cysts (SC), and a Foraminal (FOR)/Far Lateral Disc (FLD)

A patient (2018) presented with L2-L5 stenosis/OYL, a left L3-L4 foraminal (FOR)/far lateral disc (FLD), and bilateral L3-L4/L4-L5 synovial cysts [Table 2].<sup>[13]</sup> Utilizing the operating microscope, and performing L2-L5 laminectomies with medial facetectomy/foraminotomy, and undercutting the laminae/facet joints, avoided the need for fusion.

#### Fusion vs. No Fusion for Lumbar Synovial Cysts with Other Pathology

Fusion options following lumbar decompressions include; non-instrumented posterolateral fusions (PLF) vs. instrumented PLF, or rarely TLIF [Figure 16] [Table 2].<sup>[13]</sup>

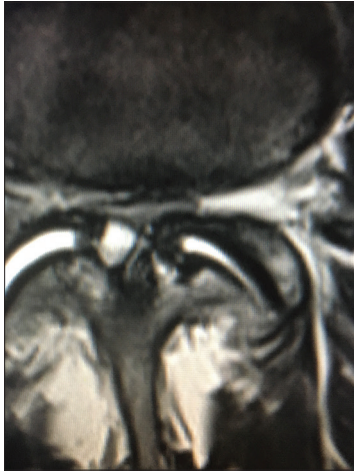#### 2004: Recommended Possible Fusion for SC with Lumbar Stenosis/OYL with/without DS

In a 2004 study, Epstein evaluated the outcomes/frequencies of instability 2 years after multilevel laminectomies for stenosis/OYL (average 3.8 levels: 45 patients) with SC vs. multilevel laminectomies for stenosis/OYL (average 3.5 levels: 35 patients) with

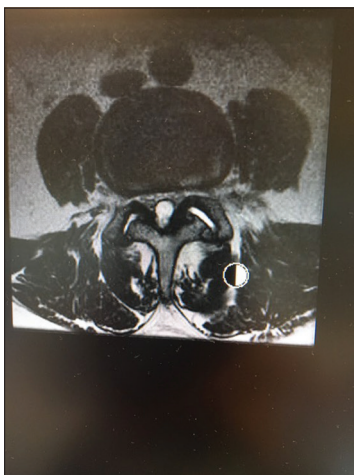
**Table 2:** Synovial Cyst Articles 2017-2019.

Author Journal Year	Study Design	History Diagnostic Studies	History Diagnostic Studies	Surgery	Complications Outcomes Conclusions
Epstein SNI 2017 <sup>[9]</sup>	59 Lam NI PLF <u>Fusion Mass</u> Lam Autograft Nanoss BMA	Surgery for SS, DS, FOR/FLD Synovial Cysts Facet Resection <u>Avg. age</u> 66.1 48 Osteoporosis 14 Obesity' 13 Morbid Obesity	<u>MR/CT Stenosis/OYL</u> 51 DS 2 Lysis 32 SC 11 Discs 10 FLD Followed 3.12 yr	4.0 LAM 1.2 PLF <u>Fused XR/CT</u> 4.9 mos Postop 97% Fused <u>2 Failed Fusion</u> Osteoporosis Morbid Obesity Smokers	<u>Lam+NI PLF 97% Fusion Rate</u> Lam Autograft Nanoss+BMA for Lumbar Stenosis+ DS, FOR/FLD, SC, Facet resections No Reoperations Multilevel SS/DS require Lam vs. Lam + NI PLF vs. Instrumented fusion (PLF/TLIF)
Epstein SNI 2017 <sup>[10]</sup>	Nursing Review Lumbar Lam+ DS <u>MR/CT</u> SS/DS, OYL, Discs, SC	DS Most at L4-L5, then L3-L4 and L5-S1 F vs. M Symptoms: R, INC, Cauda Equina	Surgery Grade I-II DS:Lam vs. Lam +NI or Instrumented PLF vs. TLIF	No fusion/NI PLF: Older pts. Osteoporosis Fused with LAM autograft + bone graft expander+BMA	4 Postop DT; 1 Recurrent disc 3 Huge SC/Calcified through dura
Epstein SNI 2017 <sup>[11]</sup>	Tisseel Used Hemostasis Lam 2-3 vs. 4-6 Levels	<u>58 2-3 Level</u> Lam: 48 Discs, 20 SC, 1 DS <u>79 4-6 Level Lam:</u> 45 SC, 39 Discs, 26 DS	Reduced Drain <u>Drain 2-3 Lam</u> 87.6 (1), 59.2 cc (2 days); Home 2 <sup>nd</sup> day	<u>Reduced Drain 4-6 level Lam:</u> 156.6 (1), 115.8 (2), 85.7 cc (3 days); Home days 3 and 4	
Epstein SNI 2018 <sup>[12]</sup>	Elderly M 6 mos INC/R 3 mos ago Cauda Equina Syndrome MR Huge SC Filling Spinal Canal L3-L4	Pain MD (Anesthesia) obtained MR 3 mos ago: Huge L3-L4 SC Marked Stenosis Moderate Stenosis L2-L3	For 3 mos Pain MD Treated with 3 ESI (1/month) Plus Attempted SC Aspiration/ Rupture	Seen by Neurosurgery had Cauda Equina Syndrome New MR/CT Confirmed Prior Findings	Surgery Delayed 3-6 mos. Lam L2-L4; Resection of Huge SC; Decompress Stenosis L2-L3, L3-L4; No fusion Postop: Regained Normal Function At Surgery Used Undercutting Technique +IONM +Microscope Avoid DT
Epstein SNI 2018 <sup>[13]</sup>	Manage Multilevel Stenosis/OYL L34/L45 SC Left L34 FOR/FLD	MR/CT Multilevel SC+ FOR/FLD	Surgery: Lam L2-L5 SS; Huge Left L3-L4 FOR/FLD, Bilateral SC L3-L4/ L4-L5	At Surgery X-ray Marker in Disc Space No Fusion No Instability	At Surgery Used Undercutting Technique +IONM +Microscope Avoid DT
Epstein SNI 2019 <sup>[14]</sup>	65 yo M 6 mos of 2- Block INC Exam Normal	<u>Cardiac Risks</u> 5 CAD-Stents <u>Last 2 Years</u> Bovine Cardiac Valve; Repair LV Aneurysm	<u>Cardiac Meds:</u> Full ASA 325 mg Clopidogrel 75 mg po bid	MR /CT; Moderate/Severe LS, L45 DS, Bilateral SC L45, L34	<u>Multiple Spine Surgeons Offered:</u> TLIF L3-L4/L4-L5 Epstein Offered NO SURGERY Medical Treatment Excellent Outcome MR/CT Failed to Diagnose Huge Left L2-L3 SC
Epstein SNI 2019 <sup>[15]</sup>	Case 77 yo F L2-S1 SS, OYL, Huge Left L2-L3 Disc	Misdiagnosed MR: Disc L23-Left/ inferior migration to mid pedicle	Misdiagnosed on CT; Disc L23 Left with inferior migration to mid pedicle level	Surgery: Lam L2-S1 Excision massive left L2-L3 SC	

Lam=Laminectomy, MR=Magnetic Resonance Image, CT=Computed Tomography, NSAID=Non steroidal anti-inflammatories, yo=Year Old, F=Female, M=Male, LE=Lower Extremity, INC=Neurogenic Claudication, DS=Degenerative Spondylolisthesis, LS=Lumbar Stenosis, CAD Stents=Cardiac Stents, LV=Left Ventricular, FLD=Far Lateral Discs, FOR=Foraminal, IONM=Intraoperative Neural Monitoring, ESI=Epidural Steroid Injections, NSGY=Neurosurgery, LAM=Laminectomy, SC=Synovial cyst, OYL=Ossification Yellow Ligament, instrumented PLF=Posterolateral fusion, TLIF=Transforaminal Lumbar interbody Fusion BMA=Bone Marrow Aspirate, NonInstr.=Noninstrumented, SS=Spinal Stenosis Avg.=Average, Reop=Reoperation, B-TCP=Beta TriCalcium Phosphate, LBP=Low Back Pain, R=Radiculopathy, SF-36=Short Form-36, yo=Years Old, mos.=Months, Pts.=Patients, SNI=Surgical Neurology International, yrs=Year(s)

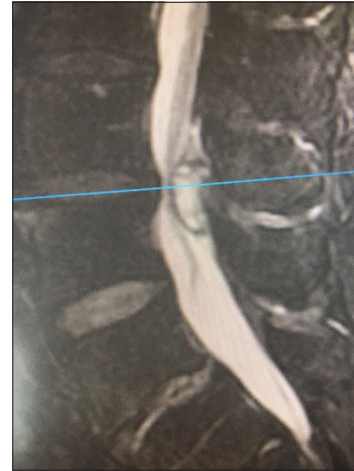

**Figure 1:** T2 axial weighted MR demonstrating extrusion of a synovial cyst originating from the right facet joint (also containing a high T2 weighted signal) at the disc space level. This resulted in marked right root and severe dorsolateral thecal sac/cauda equina compression. Also note fluid in both facet joints.

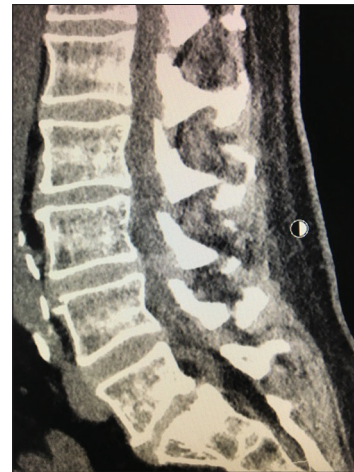

**Figure 2:** Large central synovial cyst extrusion resulting in diffuse bilateral thecal sac/cauda equina compression. Note on this study there are hyperintense signals within both facet joints, and it is difficult to determine whether this cyst originated from the right or left facets. Further, observe the hypertrophy/ossification (hypointense signal) of the yellow ligament.

synovial cysts (SC), and degenerative spondylolisthesis (DS) [Table 1].<sup>[11]</sup> Increased olisthy (to Grade I) was seen postoperatively in 5 of 45 of the former no-DS patients, while Grade I olisthy progressed to Grade II olisthy for 11 of 35 of those with preoperative DS. Interestingly, both groups showed nearly comparable moderate postoperative improvement (e.g. good/excellent results (58% and 63% using Odom’s Criteria), and improvement in SF-36 scores (e.g. Physical Function Scale +44 and +38 points respectively). The conclusion was; “As synovial cysts reflect disruption of the facet joint and some degree



**Figure 3:** T2-weighted Parasagittal MR demonstrating L3-L4 dorsolateral extruded synovial cyst. There is a hypointense rim around the hyperintense cyst/theal sac likely indicative of a hypertrophied and partially ossified capsule.

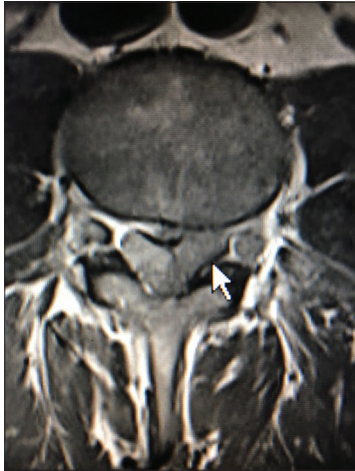

**Figure 4:** Parasagittal CT at the L3-L4 level (same patient as Figure 3) demonstrating dorsolateral compression from the extruded synovial cyst that is partially ossified/calcified.

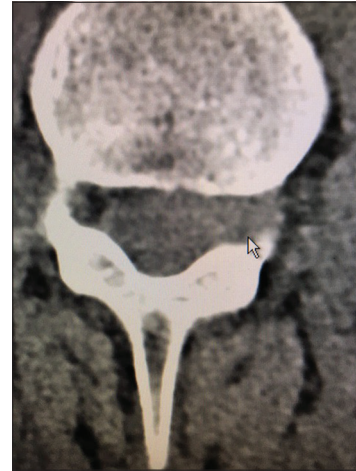of instability, primary fusion should be considered to improve operative results for patients in both categories.”

**2017: No Fusion Typically Required for Laminectomy Stenosis/OYL with/without SC/DS**

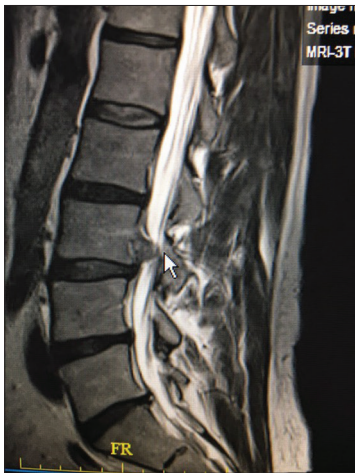In 2017, Epstein documented no need for fusion following 2-3 level (58 patients) vs. 4-6 level (79 patients) lumbar laminectomies for spinal stenosis/OYL with/without SC, and DS. [Table 2].<sup>[10]</sup> For those undergoing 2-3 level laminectomies, all 58 had stenosis/OYL, while 48 additionally had herniated discs, 20 (34.4%) additionally had synovial cysts, and one had DS. For the 79 patients having 4-6 level laminectomies, all 79 had stenosis/OYL, 45 (56.9%) additionally had synovial cysts, 39 had lumbar



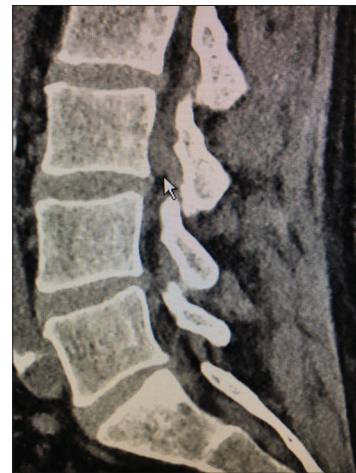**Figure 5:** Massive left L3-L4 extruded synovial cyst (documented intraoperatively) on this T1 weighted axial MR filling the lateral recess and extruding superiorly mimicking a disc herniation.



**Figure 7:** This non-contrast axial CT scan (soft tissue) showed a large left-sided, partially hyperdense foraminal/superiorly extruded synovial cyst.



**Figure 6:** In the same patient as Figure 5, this patient on the T2 parasagittal MR had a massive superiorly extruded synovial cyst that mimicked a disc herniation extending toward the mid-vertebral/parapedicular level.



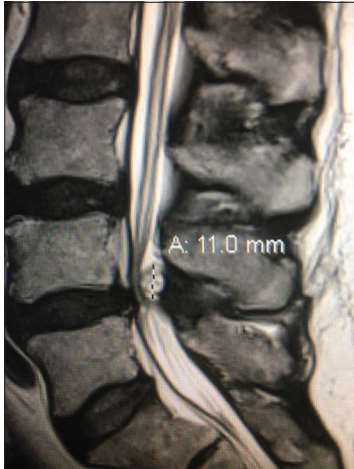
**Figure 8:** The parasagittal 2D-CT study (soft tissue) showed a left-sided hypodense (e.g. partially ossified) synovial cyst extrusion at the level of the disc space with hyperdense additional tissue seen extending cephalad to the mid vertebral level.

discs, and 26 had DS. Despite 26 of the latter 79 patients undergoing 4-6 level laminotomies with preoperative DS, none developed postoperative instability requiring fusion [Table 2].<sup>[10]</sup> This represented a significant change in opinion, regarding no necessity for fusion, compared to the 2004 study.

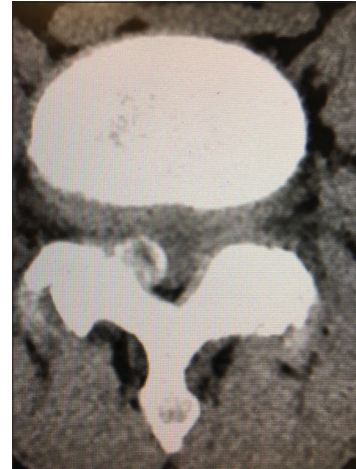**Tisseel: Promotes Hemostasis Following Lumbar Laminectomies**

Tisseel (Baxter International Inc., Westlake Village, CA, USA), a fibrin sealant, was also routinely used to minimize postoperative bleeding, facilitate hemostasis following the 2-3 (58 patients) vs. 4-6 (79 patients) level lumbar

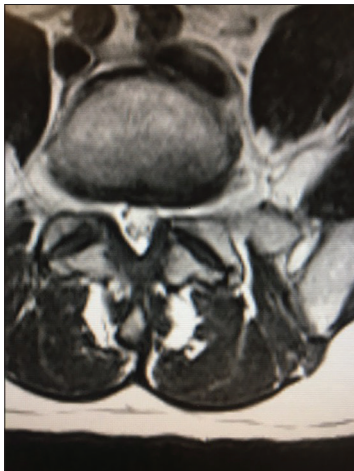laminectomies for stenosis/OYL with/without SC, and DS [Table 2].<sup>[11]</sup> For both procedures, the postoperative drainage was reduced. For the 2-3 level procedures, the average drainage was 87.26 cc, and 59.62 cc on postoperative days 1 and 2 respectively, allowing for routine discharged. For those undergoing 4-6 level laminectomies, average drainage was 156.63 cc.(79 patients), 115.8 cc. (79 patients), 85.7 cc (44 patients), and 93.6 cc (6 patients) respectively on postoperative days 1-4; discharges followed at postoperative day 2 (29 patients), day 3 (44 patients), and day 4 (6 patients) Further, Tisseel was used to treat 3 dural tears (DT) attributed to calcified synovial cysts, and one DT due to scar associated with a recurrent disc out of the box 79 patients undergoig 4-6 level decompressions.



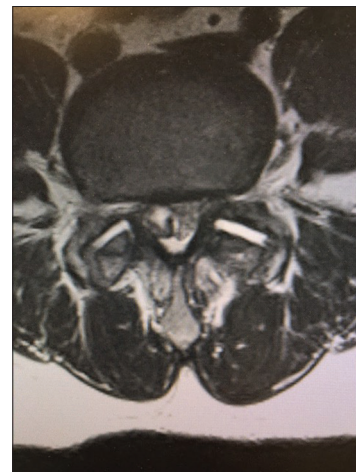**Figure 9:** Large dorsolateral synovial cyst on a T2 parasagittal MR study measuring 11 mm in the cephalad-caudad dimension. Notes its origin from the L4-5 level with cephalad extension beyond the mid-vertebral level. The cyst itself exhibits multiple inhomogeneous densities indicative of the variegated solid contents, and minimal actual crank-case fluid.



**Figure 11:** On this axial non-contrast CT scan, at the L4-L5 level, the capsule of the synovial cyst on the right side of the spinal canal is ossified with central inhomogeneous and hypodense components. Such synovial cysts are often comprised of multiple layers of dense fibrous ossified capsule, and may contain minimal amounts of actual fluid (e.g. crank case fluid or more typically hypodense soft tissue).



**Figure 10:** On the axial T2 weighted MR scan there is a mildly hyperintense structure on the left and the right sides in continuity with the facet joint indicating likely bilateral synovial cysts rather than just hypertrophy of the yellow ligament. On the left, this results in mild/moderate compromise of the nerve root in the lateral recess.



**Figure 12:** The same patient as in Figure 11 had a large right-sided synovial cyst at the L4-L5 level showed marked thecal sac and right L5 root compression. On the axial T2 weighted MR, the lesion's perimeter is hypointense (e.g. consistent with ossification) while its contents are variegated (e.g. containing hyperintense and hypointense components indicative of a combination of calcified/not calcified soft tissue and crank-case fluid).

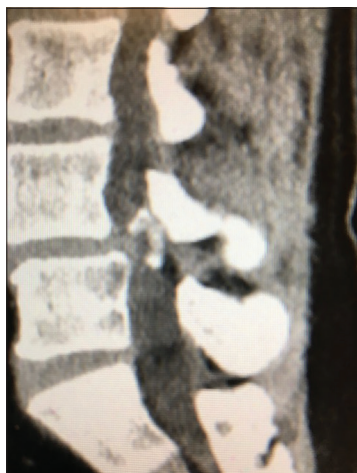### Noninstrumented PLF for Laminectomy with Stenosis/OYL with/without SC/DS Using Different Bone Graft Expanders

#### Non-Instrumented PLF Rates Using Vitoss

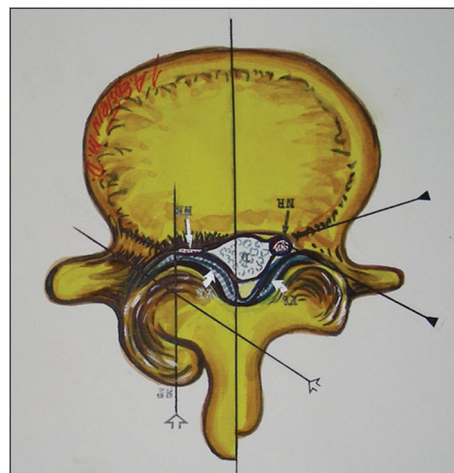
Select patients undergoing decompressive lumbar laminectomies for stenosis/OYL, foraminal/far lateral discs, synovial cysts, and DS requiring full facetectomy with major comorbidities may warrant noninstrumented posterolateral fusions (PLF) [Tables 1 and 2].<sup>[4,8,9]</sup> In 2008, in 60 patients

averaging over 70 years of age underwent average 5.4 level lumbar laminectomies and 1-2 level noninstrumented PLF; This included 48 DS, 10 degenerative scoliosis, 8 patients with synovial cysts, and 2 with spondylolysis [Table 1].<sup>[4]</sup> The fusion mass consisted of lamina autograft, Vitoss/B-TCP (Orthovita, Malvern, PA, USA), and bone marrow aspirate (BMA). The fusion rate was 85% based on dynamic X-rays/CT studies obtained up to 2 years postoperatively; only





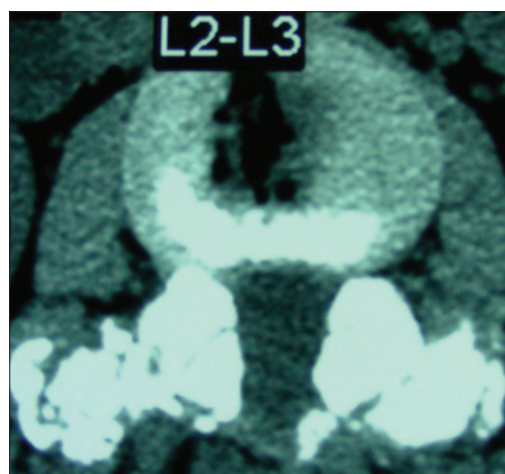
**Figure 13:** Parasagittal CT image of L4-L5 partially calcified/ossified synovial cyst filling the right side of the spinal canal.



**Figure 15:** This axial illustration by Joseph A. Epstein, M.D. demonstrates marked right-sided facet hypertrophy with hypertrophy of the yellow ligament resulting (short thick arrows) in use severe compression of the nerve root (thin white arrow) in the lateral recess. In many similar cases. There is also an accompanying component of synovial cyst extrusion as well.



**Figure 14:** In this illustration by Joseph A. Epstein, M.D., the right side shows a multilevel hemilaminectomy that would potentially be used for excision of an L4-L5 synovial cyst (e.g. with lateral, foraminal, far lateral superior extension compressing the L4, and L5 roots), as long as there is also significant stenosis L3-S1 requiring decompression.



**Figure 16:** In some cases, particularly where there is degenerative spondylolisthesis at the level of a synovial cyst extrusion, one might consider performing a non-instrumented posterolateral fusion as shown here at the L2-L3 level. Note the marked fusion mass consisting of autologous bone combined with Vitoss/BMA placed posterolaterally and bilaterally over the transverse processes at the L2-L3 level.

1 patient of the 15% with pseudarthrosis required secondary fusion. He was a mid-fifties vasculopathy who had to immediately go back on Aspirin therapy.

In a second study in 2016, 336 patients underwent multilevel laminectomies with noninstrumented multilevel fusions using Vitoss/B-TCP/lamina autograft/BMA [Table 1].<sup>[8]</sup> Patients averaged 66.5 years of age, and had average 4.7 level lumbar laminectomies, and 1.4 level noninstrumented fusions addressing; stenosis/OYL (336), DS (Grade I (195 patients), Grade II spondylolisthesis (67 patients), disc herniations (154 patients), and/or synovial cysts (66 patients). Over the average follow-up of 7.1-years, only 9 (2.7%) patients required secondary surgery an average of 6.3 years postoperatively; 7

developed Grade I DS, one progressed to a Grade II DS, 2 to new disc herniations, and/or 1 a synovial cyst.

#### ***Noninstrumented Fusion Rates for Vitoss vs. Nanoss***

In 2015, Epstein compared the relative efficacy of Vitoss (213 patients) vs. Nanoss (45 patients; Regeneration Technologies Corporation: RTI, Alachua, FL, USA) using comparable noninstrumented PLF techniques [Table 1].<sup>[6]</sup> The average times/rates for fusion based on dynamic X-rays/2-3D-CT studies were nearly comparable; Vitoss (5.3 months;

98.6%) vs. Nanoss (4.8 months: 100%), with pseudarthroses respectively occurring in 3 (1.4%) vs. 0 patients.

### ***Noninstrumented Fusion Using Nanoss Alone***

Subsequently, Epstein (2017) assessed 59 patients undergoing average 4.0 level laminectomies and average 1.2 level noninstrumented fusions for stenosis/OYL, DS (51 patients), synovial cysts (32 patients), and other pathology using Nanoss (RTI Surgical Alachua, FL, and USA) with lamina autograft/BMA [Table 2].<sup>[9]</sup> Postoperative dynamic X-rays and CT studies documented a 97% fusion rate occurring at an average of 4.9 mos. postoperatively. Notably, the 2 (3%) patients with pseudarthrosis had severe osteoporosis, were morbidly obese, and were smokers; neither, nevertheless, was sufficiently symptomatic to require additional surgery.

### **Frequency of Dural Tears (DT) with Lumbar Synovial Cyst Surgery**

The presence of synovial cysts increases the risk of intraoperative dural tears (DT) (range 3-27%) during multilevel lumbar laminectomies with/without noninstrumented vs. instrumented lumbar fusions [Table 1].<sup>[3,7]</sup> In a 2007 retrospective analysis of 110 patients undergoing multilevel laminectomies with noninstrumented PLF, Epstein identified DT in 10 of the 110 patients [Table 1].<sup>[3]</sup> These patients averaged 74 years of age (e.g. vs. 69 seen for those without DT), and also correlated with slightly more extensive laminectomies (5.5 with DT vs. 5.0 without DT), and noninstrumented PLF (1.8 vs. 1.6 levels). Additionally, 3 factors positively correlated with DT; 10 DT with severe OYL, 5 of 10 patients with synovial cysts (e.g. vs. 8 synovial cysts out of 100 without DT), and 2 with prior operative scar (e.g. vs. 10 of 100 patients with scar but without DT). Next, in 2015, Epstein evaluated the incidence of DT for 336 patients undergoing average 4.7 level laminectomies, and 1.4 level noninstrumented PLF [Table 2].<sup>[7]</sup> DT were attributed to (in descending order); preoperative epidural spinal injections (ESI) (7 patients), synovial cysts with marked dural adhesions (6 patients), severe OYL extending through the dura (5 patients), postoperative scar (3 patients), and intradural tumors (3 patients). The overall frequency of DT was 24 (7.14%) out of 336 patients, but this number was readily reduced to 4.2% by eliminating preoperative ESI, and intradural tumors.

### ***Recommended Repair Techniques for DT***

Recommended repair techniques for DT include using 7-0 Gore-Tex (Newark, Delaware, USA) sutures (e.g. where the needle is smaller than the suture itself, thus filling the needle holes), micro-dural staples (1.4 mm), muscle patch/bovine pericardial grafts, application of Duragen (Integra LifeSciences, Hawthorne, NY, USA), and use of a fibrin

sealant (e.g. safely used Tisseel; Baxter International Inc., Westlake Village, CA, USA).

### **Intraoperative Neural Monitoring; Critical Adjunct to Lumbar Surgery**

Extremely useful in performing multilevel laminectomies with/without non instrumented fusions is intraoperative neural monitoring. It typically consists of electromyography (EMG: some also including sphincteric monitoring), and somatosensory evoked potential monitoring (SEP); the EMG will signal root and/or sphincter compromise, while SEP may indicate significant thecal sac/cauda equina compression. Anesthesia's utilization of TIVA (total intravenous anesthesia) best protects the quality of these continuous EMG/SEP recordings [Tables 1 and 2].<sup>[1,2,4,6,8, 9,10]</sup>

### **When to Say No to Surgery Due to Major Comorbidities**

Not all patients with significant MR/CT documented spinal stenosis, OYL with/without synovial cysts and/or DS are appropriate surgical candidates. Major comorbidities must be carefully taken into consideration, as the risks of surgery may outweigh the benefits. The following case report illustrates this point. A 65-year-old male presented with 6 months of 2-block neurogenic claudication, but a normal neurological exam [Table 2].<sup>[14]</sup> MR/CT studies documented multilevel L2-S1 stenosis/OYL, Grade I L4-L5 DS, and bilateral multilevel L3-L4, and L4-L5 synovial cysts. However, he had required over 5 stents placed within the last five years, and 2 years ago, underwent placement of a bovine aortic valve, and left ventricular wall aneurysmal repair; he still required full-dose ASA (325 mg/day) and Clopidogrel 75 mg po bid therapy. Due to these multiple comorbidities and the normal physical exam, the patient was referred for conservative management (e.g. exclusive of ESI or other invasive procedures).

### **CONCLUSIONS**

Lumbar synovial cysts should be more fully diagnosed preoperatively utilizing both MR and CT to demonstrate foraminal/far lateral, and superior compression of the cephalad, cauda nerve roots, and lateral thecal sac [Tables 1 and 2]. Surgery for SC with accompanying stenosis/OYL with/without DS, typically requires 2 or more-level decompressions, avoiding the higher risks of neural/dural injury seen with inadequate exposures provided by minimally invasive approaches.<sup>[1-15]</sup>

### **Declaration of patient consent**

Not required as there are no patients in this study.

**Financial support and sponsorship**

Nil.

**Conflicts of interest**

There are no conflicts of interest.

**REFERENCES**

1. Epstein NE. Lumbar laminectomy for the resection of synovial cysts and coexisting lumbar spinal stenosis or degenerative spondylolisthesis: an outcome study. *Spine (Phila Pa 1976)*, 2004; 1: 29(9): 1049-55; discussion 1056.
2. Epstein NE. Lumbar synovial cysts: a review of diagnosis, surgical management, and outcome assessment. *J Spinal Disord Tech*, 2004;17(4):321-5.
3. Epstein NE. The frequency and etiology of intraoperative dural tears in 110 predominantly geriatric patients undergoing multilevel laminectomy with noninstrumented fusions. *J Spinal Disord Tech*, 2007; 20(5):380-6.
4. Epstein NE. An analysis of noninstrumented posterolateral lumbar fusions performed in predominantly geriatric patients using lamina autograft and beta tricalcium phosphate. *Spine J*, 2008; 8(6):882-7.
5. Epstein NE, Baisden J. The diagnosis and management of synovial cysts: Efficacy of surgery versus cyst aspiration. *Surg Neurol Int*, 2012; 3(Suppl 3):S157-66.
6. Epstein NE. Preliminary study showing safety/efficacy of nanoss bioactive versus vitoss as bone graft expanders for lumbar noninstrumented fusions. *Surg Neurol Int*, 2015;6(Suppl 10):S318-22.
7. Epstein NE. Incidence and management of cerebrospinal fluid fistulas in 336 multilevel laminectomies with noninstrumented fusions. *Surg Neurol Int*, 2015; 6(Suppl 19):S463-8.
8. Epstein NE. Low reoperation rate following 336 multilevel lumbar laminectomies with noninstrumented fusions. *Surg Neurol Int*, 2016; 7(Suppl 13):S331-6.
9. Epstein NE. High lumbar noninstrumented fusion rates using lamina autograft and Nanoss/bone marrow aspirate. *Surg Neurol Int*, 2017; 8:153.
10. Epstein NE, Hollingsworth RD. Nursing review of diagnosis and treatment of lumbar degenerative spondylolisthesis. *Surg Neurol Int*, 2017; 8:246.
11. Epstein NE. Tisseel's impact on hemostasis for 2-3 and 4-6-level lumbar laminectomies. *Surg Neurol Int*, 2017; 8:299.
12. Epstein NE. Spinal case of the month with short perspective: How would you treat this L3-L4 synovial cyst? *Surg Neurol Int*, 2018; 9:56.
13. Epstein NE. Case presentation and short perspective on management of foraminal/far lateral discs and stenosis. *Surg Neurol Int*, 2018;9:87.
14. Epstein NE. Avoiding inappropriate spine surgery in a patient with major cardiac comorbidities. *Surg Neurol Int*, 2019;10:44.
15. Epstein NE. Case of the Week: Preoperative MR/CT Diagnosis of Left L2-L3 Disc Surgically Documented As Massive Synovial Cyst. *Surg Neurol Int*, 2019; 10:168.

**How to cite this article:** Epstein N. Diagnosis and safe excision of lumbar synovial cysts and accompanying pathology: a perspective. *Surg Neurol Int* 2020;11:33.