



## Posterior occipito-axial fixation applied C2 laminar screws for pediatric atlantoaxial instability caused by Down syndrome: Report of 2 cases

Hiroshi Kuroki, MD \*, Shinichiro Kubo, MD, Hideaki Hamanaka, MD, Etsuo Chosa, MD

*Department of Orthopaedic Surgery, University of Miyazaki Faculty of Medicine, Miyazaki, Japan*

### Abstract

**Background:** Upper cervical spine instability is one of the most critical orthopedic problems in patients with Down syndrome. However, arthrodesis of the upper cervical spine in these patients can be very difficult to achieve and has a high complication rate because of mental retardation and accompanying various medical conditions of the vital organs. Even now, surgeries in such patients, especially pediatric cases, are challenging and the optimal operative procedure remains unsettled. The purpose of this study was to report 2 cases of pediatric atlantoaxial instability due to Down syndrome in which posterior occipito-axial fixation with C2 laminar screws was performed.

**Methods:** Case 1 was a girl aged 6 years 10 months who had atlantoaxial rotatory fixation with os odontoideum. Atlantoaxial rotatory fixation was incompletely reduced by halo traction, and it was not maintained without halo-ring and -vest fixation. Posterior occipito-axial fixation with bilateral C2 laminar screws was then performed. Case 2 was a boy aged 10 years 7 months who had atlantoaxial subluxation with os odontoideum. He also had incomplete quadriplegia, so he could neither walk nor have a meal by himself. Posterior occipito-axial fixation with right C2 pedicle and left C2 laminar screws was then carried out.

**Results:** In case 1 bone union was obtained at 3 months after surgery and the patient's symptoms were resolved. In case 2 bone union was obtained at 3 months after surgery and the paralysis was improved.

**Conclusions/level of evidence:** In cases of atlantoaxial instability due to Down syndrome, symptomatic patients often present between ages 5 and 15 years and mental retardation interferes with postoperative cervical immobilization. C2 laminar screws can be safely applied for the pediatric axis and biomechanically accomplished rigid fixation. The C2 laminar screw is one of the most useful options to achieve stability of the pediatric atlantoaxial complex without the risk of vertebral artery injuries (level IV case series).

© 2012 ISASS - International Society for the Advancement of Spine Surgery. Published by Elsevier Inc. All rights reserved.

*Keywords:* Down syndrome; Atlanto-axial instability; Laminar screw; pediatric patients; Posterior occipito-axial fixation

Upper cervical spine instability is one of the most critical orthopedic problems in patients with Down syndrome.<sup>1–3</sup> In particular, symptomatic patients should be strongly considered as candidates for a stabilization procedure. However, arthrodesis of the upper cervical spine in these patients, especially pediatric cases, can be very difficult to achieve, and a high complication rate can be expected because of mental retardation and accompanying various medically problematic conditions of the vital organs.<sup>1,2</sup> We report on the successful treatment of 2 cases of pediatric atlantoaxial instability due to Down syndrome in which posterior occipito-axial fixation with C2 laminar screws was performed.

### Case presentation

#### Case 1

A girl aged 6 years 10 months who had Down syndrome had atlantoaxial rotatory fixation with os odontoideum. No neurologic symptoms and signs were present; however, her neck showed wryneck (the so-called cock robin position), and the range of motion was extremely limited because of severe neck pain. On plain radiographs, the cervical spine had malalignment at the atlantoaxial level with torticollar deformity. Plain computed tomography (CT) showed os odontoideum, and 3-dimensional CT clearly depicted not only sagittal but also axial dislocation of the atlantoaxial joint complex (Fig. 1). The spinal cord snaked through into the spinal canal, but high-intensity change of the spinal cord on the T2-weighted image was not observed on magnetic resonance imaging (Fig. 2). Morphologic analysis of the C2 pedicles by CT imaging techniques indicated that insertion of pedicle screws was

\* Corresponding author: Hiroshi Kuroki, MD, Department of Orthopaedic Surgery, University of Miyazaki Faculty of Medicine, 5200 Kihara, Kiyotake, Miyazaki, 889-1692 Japan; Tel: 81-985-85-0986; Fax: 81-985-84-2931.

E-mail address: [hiroshik@med.miyazaki-u.ac.jp](mailto:hiroshik@med.miyazaki-u.ac.jp)

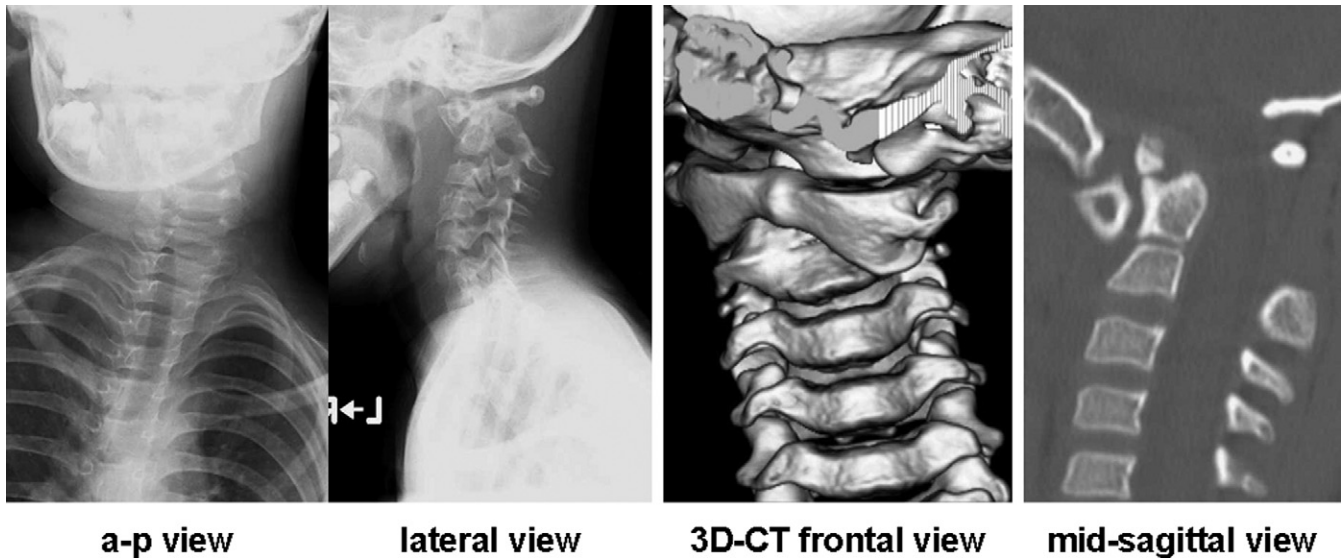


Fig. 1. Preoperative X-ray and CT scan in case 1. On plain radiographs, the cervical spine showed malalignment at the atlantoaxial level with torticollar deformity. Plain CT showed not only sagittal but also axial dislocation of the atlantoaxial joint with os odontoideum. (a-p, anteroposterior; 3D, 3-dimensional.)

judged dangerous on both sides (Fig. 3). Atlantoaxial rotatory fixation could be incompletely reduced by halo traction, but it was not maintained without halo-ring and -vest immobilization. Posterior occipito-axial fixation with bilateral C2 laminar screws (Vertex Max; Medtronic, Memphis, Tennessee) and a decompressive procedure by resection of the C1 posterior arch were then performed (Fig. 4). Fixation was achieved with a halo ring and vest for 6 weeks postoperatively, with a subsequent cervical orthosis for 3 months. Bone union was obtained

at 3 months after surgery, and the patient’s neck pain and wryneck had disappeared.

#### Case 2

A boy aged 10 years 7 months who had Down syndrome had atlantoaxial subluxation with os odontoideum after falling. He had incomplete quadriplegia with urorectal disturbance, so he could neither walk nor have a meal by himself.

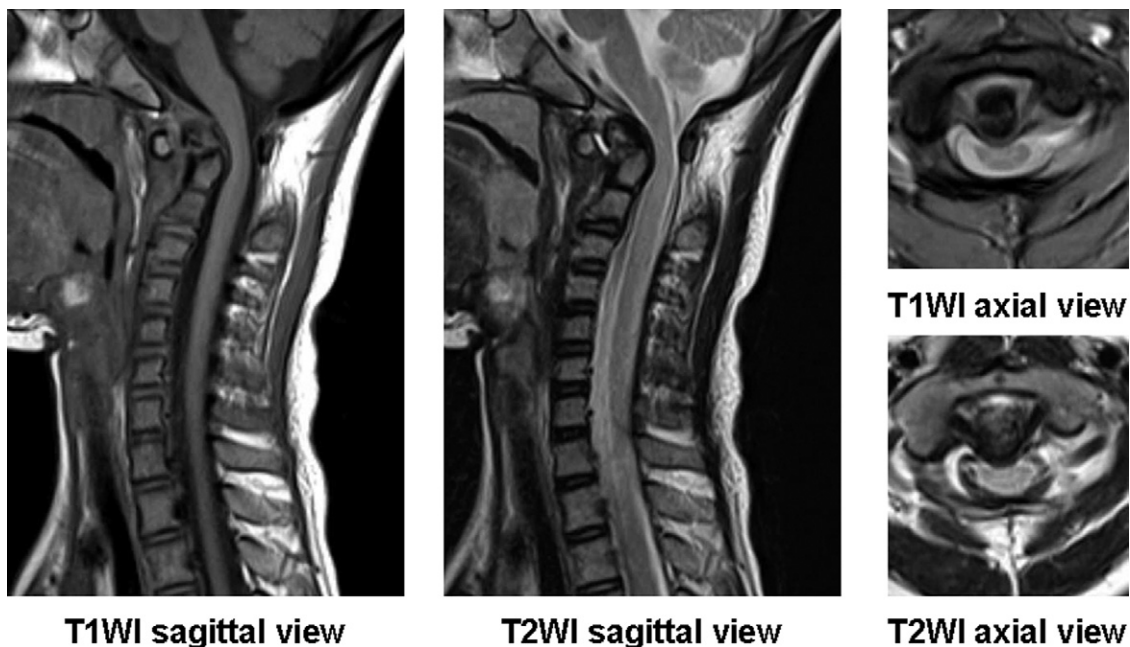


Fig. 2. Preoperative magnetic resonance image (T1WI: T1-weighted image, T2WI: T2-weighted image) in case 1. The spinal cord snaked through into the spinal canal, but high-intensity change of the spinal cord on the T2WI was not observed.

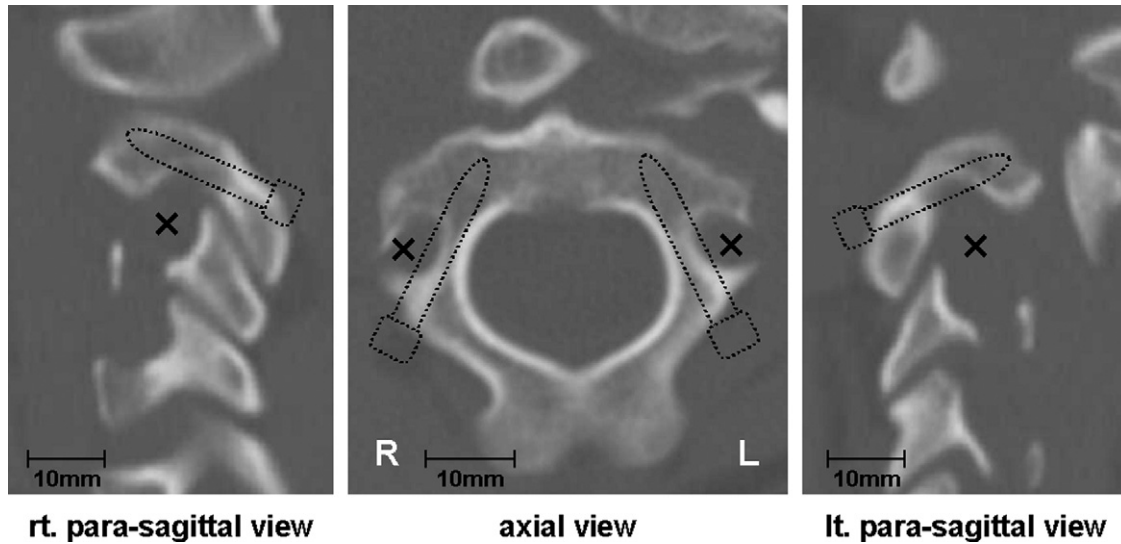


Fig. 3. Morphologic analysis of C2 pedicles by CT imaging in case 1. Insertion of pedicle screws was judged dangerous on both sides by CT imaging. (lt, left; rt, right.)

On dynamic radiographs, marked instability at the atlantoaxial joint complex was observed. Plain CT showed atlantoaxial subluxation with os odontoideum (Fig. 5). The spinal canal had a severe stenosis at the atlantoaxial level, and high-intensity change of the spinal cord on the T2-weighted image was clearly observed on magnetic resonance imaging (Fig. 6). Morphologic analysis of the C2 pedicles by CT imaging techniques indicated that insertion of pedicle screws was judged dangerous on the left side (Fig. 7). Moreover, repositioning of the atlantoaxial complex could not be obtained by preoperative direct traction. At 1 week after installation of a halo ring and vest, posterior occipito-

axial fixation with right C2 pedicle and left C2 laminar screws (Vertex Max) and a decompressive procedure by resection of the C1 posterior arch were carried out (Fig. 8). Halo-ring and -vest fixation was continued for 4 weeks, and a cervical orthosis was subsequently used for 3 months postoperatively. Bone union was obtained at 3 months after surgery, and the patient's paralysis had improved.

#### Discussion

Down syndrome is considered the most common genetic disorder in humans. It occurs in about 1 in 660 live births,

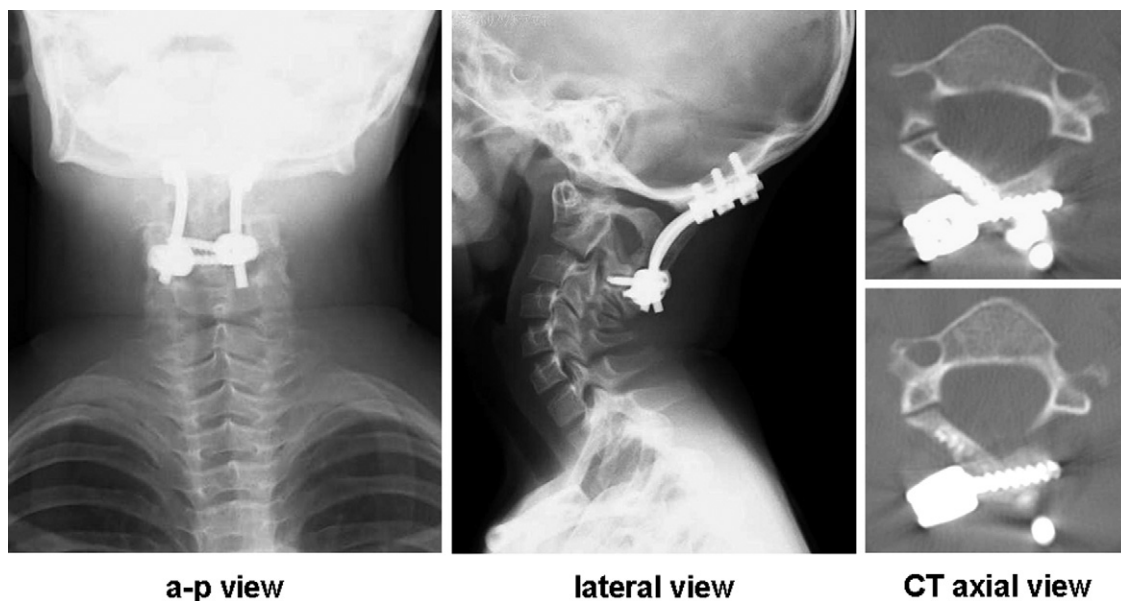


Fig. 4. Postoperative X-ray (obtained 1 year 3 months after surgery) and CT scan (obtained 4 weeks after surgery) in case 1. Alignment of the cervical spine had improved, and the positions of the bilateral C2 laminar screws were correct. (a-p, anteroposterior.)

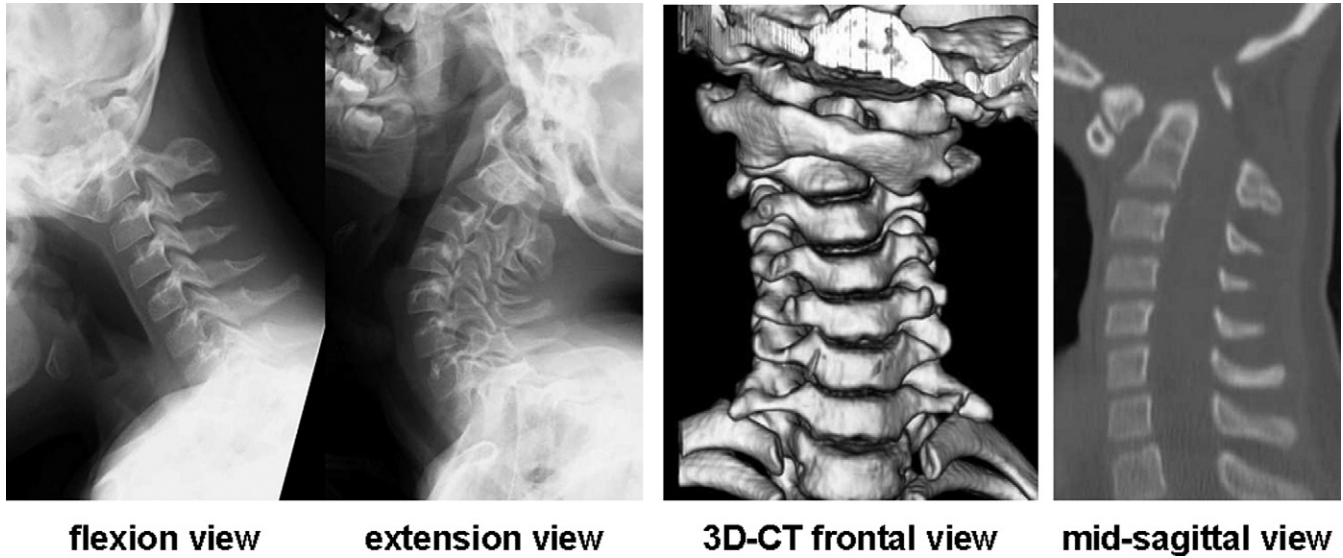


Fig. 5. Preoperative X-ray and CT scan in case 2. On dynamic radiographs, marked instability at the atlantoaxial joint was observed. Plain CT showed atlantoaxial subluxation with os odontoideum. (3D, 3-dimensional.)

and approximately 20% of patients with Down syndrome have associated musculoskeletal disorders.<sup>1,2</sup> Among these disorders, symptomatic atlantoaxial instability, which is estimated to occur in 1% to 2% of patients with Down syndrome,<sup>1</sup> is one of the most serious issues because it may result in irreversible spinal cord damage. Laxity of the transverse atlantal ligament has been thought to be the primary cause of the instability.<sup>4</sup> Among patients aged 11 to 39 years, ambulation was shown to be the best predictor of survival<sup>5</sup>; therefore surgical decompression in combination with fusion and instrumentation may be required from the

point of view of not only maintenance of activities of daily living but also life saving. However, the high rate of serious perioperative complications, especially nonunion, deep wound infection, and any problems related to spinal instrumentation, causes hesitation in choosing to perform surgical intervention.<sup>6</sup> Some articles recommend nonoperative management for patients who have Down syndrome and atlantoaxial instability without neurologic signs or symptoms.<sup>6,7</sup> However, in addition to precautions regarding daily living, regular (at least annual) follow-up is needed, when an interim history of neuromotor function can be obtained and a

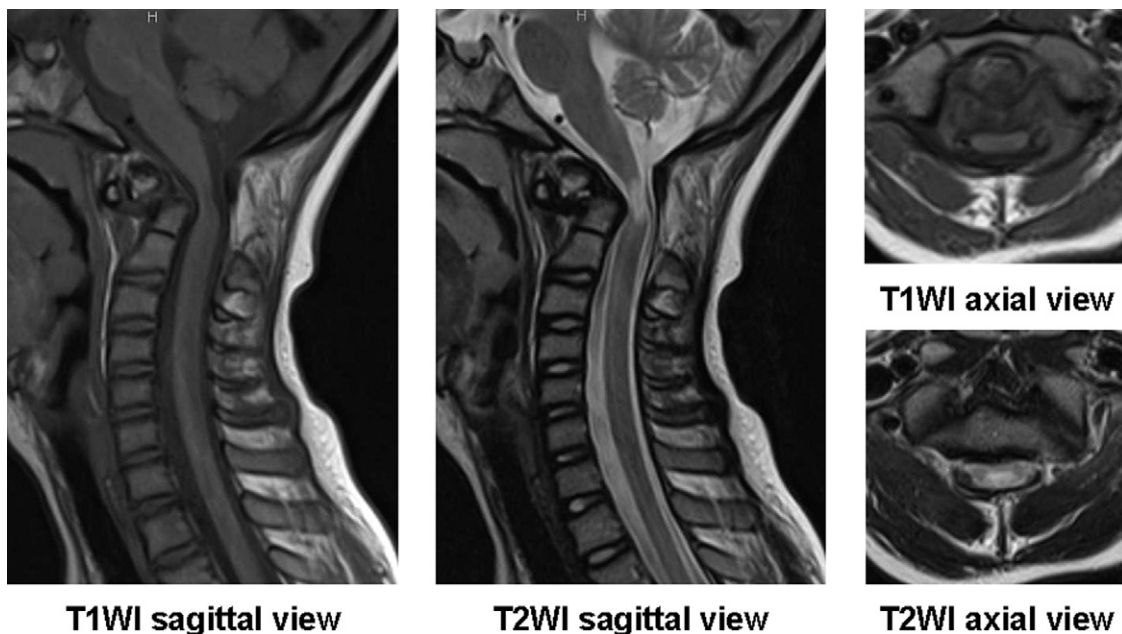


Fig. 6. Preoperative magnetic resonance image (T1WI: T1-weighted image, T2WI: T2-weighted image) in case 2. Severe spinal canal stenosis accompanied by high-intensity change of the spinal cord on the T2WI was clearly observed at the atlantoaxial level.

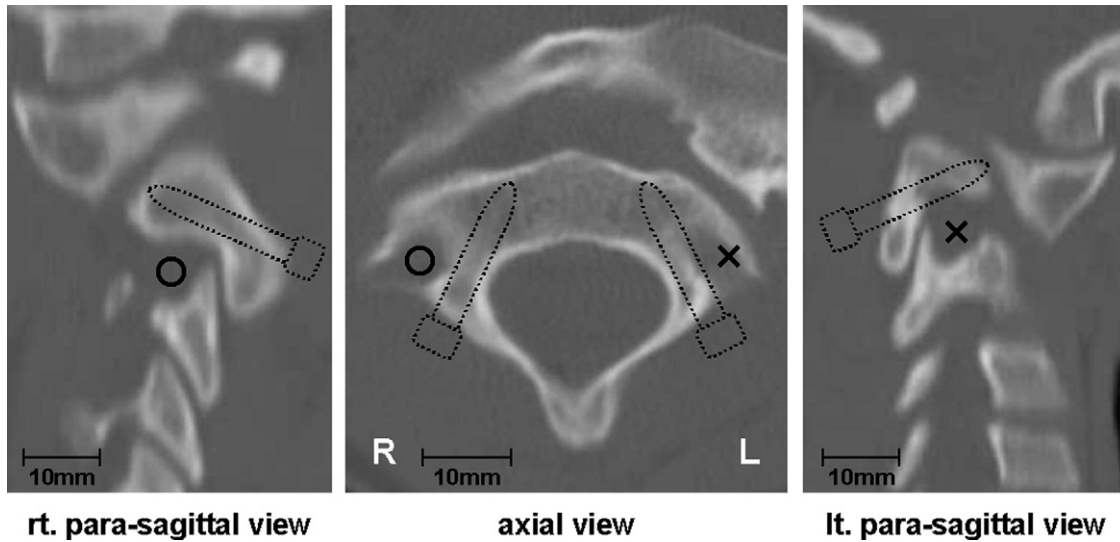


Fig. 7. Morphologic analysis of C2 pedicles by CT imaging in case 2. Insertion of pedicle screws was judged dangerous on the left side by CT imaging. (lt, left; rt, right.)

neurologic examination can be carried out.<sup>6</sup> If the severity of symptoms necessitates a posterior arthrodesis, a high rate of complications must be anticipated.<sup>7</sup>

The main problems of atlantoaxial instability due to Down syndrome are as follows: symptomatic patients often present when aged between 5 and 15 years, children with Down syndrome have a notably greater number of osseous anomalies of the upper cervical spine than do age- and sex-matched healthy children, mental retardation with restless hyperactivity interferes with postoperative cervical immobilization, and a variety of medical conditions that affect the surgical intervention are found in patients with Down syndrome.<sup>1,2</sup> In other words, safely performing not only

transarticular screw fixation but also C1 lateral mass screw and pedicle screw fixation seems impossible because adequate screw insertion may not be feasible by reason of the small size and unusual shape of the C1 and C2 vertebrae. Conventional posterior wiring procedures may not be able to achieve sufficient bone union as a result of incomplete postoperative cervical immobilization because of mental retardation even though a halo ring and vest were applied.<sup>8</sup> Furthermore, intensive care for general condition during the perioperative period is mandatory because of the accompanying various pathologic conditions of the vital organs.

Therefore we tried to carry out C2 laminar screw fixation as reported by Wright<sup>9</sup> in 2004 for patients with Down

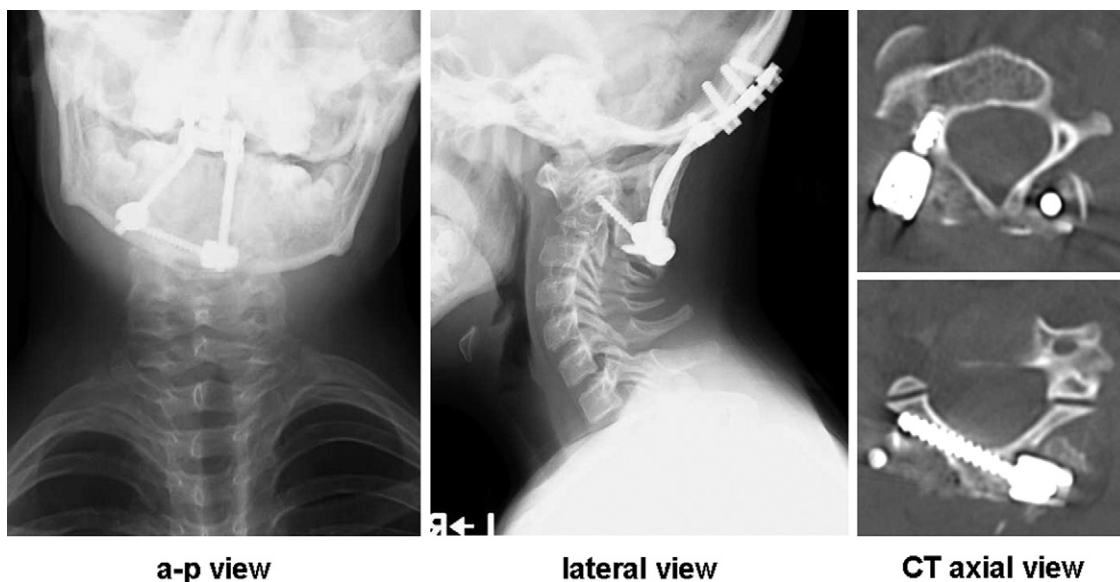


Fig. 8. Postoperative X-ray (obtained 1 year 6 months after surgery) and CT scan (obtained 1 week after surgery) in case 2. Alignment of the cervical spine had improved, and the accurate insertion of both right C2 pedicle and left C2 laminar screws was confirmed. (a-p, anteroposterior.)

syndrome in whom pedicle screw insertion was not possible. Our literature search found no report in which occipito-axial fixation with C2 laminar screws was adopted for pediatric atlantoaxial instability due to Down syndrome. This technique is technically simpler and does not require fluoroscopy or navigation because screws are placed directly into the visualized laminae.<sup>10,11</sup> In addition, C2 laminar screws yield no risk of vertebral artery injury and are acceptably inserted in pediatric patients because the laminae of the axis are relatively wide.<sup>12</sup> Furthermore, the addition of an “exit” cortical window at the facet-laminar junction ensures that the screw is bicortical and within the cancellous bone of the lamina and not deep in the spinal canal. Ferri-de-Barros et al<sup>13</sup> reported that screw insertion in the C2 laminae is anatomically safe compared with screw insertion in the C2 pedicles by morphologic analysis using CT images in pediatric patients, with a mean age of 6 years. In biomechanical studies, although the C2 pedicle screw was stiffer than the C2 laminar screw, there were no statistically significant differences between them.<sup>14–16</sup> That is, the C2 laminar screw must clinically provide enough stability. By this novel technique, favorable immediate intraoperative fixation enough to achieve sufficient bone union was accomplished with rods connected by occipital screws and C2 laminar screws. With respect to the upper foundation, occipital bone was used in both cases because C1 was too hypoplastic for placement of the lateral mass screws and the bone graft bed was lost by resection of the C1 posterior arch. Naturally, if complete repositioning of the atlantoaxial complex can be achieved and C1 lateral mass screws can be placed safely, only atlantoaxial fusion should be chosen because this procedure is less invasive and provides preservation of one motion segment. Perioperative conditions of these 2 cases were stable without any general complications. Improvements of the patients’ preoperative symptoms have been excellently maintained at 2 years after surgery. However, the atlantoaxial complex was forced to fuse in a somewhat flexed position because repositioning of the atlantoaxial malalignment could not be thoroughly accomplished. Long-term careful observation is necessary because adverse effects to the entire cervical alignment are anticipated in the future.

C2 laminar screws with which immediate rigid fixation is guaranteed are easily applied for the pediatric axis. Satisfactory clinical results will be expected combined with halo-ring and -vest immobilization even though the patients will not be able to follow the instruction about postoperative treatment because of mental retardation.

## Conclusions

Two cases of pediatric atlantoaxial instability due to Down syndrome that were treated by posterior occipito-

axial fixation with C2 laminar screws were reported. Bone union was successfully obtained with accompanying postoperative short-term halo-ring and -vest immobilization, and clinical symptoms were mostly relieved. The C2 laminar screw is one of the most useful options to achieve stability of the pediatric atlantoaxial joint complex without severe complications for patients in whom pedicle screw fixation cannot be performed safely.

## References

1. Caird MS, Wills BPD, Dormans JP. Down syndrome in children: the role of the orthopaedic surgeon. *J Am Acad Orthop Surg* 2006;14: 610–9.
2. Mik G, Gholive PA, Scher DM, Widmann RF, Green DW. Down syndrome: orthopedic issues. *Curr Opin Pediatr* 2008;20:30–6.
3. Pizzutillo PD, Herman MJ. Cervical spine issues in Down syndrome. *J Pediatr Orthop* 2005;25:253–9.
4. Burke SW, French HG, Roberts JM, Johnston CE 2nd, Whitecloud TS 3rd, Edmunds JO Jr. Chronic atlanto-axial instability in Down syndrome. *J Bone Joint Surg Am* 1985;67:1356–60.
5. Eymann RK, Call TL, White JF. Life expectancy of persons with Down syndrome. *Am J Ment Retard* 1991;95:603–12.
6. Poeschel SM, Scola FH. Atlantoaxial instability in individuals with Down syndrome: epidemiologic, radiographic, and clinical studies. *Pediatrics* 1987;80:555–60.
7. Segal LS, Drummond DS, Zanotti RM, Ecker ML, Mubarak SJ. Complications of posterior arthrodesis of the cervical spine in patients who have Down syndrome. *J Bone Joint Surg Am* 1991;73:1547–54.
8. Doyle JS, Laueran WC, Wood KB, Krause DR. Complications and long-term outcome of upper cervical spine arthrodesis in patients with Down syndrome. *Spine (Phila Pa 1976)* 1996;15:1223–31.
9. Wright NM. Posterior C2 fixation using bilateral, crossing C2 laminar screws: case series and technical note. *J Spinal Disord Tech* 2004;17: 158–62.
10. Chamoun RB, Relyea KM, Johnson KK, Whitehead WE, Curry DJ, Luerssen TG, Drake JM, Jea A. Use of axial and subaxial translaminar screw fixation in the management of upper cervical spinal instability in a series of 7 children. *Neurosurgery* 2009;64:734–9.
11. Leonard JR, Wright NM. Pediatric atlantoaxial fixation with bilateral, crossing C-2 translaminar screws: technique note. *J Neurosurg* 2006; 104(Suppl):59–63.
12. Jea A, Sheth RN, Vanni S, Green BA, Levi AD. Modification of Wright’s technique for placement of bilateral crossing C2 translaminar screws: technical note. *Spine J* 2008;8:656–60.
13. Ferri-de-Barros F, Little DG, Bridge C, Cummine J, Cree AK. Atlantoaxial and craniocervical arthrodesis in children: a tomographic study comparing suitability of C2 pedicles and C2 laminae for screw fixation. *Spine (Phila Pa 1976)* 2010;35:291–3.
14. Claybrooks R, Kayanja M, Milks R, Benzel E. Atlantoaxial fusion: a biomechanical analysis of two C1-C2 fusion techniques. *Spine J* 2007; 7:682–8.
15. Gorek J, Acaroglu E, Berven S, Yousef A, Puttlitz CM. Constructs incorporating intralaminar C2 screws provide rigid stability for atlantoaxial fixation. *Spine (Phila Pa 1976)* 2005;30:1513–8.
16. Lapsiwala SB, Anderson PA, Oza A, Resnick DK. Biomechanical comparison of four C1 to C2 rigid fixative techniques: anterior transarticular, posterior transarticular, C1 to C2 pedicle, and C1 to C2 intralaminar screws. *Neurosurgery* 2006;58:516–21.