

# Cases of thallium intoxication in Syria: A diagnostic and a therapeutic challenge

Ibrahim Almassri, Mohamed Sekkarie

Data and Research Committee, Syrian American Medical Society, Washington, DC 20005, USA

## Access this article online

Website: [www.avicennajmed.com](http://www.avicennajmed.com)

DOI: 10.4103/ajm.AJM\_17\_18

## Quick Response Code:



## ABSTRACT

In mid-March 2015, a mother and her teenage daughter and son from Syria presented to a Syrian American Medical Society (SAMS) refugee clinic in the Beqaa Valley in Lebanon with the chief complaints of hair loss together with weakness and numbness of their lower extremities. They reported that on March 1, a military foe of their relative had given him several boxes of Middle Eastern cookies which were consumed by over 20 members of their families and neighbors. Soon after the consumption, most members of the households developed symptoms including abdominal pain, nausea, vomiting, and constipation. Later, many of the affected individuals, including the three who presented to the clinic, had pain and weakness in the extremities, skin lesions, and hair loss. Two subjects died inside Syria of kidney failure. In this report, we describe the diagnostic challenges faced until the arrival to the diagnosis of thallium intoxication and the therapeutic obstacles to getting adequate therapy. We also report the results of a survey sent to all subjects in the affected households and discuss the context of lawlessness that led to this intoxication and perhaps other cases.

**Key words:** Poisoning, Syria, thallium

## INTRODUCTION

Going into its 8<sup>th</sup> year, the Syrian tragedy had led to the death and ailment of hundreds of thousands and displacement of millions of civilians in a context of human rights violations, deliberate attacks on healthcare workers and facilities,<sup>[1]</sup> and lack enforcement of international and civil laws. Most of the excess mortality and morbidity has been attributed to war injuries and deterioration of the healthcare system. Sporadic reports of poisoning have appeared in some nonscientific reports;<sup>[2,3]</sup> however, to the best of our knowledge, this potentially common problem has not been well studied in the Syrian war.

In this manuscript, we report cases of criminal thallium intoxication in 17 individuals who were presented with Middle Eastern sweets as a “gift” and discuss issues related to thallium intoxication and treatment, both in general and in the Syrian context. We also raise the question regarding

the potential of this case representing the tip of an iceberg of chemical poisoning, both criminal and accidental.

## METHODS

Records of three patients who presented to the Beqaa Valley Syrian American Medical Society (SAMS) clinic were reviewed in detail. All subjects ( $n = 23$ ) in the five households where the sweets were consumed were sent a survey to inquire about their consumption pattern of the desserts (date cookies, ghraybeh, barazek) their symptoms were reviewed using a severity on a score of 0–10. Data on deceased subjects and children were completed by their next of kin. The presence or absence of at least one symptom versus the consumption of any type of sweets

This is an open access journal, and articles are distributed under the terms of the Creative Commons Attribution-NonCommercial-ShareAlike 4.0 License, which allows others to remix, tweak, and build upon the work non-commercially, as long as appropriate credit is given and the new creations are licensed under the identical terms.

**For reprints contact:** [reprints@medknow.com](mailto:reprints@medknow.com)

**Cite this article as:** Almassri I, Sekkarie M. Cases of thallium intoxication in Syria: A diagnostic and a therapeutic challenge. *Avicenna J Med* 2018;8:78-81.

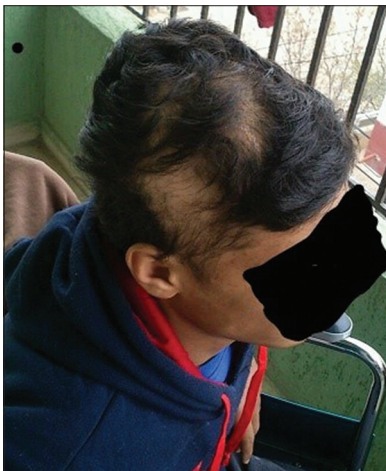**Address for correspondence:** Dr. Mohamed Sekkarie, Syrian American Medical Society, 1012 14<sup>th</sup> Street Suite 1475, Washington, DC 20005, USA.  
E-mail: [msekkarie@mail.com](mailto:msekkarie@mail.com)

was analyzed using the Fisher's exact test. A symptom score was constructed by adding the sum of the severity of each of the 72 Surveyed symptom in every case. Scores were compared by the type and quantity of the consumed sweet and correlated with the quantity of consumption. Data management and analysis were performed using Microsoft Excel and Stata software. Written consents were obtained from the patients, or in the case of minors and diseased, the next of kin.

## RESULTS

The "presented boxes" contained three types of Syrian sweets: date cookies, barazek, and Ghraybeh. The recipient of the "gift" was an ex-military foe of the donor, and the presentation was a "token of reconciliation." The consumption occurred about March 1, 2015, in a besieged area of rural Damascus. The "gift" recipient and another male, both of whom consumed a large amount of the sweets compared to the rest, became very ill. One avoided hospitals for fear of being persecuted, so he went to a local clinic where he was found to have several laboratory abnormalities including an elevated serum creatinine. He died at home a few days later. The other male together with the above three patients made it to a tertiary care hospital in Syria. The man had dialysis and died of multisystem failure. No diagnosis was reached.

The three patients who came to Lebanon were first seen at a tertiary care hospital in Damascus with the chief complaints of nausea, abdominal pain, and constipation; they were discharged without a diagnosis and presented to SAMS Beqaa Clinic on March 15 with the complaints of hair loss and nail changes [Figures 1 and 2] with pain and weakness in the lower extremities. In addition to the dermatological changes, the examination was remarkable

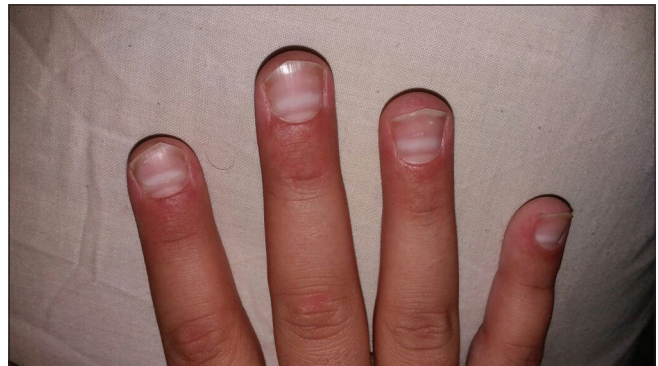


**Figure 1:** A photograph of the boy's head showing patchy hair loss, taken 4 weeks after the ingestion

for mild hypertension and increased sensitivity to painful stimuli. Routine laboratory tests were unremarkable, except for a mild elevation of alanine transferase in one subject. Chest X-ray and electrocardiography were unremarkable.

In the ensuing few days help from the Lebanese Ministry of Health, and many nongovernmental organizations was sought, for the most part, they considered diagnosing and treating these cases not-to-fit their missions. The Lebanese Ministry of Health took some samples of the sweets to look for bacterial poisoning and the results were negative. Funds collected from private citizens were used to run a blood screening for "heavy metals" including lead and arsenic (results negative), an electromyogram/nerve conduction study in one patient (axonal and mixed polyneuropathy), and dermatology and neurology consultations (no diagnosis reached). The patients also received symptomatic and physical therapy with no improvement. On April 15, 2015, the patients were seen by a visiting US nephrologist, an internet search of the terms "poisoning, neuropathy, alopecia, abdominal pain" was highly suggestive of thallium intoxication, a specialized toxicology laboratory was contacted, and they suggested obtaining a semen specimen from the teenage boy. The analysis showed a thallium level of 800 mcg/L (limit of quantitation 1 mcg/L). In one study, the 50<sup>th</sup> percentile of normal thallium concentration in semen was 0.10 mcg/L.<sup>[4]</sup>

A literature review of treatment of thallium toxicity concluded that hemodialysis at that stage would not be effective but that the antidote Prussian blue might be. Attempts to get the medicine in Lebanon were not successful, but a private donor sent 504 pills (500 mg) of the medicine from Germany which were given to the three patients at a dose of 1500 mg three times a day (recommended dose is 3000 mg three times a day) for 18 days (recommended duration is 30 days). The patients had gradual improvement of symptoms and decided to go back to their village in Syria. As of October 2016, these three



**Figure 2:** A photograph of the boy's finger nails showing Mees' lines, taken 7 weeks after the ingestion

patients are reported to be in good health, except for some undiagnosed behavioral difficulties for the boy.

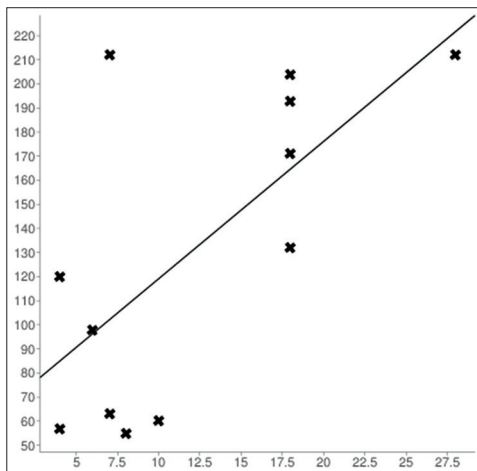
Of the 23 subjects, all 15 who ate sweets became ill as opposed to two of the eight of those who were reported not to consume any ( $P < 0.01$ ). Table 1 shows the average symptoms score according to the type of consumed sweets, 12 subjects had date cookies (D) (which turned out to be the poisoned sweet), six subjects consumed solely D, while the other six consumed D along with other types of sweets. The number of D pieces consumed correlated with the symptoms' score [Figure 3]. Analyses of a sample of the poisoned sweets the patients brought with them [Figure 4] confirmed the presence of the largest concentration of thallium in the pastry shell of the date cookies. The most common symptoms seen in the 17 symptomatic patients are shown in Figure 5.

The three patients who were seen in Lebanon had their urines checked for microalbumin to creatinine ratio at different intervals. All three had elevated values in the microalbuminuria range (20–300 mg per gram of creatinine which improved with time) [Figure 6]. Their plain urinalyses were all negative.

**Table 1: The average symptoms score according to the type of consumed sweets**

Sweet	Number of subjects who consumed sweets	Average score $\pm$ SD
Date cookies	6	128 $\pm$ 59
Barazek	2	45 $\pm$ 1
Ghraibeh	1	20
Combination (date cookies plus any of the other two mentioned above)	6	109 $\pm$ 55
Nothing	8	11 $\pm$ 22

All subjects who consumed more than one kind of sweets had date cookies also. SD: Standard deviation



**Figure 3:** A graph showing the correlation between the number of date cookies eaten and symptoms score

## DISCUSSION

Since its discovery as an element, thallium has had a history with many uses and misuses. In the early twentieth century, syphilis, gonorrhea, excess hair growth, and ringworms were treated by this agent either systemically or topically. Soon after that reports emerged describing thallium toxicity, most dramatically, the death of 14 children treated for ringworms in an orphanage in Granada around 1930.<sup>[5]</sup> As a result, medicinal uses were abandoned, and the chemical became a rodenticide. Homicidal, suicidal, and accidental cases of poisoning became a problem, so the agent was banned for this use in most countries around 50 years ago. Nowadays, thallium has some industrial uses.<sup>[5]</sup> Most currently practicing providers recognize thallium as a diagnostic agent in cardiac stress testing where it is used in very small nontoxic amounts. The diagnosis of thallium intoxication could be elusive because many manifestations such as gastrointestinal symptoms, autonomic neuropathy, cranial nerve abnormalities, altered mental status, motor weakness, and cardiac, hepatic, and renal effects are nonspecific. Alopecia areata, however, is a significant clue.<sup>[6]</sup> The agent is highly bioavailable when orally ingested and is also absorbed via skin and mucosal surfaces. It is distributed intracellularly within hours of ingestion making hemodialysis only effective in its removal in the first day or two following the exposure.<sup>[7]</sup> The antidote Prussian blue can potentially interfere with thallium's enterohepatic circulation causing a reduction in tissue stores even when given at late stages.<sup>[8]</sup>

This case series shows that the spectrum of the renal abnormalities in thallium intoxication is quite broad ranging from subtle microalbuminuria to overt renal replacement therapy requiring acute kidney injury. We can speculate that the microalbuminuria could be secondary to hypertension or a direct renal injury.<sup>[9]</sup>



**Figure 4:** A sample of the sweets brought by patients in Syria, the date cookie is the larger piece

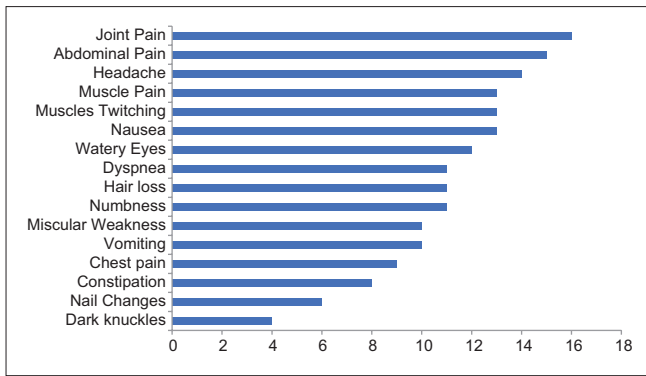


Figure 5: The most common symptoms in the affected subjects

This case series provides an example of how in addition to the usual morbidities associated with wartime, the ongoing Syrian crisis has also led to other health problems. Similar cases were reported during the Iraq war.<sup>[10]</sup> The limited resources and atmosphere of mistrust have further complicated the diagnosis and treatment of these types of cases. Furthermore, at present, performing any meaningful investigation on the prevalence of poisoning is impossible. The source of the poison is still unknown. An investigation on the available rodenticides in Syria revealed that thallium is not an ingredient in any of the available products.

In the last 2 years, reports of life-threatening poisoning cases have emerged. In October 2016, the Independent Doctors Association of Aleppo issued a notice regarding cases of hemolytic anemia in children in the then besieged Aleppo due to consumption of a material sold as citric acid which was thought to intentionally include a similar tasting powder derived from residues of exploded bombs.<sup>[2]</sup> More recently, sodium nitrite poisoning<sup>[3]</sup> was reported to result from the consumption of a material sold as table salt which was allegedly extracted from the waste products of ice manufacturing.

This manuscript points to many failures of the international communities not only in putting an end to the Syrian tragedy but also in providing relief to the suffering civilian population not only in besieged areas but also in countries hosting refugees.<sup>[11]</sup>

#### Financial support and sponsorship

Nil.

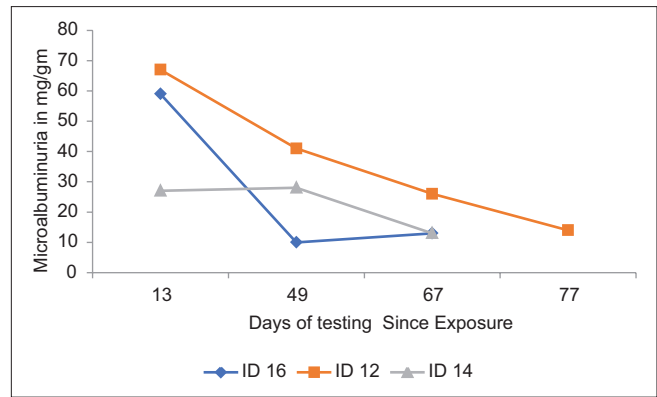


Figure 6: Microalbuminuria to creatinine ratios in the patients who presented to Lebanon, normal is <20 mg/g

#### Conflicts of interest

There are no conflicts of interest.

#### REFERENCES

- Fouad FM, Sparrow A, Tarakji A, Alameddine M, El-Jardali F, Coutts AP, *et al.* Health workers and the weaponisation of health care in Syria: A preliminary inquiry for the lancet-American University of Beirut Commission on Syria. *Lancet* 2017;390:2516-26.
- Report from Independent Doctors Association of Aleppo. 10 October, 2017. Cases of Hemolytic Anemia of Unknown Cause in Besieged Aleppo; 2017.
- Syria: Direct. Three Killed, Dozens Poisoned in East Ghouta After Residents Consume Salt-Like Substance; 23 November, 2017. Available from: <http://www.syriadirect.org/news/three-killed-dozens-poisoned-in-east-ghouta-after-%E2%80%98desperate%E2%80%99-residents-consume-salt-like-substance/>. [Last accessed on 2017 Nov 25].
- Meeker JD, Rossano MG, Protas B, Diamond MP, Puscheck E, Daly D, *et al.* Cadmium, lead, and other metals in relation to semen quality: Human evidence for molybdenum as a male reproductive toxicant. *Environ Health Perspect* 2008;116:1473-9.
- Mulkey JP, Oehme FW. A review of thallium toxicity. *Vet Hum Toxicol* 1993;35:445-53.
- Moore D, House I, Dixon A. Thallium poisoning. Diagnosis may be elusive but alopecia is the clue. *BMJ* 1993;306:1527-9.
- Ghannoum M, Nolin TD, Goldfarb DS, Roberts DM, Mactier R, Mowry JB, *et al.* Extracorporeal treatment for thallium poisoning: Recommendations from the EXTRIP workgroup. *Clin J Am Soc Nephrol* 2012;7:1682-90.
- Hoffman RS. Thallium toxicity and the role of Prussian blue in therapy. *Toxicol Rev* 2003;22:29-40.
- Winter ST, Laron Z, Michaelson IC. Renal and vascular disturbances in a case of thallium poisoning. *Arch Dis Child* 1954;29:443-6.
- Centers for Disease Control and Prevention (CDC). Thallium poisoning from eating contaminated cake – Iraq, 2008. *MMWR Morb Mortal Wkly Rep* 2008;57:1015-8.
- Spiegel PB. The humanitarian system is not just broke, but broken: Recommendations for future humanitarian action. *Lancet* 2017. pii: S0140-6736(17)31278-3.