



CASE REPORT

A rare case of asymptomatic Paget's disease of the skull in a 60-year-old Asian female

Muhammad Ali^{1*}, Omama Farooq¹, Zahra Rafique¹, Hajrah Farooq¹, Fazeelat Iftikhar¹, Muqadsa Malik²

¹Department of Internal Medicine, Islamabad Medical Complex, NESCOM Hospital, Islamabad, Pakistan, ²Department of Internal Medicine, Fauji Foundation Medical College, Rawalpindi, Pakistan

ARTICLE INFO

Article history:

Received: November 05, 2022

Revised: January 22, 2023

Accepted: May 30, 2023

Published online: July 26, 2023

Keywords:

Alkaline phosphatase

Paget's disease of bone

Osteitis deformans

Tc-99m-methylene diphosphonate

Bisphosphonates

**Corresponding authors:*

Muhammad Ali

Department of Internal Medicine, Islamabad Medical Complex, Nescom Hospital, Islamabad, Pakistan.

Tel: +92 345 5240908

Email: muhammad.ali.janjua93@gmail.com

© 2023 Author(s). This is an Open-Access article distributed under the terms of the Creative Commons Attribution-Noncommercial License, permitting all non-commercial use, distribution, and reproduction in any medium, provided the original work is properly cited.

ABSTRACT

Background and Aim: Paget's disease of the bone refers to a chronic cumulative disorder characterized by enhanced osteoclastic function followed by a secondary surge in osteoblastic activity. The condition can manifest as a polyostotic or monostotic bone disease with most patients having an asymptomatic presentation, although some may complain of pain localized to the affected bone while others express symptoms of nerve compression. A pagetic bone is predisposed to develop pathological fractures, bony deformities, and a rare yet detrimental transformation into osteosarcoma. Detection is often accidental when performing radiographic tests for other indications or when elevated blood levels of alkaline phosphatase (ALP) are detected. Treatment with third-generation bisphosphonates is helpful in preventing further bone resorption and, additionally, reduces bony pains that are believed to be caused by excessive metabolic activity. Here, we present a case of a middle-aged asymptomatic female with elevated serum ALP levels up to 1537 IU/L (reference range 40–150 U/L) during her pre-operative evaluation for elective cholecystectomy. ^{99m}Tc-methylene diphosphonate bone scintigraphy revealed diffuse uptake in the skull and, hence, was diagnosed as a case of isolated Paget's disease of the skull.

Relevance for Patients: The rarity of this disease in Southeast-Asians, its uncontrived detection, and the isolated skull involvement, imparts high clinical relevance on this case. Early detection and management of this disease can help prevent the development of life-threatening complications in affected patients, hence decreasing the morbidity.

1. Introduction

Paget's disease of bone (PDB), also known as osteitis deformans, is a chronic skeletal bone disorder characterized by focal areas of excessive disorganized bone remodeling, targeting any bone throughout the skeleton. This disease primarily affects the axial skeleton, where pelvis is the most common site of involvement, followed by femur, lumbar spine, skull, and tibia [1]. Most patients are asymptomatic and often present with an incidental finding of high serum alkaline phosphatase (ALP) levels during routine blood examination [2]. Diagnostic modalities commonly utilized include X-ray, biochemical analysis of serum total ALP, computed tomography (CT) scan, bone scintigraphy, and magnetic resonance imaging [3].

2. Case Presentation

A 60-year-old Asian female with a known case of hypertension and treated hepatitis C virus infection presented to the surgical outpatient department for her scheduled pre-operative

visit for elective cholecystectomy. She was referred to the medical department for further workup after she was found to have isolated elevated ALP levels of up to 1537 IU/L (reference range 40–150 IU/L). According to the patient she only had a history of mild, non-radiating, non-pulsatile, bilateral headache that occurred on and off several times during the day and that receded without intervention. The patient had no history of deafness, tinnitus, dental malocclusion, fractures, fatigue, or generalized body weakness. She gave no associated history of any abnormal bone enlargement, including her head, with no increase in hat size in recent years.

On inquiring further, she reported a history of dark-colored urine for the past 20 days with no history of pruritis, clay-colored stool, or weight loss. Examination revealed mild frontal bossing, whereas the rest of her general physical and systemic examination were within normal limits. Biochemical tests revealed an ALP 1537 IU/L with normal total bilirubin, aspartate transaminase, and alanine transaminase levels. Ultrasound of the abdomen showed multiple calculi in the lumen of the gallbladder with a normal caliber of the common bile duct. On further investigations, serum calcium and phosphorus levels were within normal limits.

Gamma GT was within normal limits. Urine for Bence–Jones protein came back negative and serum protein electrophoresis was within normal limits, hence ruling out multiple myeloma. X-ray of the skull revealed widening of diploid space and diffusely scattered multiple sclerotic lesions in skull vault, giving a cotton wool appearance (Figure 1). The patient was then referred to the rheumatology outpatient department for further investigations and treatment plan. A CT scan of the brain without contrast showed expanded bones of the skull with multiple sclerotic and lytic lesions (Figure 2).

Bone scintigraphy confirmed the diagnosis of PDB involving the skull bone only, showing diffusely increased uptake in the skull bone (Figure 3). The patient was commenced on third-generation intravenous bisphosphonate (15-min infusion of 5 mg zoledronic acid). The patient was advised to follow-up after 3 months at the rheumatology outpatient department to determine ALP levels. On follow-up after 3 months, repeat ALP test showed markedly reduced levels down to 250 IU/L. The patient was also advised a repeat bone scintigraphy scan on the same visit but was lost to follow-up for subsequent visits.

3. Discussion

PDB is ranked second to osteoporosis as the most common bone disorder, exhibiting higher prevalence throughout Western Europe, America, and Australia, but very low incidence among Asians and Africans. Diagnosis before the age of 40 is rare. The key abnormality in this disease points to aberrant osteoclastic bone resorption accompanied by marrow fibrosis, leading to increased bone vascularity and enhanced osteoblastic activity. A mosaic pattern of bone and lamellar tissue with enlarged osteoclast-containing distinct nuclear inclusion bodies is revealed histologically [4].

The etiology of PDB remains unclear, whereas multiple studies suggest an association with genetic mutations, environmental

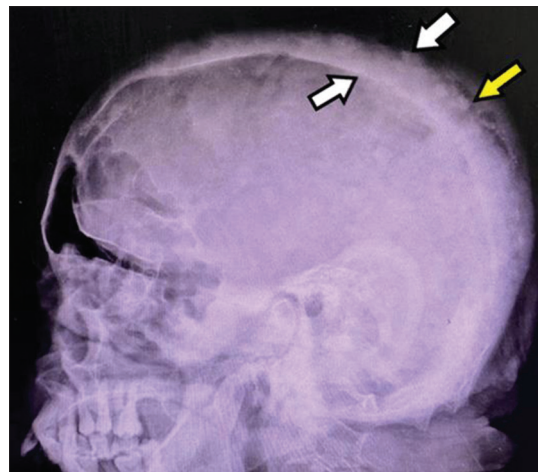


Figure 1. X-ray (lateral view) of the skull showing widening of diploid space (white arrows) and diffusely scattered multiple sclerotic lesions in skull vault (yellow arrow), yielding a cotton wool appearance.

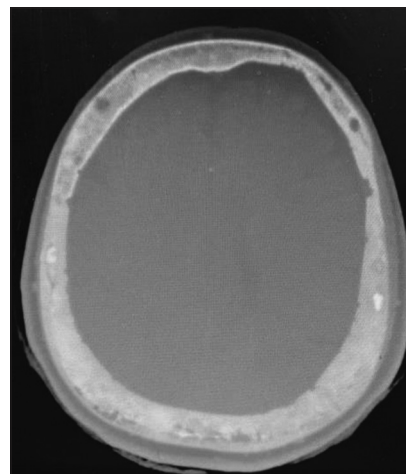


Figure 2. Computed tomography scan of the brain without contrast, showing expanded bones of the skull with multiple sclerotic and lytic lesions.

factors, and paramyxoviral infection [5]. Clinically, the usual presentation is asymptomatic but may present with bone pains, nerve entrapment, bony deformities, and increased propensity to develop fractures. Clinical symptoms differ with the disease location; skull involvement usually causes increase in the hat size, along with headaches or deafness, whereas when base of the skull is affected, it can lead to hydrocephalus, platybasia, and basilar invagination [3,6]. High-output cardiac failure, although very uncommon, is often precipitated due to enhanced vascularity of the affected bone, whereas osteosarcoma, although rare, is usually the feared complication in a pre-existing pagetic bone [7].

According to the US Endocrine Society clinical practice guidelines, effective management protocols have been formulated for patients suspected of PDB, where the first-line investigation remains to be plain X-ray of the affected regions, followed by ^{99m}Tc-methylene diphosphonate (MDP) bone scan, after the

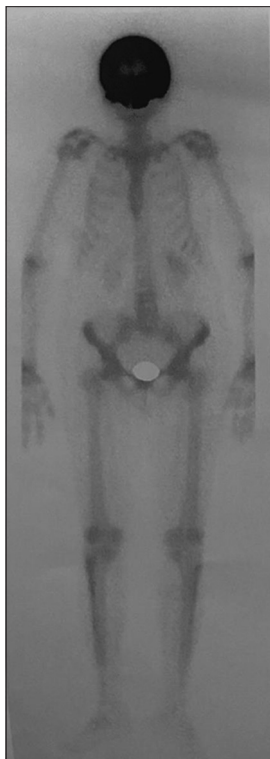


Figure 3. Anterior view of the bone scan showing diffuse uptake of the technetium-99m in the skull bones.

confirmation of diagnosis through plain X-ray. Biochemical test such as an elevated serum ALP levels aid in evaluating the activity and progression of PDB and indicate the response to treatment. Furthermore, recent studies have estimated a significant rise in serum osteopontin levels as a marker for active PDB [8]. X-ray of the skull may manifest radiolucent areas around the suture lines typically in the occipital and frontal bones, an enlarged diploic space, and focal osteosclerosis giving cotton wool appearance [3,8,9]. Nonetheless, the putative imaging modality is radionuclide bone scintigraphy (MDP), exhibiting substantially increased uptake in the affected bone. Cranial CT scans generally show evidence of cranial vault thickening [10]. Isolated skull involvement may include neurological complications such as hearing loss, headache, bone pains, tinnitus, basilar impression, and rarely cranial nerve deficits [9].

Paget's bone pains are generally the key indicator for treatment and may recede or disappear with medical therapy. The mainstay of treatment is the use of intravenous third-generation bisphosphonates such as zoledronic acid for active PDB which works by impeding bone resorption through osteoclastic activity inhibition, expending an anti-cancerous effect by enhancing the proliferation of gamma delta T cells [11], and alleviates bone pains that are believed to be caused by excessive metabolic activity. Zoledronate (zoledronic acid) is administered as 5 mg given as a single infusion over 15 min. Retreatment is mostly not required as a single infusion balances the bone turnover for about 5 years [8,9,12]. Serum ALP levels are monitored to assess the

disease status and are measured at an interval of 3 months for the first 6 months after initial treatment, and then after 6 months subsequently [11].

4. Conclusion

In conclusion, isolated raised serum alkaline phosphatase levels should always be further investigated to rule out asymptomatic patients. Management includes treatment with third-generation bisphosphonates and pain control. Effective and time-sensitive management can impart a huge difference in the outcome of Paget's disease.

Acknowledgments

None.

Funding

The authors received no financial support for the research, authorship, and/or publication of this article.

Conflicts of Interest

The authors have no conflicts of interest associated with the material presented in this paper.

Ethics Approval and Consent to Participate

Informed consent was obtained from the patient by the authors.

Consent to Participation

Consent was given by the patient to publish her data and images in this paper.

References

- [1] Corral-Gudino L, Tan AJ, Del Pino-Montes J, Ralston SH. Bisphosphonates for Paget's Disease of Bone in Adults. *Cochrane Database Syst Rev* 2017;12:CD004956.
- [2] Rianon NJ, Des Bordes JK. Paget Disease of Bone for Primary Care. *Am Fam Physician* 2020;102:224-8.
- [3] Theodorou DJ, Theodorou SJ, Kakitsubata Y. Imaging of Paget Disease of Bone and Its Musculoskeletal Complications: Review. *AJR Am J Roentgenol* 2011;196:S64-75.
- [4] Caicedo AI, Escobar VE, Coy Urrea VA, Charry JS, Loaiza JH. Sporadic Paget's Disease of the Bone. *Case Series and Literature Review. Rev Colomb Reumatol (English Ed)* 2020;27:103-11.
- [5] Karunakaran K, Murugesan P, Rajeshwar G, Babu S. Paget's Disease of the Mandible. *J Oral Maxillofac Pathol* 2012;16:107-9.
- [6] Bone HG. Nonmalignant Complications of Paget's Disease. *J Bone Miner Res* 2006;21:P64-8.
- [7] Shankar YU, Misra SR, Vineet DA, Baskaran P. Paget Disease of Bone: A Classic Case Report. *Contemp Clin*

- Dent 2013;4:227-30.
- [8] Singer FR, Bone HG 3rd, Hosking DJ, Lyles KW, Murad MH, Reid IR, *et al.* Lyles, Paget's Disease of Bone: An Endocrine Society Clinical Practice Guideline. *J Clin Endocrinol Metab* 2014;99:4408-22.
- [9] Aransiola CO, Ipadeola A. Asymptomatic Paget's Disease of Bone in a 62-Year-Old Nigerian Man: Three Years Post-Alendronate Therapy. *Endocrinol Diabetes Metab Case Rep* 2016;2016:160005.
- [10] Michou L, Brown JP. Emerging Strategies and Therapies for Treatment of Paget's Disease of Bone. *Drug Des Devel Ther* 2011;5:225-39.
- [11] Durgia H, Sahoo J, Kamalanathan S, Palui R, Kumar R, Halanaik D, *et al.* Response to Zoledronic Acid in Patients with Active Paget's Disease of Bone: A Retrospective Study. *Indian J Endocrinol Metab* 2019;23:117-21.
- [12] De Castro GR, Buss ZD, Rosa JS, Facchin BM, Fröde TS. Evaluation of Bone Metabolism Biomarkers in Paget's Disease of Bone. *Cureus* 2019;11:e4791.

Publisher's note

AccScience Publishing remains neutral with regard to jurisdictional claims in published maps and institutional affiliations.