

# Usefulness of endoscopic ultrasound in children with pancreatobiliary and gastrointestinal symptoms



## Authors

Ankit Dalal, Nagesh Kamat, Gaurav Patil, Rajen Daftary, Amit Maydeo

## Institution

Baldota Institute of Digestive Sciences, Gleneagles Global Hospital, Mumbai, Maharashtra, India

submitted 26.6.2021

accepted after revision 23.8.2021

## Bibliography

Endosc Int Open 2022; 10: E192–E199

DOI 10.1055/a-1675-2291

ISSN 2364-3722

© 2022. The Author(s).

This is an open access article published by Thieme under the terms of the Creative Commons Attribution-NonDerivative-NonCommercial License, permitting copying and reproduction so long as the original work is given appropriate credit. Contents may not be used for commercial purposes, or adapted, remixed, transformed or built upon. (<https://creativecommons.org/licenses/by-nc-nd/4.0/>)

Georg Thieme Verlag KG, Rüdigerstraße 14,  
70469 Stuttgart, Germany

## Corresponding author

Dr. Ankit Dalal, Consultant Gastroenterologist, Baldota Institute of Digestive Sciences, Gleneagles Global Hospital, Mumbai, Maharashtra, India 400012  
[ankit.dalal@gmail.com](mailto:ankit.dalal@gmail.com)

## ABSTRACT

**Background and study aims** Endoscopic ultrasound (EUS) is useful in diagnosing and treating childhood pancreatobiliary and gastrointestinal diseases. However, there are limited data on its effectiveness for various indications.

**Patients and methods** This was a retrospective analysis of prospectively collected data of patients who underwent EUS for upper gastrointestinal tract disorders from January 2018 to December 2020 to assess its indications, findings, interventions, and complications.

**Results** Ninety-two procedures were performed in 85 children, (70.5% male; mean [SD] age 12.1 years [3.9] years) with a mean (SD) symptom duration of 1.1 (0.5) years. The procedures were technically successful in all patients. The primary indication for EUS was abdominal pain in 45 (52.9%) and jaundice/cholangitis in 15 patients (17.6%). General anesthesia was used in 12 (13%) and TIVA in 80 patients (87%). The most common diagnostic findings were choledocholithiasis in 21 (24.7%) and cholelithiasis in 12 patients (14.1%). Among interventions, EUS-guided cystogastrostomy for pancreatic pseudocyst was done in four patients (4.7%), and EUS-guided rendezvous for failed ERCP in one patient (1.2%) with cholangitis. There were no immediate post-procedural complications. Overall, EUS had a meaningful impact on the subsequent clinical management in 69 cases (81.2%).

**Conclusions** EUS in the pediatric population is safe, effective, and has a meaningful impact in appropriately selected cases. It can act as a rescue in major therapeutic procedures, but adequate care should be taken at the procedural level and during anesthesia.

## Introduction

Use of endoscopic ultrasound (EUS) in children is increasing but remains limited due to the lack of trained pediatric gastroenterologists and advanced centers with expertise in pediatric EUS [1,2]. The indications for EUS have been expanding in adults, many of which have now been explored in children. The prevalence of pediatric digestive diseases is increasing. EUS is an emerging tool and valuable in diagnosing and managing a varied range of childhood illnesses, pancreaticobiliary diseases,

eosinophilic esophagitis, inflammatory bowel disease, congenital anomalies, and submucosal lesions [3,4]. Its diagnostic competence with fine-needle aspiration is proven to be safe and technically successful in pediatric patients [5]. EUS is an accurate tool when compared to conventional endoscopy as to whether endoscopic or surgical resection is needed for benign/malignant lesions [6]. The diagnostic role of EUS might influence outcomes and bring about changes in management. Although various pediatric studies have been performed [7–10], the role of EUS and its utility in advanced illnesses is little ex-

plored. The purpose of this study was to look for the indications of EUS, meaningful impact, and the occurrence of complications among children with predominant upper gastrointestinal etiology.

## Patients and methods

This was a retrospective analysis of prospectively collected data from patients who underwent EUS procedures performed between January 2018 and December 2020. This study was conducted in accordance with Good Clinical Practice and in a manner to conform with the Helsinki Declaration of 1975 and its later amendments concerning human rights. The study protocol was approved by the institutional ethics committee (Approval number: IEC/OA-24/20), and waiver of consent was obtained. Indications, findings, interventions and complications of the procedures in these patients was assessed. All children had been evaluated clinically with relevant blood and radiological investigations (ultrasonography/contrast-enhanced computed tomography abdomen/MRCP) prior to EUS. In majority of the cases an upper gastrointestinal endoscopy was already done prior to EUS.

Antibiotic prophylaxis was not administered before diagnostic EUS. For interventional EUS, amoxicillin and clavulanic acid were used according to the weight of the patient. The type of anesthesia was chosen based on the patient's age, weight, and the procedure of interest. Total intravenous anesthesia (TIVA) and general anesthesia (GA) were used in this patient population. All procedures were performed by an experienced endosonographer (AD). Diagnostic EUS was performed using a combination of the radial and curvilinear echoendoscope. EUS-FNA, where indicated, and interventional EUS were performed using a curvilinear echoendoscope (GF-UCT 180, Olympus Corp, Japan). Procedures had been performed with patients in the left lateral decubitus position. A complete examination of the organ of interest was performed with standard maneuvers. Hepatopancreatobiliary evaluation was done from the stomach and duodenum. A mediastinal examination was done from the esophagus. Evaluation of subepithelial lesions was performed using a radial echoendoscope and switched to the curvilinear scope if FNA was required. The maneuvers for curvilinear EUS were done as previously described [11, 12]. EUS-FNA/B was performed using 22 or 25 gauge FNA/B needles (EchoTip ProCore Cook Medical, Bloomington, Indiana, United States; Expect, Boston Scientific Co., Natick, Massachusetts, United States; Acquire 22 G FNB needle (Boston Scientific Co., Natick, Massachusetts, United States). Color Doppler was used to identify the best position for puncture, avoiding interposing blood vessels between the target lesion. FNA was performed using the slow pull technique. Two or three needle passes were made for solid lesions. A macroscopic on-site evaluation was used for assessing tissue adequacy [13]. For cystic lesions, a single pass was carried out with near-total aspiration of the fluid content to decrease the risk of infection. Interventional procedures were performed using the 19 gauge FNA needle. Interventional procedures included drainage of pancreatic fluid collections and biliary drainage. Transmural pancreatic pseudocyst or walled off necrosis drainage was performed by EUS guided placement of

a lumen-apposing metal stent (LAMS) (15–20 mm: Hot LAMS; Boston Scientific, Marlborough, Massachusetts, United States) or a biflanged metal stent (30 mm length, 10.5 Fr, Niti-S Nagi stent, Taewoong Medical Co., Seoul, Korea). EUS guided rendezvous technique (EUS-RV) was also performed as previously described [14]. A meaningful clinical impact was observed when a definitive diagnosis was attained that altered the future course of management.

## Safety

Predefined procedural complications were classified as defined by the ASGE lexicon criterion [15]. The timeframe for assessing these was mainly during the procedure, and immediately post-procedure up to 4 hours and/or observations from referring physicians afterward. Patients who had hospitalization had an additional assessment at 24 and 48 hours.

## Statistics

Quantitative data was entered in Microsoft Excel (Office 2016 Professional for Windows; Microsoft). The statistical analysis was performed using IBM Statistical Package for the Social Sciences (SPSS) Statistics for Windows [version 23.0, Professional] (IBM Corp, Armonk, New York, United States). Missing data were analyzed using available case analysis. For categorical variables, frequency and percentage are given. For continuous variables, descriptive statistics was used (mean with standard deviation).

## Results

Eighty-five patients (70.5% male; mean [SD] age of 12.1 years [3.9]) underwent EUS procedures, and seven of them underwent a repeat EUS at follow-up. EUS was successfully completed in all patients. The major indication for EUS was abdominal pain unexplained by other imaging techniques in 45 (52.9%) and jaundice/cholangitis in 15 patients (17.6%) (► **Table 1**). GA was used in 12 (13%) and TIVA in 80 patients (87%). As per ASA classification, 73 patients were classified as ASA I, 12 patients were classified as ASA II. The mean (SD) procedural time for diagnostic EUS was 15.4 minutes (3.1). The total time of EUS-RV was 35 minutes, while EUS-guided cystogastrostomy done in four patients took on an average of 26 minutes. The commonest diagnostic findings were choledocholithiasis in 21 (24.7%) and cholelithiasis in 12 patients (14.1%) (► **Table 2**). FNB was performed in 17 cases (20%), mainly in patients with enlarged lymph nodes, subepithelial gastric lesions, and pancreatic masses. Tuberculosis was the commonest diagnosis in patients with enlarged lymph nodes. Among patients evaluated for unexplained abdominal pain and recurrent acute pancreatitis, 13 patients were diagnosed to have features of chronic pancreatitis, while 2 patients were diagnosed to have a pancreatic divisum. Patients with equivocal changes of chronic pancreatitis on the initial EUS underwent a repeat scan after three months, and two of 85 cases (2.3%) had progressive disease with parenchymal calcification. EUS was considered normal in 16 patients (18.8%). Overall, EUS had a meaningful impact on the subsequent clinical management in 69 cases (81.2%).

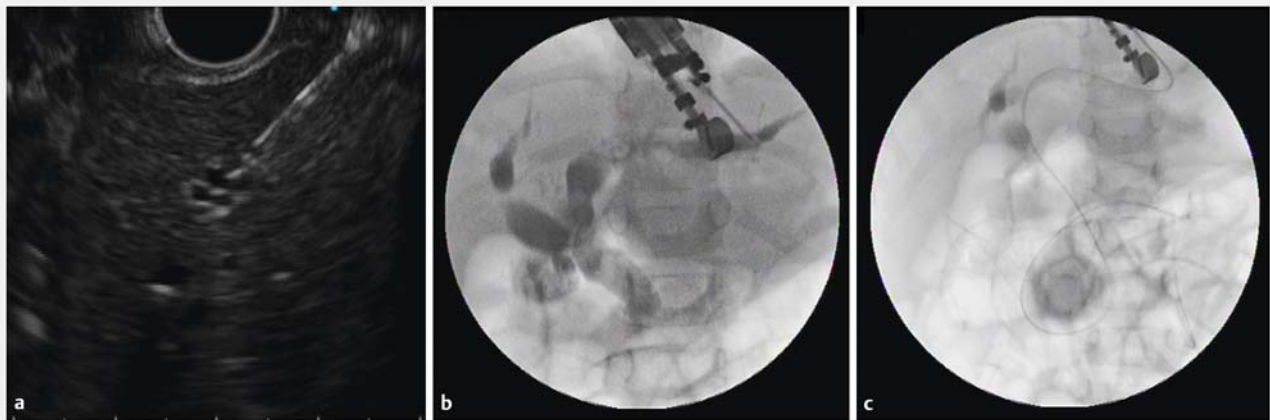
► **Table 1** Baseline characteristics.

Variable	N (%)
No. of patients	85 (100)
Age at time of EUS, mean (SD), y	12.1 (3.9)
Male	60 (70.5)
<b>Indication for procedure<sup>1</sup></b>	
▪ Abdominal pain	45 (52.9)
▪ Jaundice/cholangitis	15 (17.6)
▪ Recurrent acute pancreatitis	12 (14.1)
▪ Mediastinal lesion	8 (9.4)
▪ Lymphadenopathy	5 (5.8)
▪ Dilated biliary tract	5 (5.8)
▪ Pancreatic fluid collection	4 (4.7)
▪ Gastrointestinal submucosal lesion	4 (4.7)
Hemoglobin (g/dL)	12.9 (2.3)
Leukocytes ( $10^9 \times L$ )	6.9 (3.1)
Platelets ( $10^9 \times L$ )	214 (56.5)
Amylase (U/L)	125 (29.6)
Lipase (U/L)	145 (38.5)
Total bilirubin (mg/dL)	1.1 (0.5)
Creatinine (mg/dL)	0.9 (0.2)

<sup>1</sup> Some patients may have more than one indication.

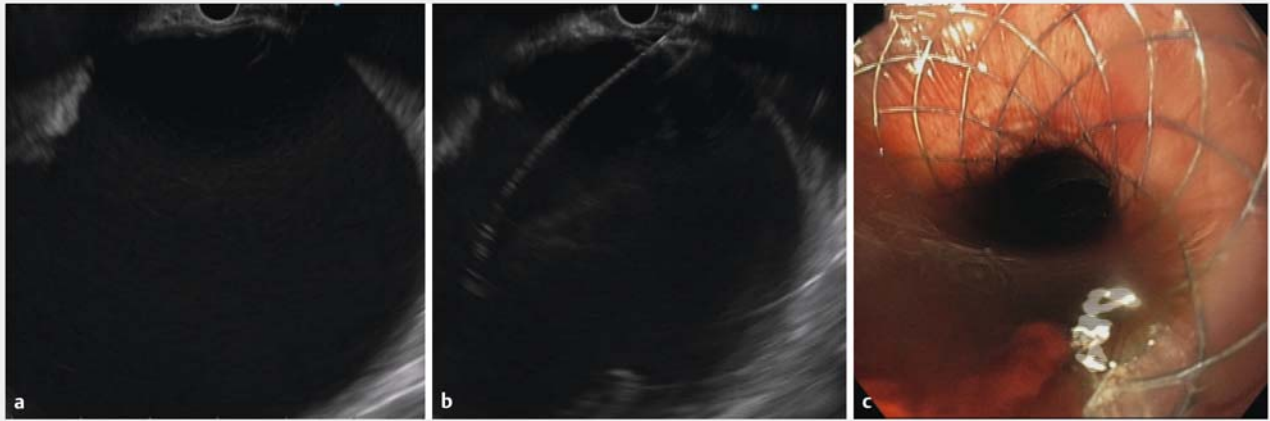
► **Table 2** Findings from EUS.

Diagnostic Findings	N (%)
▪ Choledocholithiasis	20 (23.5)
▪ Cholelithiasis/GB Microlithiasis	9 (10.6)
▪ Mediastinal Tuberculosis	9 (10.6)
▪ Chronic pancreatitis	12 (14.1)
▪ Pancreatic Pseudocyst	4 (4.7)
▪ Gastric GIST	3 (3.5)
▪ Esophageal duplication cyst	2 (2.3)
▪ Pancreatic divisum	2 (2.3)
▪ Abdominal tuberculosis (Lymph nodes)	2 (2.3)
▪ Choledochal cyst	2 (2.3)
▪ Pseudopapillary tumor of the pancreas	2 (2.3)
▪ Biliary Ascariasis	1 (1.2)
▪ Non Hodgkin Lymphoma	1 (1.2)
<b>Interventions</b>	
▪ EUS Rendezvous for failed ERCP in patient with cholangitis	1 (1.2)
▪ EUS-Guided Cystogastrostomy for pancreatic Pseudocyst	4 (4.7)
Normal EUS findings	16 (18.8)
General anesthesia	12 (13)
TIVA	80 (87)
Meaningful Impact	69 (81.2)

► **Fig. 1 a–c** EUS-guided rendezvous for failed ERCP in a patient with cholangitis.

Among interventions, EUS-guided rendezvous was done after failed endoscopic retrograde cholangiopancreatography (ERCP) in one patient (1.2%) with cholangitis with failed biliary cannulation after precut papillotomy (► **Fig. 1a**, ► **Fig. 1b**, and ► **Fig. 1c**) and EUS-guided cystogastrostomy for pancreatic

pseudocyst was done in four patients (4.7%) (► **Fig. 2a**, ► **Fig. 2b**, ► **Fig. 2c**). In patients with pseudocyst with abdominal pain and fever, transgastric drainage was performed by placing a LAMS (Hot AXIOS, Boston Scientific, United States) in two patients and a biflanged metal stent (Niti-S Nagi stent, Korea) in



► **Fig. 2a–c** EUS-guided cystogastrostomy for pancreatic pseudocyst.

the other two. After 4 weeks, CT imaging was done to confirm the cyst resolution, and the stent was removed endoscopically. In 21 patients diagnosed with CBD calculi, ERCP for stone retrieval was performed in the same session. In 12 patients with cholelithiasis, subsequent laparoscopic cholecystectomy was performed. Two patients who were diagnosed with GIST on EUS-guided FNB underwent laparoscopic resection. The endoscopy images of various pathologies have been provided in ► **Fig. 3a–i**. Patients who had mediastinal and abdominal TB, received a four-drug antitubercular regimen to which all responded well. Patients in whom no organic cause was found were managed as having functional abdominal pain. FNA for a mediastinal mass in three other patients was inconclusive. For diagnostic EUS, there were no intraoperative, delayed post-procedure, or anesthesia-related complications. For interventional procedures, mild abdominal pain was encountered in three patients who had undergone cystogastrostomy and they were treated symptomatically with analgesics.

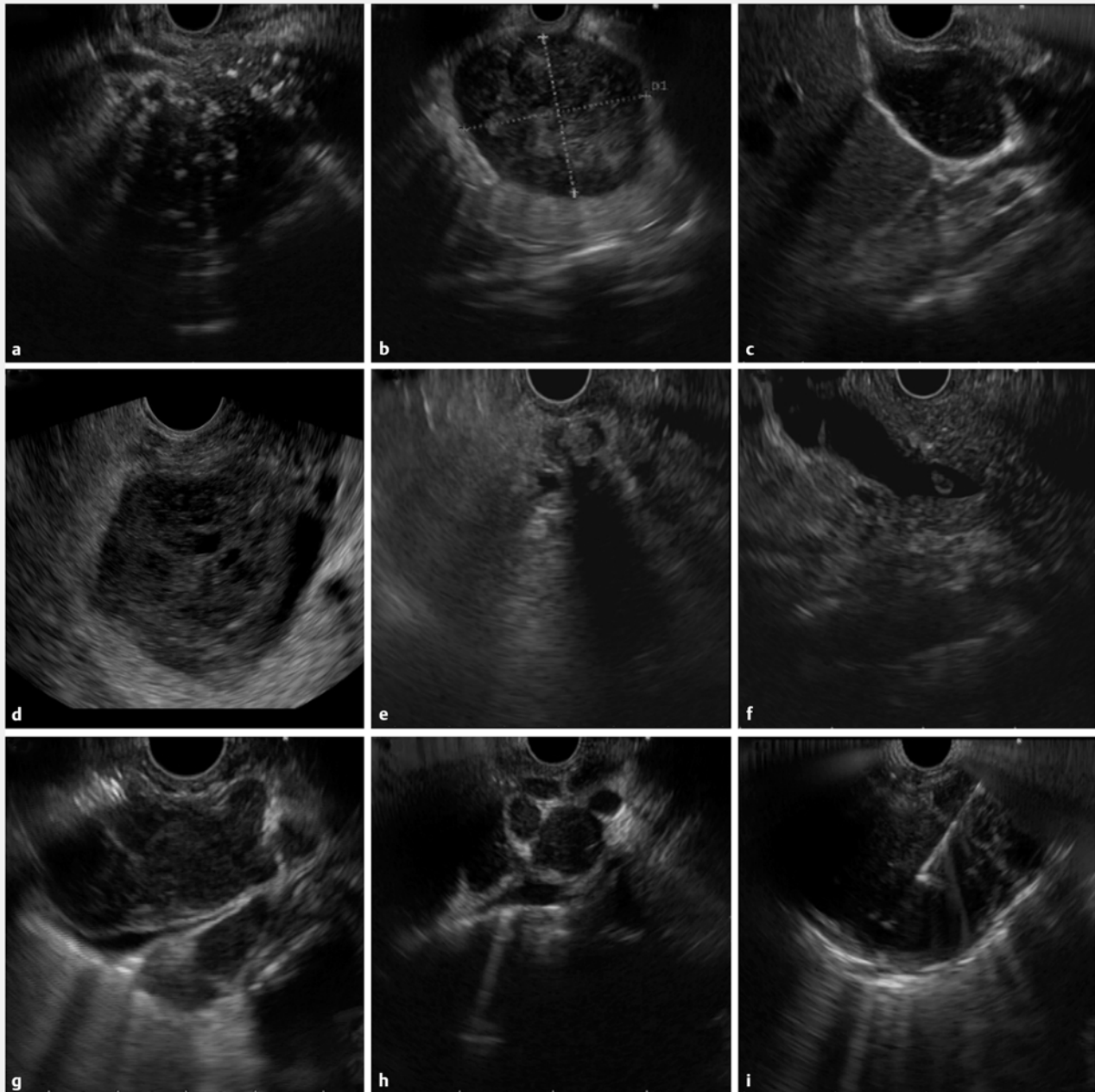
## Discussion

By retrospectively analyzing patients over 3 years, we studied the utility of EUS in pediatric patients. EUS proved useful in diagnosis of gastrointestinal and pancreatobiliary diseases. It also provided vital information on chronic pancreatitis, cholangitis, mediastinal tuberculosis, and follow-up of patients with pseudocyst. EUS is infrequently used due to its limited indications in pediatric patients. There have been a handful of studies looking at utility of EUS in children. EUS has evolved from a diagnostic modality to a therapeutic interventional procedure. The therapeutic procedures such as EUS-guided pseudocyst drainage or EUS-guided rendezvous that have been reported in this study have rarely been reported in previous studies. To the best of our knowledge, our study represents the second largest case series addressing the feasibility and the safety of EUS in the pediatric population.

General anesthesia is favored in young children undergoing complex EUS procedures. Many factors affect the choice of se-

dition during pediatric EUS procedures, including: nature and duration of the procedure, the ASA classification of the patient, anticipated cooperation of the patient, anesthetist comfort and preference, patients age, endosonographer, and parents [16]. We safely used TIVA for the majority (87%) of the cases, while GA remains an option. Most of the studies in the pediatric population have used GA, while some have used TIVA with propofol. Currently there are no clear-cut guidelines on when to use TIVA or GA in children undergoing EUS procedures. At our center, we prefer to use TIVA with propofol as the prime drug, because it has a predictable and rapid recovery profile with lower incidence of post-operative nausea and vomiting. Glycopyrrolate negates bradycardia induced by propofol and also serves as an antisialagogue. Lignocaine reduces the pain associated with propofol intravenous injection, reduces the cough reflex, and prevents laryngospasm. Nalbuphine is used as an opioid analgesic. However, when need arises TIVA can be switched over to GA. For children who undergo pseudocyst drainage and other interventional procedures, it is always advisable to use GA. Pharmacoeconomic studies on the cost of TIVA vs. GA for EUS in pediatric patients is currently unavailable.

Adult gastroenterologists carry out the majority of EUS procedures in pediatric population. This trend may continue for some time due to the limited availability of pediatric gastroenterologists trained in EUS. EUS when done by experts is safe, and has good clinical outcomes among pediatric patients with low complications, as seen in this study. MRCP and EUS are radiation-free and very useful in the detection of pancreatobiliary diseases yielding good diagnostic accuracy. MRCP is safe and noninvasive, but may require sedation to avoid movement artifacts in young children. CT cannot evaluate certain pancreatobiliary abnormalities. ERCP has a good diagnostic capability for biliary pathologies, but the complication rates range from 3.4% to 28.5% in children [17, 18]. EUS has good sensitivity and specificity for microlithiasis, and choledocholithiasis, with 33 patients were diagnosed with gallstone or CBD calculi in our study. It can prevent unnecessary ERCP in pediatric cases. The ASGE guidelines for suspected choledocholithiasis recom-



► **Fig. 3** **a** Chronic calcific pancreatitis with multiple calculi. **b** Large gastric GIST. **3c** Gallbladder sludge with microlithiasis. **d** Pseudopapillary tumor of pancreas. **e** Choledocholithiasis. **f** Choledocholithiasis. **g** Mediastinal lymph node with tuberculosis. **h** Mediastinal tuberculosis. **i** Mediastinal lymph node biopsy.

mends using a non-invasive test, such as EUS or MRCP, prior to ERCP [19]. In one patient of pancreatic divisum, MRCP was inconclusive but EUS confirmed the same. In the second patient, EUS showed the presence of pancreatic divisum which was later confirmed on MRCP before proceeding for endotherapy. Similarly, in patients in whom cholelithiasis and choledocholithiasis was missed on ultrasound of abdomen, but correctly diagnosed on EUS have been included for meaningful impact. By utilizing EUS in patient management, it has had an impact on the clinical management of cases from 35.5% to 93%. The meaningful im-

pact on the subsequent clinical management in our study was 69(81.2%) (► **Table 3**). All these studies (► **Table 4**) suggest that EUS is safe and effective in the pediatric population when performed by expert endosonographers. EUS is believed to have superior imaging qualities for pancreatic diseases, especially early diagnosis of CP [20]. The present study findings are similar to those found across the world for early diagnosis of CP. EUS whenever done carefully and by experts, can be a useful tool both for detection of CP and monitoring disease progres-

► **Table 3** Comparison of pre-EUS findings with meaningful impact during EUS.

Pre-EUS findings	Meaningful impact, n = 69 <sup>1</sup>
Abdominal pain	Choledocholithiasis
	Cholelithiasis/gallbladder microlithiasis
	Non-Hodgkin lymphoma
	Chronic pancreatitis
	Pancreatic pseudocyst
	Pseudopapillary tumor of the pancreas
Jaundice/cholangitis	Choledocholithiasis
	Choledochal cyst
	Biliary ascariasis
Recurrent acute pancreatitis	Chronic pancreatitis
	Pancreatic divisum
Gastrointestinal submucosal lesion	Esophageal duplication cyst
	Gastric GIST
Mediastinal lesion	Mediastinal tuberculosis
Lymphadenopathy	Abdominal tuberculosis (lymph nodes)

EUS, endoscopic ultrasound; GIST, gastrointestinal stromal tumor.  
<sup>1</sup> Some patients may have more than one finding.

sion. Identification of patients with CP among the acute recurrent pancreatitis cases is useful for counseling on prognosis.

Pancreatic pseudocysts were initially drained surgically or percutaneously. Over time, pancreatic fluid collections are predominantly drained endoscopically, especially with EUS guidance. Cystogastrostomy in children has got good success rate, as seen with four of our cases (100%). It is advisable to utilize endoscopic drainage when feasible as it has good outcomes [6].

EUS can differentiate gastrointestinal wall layers, thereby helping to identify mucosal/submucosal lesions [21]. Malignant tumors of the digestive system in children account for about 1% of the cases [22]. Among gastric tumors seen in the pediatric population are lymphomas and sarcomas. One child in our study had non-Hodgkin lymphoma and two patients had GIST. The former was referred to a nearby oncology institute for further management. EUS is commonly used for drainage of intraabdominal abscesses in children, with a reported improvement rate of 50% to 80% [23, 24]. The ASGE Technology Committee provides guidance on the EUS equipment for pediatric endoscopy [25]. For patients weighing <15 kg, “through-the-scope miniprbes with frequencies ranging from 12 to 30 MHz may be used through standard gastroscopes with a 2.8-mm working channel” [25].

Complications of diagnostic EUS are extremely rare. The risk of pancreatitis has been described in patients undergoing FNA of pancreatic lesions, with rates ranging from 0.44% to 2% [26, 27]. Bile peritonitis is also a risk unique to EUS. The incidence

rate for EUS-related complications by Mahajan et al. ranged between 1.96% and 7.1%, which was reported in only four studies [4]. Complications included mild pancreatitis after FNA of solid pancreatic lesions, fever, and bleeding after EUS-guided cystogastrostomy, and anesthesia-related complications (hypoxia due to airway obstruction and laryngospasm). However, in our case, we did not encounter any complications.

Of late, there have been some unique pediatric cases that have been successfully managed. EUS-guided HotAxios was used to treat a traumatic pancreatic pseudocyst in a 12-year-old child by Ardengh JC et al. in 2020 [28]. EUS-guided pancreatic duct rendezvous was done in a child with traumatic pancreatic duct disruption [29].

Successful EUS-guided drainage was achieved of an intra-abdominal abscess in a 1-year-old infant by Ito Y et al. in 2016 [30]. The youngest child known to have undergone EUS was 0.5 months old [31]. All these cases show that EUS can be safely performed in children of all age groups. However, we feel EUS is not ideal in children younger than age 2 years, in children with esophageal strictures, and those who have low body weight.

The study does have its limitations. First, it was a single centered retrospective study with a small sample size and noncomparative design; a larger patient group would have been ideal for this population. Combining data from multiple centers may overcome the limitations of a small sample size. Being a tertiary referral center, the study might have included a selected subset of referred patients; thereby an element of referral bias might exist, the results of which may not be generalizable outside of this environment. Retrospective studies can miss major clinical events. There may be misclassification bias. There may also be an element of selection bias that might have contributed to the results. But retrospective studies play a major role in health research, especially when evidence from randomized studies is not available or not feasible. Nevertheless, the findings from this study add to the current pool of existing knowledge and provide a reference for future studies in India and across the world.

## Conclusions

To summarize, the utility of EUS among the studied pediatric population appears safe and effective for the diagnosis and treatment of upper gastrointestinal tract disorders. EUS in our study had a positive meaningful impact on the clinical management of children. Adequate care should be exercised, especially during therapeutic interventions and with anesthesia care. The cost implications appear to hinder routine diagnostic use of EUS and need to be analyzed in well-controlled studies.

## Acknowledgements

The authors thank Mr. Sehajad Vora and Ms. Shubhada Sawant for assisting with the procedures. They are grateful to Mr. Milind Jadhav for editing the endoscopic images.

► **Table 4** Endoscopic ultrasound in pediatric patients from selected published studies.

Authors, year	Country	Study design, follow-up	Patients	Procedures	Age in years, range	Gender	Anesthesia N (%)	Meaningful impact, %	Complications
Roseau G et al. 1998 [10]	France	Retrospective 1987–1994	18	23	4–16	–	DS 100 %	–	–
Varadarajulu S et al. 2005 [6]	USA	Prospective 2001–2004	14	15	5–17	M 64 %	GA 100 %	93	–
Bjerring OS et al. 2008 [9]	Denmark	Retrospective 1992–2006	18	18	0.5–15	M 67 %	GA 100 %	78	–
Cohen S et al. 2008 [32]	Israel	Retrospective 1999–2005	32	32	1.5–18	M 65 %	CS 56 % GA 38 %	44	–
Attila T et al. 2009 [8]	USA	Retrospective 2001–2008	38	40	3–17	M 58 %	GA 67.5 % DS 22.5 % CS 10 %	–	–
Al-Rashdan A et al. 2010 [7]	USA	Retrospective 2000–2008	56	58	4–18	F 62.5 %	DS 73 % GA 17 % CS 6 %	86	–
Scheers I et al. 2015 [33]	Belgium	Retrospective 2000–2014	48	52	2–17	F 60.4 %	GA 86 % DS 14 %	98	3.8 %
Jia Y et al. 2015 [34]	USA	Retrospective 2011–2014	5	6	6–17	F 60 %	GA 100 %	100	–
Mahajan R et al. 2016 [4]	India	Retrospective 2006–2014	121	125	3–18	M 58 %	CS 65 % GA 35 %	35.5	2.4 %
Fugazza A et al. 2017 [3]	Italy	Retrospective 2010–2016	40	47	3–18	M 55 %	DS 48.9 % GA 21.3 %	87.2	–
Raina A et al. 2017 [35]	USA	Retrospective 2007–2012	58	70	6–21	M 50 %	GA 57 % MAC 29 % MS 14 %	88	12 %
Gordon K et al. 2016 [36]	USA	Retrospective 2005–2012	43	51	4–18	F 69.8 %	–	80	2.3 %
Singh SK et al. 2018 [37]	India	Prospective 2015–2016	32	35	8–18	M 68.7 %	CS 100 %	–	–
Téllez-Ávila et al. 2019 [38]	Mexico	Retrospective 2009–2016	54	54	9–17	F 59.3 %	DS 100 %	–	–
Altonbary AY et al. 2020 [39]	Egypt	Retrospective 2016–2020	13	13	6–18	F 61.5 %	TIVA 100 %	77	–
Our study	India	Retrospective 2018–2020	85	92	5–18	M 70.5 %	GA 13 % TIVA 87 %	81.2	–

MS, moderate sedation; MAC, monitored anesthesia care; GA, general anesthesia; CS, conscious sedation.

## Competing interests

The authors declare that they have no conflict of interest.

## References

- [1] Dhir V, Paramasivam RK, Lazaro JC et al. The role of therapeutic endoscopic ultrasound now and for the future. *Expert Rev Gastroenterol Hepatol* 2014; 8: 775–791
- [2] Bizzarri B, Nervi G, Ghiselli A et al. Endoscopic ultrasound in pediatric population: a comprehensive review of the literature. *Acta Biomed* 2018; 89: 33–39
- [3] Fugazza A, Bizzarri B, Gaiani F et al. The role of endoscopic ultrasound in children with Pancreatobiliary and gastrointestinal disorders: a single center series and review of the literature. *BMC Pediatr* 2017; 17: 203
- [4] Mahajan R, Simon EG, Chacko A et al. Endoscopic ultrasonography in pediatric patients—Experience from a tertiary care center in India. *Indian J Gastroenterol* 2016; 35: 14–19

- [5] Raina A, Conrad MA, Sahn B et al. Endoscopic ultrasound with or without fine-needle aspiration has a meaningful impact on clinical care in the pediatric population. *Endosc Ultrasound* 2017; 6: 195–200
- [6] Varadarajulu S, Wilcox CM, Eloubeidi MA. Impact of EUS in the evaluation of pancreaticobiliary disorders in children. *Gastrointest Endosc* 2005; 62: 239–244
- [7] Al-Rashdan A, LeBlanc J, Sherman S et al. Role of endoscopic ultrasound for evaluating gastrointestinal tract disorders in pediatrics: A tertiary care center experience. *J Pediatr Gastroenterol Nutr* 2010; 51: 718–722
- [8] Attila T, Adler DG, Hilden K et al. EUS in pediatric patients. *Gastrointest Endosc* 2009; 70: 892–898
- [9] Bjerring OS, Durup J, Qvist N et al. Impact of upper gastrointestinal endoscopic ultrasound in children. *J Pediatr Gastroenterol Nutr* 2008; 47: 110–113
- [10] Roseau G, Palazzo L, Dumontier I et al. Endoscopic ultrasonography in the evaluation of pediatric digestive diseases: Preliminary results. *Endoscopy* 1998; 30: 477–481
- [11] Dhir V, Adler DG, Pausawasdi N et al. Feasibility of a complete pancreatobiliary linear endoscopic ultrasound examination from the stomach. *Endoscopy* 2018; 50: 22–32
- [12] Yamao K, Irisawa A, Inoue H et al. Standard imaging techniques of endoscopic ultrasound-guided fine-needle aspiration using a curved linear array echoendoscope. *Dig Endosc* 2007; 16: S180–S205
- [13] Iwashita T, Yasuda I, Mukai T et al. Macroscopic on-site quality evaluation of biopsy specimens to improve the diagnostic accuracy during EUS-guided FNA using a 19-gauge needle for solid lesions: a single-center prospective pilot study (MOSE study). *Gastrointest Endosc* 2015; 81: 177–185
- [14] Dhir V, Bhandari S, Bapat M et al. Comparison of EUS-guided rendezvous and precut papillotomy techniques for biliary access (with videos). *Gastrointest Endosc* 2012; 75: 354–359
- [15] Cotton PB, Eisen GM, Aabakken L et al. A lexicon for endoscopic adverse events: report of an ASGE workshop. *Gastrointest Endosc* 2010; 71: 446–454
- [16] Oh SH. Sedation in pediatric esophagogastroduodenoscopy. *Clin Endosc* 2018; 51: 120–128
- [17] De Castro VL, Moura EG, Chaves DM et al. Endoscopic ultrasound versus magnetic resonance cholangiopancreatography in suspected choledocholithiasis: A systematic review. *Endosc Ultrasound* 2016; 5: 118–128
- [18] Kieling CO, Hallal C, Spessato CO et al. Changing pattern of indications of endoscopic retrograde cholangiopancreatography in children and adolescents: a twelve-year experience. *World J Pediatr* 2015; 11: 154–159
- [19] Buxbaum JL, Abbas Fehmi SM. ASGE Standards of Practice Committee. et al. ASGE guideline on the role of endoscopy in the evaluation and management of choledocholithiasis. *Gastrointest Endosc* 2019; 89: 1075–1105
- [20] Domínguez-Munoz JE, Larino-Noia J, Alvarez-Castro A et al. Endoscopic ultrasound-based multimodal evaluation of the pancreas in patients with suspected early chronic pancreatitis. *United Eur Gastroenterol J* 2020; 8: 790–797
- [21] Gong EJ, Kim DH. Endoscopic ultrasonography in the diagnosis of gastric subepithelial lesions. *Clin Endosc* 2016; 49: 425–433
- [22] Brecht IB, Graf N, Schweinitz D et al. Networking for children and adolescents with very rare tumors: foundation of the GPOH Pediatric Rare Tumor Group. *Klin Padiatr* 2009; 221: 181–185
- [23] Gervais DA, Ho CH, O'Neill MJ et al. Recurrent abdominal and pelvic abscesses: incidence, results of repeated percutaneous drainage, and underlying causes in 956 drainages. *AJR Am J Roentgenol* 2004; 182: 463–466
- [24] vanSonnenberg E, Wittich GR, Goodacre BW et al. Percutaneous abscess drainage: update. *World J Surg* 2001; 25: 362–369
- [25] Barth BA, Banerjee S. ASGE Technology Committee. et al. Equipment for pediatric endoscopy. *Gastrointest Endosc* 2012; 76: 8–17
- [26] Gress F, Michael H, Gelrud D et al. EUS-guided fine-needle aspiration of the pancreas: evaluation of pancreatitis as a complication. *Gastrointest Endosc* 2002; 56: 864–867
- [27] Wang KX, Ben QW, Jin ZD et al. Assessment of morbidity and mortality associated with EUS-guided FNA: a systematic review. *Gastrointest Endosc* 2011; 73: 283–290
- [28] Ardengh JC, Taglieri E, Ardengh AO et al. EUS-Guided Hotaxios for the treatment of traumatic pancreatic pseudocyst in pediatric patient. *Arq Gastroenterol* 2020; 57: 339–340
- [29] Ishii K, Itoi T, Tsuchiya T et al. EUS-guided pancreatic duct rendezvous in a child with traumatic pancreatic duct disruption. *Gastrointest Endosc* 2014; 80: 519–520
- [30] Ito Y, Isayama H, Nakai Y et al. Successful Endosonography-Guided Drainage of an Intra-Abdominal Abscess in a 1-Year-Old Infant. *Gut Liver* 2016; 10: 483–485
- [31] Kouchi K, Yoshida H, Matsunaga T et al. Endosonographic evaluation in two children with esophageal stenosis. *J Pediatr Surg* 2002; 37: 934–936
- [32] Cohen S, Kalinin M, Yaron A et al. Endoscopic ultrasonography in pediatric patients with gastrointestinal disorders. *J Pediatr Gastroenterol Nutr* 2008; 46: 551–554
- [33] Scheers I, Ergun M, Aouattah T et al. Diagnostic and therapeutic roles of endoscopic ultrasound in pediatric pancreaticobiliary disorders. *J Pediatr Gastroenterol Nutr* 2015; 61: 238–247
- [34] Jia Y, Maspons A, Othman MO. The therapeutic use of endoscopic ultrasonography in pediatric patients is safe: A case series. *Saudi J Gastroenterol* 2015; 21: 391–395
- [35] Raina A, Conrad MA, Sahn B et al. Endoscopic ultrasound with or without fine-needle aspiration has a meaningful impact on clinical care in the pediatric population. *Endosc Ultrasound* 2017; 6: 195–200
- [36] Gordon K, Conway J, Evans J et al. EUS and EUS-Guided Interventions Alter Clinical Management in Children with Digestive Diseases. *J Pediatr Gastroenterol Nutr* 2016; 63: 242–246
- [37] Singh SK, Srivastava A, Rai P et al. Yield of Endoscopic Ultrasound in Children and adolescent with Acute Recurrent Pancreatitis. *J Pediatr Gastroenterol Nutr* 2018; 66: 461–465
- [38] Téllez-Ávila FI, Duarte-Medrano G, Herrera-Mora D et al. Endoscopic ultrasound in pediatric patients with pancreaticobiliary disease. *Surg Laparosc Endosc Percutan Tech* 2019; 29: 271–274
- [39] Altonbary AY, Hakim H, Elkashef W. Role of endoscopic ultrasound in pediatric patients: A single tertiary center experience and review of the literature. *World J Gastrointest Endosc* 2020; 12: 355–364