



ELSEVIER

Contents lists available at ScienceDirect

JSES International

journal homepage: [www.jsesinternational.org](http://www.jsesinternational.org)

## No difference in long-term outcome between open and arthroscopic rotator cuff repair: a prospective, randomized study

Anita Hasler, MD <sup>a,\*</sup>, Silvan Beeler, MD <sup>a</sup>, Tobias Götschi, MSc ETH <sup>b,c</sup>,  
Sabrina Catanzaro, RN <sup>a</sup>, Bernhard Jost, MD <sup>d</sup>, Christian Gerber, MD, FRCS <sup>a</sup>

<sup>a</sup> Department of Orthopaedics, Balgrist University Hospital, Zürich, Switzerland

<sup>b</sup> Unit for Clinical and Applied Research, Balgrist University Hospital, Zürich, Switzerland

<sup>c</sup> Institute for Biomechanics, ETH Zürich, Zürich, Switzerland

<sup>d</sup> Department of Orthopaedics and Traumatology, Kantonsspital St. Gallen, St. Gallen, Switzerland

### ARTICLE INFO

#### Keywords:

Long-term outcome  
rotator cuff tear  
open vs. arthroscopic  
shoulder  
deltoid attenuation  
cuff integrity

Level of evidence: Level II; Randomized  
Controlled Trial; Treatment Study

**Background:** Arthroscopic rotator cuff repair techniques have almost replaced open repairs. Short- and mid-term studies have shown comparable outcomes, with no clear superiority of either procedure. The aim of this study was to compare the long-term clinical and imaging outcomes following arthroscopic or open rotator cuff repair.

**Methods:** Forty patients with magnetic resonance imaging (MRI)–documented, symptomatic supraspinatus or supraspinatus and infraspinatus tears were randomized to undergo arthroscopic or open rotator cuff repair. Clinical and radiographic follow-up was obtained at 6 weeks, 3 months, 1 year, 2 years, and >10 years postoperatively. Clinical assessment included measurement of active range of motion, visual analog scale score for pain, functional scoring according to the Constant–Murley score (CS), and assessment of the Subjective Shoulder Value. Imaging included conventional radiography and MRI for the assessment of cuff integrity and alteration of the deltoid muscle.

**Results:** We enrolled 20 patients with a mean age of 60 years (range, 50–71 years; standard deviation [SD], 6 years) in the arthroscopic surgery group and 20 patients with a mean age of 55 years (range, 39–67 years; SD, 8 years) in the open surgery group. More than 10 years' follow-up was available for 13 patients in the arthroscopic surgery group and 11 patients in the open surgery group, with mean follow-up periods of 13.8 years (range, 11.9–15.2 years; SD, 1.1 years) and 13.1 years (range, 11.7–15 years; SD, 1.1 years), respectively. No statistically significant differences in clinical outcomes were identified between the 2 groups: The median absolute CS was 79 points (range, 14–84 points) in the arthroscopic surgery group and 84 points (range, 56–90 points) in the open surgery group ( $P = .177$ ). The median relative CS was 94% (range, 20%–99%) and 96% (range, 65%–111%), respectively ( $P = .429$ ). The median Subjective Shoulder Value was 93% (range, 20%–100%) and 93% (range, 10%–100%), respectively ( $P = .976$ ). MRI evaluation showed a retear rate of 30% equally distributed between the 2 groups. Neither fatty infiltration of the deltoid muscle, deltoid muscle volume, nor the deltoid origin were different between the 2 groups.

**Conclusion:** In a small cohort of patients, we could not document any difference in clinical and radiographic outcomes at long-term follow-up between arthroscopic and open rotator cuff repair. The postulated harm to the deltoid muscle with the open technique could not be confirmed.

© 2020 University hospital Balgrist. Published by Elsevier Inc. on behalf of American Shoulder and Elbow Surgeons. This is an open access article under the CC BY-NC-ND license (<http://creativecommons.org/licenses/by-nc-nd/4.0/>).

There is consensus that for a symptomatic full-thickness rotator cuff tear (RCT) with grade  $\leq 2$  fatty infiltration according to the Goutallier classification, rotator cuff repair yields better long-term

outcomes than conservative treatment.<sup>26</sup> RCT repair can be performed using an open or mini-open technique or an arthroscopic technique. Currently, arthroscopic repair of the RCT is progressively replacing open repair.<sup>3,29,37</sup> The proportion of repairs performed arthroscopically increased from 57% in 2007 to 75% in 2015.<sup>14</sup> Many short-term studies comparing these 2 techniques have shown similar clinical outcomes.<sup>1,5–8,22,24,35,36,38,40</sup> Even regarding effectiveness, the procedures seem equal.<sup>1,8</sup> In terms of long-term follow-up, there is only 1 retrospective study, with a 10-year

The study protocol was approved by the responsible ethical committee (KEK-ZH-Nr.2018-00660).

\* Corresponding author: Anita Hasler, MD, Department of Orthopaedics, Balgrist University Hospital, Forchstrasse 340, 8008, Zürich, Switzerland.

E-mail address: [anita.hasler@balgrist.ch](mailto:anita.hasler@balgrist.ch) (A. Hasler).

<https://doi.org/10.1016/j.jseint.2020.08.005>

2666–6383/© 2020 University hospital Balgrist. Published by Elsevier Inc. on behalf of American Shoulder and Elbow Surgeons. This is an open access article under the CC BY-NC-ND license (<http://creativecommons.org/licenses/by-nc-nd/4.0/>).

follow-up, reporting equal results regarding cuff integrity after repair.<sup>2</sup> To our knowledge, there have been no randomized controlled studies reporting on the long-term outcomes of open vs. arthroscopic rotator cuff repair; however, this may be important as small differences in short-term outcomes only reach importance in the long term. Failure of a rotator cuff repair can require a revision rotator cuff repair<sup>15,23,33</sup> or tendon transfer or, if irreparable, reverse total shoulder replacement (reverse total shoulder arthroplasty [RTSA]). For optimal functional outcomes following RTSA, an intact and functioning deltoid muscle is mandatory. To our knowledge, the long-term integrity of the deltoid muscle and its insertion has never been studied with advanced imaging methods but is at risk especially after open cuff repair.

We hypothesized that arthroscopic and open rotator cuff repair would provide equal long-term shoulder function and structural integrity. We also hypothesized that arthroscopic RCT repair would cause less damage to the deltoid insertion than the open procedure.

## Methods

### Patients

The trial was conducted at a single hospital (Balgrist University Hospital, Zürich, Switzerland) and involved 3 senior shoulder surgeons. The surgeons were experienced in both open and arthroscopic RCT repair techniques. Over a 5-year period (2003–2007), each consecutive patient who underwent unsuccessful conservative treatment for  $\geq 6$  months, who had unaccepted pain and/or weakness caused by a full-thickness tear of the supraspinatus tendon, and who consented to participate in the study was prospectively included.

### Patient selection

Sample size estimation revealed a minimum required number of 18 subjects per group to detect a minimal clinically important difference of 4.6 points in the Constant-Murley score (CS)<sup>13</sup> with a power of 0.90 and  $P = .05$  assuming a Cohen effect size of 1.

Patients meeting the inclusion criteria were informed that the hypothesis was that both techniques would yield very similar results: This led to substantial difficulties in recruiting, because with comparable expected outcomes, most patients preferred to be treated arthroscopically rather than to be enrolled in the study. If patients agreed to be part of the study, they were randomized to either open or arthroscopic RCT repair. Randomization was performed with opaque numbered envelopes with the procedure listed inside. Randomization resulted in 20 patients per group. The patients in this trial were assessed clinically and radiographically with plain radiographs and magnetic resonance imaging (MRI) before surgery and 3 months, 1 year, 2 years, and if possible, >10 years after surgery.

Regarding long-term follow-up (>10 years), 11 patients in the open surgery group and 13 patients in the arthroscopic surgery group were assessed with >10 years' clinical and radiographic follow-up. Five patients died independently of surgery during the follow-up period, but 3 of them had a re-tear at their last follow-up and were included in the analysis. Seven patients were not willing to undergo clinical and radiographic follow-up but reported good shoulder function without a revision performed on the affected shoulder. Additionally, 2 patients underwent a revision before 10 years' follow-up was reached (1 conversion to RTSA and 1 revision RCT repair). Two patients could not be contacted at all despite written and telephone attempts. Details of the inclusion and exclusion criteria, as well as loss to follow-up, are documented in [Figure 1](#).

### Surgical techniques and postoperative care

Surgery was performed with the patient either under general and interscalene anesthesia or under interscalene anesthesia alone in the beach-chair position. On the basis of clinical and intraoperative findings, an additional biceps tenotomy or tenodesis, acromioplasty, and/or acromioclavicular (AC) joint resection was performed.

### Open RCT repair

An anterosuperior incision was used in all cases. The lateral deltoid was detached with a thin sharp osteotome including a thin piece of the lateral acromion starting at the anterior and lateral edge of the acromion. The anterior deltoid was left alone. The RCT was exposed through a deltoid split from the anterolateral tip of the acromion respecting the fiber orientation. The cuff underwent modified repair with 2–4 Mason-Allen stitches (No. 2 FiberWire; Arthrex, Naples, FL, USA) and transosseous fixation with a cortical bone augmentation device (DePuy Synthes, Raynham, MA, USA). At the end of the procedure, the deltoid muscle was reattached with 2 transosseous stitches (No. 2 FiberWire or No. 3 Ethibond [Ethicon, Somerville, NJ, USA]) and a No. 0 running polydioxanone suture (Ethicon) to repair the muscle fascia.

### Arthroscopic RCT repair

The arm was held in a dedicated pneumatic arm holder (Spider; Tenet Medical Engineering, Calgary, Alberta, Canada). A diagnostic arthroscopy was performed. After débridement of the footprint, bony titanium anchors (Twinfix anchors with Ultrabraid suture; Smith & Nephew, London, United Kingdom) were placed in the supraspinatus footprint, with the size of the tear dictating the number of anchors. A single-row technique with simple and/or mattress stitches was used in all cases.

### Postoperative procedures and rehabilitation

Postoperatively, both groups received paracetamol and cyclooxygenase 2 inhibitors as analgesia, and all patients wore an abduction brace for 6 weeks. Postoperative mobilization was performed under the supervision of a physiotherapist. Passive abduction in neutral rotation was allowed in the first 6 weeks. Active mobilization was started at 6 weeks, with strengthening exercises after 12 weeks.

### Clinical assessment

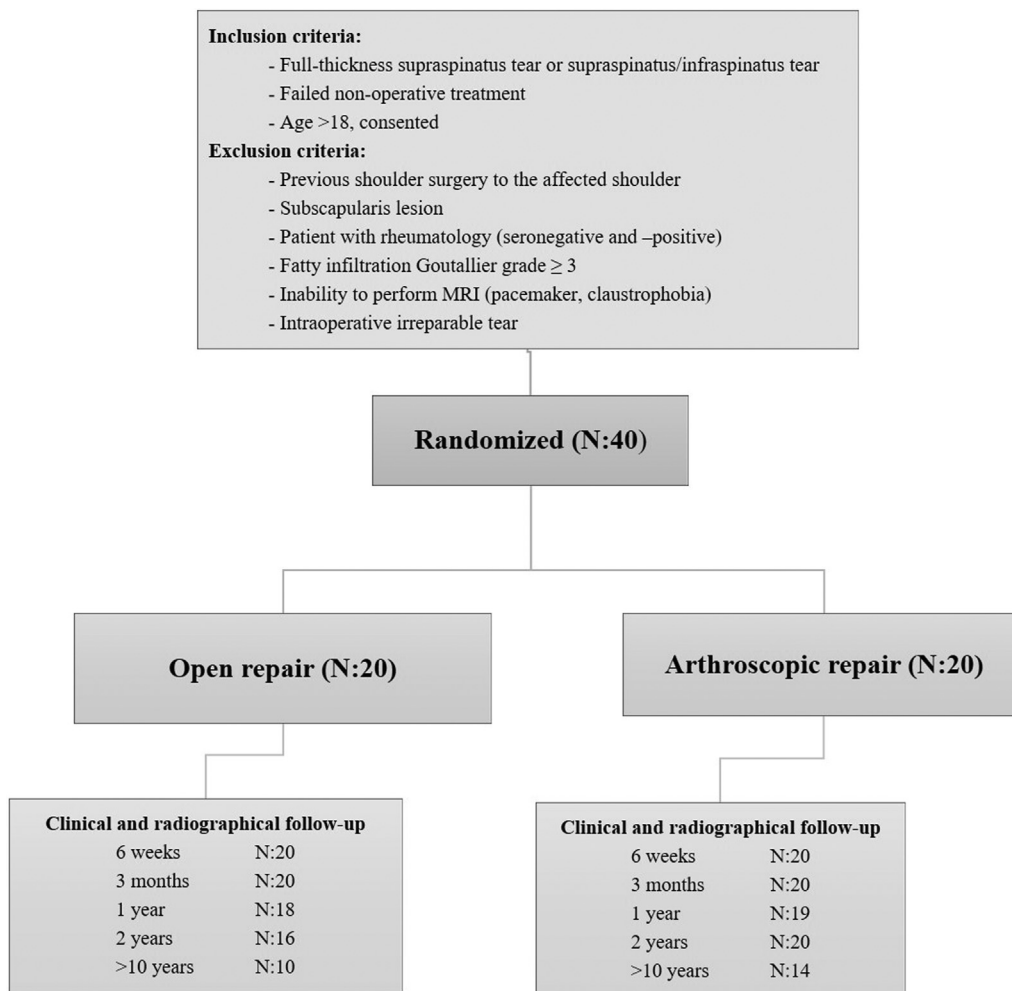
Patients were clinically assessed with a structured interview and a detailed physical examination. Baseline characteristics including rupture cause and nicotine abuse were recorded, and all surgical complications were documented intraoperatively and at every follow-up appointment.

Each patient was evaluated preoperatively and postoperatively to record active range of motion (ROM), the CS,<sup>12</sup> the Subjective Shoulder Value (SSV),<sup>18</sup> and the pain level using the CS. Patients were asked how satisfied they were with the procedure, and for the first 6 weeks postoperatively, pain documentation was performed weekly (visual analog scale score).

## Imaging

### Radiography

In all patients, plain radiographs of the shoulder were obtained preoperatively and at each postoperative visit, including



**Figure 1** Flowchart of randomized clinical trial. MRI, magnetic resonance imaging.

anteroposterior, axial, and Neer views. These radiographs were analyzed to determine the critical shoulder angle (CSA)<sup>25</sup> and acromiohumeral distance, as well as to evaluate osteoarthritis<sup>31</sup> and cuff arthropathy.<sup>20</sup>

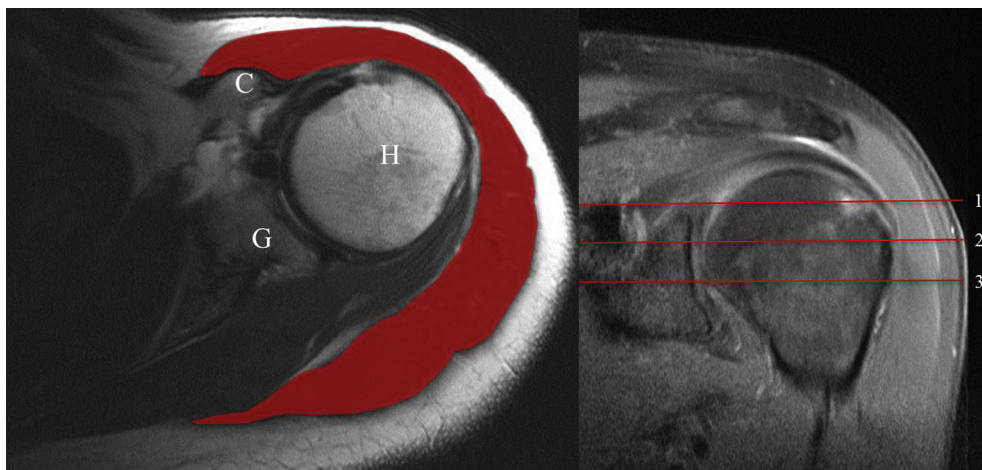
*Magnetic resonance imaging*

All MRI scans were performed on clinical 1.5- to 3-T magnetic resonance scanners (Siemens Symphony, Espree, Avanto, or AvantoFit; Siemens Healthcare, Erlangen, Germany). All patients underwent MRI of the shoulder prior to surgery and underwent further MRI at each review (3 months, 1 year, 2 years, and >10 years). The type of RCT was classified according to Collin et al.<sup>11</sup> MRI was used to assess the degree of intramuscular fatty infiltration using the adapted Goutallier classification,<sup>16</sup> and tendon retraction was assessed according to Patte.<sup>27</sup> Supraspinatus muscle atrophy was assessed using the tangent sign.<sup>39</sup> At each follow-up visit, repair integrity was assessed by MRI.<sup>34</sup> Sugaya type IV and type V were defined as re-ruptures. Two authors (A.H. and S.B.) reviewed each MRI scan to establish a consensus regarding re-rupture of the tendon following repair. To evaluate deltoid attenuation, the deltoid origin was assessed as described by Cho et al<sup>9</sup> and divided into intact, partial detachment < 50%, partial detachment  $\geq 50\%$ , and complete detachment. To measure the volume of the deltoid muscle, its cross-sectional area was measured on transverse images

using the freehand region of interest at 3 levels (the most distal axial slice with the tip of the coracoid visible and 7–8 mm above and below this). The sum of these 3 areas was calculated (Fig. 2). All mean cross-sectional areas obtained at follow-up visits were compared with the respective preoperative cross-sectional area. This is a newly developed method and, therefore, intraobserver and interobserver correlations for the mean cross-sectional area calculation were performed on 33 MRI scans. The measurements of area were repeatable with an intraclass correlation coefficient of 0.895 (95% confidence interval, 0.787–0.948). The approximate mean area of the deltoid muscle was surprisingly different between the 2 groups preoperatively. Therefore, we decided to use the change in area from preoperative to postoperative MRI to assess the effect of each procedure on the deltoid muscle.

**Statistical methods**

Sample size estimation revealed a minimum required number of 18 subjects per group to detect a minimal clinically important difference of 4.6 points in the CS<sup>13</sup> with a power of 0.90 and  $P = .05$  assuming a Cohen effect size of 1. Economic and demographic data are presented as mean and standard deviation (SD). Group differences were assessed with independent-samples *t* tests. Various functional and MRI parameters were non-normally distributed, and consequently, nonparametric tests—Mann-Whitney *U* and Fisher



**Figure 2** Approximate measurement of deltoid muscle volume by measuring cross-sectional area at 3 levels on axial magnetic resonance imaging scan. The first measurement was performed on the most distal part of the coracoid process (C), with an additional measurement 7–8 mm above and below this. The 3 images on the transverse magnetic resonance imaging scan were averaged and compared with the preoperative volume. H, humeral head; G, glenoid; 1–3, defined levels.

exact test as applicable—were used. These data are presented as median and range. Test-retest reliability and inter-rater reliability of MRI-based area measurements were assessed by calculating intraclass correlation coefficients and the respective confidence bounds based on a 2-way mixed-effects model describing absolute agreement of single measurements. The analysis was performed with SPSS software (IBM SPSS Statistics for Windows, version 25.0 [2017 release]; IBM, Armonk, NY, USA).  $P = .05$  was set for statistical significance.

## Results

### Demographic data

The mean age at the time of surgery was 60 years (range, 50–71 years; SD, 6 years) in the arthroscopic surgery group and 55 years (range, 39–67 years; SD, 8 years) in the open surgery group. There were significant differences in age, affected side, and arm dominance. In the arthroscopic surgery group, patients were younger ( $P = .038$ ) and the left side was more frequently affected ( $P = .010$ ). In the open surgery group, the dominant side was more frequently affected ( $P = .008$ ). In the arthroscopic surgery group, the median preoperative pain level was 5 points (range, 0–11 points) and was significantly lower than that in the open surgery group, with a median of 9 points (range, 4–15 points) ( $P = .011$ ). All other preoperative clinical parameters were not significantly different between the 2 groups. Patient demographic information is provided in [Table 1](#).

### Preoperative radiographic findings

Preoperative radiographic evaluation findings were not significantly different between the 2 groups. Data regarding tear classification and tendon retraction are presented in [Table II](#). None of the patients had signs of osteoarthritis or cuff tear arthropathy.

In the arthroscopic surgery group, biceps tenotomy was performed more frequently than biceps tenodesis (50% vs. 30%). The biceps tendon was addressed in the open surgery group in 95% and then always treated by biceps tenodesis was always performed (95%). In addition, AC joint resection was performed in 2 shoulders in the arthroscopic surgery group vs. none in the open surgery group ( $P = .487$ ). Acromioplasty was performed in 19 patients vs. 16 patients ( $P = .342$ ).

### Economic parameters

The mean operating time (from skin incision until wound closure) was statistically significantly shorter in the open surgery group ( $88 \pm 19$  minutes) than in the arthroscopic surgery group ( $130 \pm 32$  minutes) ( $P < .001$ ). The mean material cost of performing the surgical procedure in the arthroscopic surgery group ( $1642 \pm 296$  CHF [Swiss franc]) was almost double that in the open surgery group ( $803 \pm 282$  CHF) ( $P < .001$ ). The total number of nights patients stayed in the hospital ( $4 \pm 1$  nights for arthroscopic vs.  $5 \pm 1$  nights for open) and cost for hospitalization ( $927 \pm 255$  CHF for arthroscopic vs.  $976 \pm 290$  CHF for open) were similar between the 2 groups.

### Clinical results

Although we found a higher pain level (visual analog scale score, 0–15 points [in which 0 points indicates no pain]) 1 week after the operation in the open surgery group (6 points vs. 4 points), pain levels did not significantly differ between the 2 groups at any other time point in the first 6 weeks.

At no follow-up time points were the pain level, ROM, and abduction power significantly different between the 2 groups ( $P > .05$ ). Improvement in the absolute and relative CS and improvement in the SSV were statistically similar between the 2 groups at all time points ( $P > .05$ ). At latest follow-up, the median pain level in both groups was 15 points (range, 6–15 points in arthroscopic surgery group and 5–15 points in open surgery group;  $P = .866$ ). The median absolute CS was 79 points (range, 14–84 points) in the arthroscopic surgery group and 84 points (range, 56–90 points) in the open surgery group ( $P = .177$ ); the median relative CS was 94% (range, 20%–99%) and 96% (range, 65%–111%), respectively ( $P = .429$ ). The median SSV was 93% (range, 20%–100%) in the arthroscopic surgery group and 93% (range, 10%–100%) in the open surgery group ( $P = .976$ ). At latest follow-up, 9 patients (64.3%) in the arthroscopic surgery group and 8 (80%) in the open surgery group had excellent subjective results; 4 (28.6%) and 1 (10%), respectively, had good results; and in each group, one patient had a disappointing result (7.1% and 10%, respectively) ( $P = .675$ ).

### Postoperative radiographic findings

The CSA and acromiohumeral distance did not differ between the 2 groups at latest follow-up ( $P = .612$  and  $P = .860$ , respectively).

**Table I**  
Demographic data of entire series (N = 40)

Characteristic	Arthroscopic surgery group (n = 20)	Open surgery group (n = 20)	P value for comparison
Age at surgery, mean ± SD, yr	60 ± 6	55 ± 8	.038*
Sex, n			.155
Male	12	17	
Female	8	3	
Side affected, n			.010*
Left	13	4	
Right	7	16	
Dominant side affected, n (%)	8 (40)	17 (85)	.008*
Traumatic etiology, n (%)	10 (50)	14 (70)	.333
Occupational situation, n (%)			.512
Manual worker	8 (40)	11 (55)	
Non-manual worker	6 (30)	6 (30)	
Retired	6 (30)	3 (15)	
Nicotine abuse, n (%)	6 (30)	6 (30)	>.999
Constant-Murley score (preoperative), median (range)			
Pain (1-15), points	5 (0-11)	9 (4-15)	.011*
Activity	7 (0-10)	6 (0-10)	.869
Active ROM, median (range)			
Elevation, °	150 (40-160)	160 (80-170)	.389
External rotation, °	60 (0-90)	50 (20-70)	.428
Internal rotation, points	8 (0-10)	8 (0-10)	.347
Power total, median (range), points	6 (0-19)	9 (0-18)	.106
Total Constant-Murley score, median (range)			
Absolute, points	62 (14-93)	66 (27-80)	.245
Relative, %	72 (16-102)	74 (33-90)	.465
SSV, median (range), %	50 (0-70)	50 (0-90)	.389

SD, standard deviation; ROM, range of motion; SSV, Subjective Shoulder Value.

\* Statistically significant ( $P < .05$ ).

The findings regarding evidence of osteoarthritis (14.3% in arthroscopic group vs. 10% in open group) and cuff arthropathy (0% vs. 10%) were similar at final follow-up ( $P > .999$  and  $P = .417$ , respectively).

Overall, the degree of fatty infiltration within the rotator cuff muscles increased over time. However, on comparison of the 2 groups, fatty infiltration within the supraspinatus, infraspinatus, and teres minor muscles was not significantly different at all time points ( $P > .05$ ). Fatty infiltration of the subscapularis muscle was significantly worse in the arthroscopic surgery group at 1 year and 2 years of follow-up ( $P = .031$  and  $P = .016$ , respectively); however, at >10 years' follow-up, this difference was no longer evident (Fig. 3).

Fatty infiltration of the deltoid muscle did not change significantly over time in either group (Fig. 4). In the assessment of all MRI scans, we found evidence local fatty infiltration in the posterior deltoid muscle in 1 patient in the arthroscopic surgery group.

There was no significant difference in deltoid muscle cross-sectional area change between the 2 groups. In the arthroscopic surgery group, the mean area decreased from 100% to 92% at 12 weeks and increased to 104% and 107% at 1 and 2 years, respectively. After >10 years' follow-up, we found an increase in the area to 111%. Similar findings were detected in the open surgery group: 93%, 101%, and 104% to 111% at >10-year follow-up. Preoperatively, in 1 patient in the arthroscopic surgery group, we found a partial detachment of the deltoid in zone 3 (detached <50%) and zone 4 (detached <50%). This lesion remained stable over time. No other detachments were seen over time. There was no statistically significant difference between the 2 groups ( $P > .05$ ).

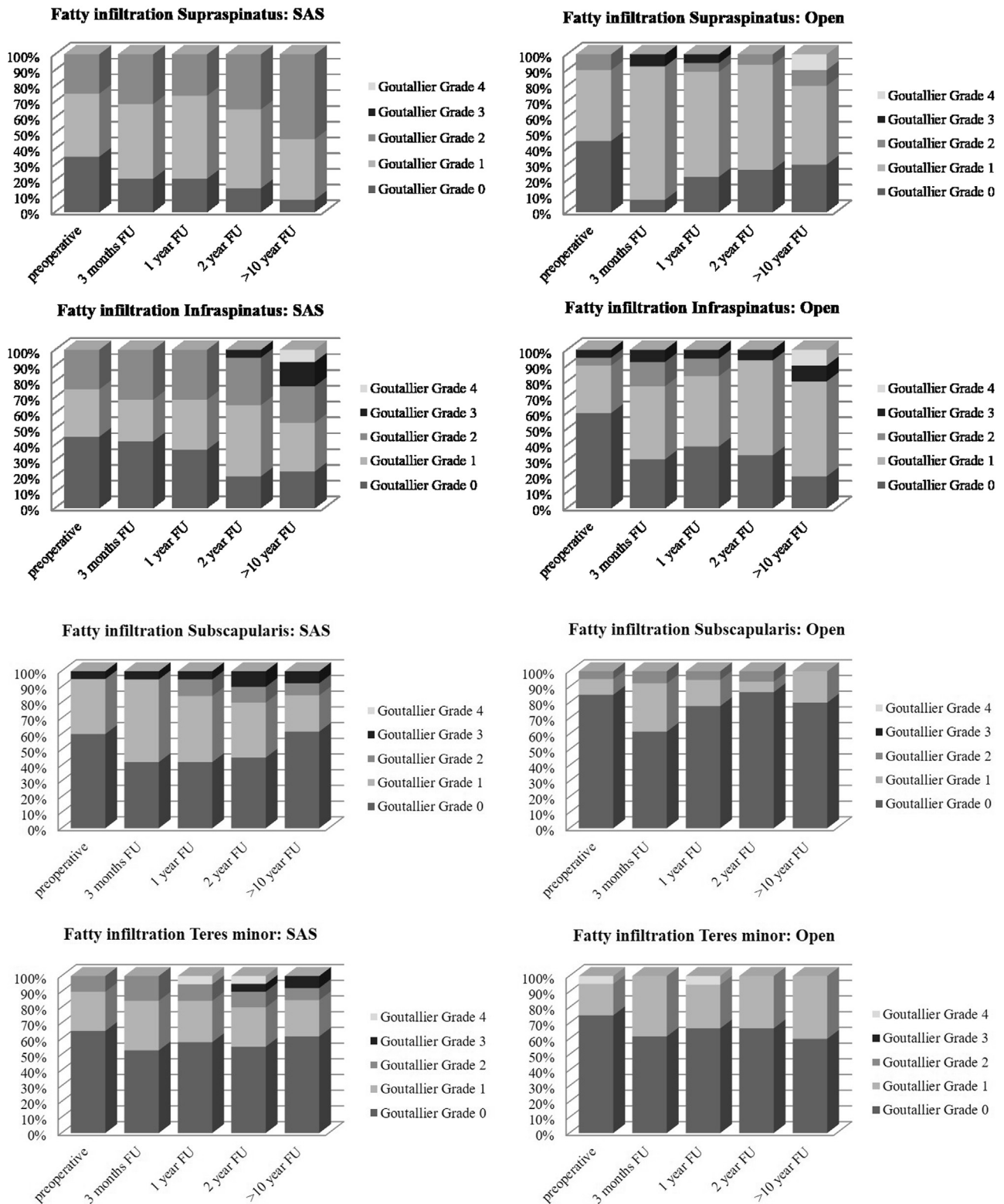
In the open RCT repair group, 10 of 20 patients had an irregularity of the acromion, where the osteotomy had been performed. This could best be seen on conventional radiographs. Some of these bony deposits led to an increase in the CSA value at follow-up.

**Table II**  
Preoperative radiographic findings of entire series (N = 40)

Characteristic	Arthroscopic surgery group (n = 20)	Open surgery group (n = 20)	P value for comparison (Fisher exact test)
Tear classification (Collin et al <sup>11</sup> ), n (%)			.643
A	4 (20)	3 (15)	
C	4 (20)	2 (10)	
D	12 (60)	15 (75)	
Retraction of supraspinatus (Patte <sup>27</sup> ), n (%)			.671
Stage 1	6 (30)	9 (45)	
Stage 2	12 (60)	9 (45)	
Stage 3	2 (10)	2 (10)	
Positive tangent sign (Zanetti et al <sup>39</sup> ), n (%)	2 (10)	2 (10)	>.999
ACHD, mm	10 (8-18)	10 (6-16)	.569
CSA, ° (Moor et al <sup>25</sup> )	37 (31-41)	36 (31-43)	.765

ACHD, acromiohumeral distance; CSA, critical shoulder angle.

Data are given as number of patients (percentage) or mean (range).



**Figure 3** Fatty infiltration of rotator cuff muscles over time. SAS, shoulder arthroscopic surgery; FU, follow-up.

**Complications**

There were 12 complications (30%) overall (evenly distributed between the 2 groups,  $P > .999$ ) (unaddressed retears are listed separately and are not included in this number). Capsulitis

developed postoperatively in 8 patients (5 in the arthroscopic surgery group), 2 of whom required mobilization under interscalene anesthesia and/or a capsulotomy. In the open RCT repair group, complex regional pain syndrome of the operated limb occurred in 2 patients. Three patients underwent 1 or more

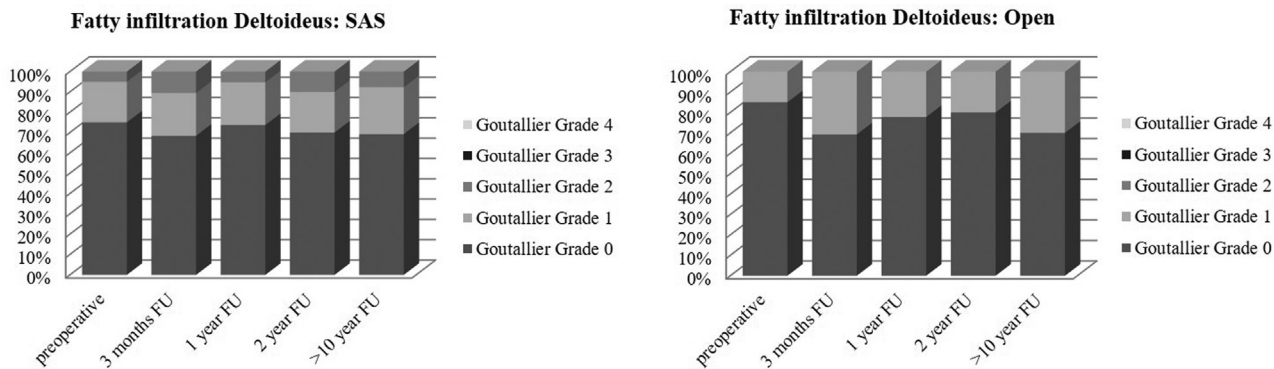


Figure 4 Fatty infiltration of deltoid muscle over time. SAS, shoulder arthroscopic surgery; FU, follow-up.

additional surgical procedures: The first patient (arthroscopic surgery group) underwent AC joint resection. The second patient (open surgery group) underwent (1) plate removal of the button plate because of local irritation of the cuff (8 months postoperatively), (2) shoulder arthroscopy and re-reconstruction of a retear (supraspinatus); and (3) shoulder arthroscopy and AC joint resection. Finally, the third patient (open surgery group) underwent RTSA implantation because of cuff repair failure. There were no infections in either group of patients.

Retear

Retear of the RC, defined as Sugaya type IV and V tears,<sup>34</sup> occurred in 12 patients (30%) over the whole study period. Two of them required revision surgery for cuff repair failure (already reported in the “Complications” section). Of the retears, 8 occurred within 3 months of follow-up whereas 1 was documented at 1 year, 1 was noted at 5 years, and 2 were observed at >10 years. Between the 2 groups, there was no significant difference regarding the absolute number, time of occurrence, and type of retear at any time point (each group had 6 retears; *P* values of retear type distribution: 12 weeks, *P* = .820; 1 year, *P* = .500; 2 years, *P* = .937; and >10 years, *P* = .952).

Discussion

This study compared open and arthroscopic RCT repair in a randomized, controlled study with long-term follow-up (>10 years). The aim of the study was to determine whether open surgery is still justified despite manipulation of the deltoid. We could not document any significant difference between the 2 techniques regarding functional outcomes, rotator cuff integrity, and complication rates at the minimum follow-up of 10 years. Neither an open repair as performed in this study nor an arthroscopic procedure harmed the deltoid muscle by use of MRI parameters. Even though arthroscopic RCT repair has the reputation of being less invasive, documented pain levels during the first 6 weeks did not significantly differ between open and arthroscopic repair, and these findings are similar to those of other studies.<sup>28</sup> In addition, we could not show a difference in clinical outcomes at any time point between the 2 groups, although other studies have shown greater ROM at 6 and 12 weeks postoperatively in patients undergoing all-arthroscopic repair.<sup>32</sup> In this randomized study, the complication and retear rates were both 30%, with no significant difference between the 2 procedures. These rates seem to be high, but owing to the prospective design of the study, all complications have been recognized and a retear rate of 30% is comparable with rates in the published literature.<sup>8</sup> However, unlike a previous large

retrospective comparative study,<sup>4</sup> our study did not find a lower risk of adverse events or complication rate for arthroscopic RC repair. Deltoid muscle injury is a potential complication of open rotator cuff repair.<sup>17</sup> In a study of 112 patients treated with open RCT repair, Gumina et al<sup>19</sup> found that 8% of patients had a deltoid muscle detachment 3 months postoperatively. However, there is limited evidence that deltoid muscle injury is different after arthroscopic vs. open repair.<sup>9</sup> This may be important because RTSA is often necessary after failed RCT repair, and lack of integrity of the deltoid muscle will affect clinical outcomes following RTSA. Our results allow an understanding of why other investigators have found no difference in final clinical outcome scores or complication rates in patients undergoing RTSA with previous RCT repair.<sup>30</sup>

Although we did find irregularities on plain radiographs after the open procedure, we could not find any difference in fatty infiltration, cross-sectional area, and detachment of the deltoid muscle at any time point. In the literature, mini-open rotator cuff repair techniques have been found to have a shorter operative time and to be less expensive.<sup>10</sup> Our study confirmed the increased intraoperative cost of arthroscopic surgery, but because the operations were performed between 2003 and 2007, these data may not be valid currently owing to improvements in arthroscopic RCT repair techniques and increased experience.

This study has limitations. The sample size is small and the time needed to recruit the patients was high despite a high overall patient volume. Patients had to be informed that a similar outcome was expected after the 2 procedures: With the expectation of the same results being achieved without a skin incision, it was difficult to recruit patients to possibly undergo an open surgical procedure. Although patients were randomized, the arthroscopic surgery group turned out to be significantly older. This may have had an effect on the clinical as well as radiographic outcomes, but the absolute CS, the age- and sex-adjusted relative CS, and the SSV were the same not only at the final outcome assessment but also preoperatively. Because of the long follow-up period of >10 years, the number of patients lost to follow-up was high (16 patients, 40%; detailed in Fig. 1). However, the number of patients lost was almost equal in the 2 groups; therefore, this potential bias should not impact our conclusions. At 2 years postoperatively, 36 patients (90%) were personally reviewed and no clinical differences were observed either. As a matter of fact, the very similar outcomes in the 2 groups prompted the longer follow-up. Even though this left a small number of patients for long-term evaluation, because of the randomized study protocol, we do not see a bias regarding the chosen procedure, which is unique for long-term data. Nevertheless, the study was underpowered at long-term follow-up >10 years because we were unable to include groups with a minimum

of 18 subjects per group. The method used to assess deltoid muscle volume is an approximation because standard MRI does not involve the whole muscle. However, our method of assessing muscle volume on MRI had good intraobserver and interobserver correlation and, in our hands, seems to be more precise than previously described methods.<sup>9,21</sup>

## Conclusion

Although recent trends for RCT repair favor an arthroscopic technique, neither the arthroscopic nor open surgical procedure, as performed in this study, is superior at 2 years' follow-up and probably at >10 years' follow-up. Both approaches result in very high patient satisfaction but a retear rate of approximately 30%. The postulated damage to the deltoid caused by deltoid detachment could be refuted for the technique used in this study.

## Disclaimer

The authors, their immediate families, and any research foundations with which they are affiliated have not received any financial payments or other benefits from any commercial entity related to the subject of this article.

## References

- Adla DN, Rowsell M, Pandey R. Cost-effectiveness of open versus arthroscopic rotator cuff repair. *J Shoulder Elbow Surg* 2010;19:258–61. <https://doi.org/10.1016/j.jse.2009.05.004>.
- Agout C, Berhouet J, Bouju Y, Godeneche A, Collin P, Kempf JF, et al. Clinical and anatomic results of rotator cuff repair at 10 years depend on tear type. *Knee Surg Sports Traumatol Arthrosc* 2018;26:2490–7. <https://doi.org/10.1007/s00167-018-4854-1>.
- Alluri RK, Kupperman AI, Montgomery SR, Wang JC, Hame SL. Demographic analysis of open and arthroscopic distal clavicle excision in a private insurance database. *Arthroscopy* 2014;30:1068–74. <https://doi.org/10.1016/j.arthro.2014.04.088>.
- Baker DK, Perez JL, Watson SL, McGwin G, Brabston EW, Hudson PW, et al. Arthroscopic versus open rotator cuff repair: which has a better complication and 30-day readmission profile? *Arthroscopy* 2017;33:1764–9. <https://doi.org/10.1016/j.arthro.2017.04.019>.
- Bayle X, Pham TT, Faruch M, Gobet A, Mansat P, Bonnevalle N. No difference in outcome for open versus arthroscopic rotator cuff repair: a prospective comparative trial. *Arch Orthop Trauma Surg* 2017;137:1707–12. <https://doi.org/10.1007/s00402-017-2796-6>.
- Bishop J, Klepps S, Lo IK, Bird J, Gladstone JN, Flatow EL. Cuff integrity after arthroscopic versus open rotator cuff repair: a prospective study. *J Shoulder Elbow Surg* 2006;15:290–9. <https://doi.org/10.1016/j.jse.2005.09.017>.
- Buess E, Steuber KU, Waibl B. Open versus arthroscopic rotator cuff repair: a comparative view of 96 cases. *Arthroscopy* 2005;21:597–604. <https://doi.org/10.1016/j.arthro.2005.01.002>.
- Carr AJ, Cooper CD, Campbell MK, Rees JL, Moser J, Beard DJ, et al. Clinical effectiveness and cost-effectiveness of open and arthroscopic rotator cuff repair [the UK Rotator Cuff Surgery (UKUFF) randomised trial]. *Health Technol Assess* 2015;19:1–218. <https://doi.org/10.3310/hta19800>.
- Cho NS, Cha SW, Rhee YG. Alterations of the deltoid muscle after open versus arthroscopic rotator cuff repair. *Am J Sports Med* 2015;43:2927–34. <https://doi.org/10.1177/0363546515603063>.
- Churchill RS, Ghorai JK. Total cost and operating room time comparison of rotator cuff repair techniques at low, intermediate, and high volume centers: mini-open versus all-arthroscopic. *J Shoulder Elbow Surg* 2010;19:716–21. <https://doi.org/10.1016/j.jse.2009.10.011>.
- Collin P, Matsumura N, Ladermann A, Denard PJ, Walch G. Relationship between massive chronic rotator cuff tear pattern and loss of active shoulder range of motion. *J Shoulder Elbow Surg* 2014;23:1195–202. <https://doi.org/10.1016/j.jse.2013.11.019>.
- Constant CR, Murley AH. A clinical method of functional assessment of the shoulder. *Clin Orthop Relat Res* 1987;160–4.
- Cvetanovich GL, Gowd AK, Liu JN, Nwachukwu BU, Cabarcas BC, Cole BJ, et al. Establishing clinically significant outcome after arthroscopic rotator cuff repair. *J Shoulder Elbow Surg* 2019;28:939–48. <https://doi.org/10.1016/j.jse.2018.10.013>.
- Day MA, Westermann RW, Bedard NA, Glass NA, Wolf BR. Trends associated with open versus arthroscopic rotator cuff repair. *HSS J* 2019;15:133–6. <https://doi.org/10.1007/s11420-018-9628-2>.
- Denard PJ, Burkhart SS. Arthroscopic revision rotator cuff repair. *J Am Acad Orthop Surg* 2011;19:657–66. <https://doi.org/10.5435/00124635-201111000-00002>.
- Fuchs B, Weishaupt D, Zanetti M, Hodler J, Gerber C. Fatty degeneration of the muscles of the rotator cuff: assessment by computed tomography versus magnetic resonance imaging. *J Shoulder Elbow Surg* 1999;8:599–605.
- Gartsman GM. Combined arthroscopic and open treatment of tears of the rotator cuff. *Instr Course Lect* 1998;47:51–7.
- Gilbart MK, Gerber C. Comparison of the Subjective Shoulder Value and the Constant score. *J Shoulder Elbow Surg* 2007;16:717–21. <https://doi.org/10.1016/j.jse.2007.02.123>.
- Gumina S, Di Giorgio G, Perugia D, Postacchini F. Deltoid detachment consequent to open surgical repair of massive rotator cuff tears. *Int Orthop* 2008;32:81–4. <https://doi.org/10.1007/s00264-006-0285-6>.
- Hamada K, Fukuda H, Mikasa M, Kobayashi Y. Roentgenographic findings in massive rotator cuff tears. A long-term observation. *Clin Orthop Relat Res* 1990;92–6.
- Hata Y, Saitoh S, Murakami N, Kobayashi H, Takaoka K. Atrophy of the deltoid muscle following rotator cuff surgery. *J Bone Joint Surg Am* 2004;86:1414–9. <https://doi.org/10.2106/00004623-200407000-00008>.
- Ide J, Maeda S, Takagi K. A comparison of arthroscopic and open rotator cuff repair. *Arthroscopy* 2005;21:1090–8. <https://doi.org/10.1016/j.arthro.2005.05.010>.
- Keener JD, Wei AS, Kim HM, Paxton ES, Teefey SA, Galatz LM, et al. Revision arthroscopic rotator cuff repair: repair integrity and clinical outcome. *J Bone Joint Surg Am* 2010;92:590–8. <https://doi.org/10.2106/JBJS.I.00267>.
- Liu J, Fan L, Zhu Y, Yu H, Xu T, Li G. Comparison of clinical outcomes in all-arthroscopic versus mini-open repair of rotator cuff tears: a randomized clinical trial. *Medicine (Baltimore)* 2017;96:e6322. <https://doi.org/10.1097/MD.00000000000006322>.
- Moor BK, Bouaicha S, Rothenfluh DA, Sukthankar A, Gerber C. Is there an association between the individual anatomy of the scapula and the development of rotator cuff tears or osteoarthritis of the glenohumeral joint?: A radiological study of the critical shoulder angle. *Bone Joint J* 2013;95-B:935–41. <https://doi.org/10.1302/0301-620X.95B7.31028>.
- Moosmayer S, Lund G, Seljom US, Haldorsen B, Svege IC, Hennig T, et al. At a 10-year follow-up, tendon repair is superior to physiotherapy in the treatment of small and medium-sized rotator cuff tears. *J Bone Joint Surg Am* 2019;101:1050–60. <https://doi.org/10.2106/JBJS.18.01373>.
- Patte D. Classification of rotator cuff lesions. *Clin Orthop Relat Res* 1990;81–6.
- Pham TT, Bayle X, Iniguez X, Mansat P, Maubisson L, Bonnevalle N. Postoperative pain after arthroscopic versus open rotator cuff repair. A prospective study. *Orthop Traumatol Surg Res* 2016;102:13–7. <https://doi.org/10.1016/j.jotsr.2015.11.005>.
- Randelli P, Arrigoni P, Cabitza F, Ragone V, Cabitza P. Current practice in shoulder pathology: results of a web-based survey among a community of 1,084 orthopedic surgeons. *Knee Surg Sports Traumatol Arthrosc* 2012;20:803–15. <https://doi.org/10.1007/s00167-011-1673-z>.
- Sadoghi P, Vavken P, Leithner A, Hochreiter J, Weber G, Pietschmann MF, et al. Impact of previous rotator cuff repair on the outcome of reverse shoulder arthroplasty. *J Shoulder Elbow Surg* 2011;20:1138–46. <https://doi.org/10.1016/j.jse.2011.01.013>.
- Samilson RL, Prieto V. Dislocation arthroplasty of the shoulder. *J Bone Joint Surg Am* 1983;65:456–60.
- Severud EL, Ruotolo C, Abbott DD, Nottage WM. All-arthroscopic versus mini-open rotator cuff repair: a long-term retrospective outcome comparison. *Arthroscopy* 2003;19:234–8. <https://doi.org/10.1053/jars.2003.50036>.
- Shamsudin A, Lam PH, Peters K, Rubenis I, Hackett L, Murrell GA. Revision versus primary arthroscopic rotator cuff repair: a 2-year analysis of outcomes in 360 patients. *Am J Sports Med* 2015;43:557–64. <https://doi.org/10.1177/0363546514560729>.
- Sugaya H, Maeda K, Matsuki K, Moriishi J. Repair integrity and functional outcome after arthroscopic double-row rotator cuff repair. A prospective outcome study. *J Bone Joint Surg Am* 2007;89:953–60. <https://doi.org/10.2106/JBJS.F.00512>.
- van der Zwaal P, Thomassen BJ, Nieuwenhuijse MJ, Lindenburg R, Swen JW, van Arkel ER. Clinical outcome in all-arthroscopic versus mini-open rotator cuff repair in small to medium-sized tears: a randomized controlled trial in 100 patients with 1-year follow-up. *Arthroscopy* 2013;29:266–73. <https://doi.org/10.1016/j.arthro.2012.08.022>.
- Walton JR, Murrell GA. A two-year clinical outcomes study of 400 patients, comparing open surgery and arthroscopy for rotator cuff repair. *Bone Joint Res* 2012;1:210–7. <https://doi.org/10.1302/2046-3758.19.2000072>.
- Yamaguchi K, Ball CM, Galatz LM. Arthroscopic rotator cuff repair: transition from mini-open to all-arthroscopic. *Clin Orthop Relat Res* 2001;83–94.
- Youn T, Murray DH, Kubiak EN, Rokito AS, Zuckerman JD. Arthroscopic versus mini-open rotator cuff repair: a comparison of clinical outcomes and patient satisfaction. *J Shoulder Elbow Surg* 2005;14:455–9. <https://doi.org/10.1016/j.jse.2005.02.002>.
- Zanetti M, Gerber C, Hodler J. Quantitative assessment of the muscles of the rotator cuff with magnetic resonance imaging. *Invest Radiol* 1998;33:163–70.
- Zhang AL, Montgomery SR, Ngo SS, Hame SL, Wang JC, Gamradt SC. Analysis of rotator cuff repair trends in a large private insurance population. *Arthroscopy* 2013;29:623–9. <https://doi.org/10.1016/j.arthro.2012.11.004>.