

# Management of renal cell carcinoma presenting as inflammatory renal mass

Ehab Eltahawy, Mohamed Kamel, Mahmoud Ezzet<sup>1</sup>

Departments of Urology, University of Arkansas for Medical Sciences, USA, <sup>1</sup>Ain Shams University Hospitals, Egypt

## Abstract

**Introduction:** Renal cell carcinoma (RCC) can have a wide spectrum of clinical presentations. In the immunocompromised patient fever and an inflammatory renal mass can harbor RCC.

**Materials and Methods:** We reviewed the charts of patients who were managed at our department during 1998-2008 as renal abscess or perinephric collection. Renal ultrasound and subsequently abdominal CT was done. Medical treatment in the form of antibiotics, control of diabetes and drainage was done. Percutaneous or open biopsy, pus cultures, and histopathology were used to guide therapy. With a positive biopsy radical surgery was considered, while with a negative result a follow up CT was planned.

**Results:** We identified 11 patients who had high fever, a renal abscess (in 4), or a suspicious mass with perinephric collection (in 7), and were eventually diagnosed to have RCC. Mean patient age was 66 years (53-82). 8 patients had uncontrolled diabetes. Five patients had a percutaneous drainage biopsy; of those two had a positive histopathology, the other three patients had a persistent enhancing mass on follow-up CT scan. Of this group three patients underwent radical nephrectomy. Another five patients had open drainage and biopsy, four patients had very poor performance status. One patient had radical surgery without the need for biopsy.

**Conclusion:** In the elderly and immunocompromised patient renal cancer may present as renal abscess or perinephric collection. Histopathology and bacteriology are the mainstay of diagnosis. If biopsy was negative, follow up should include a CT scan to exclude any residual enhancing masses.

**Key Words:** Renal abscess, renal biopsy, renal cell carcinoma

## Address for correspondence:

Dr. Ehab Eltahawy, MD, MRCS 4301 W Markham St #540 Little Rock, AR, USA. E-mail: eeltahawy@uams.edu

Received: 04.09.2013, Accepted: 18.01.2014

## INTRODUCTION

Renal cell carcinoma (RCC) can present as a mass, or cause pain or bleeding. Unusual presentations include paraneoplastic syndromes and renal abscess or perinephric collection. The diagnosis and management is particularly challenging in the setting of the elderly

and the immunocompromised patient. The advances in imaging and the improvements in technique of renal biopsy in the diagnosis of such lesions have improved the outcome.

## MATERIALS AND METHODS

Between 1998 and 2008 we identified 11 patients who presented with an initial diagnosis of perinephric suppuration or renal abscess, and their final diagnosis was confirmed to be RCC. Pelviabdominal ultrasound was done initially for all patients, then an abdominal CT scan (with contrast if serum creatinine was  $< 2$  mg/ml). Resuscitation and broad spectrum antibiotics were administered in all cases. Drainage and biopsy was taken from suspicious lesions. The percutaneous biopsies were done under intravenous sedation. We used an 18-gauge needle to collect FNA samples using a 20 cc

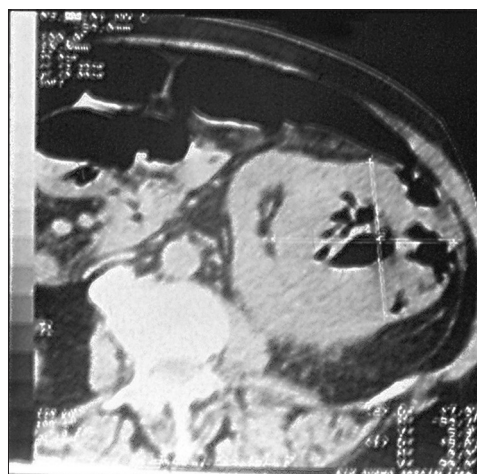Access this article online	
Quick Response Code:	Website: www.urologyannals.com
	DOI: 10.4103/0974-7796.152051

syringe while applying suction moved under ultrasound guidance in multiple planes. Attempts were made to avoid the pus and the necrotic areas. Core biopsies were complementary, and in the same setting if the FNAB was thought inadequate. An 18-gauge automatic side cutting needles were used, and a drainage tube were placed concomitantly if a small amount of collection was found. Samples were then sent for histopathology and bacteriology. Open surgical drainage was done when percutaneous drainage was inadequate, and when the diagnosis was uncertain. This was required in five patients who had large amounts of pus, after the loculi were drained, and an indurated mass identified peripheral zone biopsies were obtained. All imaging were retrieved and reviewed by a dedicated urologist.

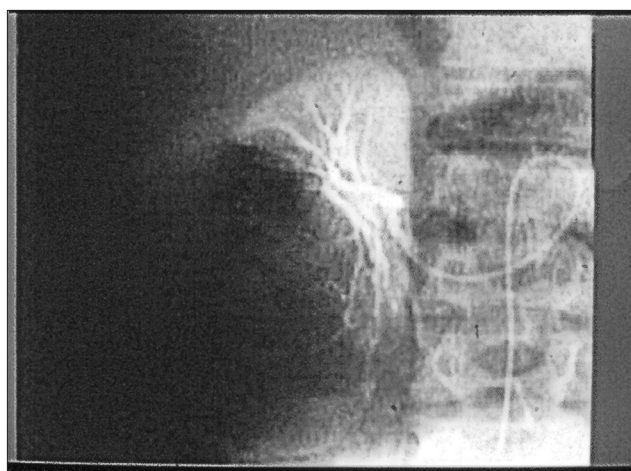
**RESULTS**

There were a total of 11 patients with constitutional symptoms of toxemia, high fever (>39°C), and an inflammatory renal lesion. Patient data and management are summarized in Table I. Mean patient age was 66 years (53-82). All but 3 patients had uncontrolled diabetes and were started during their hospital stay on short acting insulin by sliding scale protocol. 5 patients had renal impairment (s. creatinine > 1.4 mg/ml). Pelvi abdominal US and CT findings were: Renal abscess in four, and a suspicious mass with perinephric collection extending in the psoas with or without gas, in seven patients. The size of this suspicious mass was < 5 cm in five patients and > 5 cm in two patients. Initial management was broad-spectrum antibiotics, antipyretics, and fluids, later adjustments according to the case progress were done. Five of the patients in this study underwent percutaneous drainage and biopsy [Figure 1]. Of the five patients, histopathology in two patients revealed renal adenocarcinoma Furman grade (I-II), with extensive necrosis and inflammatory infiltrate. In those two patients with a positive biopsy elective radical surgery was planned. The three other patients had persistent enhancing mass in the follow-up CT scans despite a negative biopsy. One of them only was prepared for a nephrectomy. By radiography alone one patient

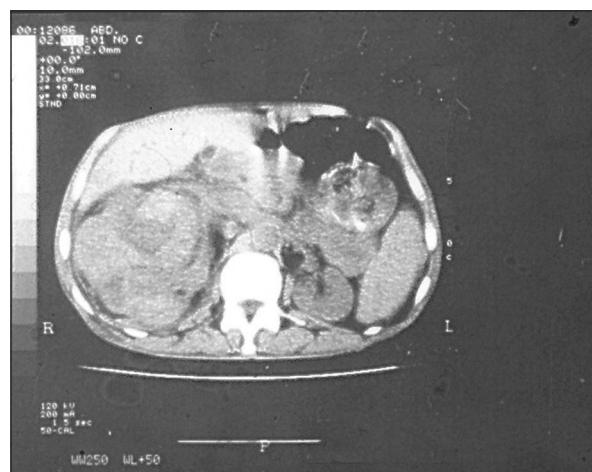
had a highly suspicious mass; arteriography was performed to confirm the diagnosis [Figure 2]. After the initial therapy he underwent radical nephrectomy. Five patients had a collection of pus that was drained by open surgical drainage [Figure 3].



**Figure 1:** Renal CT scan reveals a large, heterogeneous left renal tumor with central gas formation



**Figure 2:** Selective right renal angiography showing neovascularity



**Figure 3:** Renal CT scan with large right perirenal collection with areas of increased tissue enhancement

**Table 1: Imaging results, biopsy type and result, culture results and final management**

Pt. No.	Age	DM	US/CT	Biopsy	RCC on Initial biopsy	Culture	Radical nephrectomy
1	77	No	Abscess	Open	No	<i>E. coli</i>	No
2	69	Yes	Abscess	Open	Yes	Mixed	No
3	80	Yes	Mass+collection	Perc	No	Fungal	No
4	58	Yes	Mass+gas	Perc	Yes	<i>E. coli</i>	Yes
5	72	No	Abscess	Open	Yes	<i>Proteus</i>	No
6	82	Yes	Mass+collection	Perc	No	<i>Proteus</i>	No
7	53	Yes	Mass+collection	Radical	Not done	Mixed	Yes
8	74	Yes	Mass+gas	Perc	No	<i>E. coli</i>	Yes
9	66	Yes	Abscess	Open	No	<i>Proteus</i>	Yes
10	70	No	Mass+collection	Perc	Yes	<i>E. coli</i>	Yes
11	75	Yes	Mass+collection	Open	Yes	Fungal	No

RCC: Renal cell carcinoma

The initial histopathology revealed no evidence of malignancy in two of them. Those were discharged for follow up. The wound site however continued to discharge pus. The follow-up CT scan revealed a resectable mass in one patient who underwent nephrectomy. In the other patient, the mass was irresectable. Three patients who underwent open drainage and biopsy had RCC on histopathology. Their performance status did not allow further therapy.

Pus culture grew *Escherichia coli* in four cases, *Proteus* in three, and fungal in two patients. Five of the 11 patients underwent radical nephrectomy either concomitant with drainage or delayed.

## DISCUSSION

RCC was previously referred to as the “internist’s tumor” owing to the prevalence of systemic rather than local manifestations.<sup>[1]</sup> Symptoms associated with RCC could be due to local tumor growth, hemorrhage, paraneoplastic syndromes, or metastatic disease. Nowadays, more than 50% of RCC are detected incidentally.<sup>[2]</sup> Constitutional symptoms in RCC such as weight loss, fever, or night sweats could indicate advanced disease, and less frequently could be due to an abscess or a perinephric collection. This may be confused with the picture of Xanthogranulomatous pyelonephritis (XGP). This serious, chronic inflammatory disorder of the kidney presents with a destructive mass that invades the renal parenchyma. XGP is most commonly associated with *Proteus* or *E. coli* infection and is characterized by lipid-laden foamy macrophages. XGP shares many characteristics with true renal neoplasms in terms of its radiographic appearance and its ability to involve adjacent structures or organs. XGP is often associated with urinary tract obstruction, infection, nephrolithiasis, diabetes, and/or immunocompromised.

In our study elderly and diabetic patients presented with fever and loin pain as the primary complain. The initial US demonstrated an echo-free or low-echo-density space-occupying lesion suspicious of renal abscess or a suspicious mass with a perinephric collection. Although US is the quickest and least expensive method to demonstrate a renal abscess, differentiation between an abscess and a tumor however is impossible in many cases. CT appears to be the diagnostic procedure of choice for both renal abscesses and renal malignancy. It provides excellent delineation of the tissue, abscesses on CT, are characteristically well defined both before and after contrast agent enhancement. The distortion in imaging caused by malignancy superimposed by the infection depends on the degree of tissue necrosis and breakdown due to pus formation. Rarely arteriography may be used to demonstrate an abscess; in this study we

resorted to it in only one case to confirm the presence of neovascularity.

Conservative treatment in the form of medical therapy and percutaneous drainage was successful in controlling the infection in five patients, and the management was then planned on an elective basis. This has been our, and others, preferred method of management for severe forms of renal infection.<sup>[3]</sup>

Five patients had a large perirenal collection or/and abscess > 5 cm, two patients had gas formation on the imaging indicating emphysematous pyelonephritis. Prompt good control of blood sugar may decrease the rapid catabolism and subsequent gas formation, and percutaneous or surgical drainage may improve tissue perfusion and gas transport.<sup>[4]</sup> Those patients were managed by open surgical drainage. Later management was planned according to the biopsy results. Of this group only one patient had a performance status that would allow radical surgery.

Traditionally, there have been concerns regarding the safety and efficacy of fine-needle aspiration and needle core biopsy in the evaluation of renal masses. Using modern biopsy techniques the sensitivity and specificity of a needle core biopsy is reported to be 70-100% and 100% respectively, with accuracy superior to 90% in all recent series.<sup>[5-7]</sup> The previously reported high incidence of false-negative biopsies in patients with renal malignancy<sup>[8]</sup> that range from 80% to 95% likely reflects a different less-refined technique, which could also explain the previously reported higher incidence of tumor seeding at the puncture site, and bleeding in up to 44% in one study.<sup>[9]</sup> The average sensitivity of FNA for diagnosing malignancy is 76-97%, and is lower than that of needle cores.<sup>[10]</sup> In a contemporary study, there were four distinct indications for renal FNAB: (1) solid renal masses with atypical radiological features or poorly characterized on imaging studies due to lack of intravenous contrast or body habitus; (2) confirmation of radiologically suspected RCC in inoperable patients (advanced stage disease or poor surgical candidate status); (3) kidney mass in a patient with a prior history of other malignancy; and (4) miscellaneous (drainage of abscess, indeterminate cystic lesion, urothelial carcinoma), 36 patients (83.7%) in that study received a specific diagnosis based on renal FNAB cytology.<sup>[11]</sup> Accuracy is highly dependable on cytologist interpretative skills. It is thus reasonable to consider this option in patients with flank pain, febrile urinary tract infection, and renal mass. Those could benefit from percutaneous aspiration or biopsy to establish a diagnosis of renal abscess rather than malignancy. In this series five patients underwent a percutaneous biopsy using an 18-gauge or smaller needles, and we have not encountered cases complications or bleeding using the technique described

previously. Despite care to avoid areas of necrosis, and pus collection, these tumors proved difficult to biopsy, and only two patients had a positive histopathology.

In any case when we could not obtain adequate histopathology by the percutaneous or concomitant with the open drainage, the patients had a follow-up CT scan 2-3 weeks after they were discharged.

Few cases in the literature reported on renal infection and RCC and/or TCC.<sup>[12,13]</sup> Since hypernephroma can present with misleading systemic effects, imaging studies have to be carefully examined particularly in the immunocompromised patient with urinary tract infection and a renal mass. With initial medical therapy to control the diabetes and infection, and planning on obtaining histopathology either percutaneously or with the open drainage, the correct diagnosis was eventually reached in this small series of cases. We were able to reach the diagnosis initially in six patients, and a delayed diagnosis of RCC, with the follow-up CT scans in five patients when the infection subsided and the collection was drained.

## CONCLUSION

In the elderly and immunocompromised patient renal cancer may present as unusual renal abscess or perinephric collection due to superadded infection. Due to the complex pathology in this subset of patients, the clinical diagnosis was delayed till the tissue diagnosis was available. Histopathology and bacteriology are thus the mainstay of diagnosis. If the biopsy was negative, post drainage follow-up CT scan should be done to exclude any residual enhancing masses. Newer imaging technologies such as MRI and PET scan may prove valuable in patients with renal impairment, and when CT scan is not conclusive.

## REFERENCES

1. Gold PJ FA, Thompson JA. Paraneoplastic manifestations of renal cell carcinoma. *Semin Urol Oncol* 1996;14:216-22.
2. Kessler O, Mukamel E, Hadar H, Gillon G, Konechezky M, Servadio C. Effect of improved diagnosis of renal cell carcinoma on the course of the disease. *J Surg Oncol* 1994;57:210-4.
3. Aswathaman K GG, Gnanaraj L, Chacko NK, Kekre NS, Devasia A. Emphysematous pyelonephritis: Outcome of conservative management. *Urology* 2008;71:1007-9.
4. Huang JJ CK, Ruann, MK. Mixed acid fermentation of glucose as a mechanism of emphysematous urinary tract infection. *J Urol* 1991;146:148-51.
5. Neuzillet Y, Lechevallier E, Andre M, Daniel L, Coulange C. Accuracy and clinical role of fine needle percutaneous biopsy with computerized guidance of small (less than 4 cm) renal masses. *J Urol* 2004;171:1802-5.
6. Dechet CB, Zincke H, Sebo TJ, King BF, LeRoy AJ, Farrow GM, et al. Prospective analysis of computerised tomography and needle biopsy with permanent sectioning to determine the nature of solid renal masses in adults. *J Urol* 2003;169:71-4.
7. Shah RB, Bakshi N, Hafez KS, Wood DP Jr, Kunju LP. Image guided biopsy in the evaluation of renal mass lesions in contemporary urological practice. indications, adequacy, clinical impact, and limitations of the pathological diagnosis. *Hum Pathol* 2005;36:1309-15.
8. Herts BR, Baker ME. The current role of percutaneous biopsy in the evaluation of renal masses. *Semin Urol Oncol* 1995;13:254-61.
9. Lechevallier E, André M, Barriol D, Daniel L, Eghazarian C, De Fromont M, et al. Fine needle percutaneous biopsy of renal masses with helical CT guidance. *Radiology* 2000;216:506-10.
10. Campbell SC, Novick AC, Herts B, Fischler DF, Meyer J, Levin HS, et al. Prospective evaluation of fine needle aspiration of small solid renal masses: Accuracy and morbidity. *Urology* 1997;50:25-9.
11. Dragoescu EA, Liu L. Indications for renal fine needle aspiration biopsy in the era of modern imaging modalities. *Cytojournal* 2013;16:10-5.
12. Perimenis P. Pyonephrosis and renal abscess associated with kidney tumours. *Br J Urol* 1991;68:463-5.
13. Van Poppel H, Vereecken RL, Wilms G. Bilateral renal cell carcinoma diagnosed as renal abscesses. *Urology* 1985;25:548-50.

**How to cite this article:** Eltahawy E, Kamel M, Ezzet M. Management of renal cell carcinoma presenting as inflammatory renal mass. *Urol Ann* 2015;7:330-3.

**Source of Support:** Nil, **Conflict of Interest:** None.