

# Pediatric growing teratoma syndrome of the ovary

## A case report and review of the literature

Takanori Oyama, MD, PhD<sup>a,\*</sup> , Takuo Noda, MD, PhD<sup>a</sup>, Kana Washio, MD, PhD<sup>b</sup>, Akira Shimada, MD, PhD<sup>b</sup>

### Abstract

**Rationale:** Growing teratoma syndrome is defined as an increase in tumor size during or after systemic chemotherapy for germ cell tumors. These cases involve normal tumor marker levels and histological features of only mature teratoma. We report a rare case of an ovarian immature teratoma in a Japanese child that was diagnosed as growing teratoma syndrome.

**Patient concerns:** A 12-year-old girl presented a painful abdominal mass. She underwent left salpingo-oophorectomy for grade 1 immature teratoma in the left ovary. She did not undergo additional chemotherapy or radiotherapy. Four months later, she presented with grade 3 immature teratoma disseminated into the abdomen and pelvis. Chemotherapy resulted in the tumor marker levels returning to their normal ranges, although the tumors had grown slightly.

**Diagnosis:** The specimens resected by laparotomy after the chemotherapy consisted of mature tissue predominantly, although primitive neuroepithelium was observed in a small part of the specimen. The pathological diagnosis was grade 1 immature teratoma, notwithstanding the clinical diagnosis was growing teratoma syndrome based on the clinical features and pathogenesis.

**Interventions:** Laparotomy was performed at 7 months after the first operation, with resection of various tumors as well as the rectum, sigmoid colon, residual left fallopian duct, and a small part of the ileum and omentum. Some small tumors at the parietal peritoneum were ablated, although many tiny tumors around the uterus were left untreated.

**Outcomes:** The patient has been free from recurrence for 5 years.

**Lessons:** Growing teratoma syndrome can develop in children, and their tumor size is comparable to that in adolescents and adults. Furthermore, development of growing teratoma syndrome from a primary germ cell tumor is presumably faster in children than in adolescents and adults. Complete resection of all growing teratoma tissue is recommended, although fertility-sparing surgery should be considered when possible.

**Abbreviations:** AFP = alfa-fetoprotein, BEP = bleomycin, etoposide and cisplatin, Beta-HCG = beta-human chorionic gonadotropin, CA125 = carbohydrate antigen 125, CT = computed tomography, GP = gliomatosis peritonei, GTS = growing teratoma syndrome, ICE = ifosfamide, carboplatin, etoposide, NSGSts = non-seminomatous germ cell tumors, PET-CT = positron emission tomography-computed tomography.

**Keywords:** growing teratoma syndrome, immature teratoma, ovarian tumor, pediatric

## 1. Introduction

Growing teratoma syndrome (GTS) is defined as an increase in tumor size during or after systemic chemotherapy for germ cell

Editor: Maya Saranathan.

Written informed consent was obtained from the patient's parents for the publication of this case report and the accompanying images.

The authors have no funding and conflicts of interest to disclose.

Data sharing not applicable to this article as no datasets were generated or analyzed during the current study.

<sup>a</sup> Department of Pediatric Surgery, <sup>b</sup> Department of Pediatrics, Okayama University Hospital, Okayama, Japan.

\* Correspondence: Takanori Oyama, Department of Pediatric Surgery, Okayama University Hospital, 2-5-1 Shikata-cho, Kita-ku, Okayama, 700-8558, Japan (e-mail: oyama@cc.okayama-u.ac.jp).

Copyright © 2020 the Author(s). Published by Wolters Kluwer Health, Inc.

This is an open access article distributed under the Creative Commons Attribution License 4.0 (CCBY), which permits unrestricted use, distribution, and reproduction in any medium, provided the original work is properly cited.

How to cite this article: Oyama T, Noda T, Washio K, Shimada A. Pediatric growing teratoma syndrome of the ovary: A case report and review of the literature. *Medicine* 2020;99:38(e22297).

Received: 18 November 2019 / Received in final form: 7 August 2020 /

Accepted: 21 August 2020

<http://dx.doi.org/10.1097/MD.00000000000022297>

tumors, with normal tumor markers and histological features of only mature teratoma. Logothetis et al<sup>[1]</sup> first used this term in 1982, although DiSaia et al<sup>[2]</sup> previously described a similar phenomenon as “chemotherapeutic retroconversion” in 1977. Amsalem et al<sup>[3]</sup> subsequently concluded that GTS and chemotherapeutic retroconversion were probably the same phenomenon.

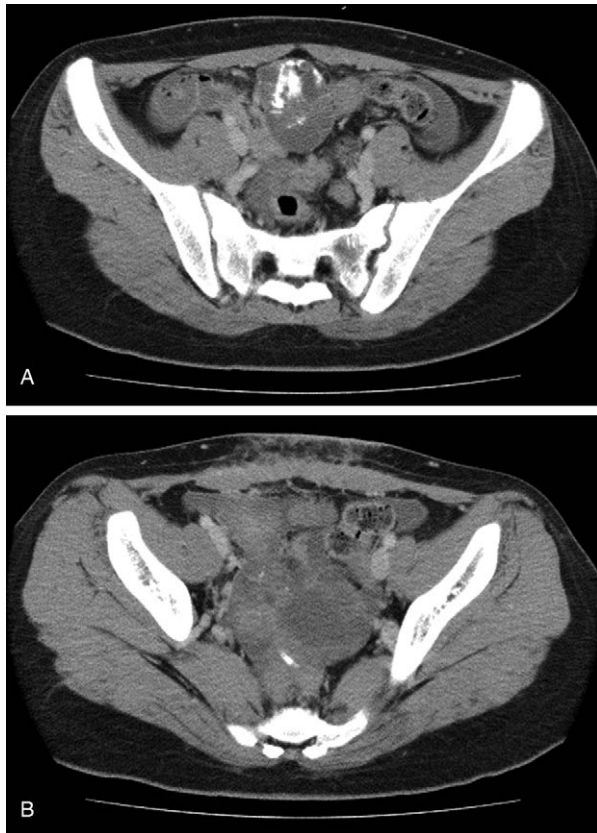Although GTS is well known in male patients with germ cell tumors, ovarian GTS is less commonly reported. According to Li et al,<sup>[4]</sup> who reviewed 101 cases reported in the English literature, ovarian GTS typically occurs in adolescents and young adults (median age at diagnosis of primary immature teratoma: 22 years), and only 8 cases (7.9%) were diagnosed in children. Thus, we report a rare case of an ovarian immature teratoma that was diagnosed as GTS in a 12-year-old Japanese girl, and review the literature regarding ovarian GTS in children.

## 2. Case report

A 12-year-old girl was admitted to a local hospital with a painful abdominal mass. Abdominal computed tomography (CT) revealed a large cystic mass containing calcified tissues and fat in the pelvic cavity. Serum tumor marker levels were normal (alfa-fetoprotein [AFP]: 11.25 ng/mL, beta-human chorionic gonadotropin [beta-HCG]: <0.10 mg/mL), although serum CA125 levels were not

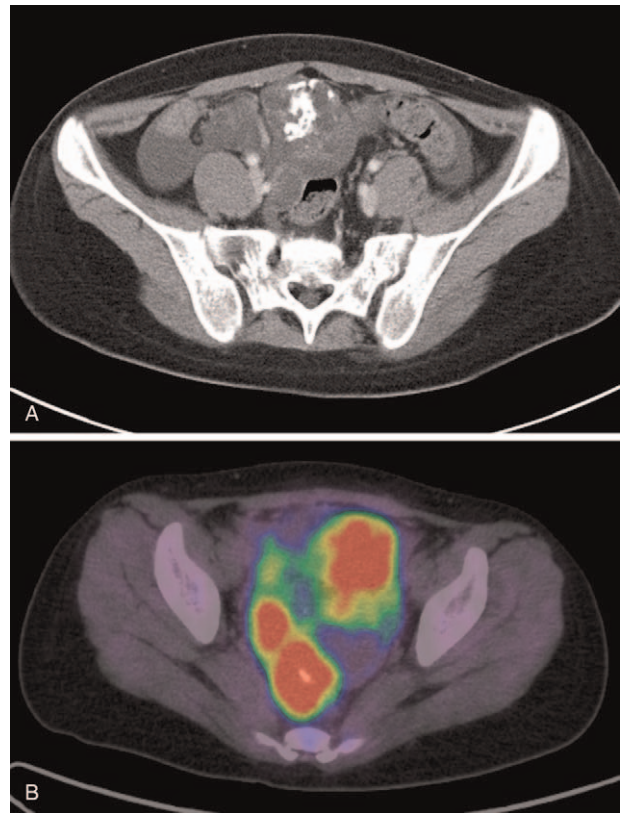
measured. Left salpingo-oophorectomy was performed based on a suspicion of a teratoma in the left ovary. Interestingly, malignant cells were not observed in the ascites despite previous rupture of the tumor. Gross total resection was achieved and the pathological diagnosis was grade 1 immature teratoma. No additional chemotherapy or radiotherapy was performed.

Four months after the operation, abdominal CT revealed multiple multinodular tumors with a maximum diameter of 9.0 cm in the pelvis, which contained calcified and fatty tissue (Fig. 1), although the lymph nodes were not enlarged. Open biopsy was used to obtain a specimen for histological evaluation, which supported a diagnosis of grade 3 immature teratoma with substantial primitive neuroepithelium. The patient was admitted to our hospital soon after the recurrence with lower abdominal distention and tenderness, and the elastic hard tumor was palpable. Serum tumor marker testing revealed that her CA125 level was elevated to 198.2 U/mL, but with normal levels of AFP (5.1 ng/mL) and beta-HCG (<0.40 mIU/mL), despite the tumor's immaturity. Treatment was started using 1 cycle of bleomycin, etoposide, and cisplatin (BEP) chemotherapy, which normalized the CA125 levels, but the tumor became slightly enlarged. The treatment was then changed to 1 cycle of ifosfamide, carboplatin, and etoposide (ICE) chemotherapy, although the tumor became further enlarged. After the ICE chemotherapy, positron emission tomography-computed tomography (PET-CT) revealed abnormal accumulation in the lower abdomen and pelvis, which was considered indicative of a recurrent lesion (Fig. 2).

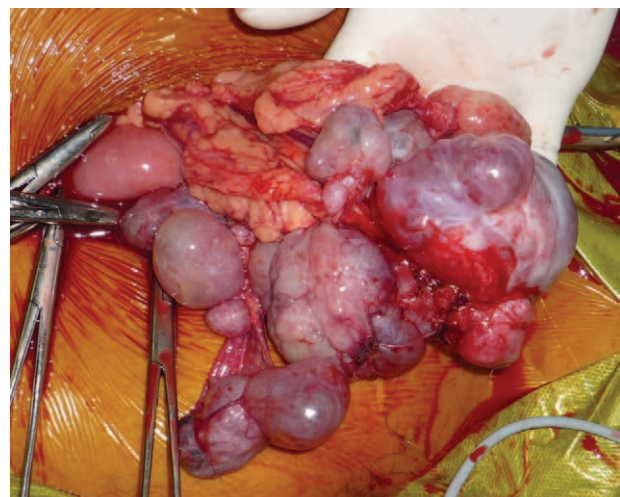


**Figure 1.** Abdominal computed tomography findings from 4 months after the first operation revealed multiple multinodular tumors containing calcified and fatty tissues (A). Invasion or lymph node swelling were not detected. Small amounts of ascites were observed around the liver and in the pelvic cavity (B).

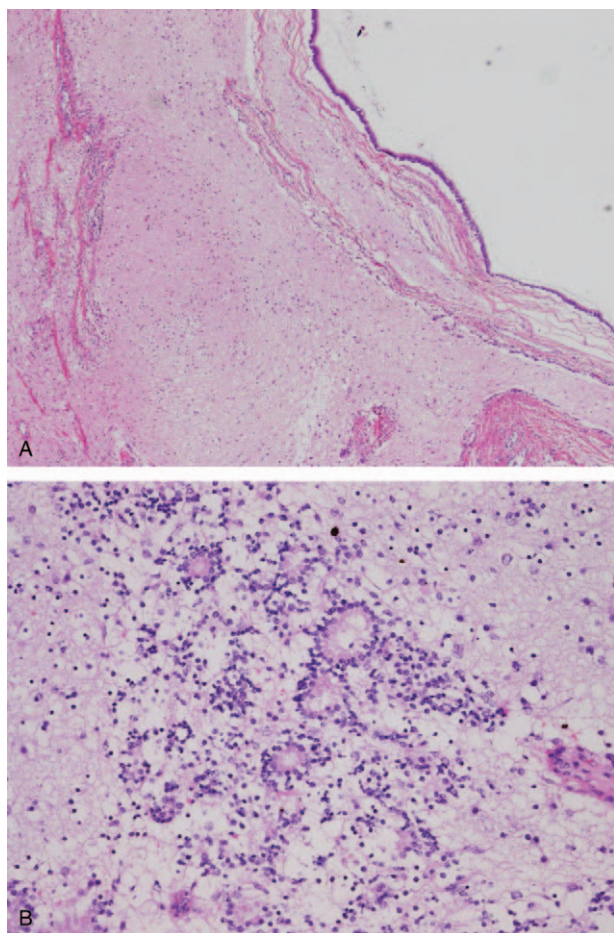
Given the tumor growth, despite normalization of tumor markers after 2 chemotherapy cycles, we suspected GTS, which requires a pathological diagnosis and total resection even in asymptomatic cases. Thus, at 7 months after the first operation, we performed laparotomy (Fig. 3) and observed numerous disseminated tumors at the parietal and visceral peritoneum in



**Figure 2.** Post-chemotherapy findings from abdominal computed tomography (A) and positron emission tomography-computed tomography (B). The tumor had grown (A), and abnormal accumulation was observed (B).



**Figure 3.** The surgery revealed numerous disseminated tumors in the great omentum.



**Figure 4.** Pathological findings revealed mature tissue in almost all parts of the tumor (A), but a primitive neuroepithelium, represented by a slightly high cell density, in a small part of the tumor (B).

the lower abdomen and pelvis. We resected the rectum and sigmoid colon because several disseminated tumors were firmly adherent to the ventral side of the rectum. We also resected the residual left fallopian duct and small parts of the ileum and omentum with the tumors. Some small tumors at the parietal peritoneum were ablated, although many tiny tumors around the uterus were not treated. The abdominal lymph nodes were not enlarged and the cytology results for the ascites were negative.

Pathological analysis of the resected specimens revealed that most of the specimen consisted of mature tissue, although primitive neuroepithelium was observed in a small part of the specimen (Fig. 4). The pathological diagnosis was grade 1 immature teratoma, which did not fulfill the pathological criteria for GTS (histological evidence of only mature teratoma). However, the pathogenesis agreed with that of GTS, and the use of additional chemotherapy could have converted the tumor into a mature teratoma. Thus, we considered the tumor to be GTS. The postoperative course was uneventful, and the patient was discharged 1 month after the operation with no additional chemotherapy or radiotherapy. The residual disseminated tumors have not enlarged during the 5-year follow-up.

### 3. Discussion

Ovarian immature teratoma is a relatively rare tumor that arises in young women, whose prognosis has been dramatically improved by BEP chemotherapy after fertility-preserving surgery. However, in the advanced cases with peritoneal metastasis, the prognosis remains poor even after appropriate treatment. In these cases, the diagnosis of GTS relies on 3 criteria:

- (1) germ cell tumor growth during or after systemic chemotherapy,
- (2) the normalization of previously elevated serum tumor markers, and
- (3) the absence of immature components, other than mature teratoma, in the resected specimen.

In this context, ovarian teratoma of any grade can induce peritoneal implantation of mature glial tissues, which are known as gliomatosis peritonei (GP), and GTS is considered a type of GP, as both GTS and GP are associated with benign peritoneal glial implants regardless of the original tumor's malignancy grade.<sup>[5]</sup>

Two different pathogenic mechanisms have been proposed for GTS:

- (1) chemotherapy induces the malignant differentiation of immature teratoma into a mature component<sup>[2]</sup> or
- (2) chemotherapy destroys only the immature malignant cells and spares the mature benign teratomatous elements.<sup>[1]</sup>

In the present case, the tumor had ruptured before the first operation, which might have been the cause of GTS development. Chemotherapy or radiotherapy was not performed after the first operation because there was no evidence of malignant ascites, dissemination was not detected using PET-CT, and the immature teratoma was histologically classified as grade 1. However, the disseminated tumor had enlarged at 4 months after the first surgery, and the histological classification was a grade 3 immature teratoma with an elevated CA125 level. Thus, the teratoma recurred as a higher-grade immature teratoma, rather than as GTS, which was induced by the BEP and ICE chemotherapy that was performed after the recurrence. Interestingly, the present case developed from a recurrent tumor, whereas the reported cases have developed from a primary tumor. In our case, the pathological diagnosis after the last surgery was grade 1 immature teratoma, and we suspect that further chemotherapy might have led to teratoma maturation that would ultimately have fulfilled the criteria for GTS. Therefore, we clinically diagnosed the tumor as GTS. Another important difference is that the only elevated tumor marker in the present case was CA125, while almost all reported cases have involved pre-treatment elevations of AFP and HCG, AFP and CA125, or only AFP.<sup>[4]</sup> Thus, although the cause for this discrepancy is unclear, the tumor marker profile from present case appears to be rare.

The incidence of GTS in non-seminomatous germ cell tumors of the testis is 1.9% to 7.6%.<sup>[1,6]</sup> In contrast, the incidence of ovarian GTS in ovarian immature teratomas is 12% to 19%,<sup>[7,8]</sup> with the GTS originating from the right ovary in 57% of cases and the left ovary in 43% of cases. The median primary tumor size was reportedly 18.7 cm (range: 6–45 cm) and median subsequent tumor size was 8.6 cm (range: 1–25 cm). During the interval between the primary treatment and the diagnosis of ovarian GTS, the median tumor growth was 0.94 cm/month (range: 0.3–4.3 cm/month) and the median interval to diagnosis was 26.6 months (range: 1–264 months).<sup>[4]</sup> While the GTS

usually occurs at the primary site of the germ cell tumor, 13% of GTS cases involve metastatic sites.<sup>[9]</sup>

Ovarian GTS typically occurs in adolescents and young adults, with a median age of 22 years at the diagnosis of primary immature teratoma and only 7.9% of GTS cases being diagnosed during childhood.<sup>[4]</sup> We have identified 17 cases of ovarian GTS

in children in the English literature (Table 1).<sup>[10–18]</sup> The youngest patient was 4 years old at the diagnosis of the primary germ cell tumor. The primary tumor size was 9 to 30 cm, which is comparable to in adolescent and adult patients, and our case involved the smallest reported primary tumor size (9 cm). The histology of the primary germ cell tumor was immature teratoma

**Table 1**  
**Ovarian growing teratoma syndrome in children: review of the literature.**

Case	Author	Year	n	Age (yr)	Initial symptoms	Histology	Location	Size (cm)	Primary germ cell tumor			Tumor makers after primary Treatment
									Elevated tumor makers	Treatment	CT regimen	
1	Moskovic et al <sup>[10]</sup>	1991	1	12	N/A	IT	Right ovary	N/A	AFP	S + CT	N/A	Negative
2	Inaoka et al <sup>[11]</sup>	2003	1	5	Abdominal distension	IT grade 2	Right ovary, peritoneum	Huge	AFP, CA125, NSE	S + CT + S + CT	Combination	Negative
3	Amsalem et al <sup>[9]</sup>	2004	1	12	Abdominal pain and distension	IT grade 2	Left ovary, omentum	30	AFP, CA125, LDH	S + CT	BEP 3 cycles	Negative
4	Nimkin et al <sup>[12]</sup>	2004	1	12	Abdominal distension	IT grade 3	Right ovary, omentum, peritoneum	25 × 25 × 20	AFP, CA125	S + CT	N/A	Negative
5	Tangjitgamol et al <sup>[13]</sup>	2006	1	5	Abdominal pain	IT grade 3	N/A	11	AFP	S + CT	BEP 2 cycles, VAC 2 cycles	Negative
6	Zagame et al <sup>[7]</sup>	2006	3	12	N/A	Mixed GCT	N/A	N/A	N/A	S	N/A	N/A
7				11	N/A	IT	N/A	N/A	N/A	S	N/A	N/A
8				9	N/A	Mixed GCT	N/A	N/A	N/A	S	N/A	N/A
9	Hsieh et al <sup>[14]</sup>	2009	1	4.5	N/A	IT grade 3	Left ovary, omentum, peritoneum	13 × 15 × 14	AFP	S + CT	VIP 1 cycle, EC 1 cycle	Negative
10	Al-Jumaily et al <sup>[15]</sup>	2012	1	12	Abdominal pain and distension	Mixed GCT	Right ovary	Huge	AFP, hCG	S + CT	BEP 6 cycles, VAC 4 cycles	Negative
11-13	Bentivegna et al <sup>[8]</sup>	2015	3	<12	N/A	N/A	N/A	N/A	N/A	N/A	N/A	Negative
14	Daher et al <sup>[16]</sup>	2015	1	4	Vomiting and abdominal pain	Mixed GCT (IT grade 3)	Left ovary, omentum	17 × 12 × 7	AFP, hCG	S + CT	VIP	Negative
15	Rentea et al <sup>[17]</sup>	2017	1	12	Abdominal mass	IT grade 3	Right ovary, peritoneum	Large	AFP	S + CT	BEP 4 cycles	Negative
16	Frazer et al <sup>[18]</sup>	2019	1	12	Abdominal pain and distension	Mixed GCT (IT grade 3)	Right ovary	30	AFP	S + S + CT	CEB 2 cycles	N/A
17	Our case		1	12	Abdominal pain and mass	IT grade 1→3	Left ovary	9	CA125	S + CT	BEP 1 cycle, ICE 1 cycle	Negative

#### Growing teratoma syndrome lesion

Case	Time to development	Location	Size (cm)	Treatment	Residual tumor	Follow-up	Fertility-preserving surgery
1	During CT	Pelvis	N/A	Resection	Yes	N/A	N/A
2	6 mo after CT	Around the liver and inferior vena cava	N/A	Resection	Yes	Mass remained stable for 3 yr.	N/A
3	7 mo after Dx	Right subdiaphragmatic area, Pouch of Douglas	2–3	Resection, omentectomy, paraortic lymph node dissection	No	No recurrence for 2 yr.	N/A
4	12 mo after CT	Right subdiaphragmatic area, mesentery, bilateral paracolic gutters, broad ligament, cul-de-sac.	N/A	Resection × 3	Yes	144 mo	N/A
5	2–3 mo after Dx (during CT)	Right subdiaphragmatic area, pelvis, cul-de-sac	16	Resection × 2	Yes	No recurrence for 2 yr.	N/A
6	15 mo after Dx	Retroperitoneum	N/A	Resection	No	180 mo.	N/A
7	7 mo after Dx	Peritoneum	N/A	Resection	No	184 mo.	N/A
8	6 mo after Dx	Peritoneal carcinomatosis	N/A	Resection	Yes	177 mo.	N/A
9	During CT	Peritoneum	N/A	Resection, interferon α-2b, gamma-knife surgery	N/A	No recurrence for 2 yr.	N/A
10	6 mo after Dx (during CT)	Right suprarenal area	N/A	Resection	No	Complete response after 32 mo.	N/A
11-13	N/A	N/A	N/A	N/A	N/A	N/A	N/A
14	4 mo after Dx (during CT)	Right subdiaphragmatic area, omentum, appendix, pelvis	N/A	Resection × 3	Yes	Healty.	N/A
15	6 mo after Dx (during CT)	Right subdiaphragmatic area, pelvis, cardiophrenic area	7.9 × 7.7 × 8.7	Resection, omentectomy, paraaortic lymph node dissection, CT (temozolomide, tretinoin, and sorafenib)	Yes	No new tumor growth.	N/A
16	2 mo after S	Pelvis and liver	8 × 6	Resection, partial hepatectomy	No	No recurrence for 18 mo.	N/A
17	3 mo after recurrence (during CT)	Pelvis	Up to 9.8	Resection, lymph node dissection	Yes	Stable for 5 yr.	Yes

AFP = alpha-fetoprotein, BEP = bleomycin + etoposide + cisplatin, CA-125 = carbohydrate antigen 125, CEB = carboplatin, etoposide, and bleomycin, CT = chemotherapy, Dx = diagnosis, EC = epirubicin + cyclophosphamide, GCT = germ cell tumor, hCG = human chorionic gonadotropin, IT = immature teratoma, N/A = not available, NSE = neuron-specific enolase, S = surgery, VAC = vincristine + actinomycin + cisplatin, VIP = etoposide + ifosfamide + cisplatin.

in 9 cases and mixed germ cell tumor in 5 cases. Eleven patients received chemotherapy, and the GTS diagnosis was made during the chemotherapy in 6 cases (including the present case), which suggests that GTS development is faster in children than in adolescents and adults. The GTS may cause obstruction or compression of abdominal structures, including the urinary tract, vascular structures, and gastrointestinal tract.<sup>[11]</sup> Another report described mesenteric compression with bowel necrosis, renal failure due to ureteral compression, bowel obstruction, and bile duct obstruction.<sup>[9]</sup> Fortunately, most children (including our patient) did not develop serious symptoms.

The imaging-based diagnosis of GTS is supported by a mass with increasing size that contains fat, calcification, or cystic changes.<sup>[19]</sup> Thus, similar to in ovarian cancer, PET-CT provides more information than CT alone, although a positive PET-CT finding does not always reflect malignancy.<sup>[20]</sup> For example, positive PET-CT findings could be related to the high rate of glucose metabolism in brain tissues for cases of GTS (as in the present case).<sup>[21]</sup>

The GTS lesions are refractory to chemotherapy, which makes surgery the only curative treatment.<sup>[19]</sup> Complete resection of all GST tissue is recommended, as incomplete resection can lead to progression or malignant transformation. For example, Shigeta et al reviewed 55 cases of ovarian GTS and reported that GTS recurred in 12.7% of cases (7/55) and underwent malignant transformation in 5.4% of cases (3/55),<sup>[22]</sup> which can result in sarcoma, adenocarcinoma, or a primitive neuroectodermal tumor and carcinoid.<sup>[23]</sup> Thus, if the residual teratoma components are caused by chemotherapeutic retroconversion, it appears logical that they would retain a high level of histopathological genetic aneuploidy and their malignant potential.<sup>[24–26]</sup> Therefore, complete surgical resection is a highly desirable treatment,<sup>[27]</sup> although recurrence or malignant transformation have not been reported in children. Nevertheless, fertility-sparing surgery is recommended when possible based on the findings of 2 studies. Li et al reviewed 101 patients with ovarian GTS and found that 5 of these patients became pregnant during the interval between the primary disease and GTS, with 1 patient becoming pregnant after the diagnosis of ovarian GTS. Bentivegna et al<sup>[8]</sup> have also reported that 5 of 38 patients with ovarian GTS became pregnant after the diagnosis of ovarian GTS. Both studies mention that fertility-sparing surgery is recommended “when possible,” although the criteria for evaluating this possibility remain unclear. Further studies are needed to address this issue, as none of the reports regarding the children in Table 1 indicate whether they underwent fertility-sparing surgery, subsequently became pregnant, and relapsed.

The recurrence rate for ovarian GTS is up to 83% in cases with partial resection but only 0% to 4% in cases with complete resection.<sup>[4]</sup> Among the reported children, only 2 cases involved complete resection (Table 1), and the median recurrence-free interval (from the final treatment for GTS to recurrence) was 24 months. These findings strongly indicate that a prolonged follow-up is needed in cases with GTS.<sup>[22]</sup> Furthermore, several cases involved malignant transformation of GTS, which might be misdiagnosed as mature teratoma because the low-grade primitive neuroepithelium is only present in a small part of the specimen (as in the present case). Moreover, in the present case, we elected to leave many disseminated small immature tumors, and did not perform chemotherapy or radiotherapy because of the paucity of the primitive neuroepithelium, although close

follow-up is necessary given the possibility of malignant transformation.

#### 4. Conclusions

We encountered a rare case of an ovarian immature teratoma that was diagnosed as GTS in a Japanese child. In similar cases, the GTS can develop during early childhood and the tumor size is comparable to that in adolescents and adults, although the development of the GTS from the primary germ cell tumor is presumably faster in children. Complete resection of all GST tissue is recommended based on the possibility of malignant transformation, although fertility-sparing surgery should be considered when possible.

#### Acknowledgment

The authors thank Editage for English language editing.

#### Author contributions

**Conceptualization:** Takanori Oyama, Takuo Noda, Akira Shimada.

**Data curation:** Takanori Oyama.

**Investigation:** Takanori Oyama, Takuo Noda, Kana Washio, Akira Shimada.

**Project administration:** Takuo Noda, Akira Shimada.

**Supervision:** Takuo Noda.

**Visualization:** Takanori Oyama.

**Writing – original draft:** Takanori Oyama.

**Writing – review & editing:** Takanori Oyama, Takuo Noda, Kana Washio, Akira Shimada.

#### References

- [1] Logothetis CJ, Samuels ML, Trindade A, et al. The growing teratoma syndrome. *Cancer* 1982;50:1629–35.
- [2] DiSaia PJ, Saltz A, Kagan AR, et al. Chemotherapeutic retroconversion of immature teratoma of the ovary. *Obstet Gynecol* 1977;49:346–50.
- [3] Amsalem H, Nadjari M, Prus D, et al. Growing teratoma syndrome vs chemotherapeutic retroconversion: case report and review of the literature. *Gynecol Oncol* 2004;92:357–60.
- [4] Li S, Liu Z, Dong C, et al. Growing teratoma syndrome secondary to ovarian giant immature teratoma in an adolescent girl: a case report and literature review. *Medicine (Baltimore)* 2016;95:e2647.
- [5] Umekawa T, Tabata T, Tanida K, et al. Growing teratoma syndrome as an unusual cause of gliomatosis peritonei: a case report. *Gynecol Oncol* 2005;99:761–3.
- [6] Jeffery GM, Theaker JM, Lee AH, et al. The growing teratoma syndrome. *Br J Urol* 1991;67:195–202.
- [7] Zagamé L, Pautier P, Duvillard P, et al. Growing teratoma syndrome after ovarian germ cell tumors. *Obstet Gynecol* 2006;108:509–14.
- [8] Bentivegna E, Azais H, Uzan C, et al. Surgical outcomes after debulking surgery for intraabdominal ovarian growing teratoma syndrome: analysis of 38 cases. *Ann Surg Oncol* 2015;22(Suppl 3):S964–70.
- [9] André F, Fizazi K, Culine S, et al. The growing teratoma syndrome: results of therapy and long-term follow-up of 33 patients. *Eur J Cancer* 2000;36:1389–94.
- [10] Moskovic E, Jobling T, Fisher C, et al. Retroconversion of immature teratoma of the ovary: CT appearances. *Clin Radiol* 1991;43:402–8.
- [11] Inaoka T, Takahashi K, Yamada T, et al. The growing teratoma syndrome secondary to immature teratoma of the ovary. *Eur Radiol* 2003;13:2115–8.
- [12] Nimkin K, Gupta P, McCauley R, et al. The growing teratoma syndrome. *Pediatr Radiol* 2004;34:259–62.
- [13] Tangjitgamol S, Manusirivithaya S, Leelahakorn S, et al. The growing teratoma syndrome: a case report and a review of the literature. *Int J Gynecol Cancer* 2006;16(Suppl 1):384–90.

- [14] Hsieh YL, Liu CS. Progression from an immature teratoma with miliary gliomatosis peritonei to growing teratoma syndrome with nodular gliomatosis peritonei. *Pediatr Neonatol* 2009;50:78–81.
- [15] Al-Jumaily U, Al-Hussaini M, Ajlouni F, et al. Ovarian germ cell tumors with rhabdomyosarcomatous components and later development of growing teratoma syndrome: a case report. *J Med Case Rep* 2012; 6:13.
- [16] Daher P, Riachy E, Khoury A, et al. Growing teratoma syndrome: first case report in a 4-year-old girl. *J Pediatr Adolesc Gynecol* 2015; 28:e5–7.
- [17] Rentea RM, Varghese A, Ahmed A, et al. Pediatric ovarian growing teratoma syndrome. *Case Rep Surg* 2017;2017:3074240.
- [18] Frazer JL, Hook CE, Addley HC, et al. Recurrent ovarian immature teratoma in a 12-year-old girl: Implications for management. *Gynecologic Oncology* 2019;154:259–65.
- [19] Panda A, Kandasamy D, Sh C, et al. Growing teratoma syndrome of ovary: avoiding a misdiagnosis of tumour recurrence. *J Clin Diagn Res* 2014;8:197–8.
- [20] Kikawa S, Todo Y, Minobe S, et al. Growing teratoma syndrome of the ovary: a case report with FDG-PET findings. *J Obstet Gynaecol Res* 2011;37:926–32.
- [21] Hariprasad R, Kumar L, Janga D, et al. Growing teratoma syndrome of ovary. *Int J Clin Oncol* 2008;13:83–7.
- [22] Shigeta N, Kobayashi E, Sawada K, et al. Laparoscopic excisional surgery for growing teratoma syndrome of the ovary: case report and literature review. *J Minim Invasive Gynecol* 2015;22:668–74.
- [23] Shibata K, Kajiyama H, Kikkawa F. Growing teratoma syndrome of the ovary showing three patterns of metastasis: a case report. *Case Rep Oncol* 2013;6:544–9.
- [24] Davey DD, Ulbright TM, Loehrer PJ, et al. The significance of atypia within teratomatous metastases after chemotherapy for malignant germ cell tumors. *Cancer* 1987;59:533–9.
- [25] Castedo SM, de Jong B, Oosterhuis JW, et al. Chromosomal changes in mature residual teratomas following polychemotherapy. *Cancer Res* 1989;49:672–6.
- [26] Molenaar WM, Oosterhuis JW, Meiring A, et al. Histology and DNA contents of a secondary malignancy arising in a mature residual lesion six years after chemotherapy for a disseminated nonseminomatous testicular tumor. *Cancer* 1986;58:264–8.
- [27] Homs MY, Schreuder HW, Jonges GN, et al. Clinical and radiologic signs of relapsed ovarian germ cell tumor: tissue is the issue. *Case Rep Obstet Gynecol* 2013;2013:984524.