

PERCUTANEOUS TRANSLUMINAL ANGIOPLASTY

by

RODNEY CURRY and LYNN JOHNSTON

Belfast City Hospital

IN 1963 Dr Charles Dotter, a radiologist of Portland, Oregon whilst performing an aortogram by retrograde catheterisation of the right iliac artery inadvertently passed his guide wire, and then a catheter, through a complete occlusion of the artery. There was a palpable though diminished femoral pulse in the groin and the catheter was passed easily. It was only when radiographs were taken that these revealed the catheter had been passed through an apparent occlusion of the iliac artery. It occurred to him that it might be possible to dilate a blocked or narrowed artery by this means. A year passed before the opportunity arose, when he successfully dilated a tight stenosis of the femoral artery in an elderly woman with gangrenous toes. This was achieved by passing a guide wire through the stenosis, then passing a catheter over it, then passing a larger catheter over that, thus dilating the artery step by step. Publication of this achievement¹ caused slight interest in Europe and less in America. At certain centres attempts were made to modify the technique by using a balloon catheter which could be positioned in the stenotic area and then inflated, but the various types of balloon catheter developed did not have the strength to dilate the stenosis, tending to take up an hour-glass shape.

In 1974 balloon dilatation, or transluminal angioplasty as it has come to be called, was revolutionised by a Swiss radiologist, Andreas Gruntzig, when he developed a double lumen catheter with a balloon, made of polyvinyl chloride, near its tip, which had the authority to dilate stenotic arteries without deforming.² Initially used to dilate peripheral vessels it has come to be used in coronary and renal vessels.

It took about fifteen years from Dotter's original publication and about five years from Gruntzig's paper before the medical world at large accepted this technique. Those working in Britain interested in vascular occlusions have been slower than most in overcoming their scepticism. Reports now suggest that dilatation of iliac stenoses have been successful in a high proportion of cases with an initial success rate of 92 percent^{3, 4} and with two year patency rates of 87 percent³ and 86 percent.⁵ Results for femoro-popliteal dilatation are not as good as for iliac dilatation though Gruntzig has reported an 84 percent initial success rate for occlusions of less than 10 cm with a three year patency rate of 70 percent.⁶ Patients with acute thrombosis and embolism are not suitable.

TECHNIQUE

The procedure of percutaneous transluminal angioplasty (PTA) using the Gruntzig catheter is performed by passing a guide wire, under local anaesthetic, through the stenosis or occlusion which has been identified by an arteriogram. An angiographic catheter is then passed and the pressure gradient across the stenosis is measured. The patient is then given 5000 units of heparin via the catheter. The catheter is then replaced by a balloon catheter of appropriate size which is positioned in the narrowed area and inflated several times. The pressure gradient is then

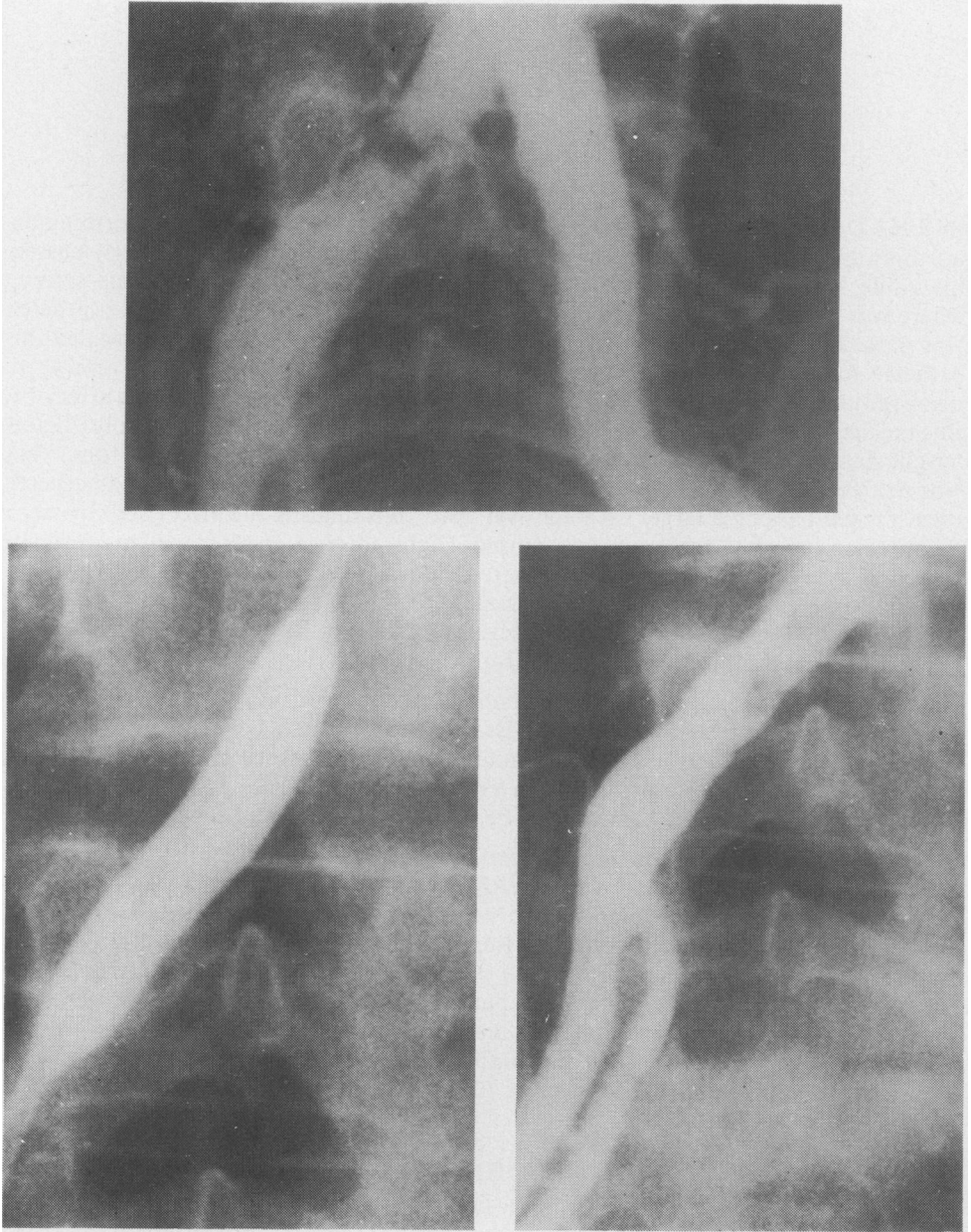


FIG. 1

Top. *Localised stenosis in right common iliac artery.*

Bottom Left. *Catheter in position and balloon inflated with contrast medium.*

Bottom Right. *Post dilatation film.*

re-assessed: ideally it has been abolished or markedly reduced. Finally, a post-dilatation angiogram is taken. The patient is started on anti-platelet therapy, Persantin or aspirin. He remains in bed for 24 hours and is usually fit for discharge on the second day.

CASE REPORTS AND REVIEW OF PATIENTS TREATED

The ideal case is a patient with intermittent claudication or more severe ischaemia with a short segment block in a major vessel, especially an iliac artery.

Case 1

A 58 year old man complaining of intermittent claudication in the right leg. A series of arteriograms (Fig. 1) shows a short localised stenosis in the right common iliac artery, the dilated Gruntzig balloon filled with contrast medium positioned across the stenosis, and the arteriogram after dilatation. The appearances of the stenosis is improved. The pressure trace (Fig. 2) shows the gradient across the stenosis before and after dilation and demonstrates the abolition of the gradient.

This man's intermittent claudication was abolished and ankle pulses regained after his PTA. He was discharged from hospital three days after the procedure.

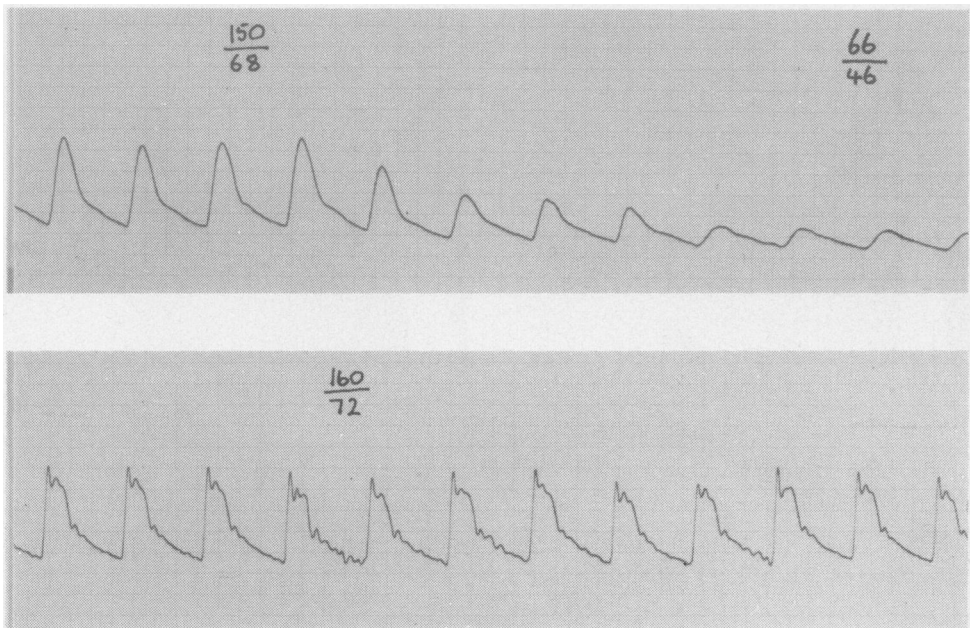


FIG. 2

Top. *Pre-dilatation pressure trace—showing gradient above and below stenosis.*

Bottom. *Post-dilatation pressure trace—showing abolition of gradient.*

Short localised blocks in the femoral and popliteal arteries are also suitable.

Case 2

A 70 year old man with bilateral intermittent claudication. Arteriogram showed a short stenosis in the distal femoral artery on both sides. PTA was performed bilaterally with resultant improvement in the arteriographic appearance and abolition of his intermittent claudication. He was discharged three days after PTA. The arteriograms (Fig. 3) show the vessels of one side before and after angioplasty.

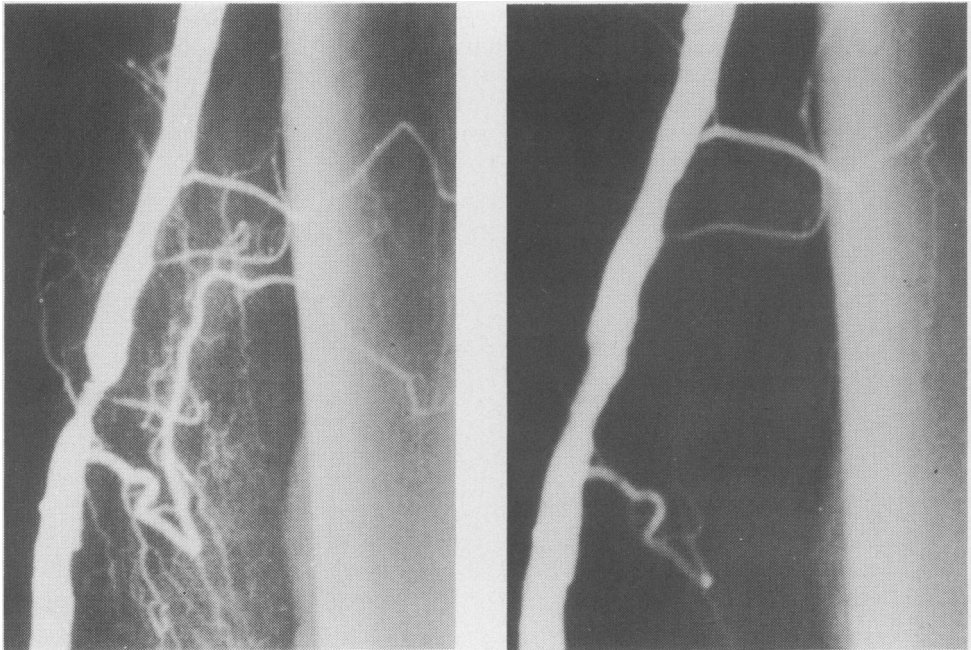


FIG. 3

Left. Pre-dilatation arteriogram showing localised stenosis in distal superficial femoral artery.

Right. Post-dilatation arteriogram showing marked reduction in degree of stenosis and reduction of collateral flow.

Long segment occlusions can be attempted but it is generally considered that total occlusion of the iliac arteries and occlusions of the femoro-popliteal arteries of more than 10 cm are unsuitable and are better dealt with by operation. However, in cases where the limb is in jeopardy and surgery is not feasible, i.e., where there is no distal pick-up, there is nothing to be lost by attempted PTA.

Case 3

A 57 year old diabetic woman was admitted with three gangrenous toes and a black patch on her heel. There were no distal pulses. Arteriogram showed a blocked femoral artery with no pick-up in the popliteal artery and therefore unsuitable for operation. PTA was attempted with re-canalisation of femoral, popliteal and distal arteries. She lost three gangrenous toes but the rest of the limb was salvaged. The change in the circulation in the limb is illustrated in Fig. 4.

We first used this technique six months ago at the Belfast City Hospital, and we have now tried it in ten cases. In four cases there was an iliac artery stenosis (two had femoral occlusions as well), three cases had femoral stenoses or blocks (one bilateral), one case had a popliteal stenosis, one had acute thrombosis of the tibial vessels and one had a brachial artery block.

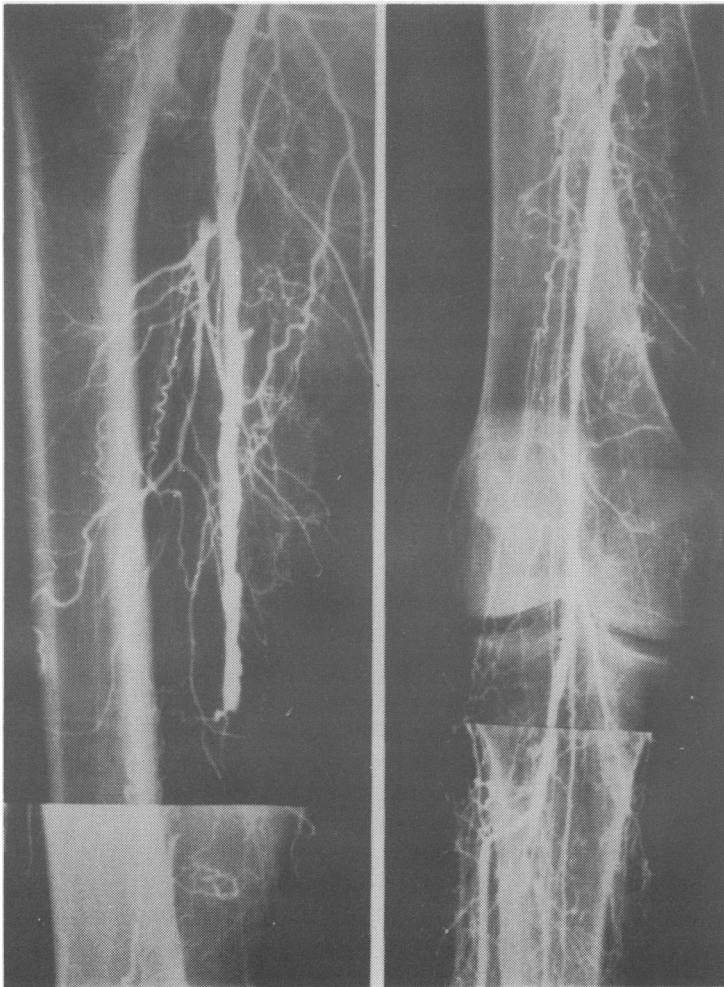


FIG. 4

Left.

Pre-dilatation arteriogram showing complete occlusion of distal superficial femoral artery and popliteal artery. There was no significant run off down the right leg.

Right.

Post-dilatation arteriogram showing recanalisation of distal superficial femoral and popliteal artery and good flow down the anterior tibial artery.

Of the four iliac stenoses, one has been a total success, one who also has a femoro-popliteal block as yet unrelieved, had his pressure gradient decreased and his claudication distance doubled. The third patient in this group had a PTA and a femoro-popliteal bypass done at the same time. The procedure was difficult for the radiologist working in the operating theatre with inadequate x-ray equipment and we would not attempt it again. However, the limb which was in jeopardy was salvaged and the attempt can be counted a success. The fourth case was a failure, being abandoned on account of bleeding.

Of the three femoral or femoro-popliteal cases, two were very successful (Cases 2 and 3). The third case had a block of about 10 cm which was completely re-canalised but it re-occluded two weeks after leaving hospital. The one popliteal stenosis was successful. The technique failed in the case with acute thrombosis of the distal vessels. The brachial artery occlusion was a failure because the guide wire could not be pushed through the block.

COMPLICATIONS

The most common complication is bleeding at the site of arterial puncture. This is not usually serious but in the first case in our series we encountered great difficulty in entering the femoral artery, there being no pulse palpable though there was one identifiable with a Doppler probe. The attempt was eventually abandoned because of severe bleeding, the patient being taken to the operating theatre where a repair of the artery was performed.

The other complications described include peripheral embolism but this rarely gives rise to any sequelae or symptoms. In one case in our series where the popliteal artery was dilated there was transient arterial spasm, possibly due to contrast entering the vessel wall. This was treated with intra-arterial lignocaine and the spasm soon passed. X-rays show a stenosis of the popliteal artery and after dilatation dye in the vessel wall (Fig. 5).

The one complication which might be expected to occur, namely aneurysm formation at the site of dilatation, has not been reported.

DISCUSSION

It was originally thought that the arterial lumen was increased due to compression of the atheromatous material. However, atheroma is essentially incompressible and it appears that splitting of the intima and the atheromatous area occurs which allows the media to be dilated.^{7, 8} Healing of the vessel wall occurs by formation of a new intima and scar tissue. Contrast medium may sometimes be seen sub-intimally in the wall of the vessel after dilatation (Fig. 5).

From our experience this technique has a very important place in the management of peripheral arterial disease. It has, in suitably selected cases, very obvious advantages over traditional surgery. Thus, it is done under local anaesthesia and can therefore be carried out in poor risk patients. There is no large wound either in the belly or thigh. The patients post-operative stay is 48 hours or less (in the USA and Scandinavia PTA is being done on out-patients). Also very important is that it is easily repeatable: according to Dotter it can be done again and again if necessary.

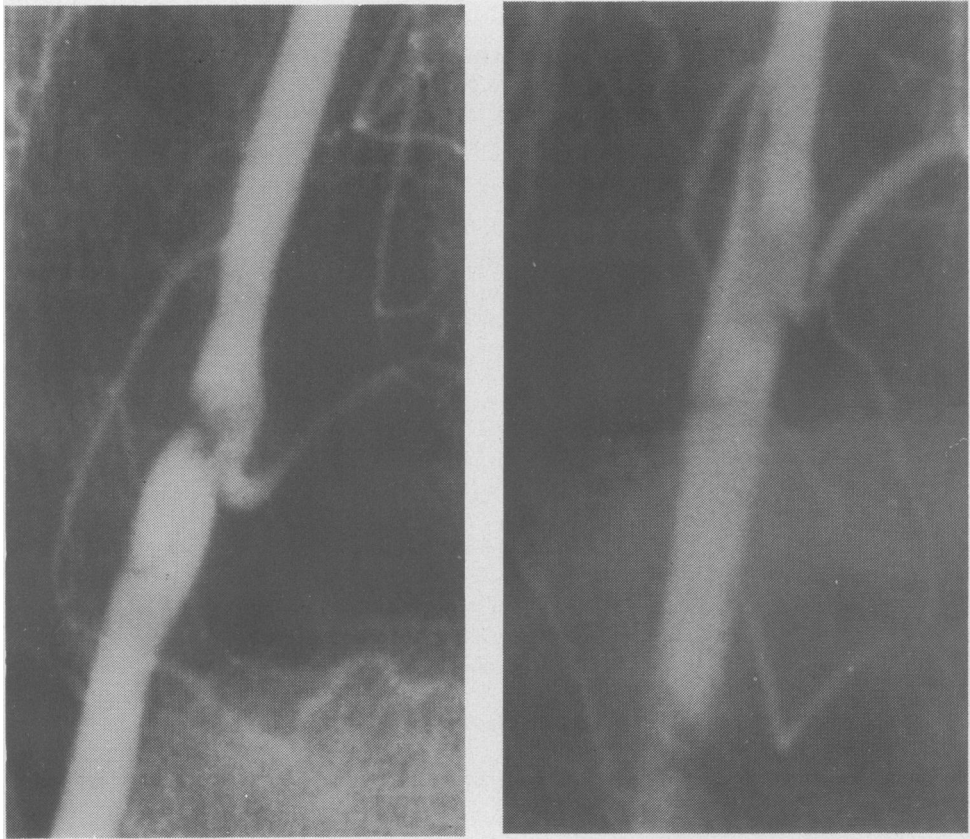

FIG. 5.

Left. *Pre-dilatation arteriogram showing localised stenosis of right popliteal artery.*
Right. *Post-dilatation arteriogram (slightly more enlarged) showing dilatation of stenosis and contrast medium sub-intimally in the vessel wall.*

Exactly how big a place PTA has in the treatment of peripheral arterial disease remains to be seen. One series claims 82 percent of patients as being suitable for PTA.^{8,9} This certainly would not be our experience as the majority of the patients we see have long-segment femoro-popliteal blocks. However, dilatation of the profunda femoris may be of value in attempting limb salvage where there is extensive femoro-popliteal occlusion¹⁰ and there could be significant use made of the technique as a complement to more radical surgery.¹¹ This could be to improve the inflow where there is an iliac block, or more importantly and more commonly to improve the run-off. This dilatation would have to be done at the same time as the surgery, preferably in the operating theatre and would demand better x-ray facilities than we have at present. Finally we would emphasise that this technique should not be attempted without the back-up of a vascular surgical unit as in the event of complications arising open surgery may be required immediately.

SUMMARY

Experience of balloon dilatation of stenosed arteries (percutaneous transluminal angioplasty) is described in a series of ten cases. Results would suggest that this is a valuable technique in short occlusions of the major vessels of the periphery. It may sometimes be a value in the more distal vessels and as an adjunct to surgery but its place in these cases is less certain.

REFERENCES

- 1 Dotter CT, Judkins MP. Transluminal treatment of arteriosclerotic obstruction: description of a new technique and a preliminary report of its application. *Circulation* 1964; **30**: 654-670.
- 2 Gruntzig A, Hopff H. Perkutane rekanalisation chronischer arterieller verschlüsse mit einer neuen Dilatations-Katheter, *Dtsch med Wschr* 1974; **99**: 2502-2505.
- 3 Gruntzig A, Kumpe DA. Techniques and percutaneous transluminal angioplasty with Grantzig balloon catheter. *Amer J Roent* 1979; **132**: 547.
- 4 Van Andel GJ. Transluminal angioplasty: Long term results. *Radiol* 1980; **135**: 607-611.
- 5 Colocpinto RF, Harris-Jones P, Johnston KW. Percutaneous transluminal angioplasty. *Cardio-vascular interventional Radiol* 1980; **3**: 213.
- 6 Gruntzig A. Percutaneous transluminal angioplasty: A two year experience. *Amer J Radiol* 1981; **136**: 216.
- 7 Castaneda-Zuniga WR *et al.* The mechanism of balloon angioplasty. *Radiol* 1980; **135**: 565-571.
- 8 Block PC. Percutaneous transluminal coronary angioplasty. *Amer J Radiol* 1980; **135**: 955-959.
- 9 Motarjeme A, Keifer JW, Zuska AJ. Percutaneous transluminal angioplasty and case selection. *Radiol* 1980; **135**: 573-581.
- 10 Motarjeme A, Keifer JW, Zuska AJ. Percutaneous transluminal angioplasty of the deep femoral artery. *Radiol* 1980; **135**: 613-621.
- 11 Motarjeme A, Keifer JW, Zuska AJ. Percutaneous transluminal angioplasty as a complement to surgery. *Radiol* 1981; **141**: 341-345.