







Carotid Vessel Wall MRI Findings in Acute Cerebral Infarction Caused by Polycythemia Vera: A Case Report

적혈구 증가증으로 인한 급성 뇌경색에서 경동맥 혈관벽 자기공명영상 소견: 증례 보고

Jun Kyeong Park, MD¹ , Eun Ja Lee, MD^{1*} ,
Dong-Eog Kim, MD² , Hyun Jung Lee, MD³ 

Departments of ¹Radiology and ²Neurology, Dongguk University Ilsan Hospital, Goyang, Korea

³Division of Hematology and Medical Oncology, Department of Internal Medicine, Dongguk University Ilsan Hospital, Goyang, Korea

Polycythemia vera (PV) is a rare myeloproliferative disease that causes elevated absolute red blood cell (RBC) mass due to uncontrolled RBC production. Moreover, this condition has been associated with a high risk of ischemic stroke and large vessel stenosis or occlusion, with many studies reporting cerebral infarction in PV patients. Despite these findings, there have been no reports on the vessel wall MRI (VW-MRI) findings of the narrowed vessels in PV-associated ischemic stroke patients. To the best of our knowledge, this is the first report in English regarding the carotid VW-MRI findings of a 30-year-old male diagnosed with PV after being hospitalized due to stroke.

Index terms Polycythemia Vera; Cerebral Infarction; Stenosis; Magnetic Resonance Imaging

INTRODUCTION

Polycythemia vera (PV) is a myeloproliferative disorder that occurs in multipotent hematopoietic progenitor cells that cause the accumulation of morphologically normal red blood cells (RBCs) in the peripheral blood. It may also result in the overproduction of white blood cells and platelets (1). The cumulative incidence of cerebral infarction was 25% in European PV patients (2). It is important to prevent cerebrovascular events in PV patients.

Received June 3, 2021
Revised August 12, 2021
Accepted August 23, 2021





*Corresponding author

Eun Ja Lee, MD
Department of Radiology,
Dongguk University Ilsan Hospital,
27 Dongguk-ro, Ilsandong-gu,
Goyang 10326, Korea.

Tel 82-31-961-7827
Fax 82-31-961-8281
E-mail ejl1048@hanmail.net

This is an Open Access article distributed under the terms of the Creative Commons Attribution Non-Commercial License (<https://creativecommons.org/licenses/by-nc/4.0>) which permits unrestricted non-commercial use, distribution, and reproduction in any medium, provided the original work is properly cited.

ORCID iDs

Jun Kyeong Park 
<https://orcid.org/0000-0003-1965-9422>
Eun Ja Lee 
<https://orcid.org/0000-0002-3083-9339>
Dong-Eog Kim 
<https://orcid.org/0000-0002-9339-6539>
Hyun Jung Lee 
<https://orcid.org/0000-0001-8499-736X>

Several cases of PV-related cerebral infarction with arterial steno-occlusive change have been reported (3-5). New advanced vessel wall MRI (VW-MRI) techniques can allow direct characterization of the VW. To our knowledge, there are still no MRI reports of vascular pathology for these patients. We report for the first time MRI findings of vascular changes in PV patients with acute cerebral infarction through carotid VW-MRI.

CASE REPORT

A 30-year-old male complained of aphasia that started suddenly 7 hours ago. He also experienced dizziness before aphasia appeared. Regular peripheral blood tests were not remarkable except for a hematocrit of 62.2% and hemoglobin of 20.9 g/dL. A peripheral blood smear showed normocytic normochromic RBCs. Serum erythropoietin (EPO) was reduced to 2.2 mIU/mL (normal range: 4.3–29.0 mIU/mL). A bone marrow examination performed due to the increased hematocrit and abnormal range EPO levels revealed three proliferation lineages. There was no Janus Kinase 2 (JAK2) mutation, but a calreticulin mutation was observed. He was confirmed as JAK2-negative PV.

The initial brain MRI showed acute infarction in the frontal cortical and subcortical areas of the left middle cerebral artery (MCA) territory on the diffusion-weighted images (Fig. 1A). Susceptibility-weighted imaging showed no susceptibility vessel signs in the left MCA, so acute thrombus was not considered. Time-of-flight MR angiography revealed moderate to severe stenosis in the insular (M2) segment of the left MCA and the horizontal (A1) segment of the right anterior cerebral artery, and mild stenosis in the sphenoidal (M1) segment of the right MCA (Fig. 1B). In addition, short segmental severe stenosis was seen in the left carotid bulb to the proximal cervical internal carotid artery (ICA) with diffuse luminal narrowing of its distal ICA, and moderate stenosis was seen in the right carotid bulb (Fig. 1C). Electrocardiographic monitoring showed normal sinus rhythm, and transthoracic echocardiography revealed no cardiac thrombi. There were no high-intensity transient signals on transcranial color-coded duplex ultrasonography, reflecting no microembolisms. There was decreased perfusion in the acute infarction area and the left border zone territory on mean transit time of the perfusion CT. Thus, perfusion abnormality was thought to be caused by severe stenosis of the carotid artery.

We performed carotid artery VW-MRI using black-blood three dimensional fast spin-echo to identify the etiology of the stenosis. Intracranial VW-MRI was not performed because it was thought that VW-MRI of the carotid artery in PV patients could reflect the generalized vascular status. The VW-MRI showed circumferential wall thickening of T1 and T2 iso-signal intensity along both cervical ICAs and carotid bulbs, resulting in luminal narrowing of variable degrees, although the image quality was not good due to motion artifacts. Most thickened blood VWs showed no enhancement in the post-contrast imaging, but some showed multifocal minor enhancement in the left carotid bulb and cervical ICA (Fig. 1D, E; left carotid artery is 1D, and right carotid artery is 1E).

Transfemoral cerebral angiography showed > 90% stenosis in the left carotid bulb to the proximal cervical ICA. Angioplasty and carotid stenting were performed on the severely narrowed left proximal ICA area, and the proximal ICA lumen was widened, but there was a re-

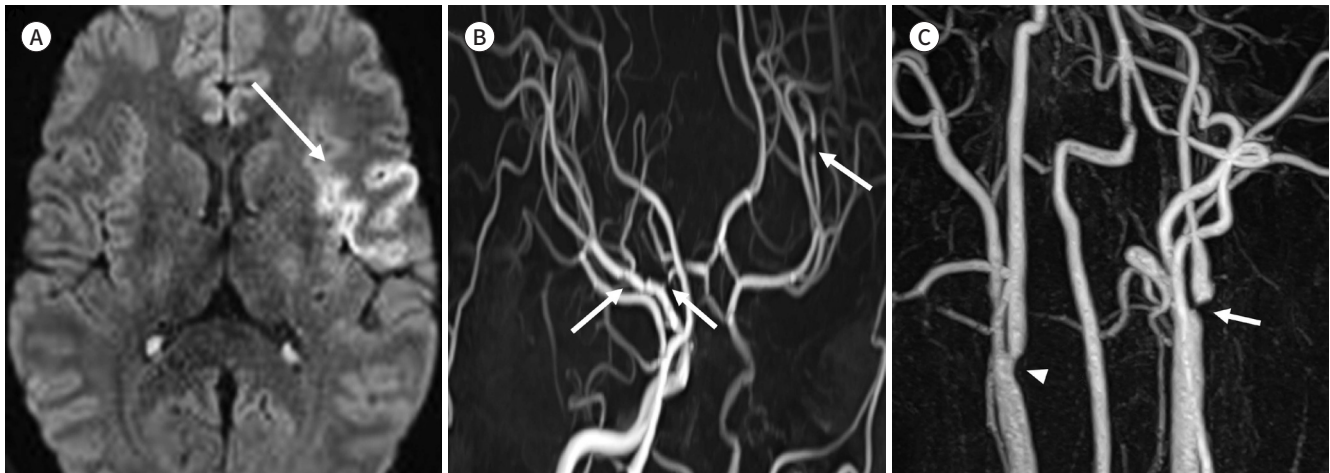
Fig. 1. Carotid vessel wall MRI of acute cerebral infarction caused by polycythemia vera in a 30 year-old male.

A. Diffusion-weighted imaging depicts restricted diffusion in the left frontal lobe (arrow, apparent diffusion coefficient map is not shown), reflecting acute infarction.

B. Intracranial TOF MR angiography demonstrates multifocal stenosis (arrows) in the left M2 segment, right A1 segment, right M1 segment, and diffuse luminal narrowing at the left distal ICA.

C. Neck TOF MR angiography depicts short segmental severe stenosis in the left carotid bulb to the proximal cervical ICA (arrow), diffuse luminal narrowing of the ICA, and moderate stenosis in the right carotid bulb (arrowhead).

ICA = internal carotid artery, TOF = time-of-flight



sidual waist. The patient was treated with phlebotomy, reducing the hematocrit from 62.2% to 48.8%. The patient also started antiplatelet and oral anticoagulant therapies and was discharged home.

This retrospective case report was prepared according to the ethical principles in the Declaration of Helsinki.

DISCUSSION

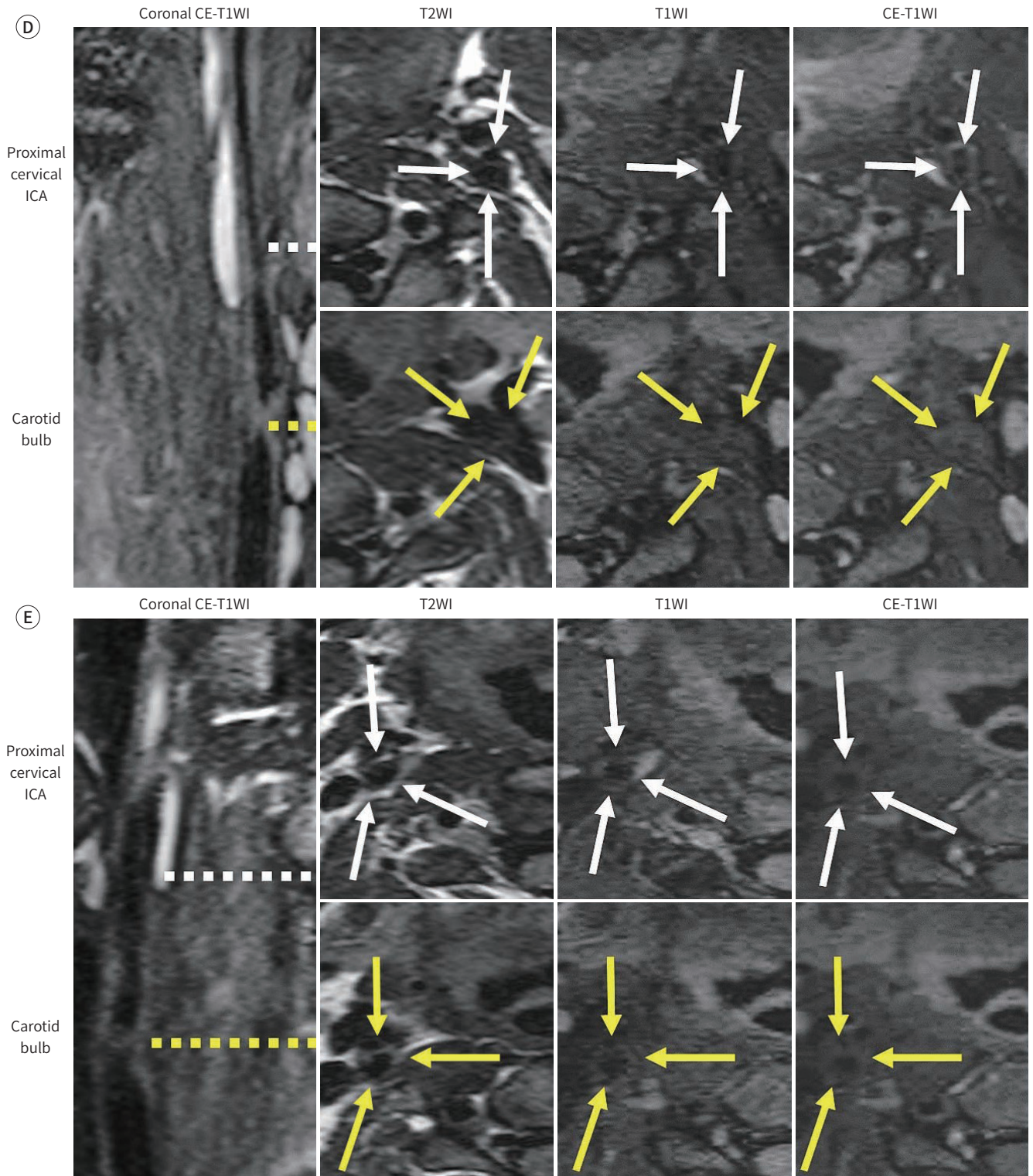
PV is a chronic myeloproliferative disease and is accompanied by a variety of vascular events. An ischemic stroke is common and can occur as the first symptom in up to 15% of PV patients. The incidence of ischemic stroke or transient ischemic attacks is 1.2% per patient-year (1). Various mechanisms underlie ischemic events in PV patients, including thrombosis, hyperviscosity, and reducing blood flow velocity. With these mechanisms, the elevated hematocrit could lead to endothelial dysfunction due to the exfoliation of the protective glycocalyx between the endothelium and the circulating blood. This leads to an inflammatory cascade and vascular stenosis (6). The stenosis or occlusion of the large vessel occurs in approximately 20% of myeloproliferative neoplasms patients, including PV (2). Several cases of steno-occlusive change in PV patients have been reported, but no information exists about the VW findings in a stenotic area using MRI (3-5).

Our case showed that carotid artery VW-MRI revealed circumferential diffuse wall thickening in the stenotic vessels. Post-contrast imaging generally showed no contrast enhancement in the thickened VWs, even with multifocal minor contrast enhancements. These findings differed from those of arterial stenosis due to other causes, including atherosclerotic plaque,

Fig. 1. Carotid VW MRI of acute cerebral infarction caused by polycythemia vera in a 30 year-old male.

D, E. The left carotid VW-MRI (**D**) and the right carotid VW-MRI (**E**) show diffuse circumferential wall thickening along both cervical ICAs and carotid bulbs with iso-signal intensity on both T1- and T2WIs; most thickened VWs show no enhancement on post-contrast images, but some show multifocal minor enhancement in the left carotid bulb and cervical ICA; the dotted lines indicate the level of axial imaging, and the arrows point to each blood vessel (VW-MRI parameters are the following: matrix of 320 x 288, field of view of 160 x 160 mm, and section thickness of 1.0 [reconstructed]).

CE = contrast-enhanced, ICA = internal carotid artery, T1WI = T1 weighted image, T2WI = T2 weighted image, VW = vessel wall



vasculitis, dissection, and vasospasm. In general, if the VW-MR image shows eccentric arterial wall thickening, this is likely to be atherosclerotic plaque. However, if the VW-MR image shows smooth and homogeneous concentric arterial wall thickening and contrast enhancement, it can be considered vasculitis. Vasospasm may show concentric wall thickening without contrast enhancement, but the stenosis increases disproportionately more than the wall thickening. Typical findings of arterial dissection include a dissection flap, eccentric intramural T1 shortening indicating intramural hematoma, and abnormal enhancement (7).

Some studies have found intimal proliferation caused by intimal exfoliation in the narrowed coronary artery (8, 9). These features can explain our VW-MRI results. Diffuse intimal proliferation is likely to result from circumferential wall thickening without contrast enhancement. Minor contrast enhancement in the lesion is thought to be associated with intimal exfoliation. Future pathologic correlation is needed to fully understand the pathophysiology of macrovascular stenosis in PV patients.

The recommended treatment for patients with PV includes careful assessment of the cardiovascular risk factors and the use of low-dose aspirin. Erythrocytosis should be controlled by phlebotomy to maintain a hematocrit below 45%. High-risk PV patients for thrombotic events with previous thrombotic events and/or age > 60 years or JAK2 mutations require pharmacological treatment to decrease their RBCs. Hydroxyurea is the most commonly used cytoreductive drug, and JAK inhibitors (ruxolitinib and fedratinib) may be used in patients refractory to first-line therapy (10).

In conclusion, this case revealed that the stenotic vessels of the PV patient showed circumferential wall thickening without enhancement by carotid VW-MRI. Therefore, VW-MRI helps to understand the etiology of stenotic vessels in PV patients with ischemic stroke.

Author Contributions

Conceptualization, P.J.K., L.E.J.; data curation, P.J.K., L.E.J.; formal analysis, P.J.K., L.E.J.; investigation, all authors; methodology, P.J.K., L.E.J.; project administration, P.J.K., L.E.J.; resources, all authors; supervision, L.E.J.; validation, P.J.K., L.E.J.; visualization, P.J.K., L.E.J.; writing—original draft, P.J.K.; and writing—review & editing, L.E.J.

Conflicts of Interest

The authors have no potential conflicts of interest to disclose.

Funding

None

REFERENCES

1. No authors listed. Polycythemia vera: the natural history of 1213 patients followed for 20 years. Gruppo Italiano Studio Policitemia. *Ann Intern Med* 1995;123:656-664
2. Nagai K, Shimoyama T, Yamaguchi H, Sakamoto Y, Suda S, Wakita S, et al. Clinical characteristics and brain MRI findings in myeloproliferative neoplasms. *J Neurol Sci* 2020;416:116990
3. Hua le H, Dodd RL, Schwartz NE. Concurrent stenooclusive disease of intracranial and extracranial arteries in a patient with polycythemia vera. *Case Rep Med* 2012;2012:151767
4. Nezu T, Aoki S, Ochi K, Sugihara S, Takahashi T, Hosomi N, et al. A case of recurrent ischemic stroke involving subacute, progressive intracranial cerebral arterial sclerosis prior to diagnosis with JAK2-mutated polycythemia vera. *J Stroke Cerebrovasc Dis* 2015;24:e4-e6
5. Crespo AM, Abaira L, Guanyabens N, Millán M, Munuera J, Dávalos A, et al. Recurrent stroke with rapid de-

- velopment of intracranial stenoses in polycythemia vera. *J Stroke Cerebrovasc Dis* 2016;25:e41-e43
6. Richter V, Savery MD, Gassmann M, Baum O, Damiano ER, Pries AR. Excessive erythrocytosis compromises the blood-endothelium interface in erythropoietin-overexpressing mice. *J Physiol* 2011;589:5181-5192
 7. Mandell DM, Mossa-Basha M, Qiao Y, Hess CP, Hui F, Matouk C, et al. Intracranial vessel wall MRI: principles and expert consensus recommendations of the American Society of Neuroradiology. *AJNR Am J Neuroradiol* 2017;38:218-229
 8. Hermanns B, Handt S, Kindler J, Füzesi L. Coronary vasculopathy in polycythemia vera. *Pathol Oncol Res* 1998;4:37-39
 9. Nishiguchi T, Tanaka A, Yamano T, Kubo T, Akasaka T. Intimal exfoliation following abnormal circular proliferation as a cause for acute coronary syndrome in a patient with polycythemia vera. *Int J Cardiol* 2015;199:239-240
 10. Ferro JM, Infante J. Cerebrovascular manifestations in hematological diseases: an update. *J Neurol* 2021;268:3480-3492

적혈구 증가증으로 인한 급성 뇌경색에서 경동맥 혈관벽 자기공명영상 소견: 증례 보고

박준경¹ · 이은자^{1*} · 김동역² · 이현정³

진성적혈구증가증은 드문 골수 증식성 질환이며 제어되지 않은 적혈구 생산으로 인해 절대 적혈구 질량이 증가한다. 진성적혈구증가증은 큰 혈관의 협착 또는 폐색과 함께 허혈성 뇌졸중의 위험이 높다. 진성적혈구증가증 환자에서 뇌경색에 대한 많은 증례 보고가 있다. 그러나 합병증으로 뇌졸중이 발생한 진성적혈구증가증 환자의 좁아진 혈관에서 혈관벽 자기공명영상 소견은 보고되지 않았다. 저자들은 뇌졸중으로 인해 입원한 후 PV로 진단된 30세 남성의 경동맥 VW-MRI 소견에 관해 보고하고자 하며, 이는 우리가 아는 한 영어로 된 첫 번째 보고이다.

동국대학교 의과대학 ¹영상의학과, ²신경과, ³혈액종양내과