

Technical innovations

Open Access

## Cervicopectoral flap in head and neck cancer surgery

Eray Copcu\*<sup>1</sup>, Kubilay Metin<sup>2</sup>, Alper Aktas<sup>3</sup>, Nazan S Sivrioglu<sup>1</sup> and Yücel Öztan<sup>3</sup>

Address: <sup>1</sup>Department of Plastic and Reconstructive Surgery, Medical Faculty, Adnan Menderes, University, Aydin, Turkey, <sup>2</sup>Department of E.N.T, Medical Faculty, Adnan Menderes University, Aydin, Turkey and <sup>3</sup>Department of Plastic and Reconstructive Surgery, Ataturk Training Hospital, Izmir, Turkey

Email: Eray Copcu\* - copcu@lycos.com; Kubilay Metin - metinkk@hotmail.com; Alper Aktas - aaktas@msn.com; Nazan S Sivrioglu - nsivrioglu@adu.edu.tr; Yücel Öztan - yuceloztan@yahoo.com

\* Corresponding author

Published: 22 December 2003

Received: 11 July 2003

World Journal of Surgical Oncology 2003, 1:29

Accepted: 22 December 2003

This article is available from: <http://www.wjso.com/content/1/1/29>

© 2003 Copcu et al; licensee BioMed Central Ltd. This is an Open Access article: verbatim copying and redistribution of this article are permitted in all media for any purpose, provided this notice is preserved along with the article's original URL.

### Abstract

**Background:** Reconstruction of the head and neck after adequate resection of primary tumor and neck dissection is a challenge. It should be performed at one sitting in advanced tumors. Defects caused by the resection should be closed with flaps which match in color, texture and hair bearing characteristics with the face. Cervicopectoral flap is a one such flap from chest and neck skin mainly used to cover the cheek defects.

**Methods:** This study included twelve patients presenting with cancer of the head and neck to Izmir Ataturk Training Hospital and Adnan Menderes University Hospital. Tumor resection and neck dissection was performed in one session by the same surgeon. A single incision was made and a medially based cervicopectoral fascio-cutaneous flap was used for surgical exposure in neck dissection and for closure of defects after tumor resection.

**Results:** There was no major complication. Two flaps had partial superficial epidermolysis at the suture line. Good aesthetic and functional results were achieved.

**Conclusion:** The cervicopectoral flap is an excellent alternative for the reconstruction of head and neck. Harvesting and application of the flap is rapid and safe. Only a single incision is sufficient for dissection and flap elevation. This flap achieves perfect surgical exposure, makes neck dissection easy and allows one to perform both tumor resection and neck dissection in one session.

### Introduction

At times, management of head and neck cancer is difficult. The greatest difficulty is in reconstruction of the defect caused by tumor resection. Generally, head and neck cancers, which invade the skin, require extensive resection. The unique character of the facial skin and limited availability of local matching tissue poses difficulty in facial

reconstruction. The secret of an aesthetic reconstruction lies in visualization of what is normal and determination of what is missing from anatomic and aesthetic point of view [1]. Good functional and aesthetic results can be achieved with thin flaps which match in color, texture, skin quality and hair bearing characteristics with the face.

When aesthetic appearance becomes important, local and regional tissues are required for resurfacing the cheek [2].

Neck dissection is one of the most commonly performed procedures in the management of nodal metastasis in head and neck cancers. Since its original description by George Crile in 1906, numerous modifications in the extent and the technique of the operation have been described [3-6]. In addition to the perceived advantages in terms of the ease of access and adequacy of exposure, other factors like primary wound healing, cosmesis, and functional results are generally used to compare one technique with another [7]. As with any other procedures, surgical exposure is as important as the easiness of the technique and low complication rate in neck dissection.

This paper describes our experience of single incision technique of cervicopectoral flap in patients with head and neck cancer especially in the middle third area of the face for neck dissection as well as reconstruction in a short operative period.

## Methods

A retrospective analysis of reconstruction of the head and neck defects using cervicopectoral fascio-cutaneous rotation advancement flap was performed in 12 patients, aged 52 to 69, and treated at Izmir Atatürk Training Hospital and Adnan Menderes University Hospital between August 1994 and January 2002. All patients were staged using TNM classifications [8-10]. A single incision was made and tumor excision, neck dissection and closure of the defects were carried out by the same surgeon in one session. The procedures were carried out under general anesthesia in all patients. Data about the patients and the operations were recorded. Time from the first incision to the end of suturing was considered as operative period. Excision of the tumors caused the full thickness skin defects in all cases. Mucosal advancement flaps were used for the mucosal defects in oral commissure. Skin defects were closed with cervicopectoral flap. Defects sizes varied between 40 mm × 40 mm to 150 mm × 100 mm. Lymph nodes were clinically present in all cases except two cases of malignant melanoma. Prophylactic neck dissection was performed in these two patients. Elective neck dissections were performed in patients with palpable lymph nodes. All parotid gland tumors had skin invasion. Facial nerve was preserved during parotidectomy. Preoperative cervical ultrasonography, computed tomography and a tissue biopsy was performed in all patients. Tumors more than 4 cm were considered as "advanced tumor". Radiotherapy was given to the patients who had advanced tumor or positive surgical excision margin.

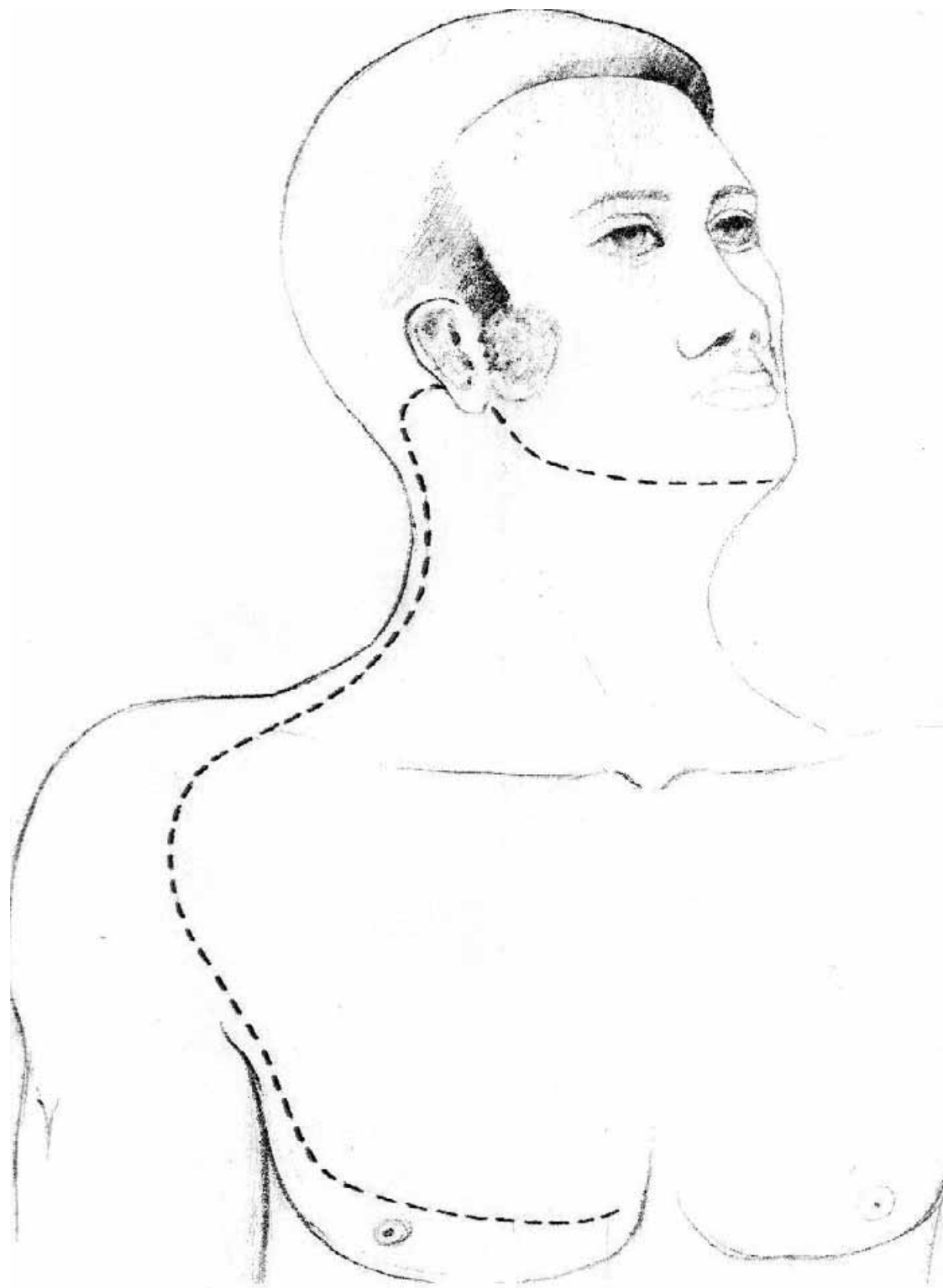
## Surgical Technique

In all the patients the entire tumor was resected *en block* with a margin of one cm. The flap was marked preoperatively (figure 1 and 2) so that the inferior border of the excision of the tumor would be the upper border of the flap. The outline of the flap was extended posteriorly around the earlobe towards the hairline behind the ear and inferiorly 2 cm behind the anterior edge of the trapezius muscle. The incision was extended across the clavicle parallel to the lateral border of the pectoralis muscle. The inferior border of the flap was two cm above the nipple and parallel to the clavicle. The flap was elevated with the deep fascia of the pectoralis muscle, and dissection was performed inferiomedially, the flap was raised till the sternal border (figure 3). A horizontal incision was placed for more mobilization in upper part of the flap if required. Elevation above the clavicle was performed in a subplatysmal plane as far as the lower border of the resection. Excellent visualization was achieved and neck dissection was performed quite easily (figure 3). After neck dissection was completed, the flap was rotated to the defect in a tension-free manner and was sutured with 4-0 or 5-0 nylon. Dog-ear if seen was trimmed. The head was immobilized in the midline position for three days. The drainage tubes were removed on second postoperative day. Third generation cephalosporin were used as prophylactic antibiotics in all patients. Sutures were removed seven days after the operation. Donor area was closed primarily without tension and no tissue was needed to cover it.

## Results

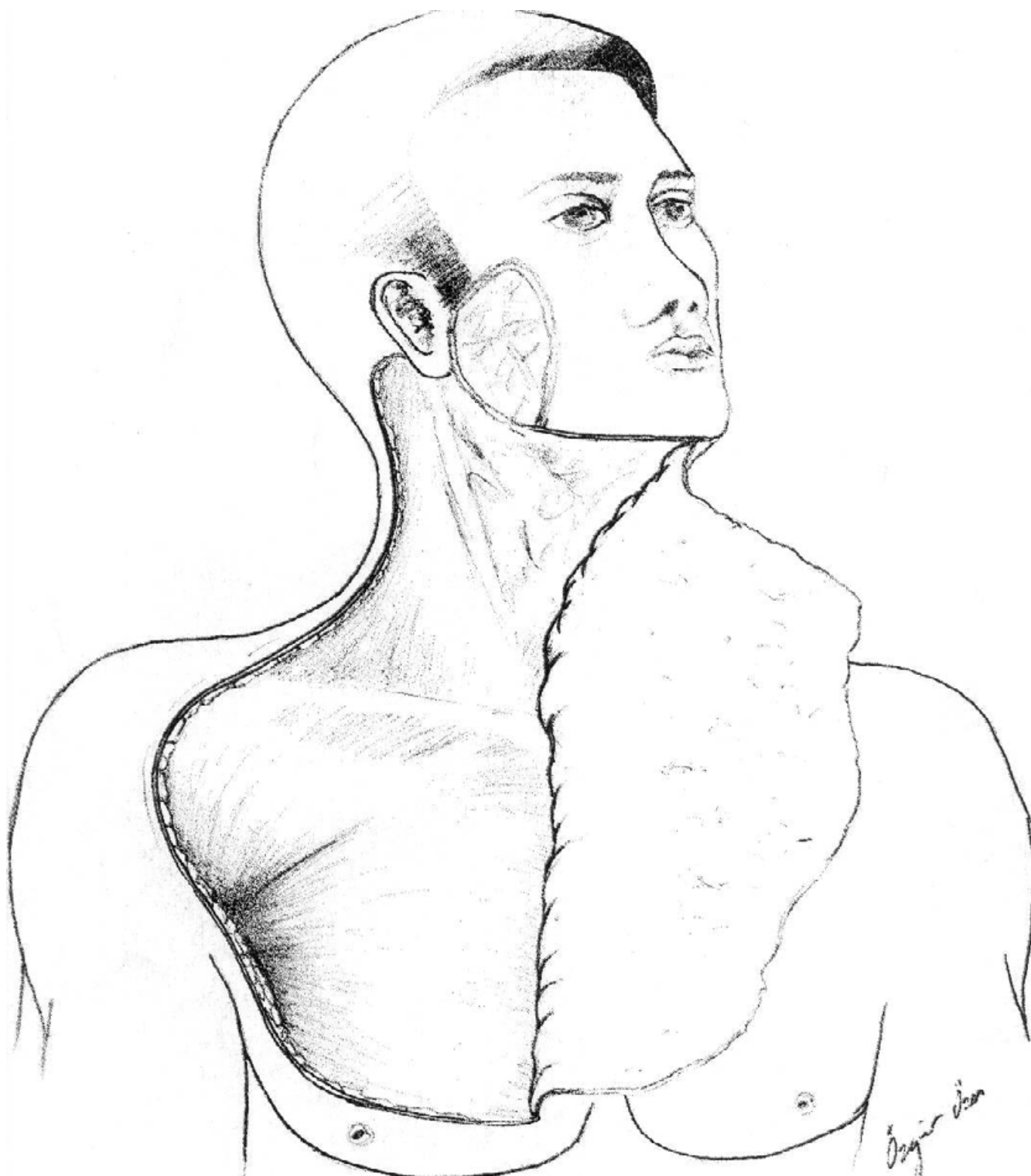
General characteristics of the patients, site of the lesion, the procedures performed and the obtained results are summarized in table 1. Male to female ratio was 2:1 and the mean age of the patients was 59 years. Tumor size ranged from 20 × 15 mm to 60 × 50 mm with a mean of 42 × 32 mm. According to histological type and localization of the tumor, TNM classification of the American Joint Committee on Cancer (AJCC) was used the staging of the patients [8-10]. Ten patients were in stage III, and 2 in stage II. Intra-operative blood transfusion was used in only one patient. Hospitalized ranged from 5 days to a maximum of 11 days with average hospital stay of 6.7 days. On histopathological examinations of the specimen, 8 patients had squamous carcinoma, 2 each had malignant melanoma and mucoepidermoid carcinoma. Nodes were metastatic in 8 patients.

There were no major complications like flap loss, total or partial necrosis, wound dehiscence or infection. One patient had superficial epidermolysis at the lateral border of the flap which healed spontaneously in two weeks. One patient with SCC of the left oral commissure had poor oral incompetence. He refused to undergo a second surgery for correction.



**Figure 1**

Outline of the flaps: Incision was extended posteriorly around the earlobe toward the hairline, behind the ear and then downward 2 cm behind the anterior border of the trapezius muscle. It then transverses the clavicle and deltopectoral groove running parallel to lateral border of pectoralis muscle. The inferior border of the flap runs medially parallel to the clavicle at the fourth intercostals space.



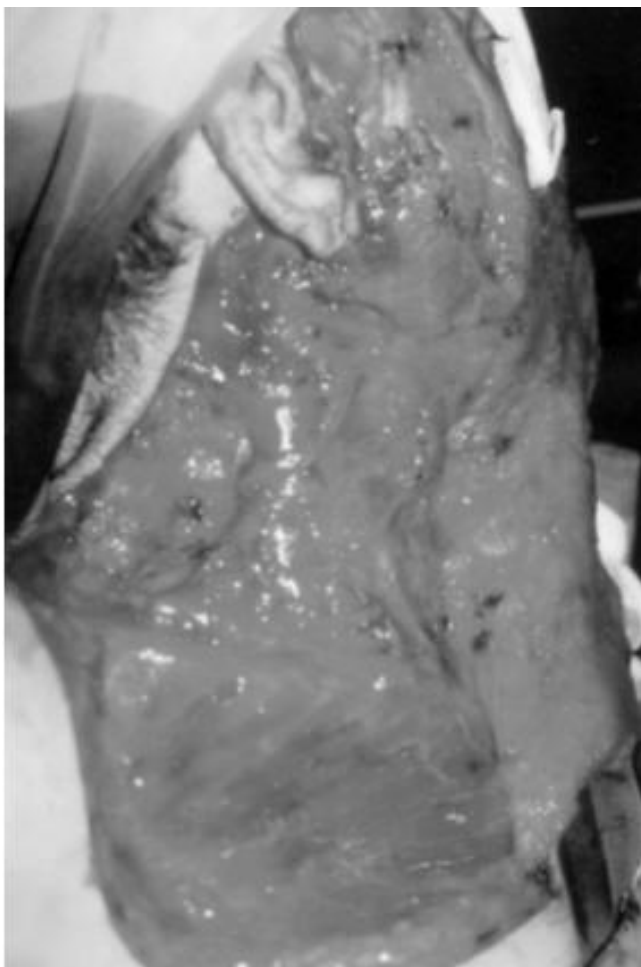
**Figure 2**

Elevation of the flap: The flap is elevated deep to the fascia of the pectoralis major muscles, with dissection proceeding infero-medially. Elevation above the clavicle is in a subplatysmal plane, including the superficial layer of the deep cervical fascia. Once elevation has been completed, the flap is rotated in a superior and medial direction to cover the defect in a tension-free manner.

**Table 1: Details of the patients and summary results of surgery.**

Case No:	Age:	Sex	Location	Tumor size (MM)	Operation (*)	Operative time	Result
1	55	M	parotid	35 × 30	MND type III	4 hr 15 min	Good, no complication
2	68	M	Oral commissure	40 × 30	RND	4 hr 30 min	poor oral incompetence
3	52	F	Buccal	20 × 15	RND	3 hr 45 min	Good, no complication
4	48	F	Buccal	50 × 20	RND	3 hr 30 min	Good, no complication
5	61	M	Skin parotid region	45 × 30	RND	3 hr 45 min	Good, no complication
6	58	F	Skin parotid region	35 × 30	MND type III	3 hr 30 min	Good, no complication
7	62	M	Oral commissure	45 × 45	MND type III	3 hr 15 min	Good, no complication
8	69	F	Skin parotid region	50 × 20	RND	4 hrs	Good, no complication
9	52	M	Buccal area	45 × 40	RND + c/l MND type III	4 hr 45 min	superficial epidermolysis
10	55	M	Skin parotid region	60 × 50	MND type III	3 hr 45 min	Good, no complication
11	59	M	Parotid region	40 × 30	RND	4 hrs	Good, no complication
12	68	M	Parotid region	40 × 40	RND	3 hr 30 min	Good, no complication

(\*) MND: Modified neck dissection, RND: Radical neck dissection; hr-hour; min-minute; c/l-*contra lateral*



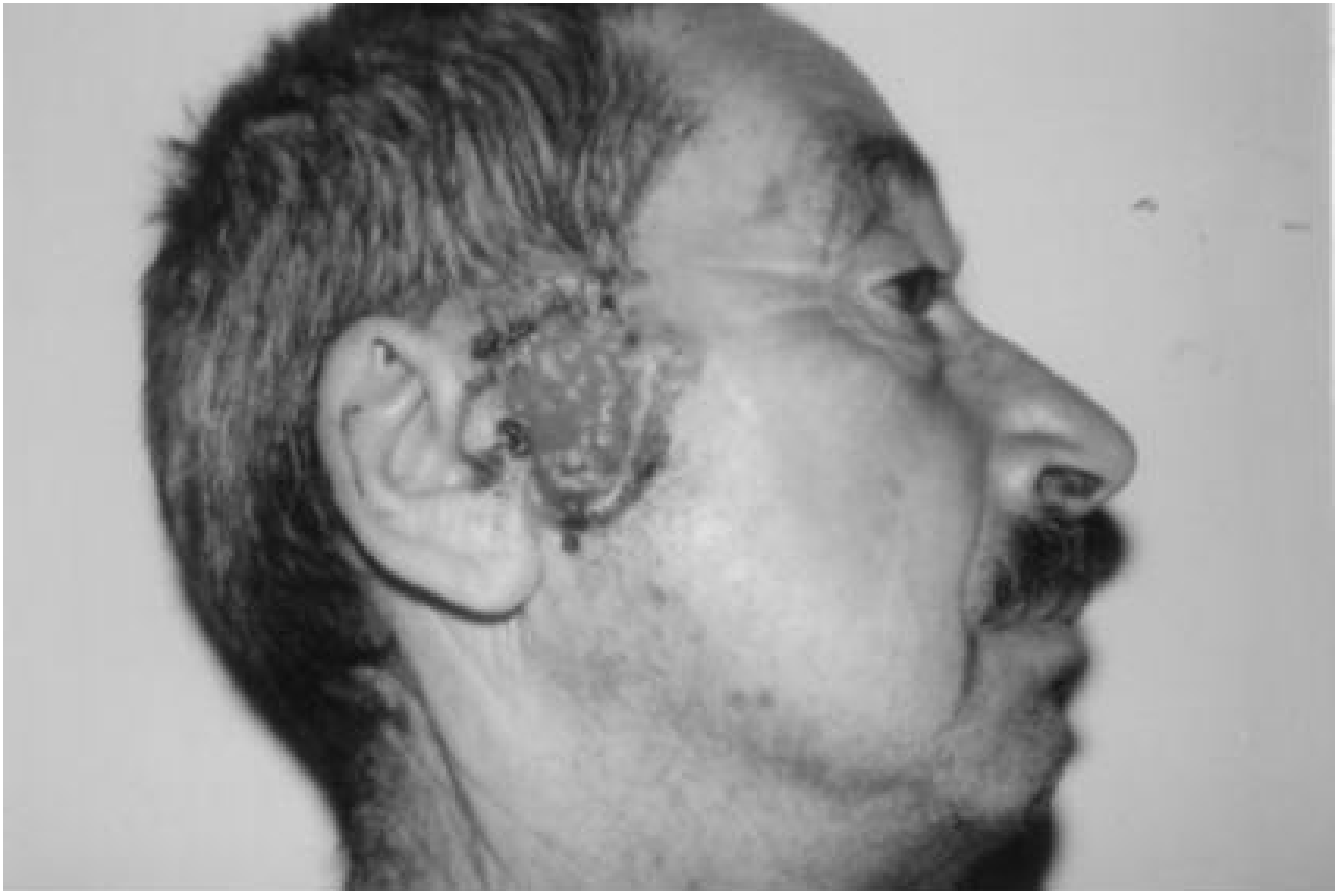**Figure 3**  
Surgical exposure after flap elevation for neck dissections

The complication rate was 16.6%. The mean operation time was 3 hours and 50 minutes (minimum 3 hours 15 minutes, maximum 4 hours 20 minutes). Follow-up ranged from 10 to 24 months, with a mean of 18 months. Good aesthetic and functional results were achieved at six months postoperatively (Figures 4, 5). One patient with positive surgical margin and five patients with advanced (T3) head and neck cancer were treated with postoperative radiotherapy (50 to 60 Gy in 15 to 20 fractions) 1 month after surgery. There was no complication after radiotherapy especially in flap area. None of the patients had any complains about their scars, hence we conclude that the scars were aesthetically acceptable (Figure 6).

### Discussion

Management of the advanced head and neck cancers are often complicated by challenging anatomy, complex reconstructions and long surgical procedures [11]. Reconstruction of the head and neck defects may be achieved in a variety of ways. These include skin grafts, smaller local flaps such as limberg [12], bi-lobed flap [13], tri-lobed flap [14] and myocutaneous or faciocutaneous flaps such as pectoralis major flap [15,16], platysma flap [17], sternocleidomastoid flap [18], deltopectoral flap [19], cervicothoracic flap [20], posterior auricular flap [21], trapezius island flap [22], latissimus dorsi flap [23], or free vascularized flaps [24,25]. Although there are a number of alternatives in reconstruction of the face, only a few have the same texture, color, and hair bearing characteristics as the face. As in other clinical situations, availability of a number of alternatives means that there is not one single perfect choice.

Becker first described the cervicopectoral fascio-cutaneous flap for reconstruction of large soft tissue defects in the cheek [26]. This flap is supplied by the anterior thoracic

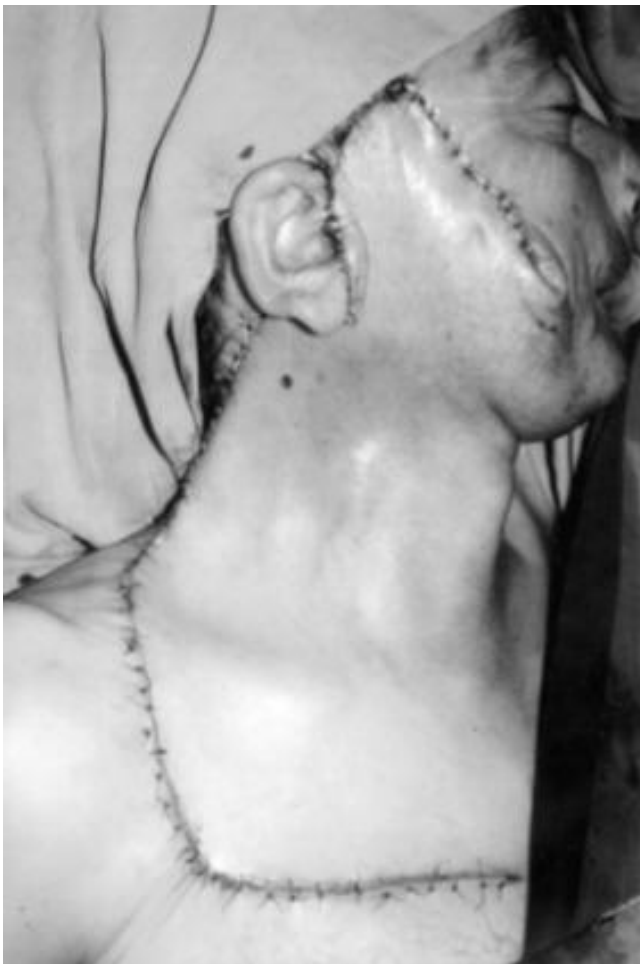

**Figure 4**  
Skin tumor (squamous cell carcinoma) in right parotid region, preoperative view.

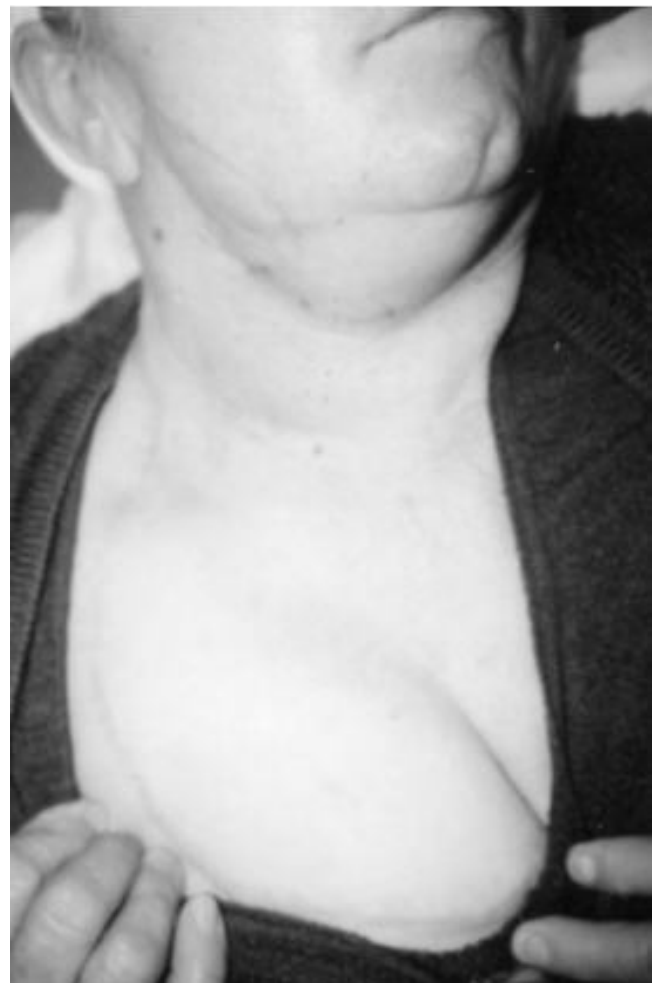perforators of the internal mammary artery [27]. It is reliable for reconstruction of defects of the lower cheek below the line connecting tragus and oral commissure [28]. The color, skin texture and hair bearing characteristics of the flap make it an aesthetically ideal replacement for the cheek tissue [26-32]. Many authors agree that it is an excellent procedure [27-33] when compared to other techniques.

*Pectoralis major* musculocutaneous flap is one of the most frequently used flap in management of head and neck cancer. It has two major disadvantages. One, it is extremely bulky and second it does not match in color with the recipient area. Cervicopectoral flap is usually of similar thickness to the defect. The vascularity of platysma flap is not reliable [28], and sternomastoid flap can not be used in patients with neck node metastasis as this may violate oncological principals. Free vascularized flaps have been popularized recently. However, they require technical expertise and needs more time to perform [23].

Application of the cervicopectoral flap is easy and rapid [32]. In patients with head and neck cancer, oncologic principles are not violated with this flap because the excision margins of the primary site are not compromised for fear of creating too large a surgical defect. The surgeon will have plentiful tissue to perform the reconstruction. Also, the plane of elevation of the flap in the neck is identical to that used in radical neck dissection operations [32]. An ideal neck incision for radical neck dissection requires sufficient exposure of the operation field, viability of the elevated skin flap, protection of the carotid artery, and acceptable postoperative cosmetic results [33,34]. Cervicopectoral flap has all these features and it provides an excellent surgical exposure as seen in Figure 3. Head and neck patients may frequently have a history of tobacco and/or alcohol use and they may have significant coexisting pulmonary disease [11]. Shorter operative time alone cannot be accepted as an advantage, but it should be kept in mind that a longer operative period may cause more morbidity under general anesthesia in select cases.



**Figure 5**  
Tumor excision, radical neck dissection and cervicopectoral flap application for the defect after resection was performed. (Early postoperative view).



**Figure 6**  
Tumor excision, radical neck dissection and cervicopectoral flap application for the defect after resection was performed in patient with malignant melanoma of buccal area. Late postoperative view (Two years after operation).

The elderly too are at greater risk for perioperative complications and mortality due to an increased prevalence of age-related concomitant diseases, and decline in organ functioning over time [35]. Haljamae has shown that duration of anesthesia influences the incidence of postoperative complications but suggests that this incidence might reflect the extent of the surgery performed instead of some unique characteristics of a prolonged exposure to anesthetics [36]. Farwell *et al* [11] and Singh *et al* [37] concluded that duration of the operation is a powerful predictor of adverse events. For the procedures lasting less than 8 hours, the risk of complications were lesser than prolonged operations [8,36,37].

There is no specific contraindication for the cervicopectoral flap. This flap is safe, well perfused and easy to harvest.

It can be performed in most of the patients with head and neck cancer. Scar on donor site, previously irradiated neck and chest skin, advanced age and heavy smoking may limit the use of cervicopectoral flap. Surgery or radiotherapy alone may suffice for patients with small T1-T2 lesions, no regional lymph node or nodes < 2 cm, and no distant metastases. Most patients with stage III or IV tumors are candidates for treatment by a combined modality [38]. In our series post-operative radiotherapy was tolerated well by the cervicopectoral fasciocutaneous flap.

Local flaps are always advantageous compared with microsurgical reconstruction techniques or distant flaps as

they are simple and fast to harvest. Cervicopectoral flap may be a good alternative for the surgeons in the treatment of patients with head and neck cancer where comorbid conditions preclude lengthy operations since a single incision is adequate for excision, neck dissection and reconstruction of the defect.

## References

- Menick FJ: **Facial reconstruction with local and distant tissue: The interface of aesthetic and reconstructive surgery.** *Plast Reconstr Surg* 1998, **102**:1424-1433.
- Menick FJ: **Reconstruction of the cheek.** *Plast Reconstr Surg* 2001, **108**:496-504.
- Crile G: **Excision of cancer of the head and neck, with special reference to the plan of dissection based on 132 patients.** *JAMA* 1906, **47**:1780-1784.
- Martin H, Del Valle B, Ehrlich H, Cahan WG: **Neck dissection.** *Cancer* 1951, **4**:441-445.
- Grandon EL, Brintall ES: **Utility neck incision.** *Arch Otolaryngol* 1960, **72**:743-747.
- Ariyan S: **Radical neck dissection.** *Surg Clin North Am* 1986, **66**:133-148.
- Yii NH, Patel SG, Williamson P, Breach NM: **Use of apron flap incision for neck dissection.** *Plast Reconstr Surg* 1999, **103**:1655-1660.
- American Joint Committee on Cancer: **Lip and oral cavity.** In: *AJCC Cancer Staging Manual* 5th edition. Philadelphia, Lippincott-Raven Publishers; 1997:24-30.
- American Joint Committee on Cancer: **Carcinoma of the skin (excluding eyelid, vulva, and penis).** In: *AJCC Cancer Staging Manual* 5th edition. Philadelphia, Pa: Lippincott-Raven Publishers; 1997:157-161.
- Rogers GS, Voseburg E, Wazer DE: **New approaches to treating advanced melanoma: adjuvant treatment of high-risk primary melanoma and boron neutron capture therapy.** *Semin Cutan Med Surg* 1997, **16**:165-173.
- Farwell GD, Reilly DF, Weymuller EA, Greenberg DL, Staiger TO, Futran NA: **Predictors of perioperative complications in head and neck patients.** *Arch Otolaryngol Head Neck Surg* 2002, **148**:505-511.
- Quaba A, Sommerlad B: **A square peg into a round hole: a modified rhomboid flap and its clinical application.** *Br J Plast Surg* 1987, **40**:163-165.
- Yenidunya MO: **The bi-lobed flap design on expanded skin of the face and neck region.** *Plast Reconstr Surg* 1998, **101**:1741-1742.
- Weerda H: **Special techniques in the reconstruction of cheek and lip defects.** *Laryngol Rhinol Otol* 1980, **59**:630-640.
- Liu R, Gullane P, Brown D, Irish J: **Pectoralis major myocutaneous pedicled flap in head and neck reconstruction: retrospective review of indications and results in 244 consecutive cases at the Toronto General Hospital.** *J Otolaryngol* 2001, **30**:34-40.
- Kerawala CJ, Sun J, Zhang ZY, Guoyu Z: **The pectoralis major myocutaneous flap: Is the subclavicular route safe?** *Head Neck* 2001, **23**:879-884.
- Ariyan S: **The transverse platysma myocutaneous flap for head and neck reconstruction.** *Plast Reconstr Surg* 1997, **99**:340-347.
- Alvi A, Stegnjajic A: **Sternocleidomastoid myofascial flap for head and neck reconstruction.** *Head Neck* 1994, **16**:326-330.
- Kingdom TT, Singer MI: **Enhanced reliability and renewed applications of the deltopectoral flap in head and neck reconstruction.** *Laryngoscope* 1996, **106**:1230-1233.
- Blevins PK, Luce EA: **Limitations of the cervicohumeral flap in head and neck reconstruction.** *Plast Reconstr Surg* 1980, **66**:220-224.
- Leonard AG, Kolhe PS: **The posterior auricular flap: intra-oral reconstruction.** *Br J Plast Surg* 1987, **40**:570-581.
- Bertotti JA: **Trapezius-musculocutaneous island flap in the repair of major head and neck cancer.** *Plast Reconstr Surg* 1980, **65**:16-21.
- Bhaya MH, Har-el G: **Resident training in head and neck flap reconstruction in U.S. academic otolaryngology programs.** *J Laryngol Otol* 2001, **115**:119-121.
- Bogle M, Kelly P, Shenaq J, Friedman J, Evans GR: **The role of soft tissue reconstruction after melanoma resection in the head and neck.** *Head Neck* 2001, **23**:8-15.
- Disa JJ, Pusic AL, Hidalgo DH, Cordeiro PG: **Simplifying microvascular head and neck reconstruction: a rational approach to donor site selection.** *Ann Plast Surg* 2001, **47**:385-389.
- Becker DW Jr: **A cervicopectoral rotation flap for cheek coverage.** *Plast Reconstr Surg* 1978, **61**:868-870.
- Becker DW: **Cervicopectoral skin flap to the cheek.** In *Encyclopedia of flaps* Edited by: Strauch B, Vasconez LO, Hall-Findlay EJ. Philadelphia: Lippincott-Raven; 1998:412-422.
- Shestak KC, Roth AG, Jones NF, Myers EN: **The cervicopectoral rotation flap—a valuable technique for facial reconstruction.** *Br J Plast Surg* 1993, **46**:375-377.
- Dyer PV, Irvine GH: **Cervicopectoral rotation flap.** *Br J Plast Surg* 1994, **47**:68-69.
- Garrett WS Jr, Giblin TR, Hoffman GW: **Closure of skin defects of the face and neck by rotation and advancement of cervicopectoral flaps.** *Plast Reconstr Surg* 1966, **38**:342-346.
- Lazaridis N, Tilaveridis I, Dalambiras S, Iordanidis S: **The fasciocutaneous cervicopectoral rotation flap for lower cheek reconstruction: report of three cases.** *J Oral Maxillofac Surg* 1997, **55**:1166-1171.
- Soler-Presas F, Cuesta-Gil M, Borja-Morant A, Concejo-Cutoli C, Acero-Sanz J, Navarro-Vila C: **Midface soft tissue reconstruction with the facio-cervico-pectoral flap.** *J Craniomaxillofac Surg* 1997, **25**:39-45.
- Loré JM Jr: **An atlas of head and neck surgery.** Philadelphia: W.B. Saunders 1988:662-665.
- Shaw HJ: **A modification of the MacFee incisions for neck dissection.** *J Laryngol Otol* 1988, **102**:1124-1166.
- Zambricki CS: **Special anesthesia considerations for the elderly plastic surgery patient.** *Plast Surg Nurs* 2000, **20**:157-160.
- Haljamae H: **Anesthetic risk factors.** *Acta Chir Scand* 1989, **550**:11-19.
- Singh B, Cordiero PG, Santamaria E, Shaha AR, Pfister DG, Shah JP: **Factors associated with complications in microvascular reconstruction of head and neck defects.** *Plast Reconstr Surg* 1999, **103**:403-411.
- Harris LB, Sessions RB, Hong WK, Eds: *Head and Neck Cancer: A Multidisciplinary Approach* Philadelphia: Lippincott-Raven; 1998.

Publish with **BioMed Central** and every scientist can read your work free of charge

"BioMed Central will be the most significant development for disseminating the results of biomedical research in our lifetime."

Sir Paul Nurse, Cancer Research UK

Your research papers will be:

- available free of charge to the entire biomedical community
- peer reviewed and published immediately upon acceptance
- cited in PubMed and archived on PubMed Central
- yours — you keep the copyright

Submit your manuscript here:  
[http://www.biomedcentral.com/info/publishing\\_adv.asp](http://www.biomedcentral.com/info/publishing_adv.asp)

