

Case Report

Transmastoid pediatric penetrating brain injury, interdisciplinary, and tailored patient's treatment

Tommy Alfandy Nazwar¹, Farhad Bal'afif¹, Donny Wisnu Wardhana¹, Akmal Niam Firdaus Masyhudi², Christin Panjaitan¹

¹Division of Neurosurgery, Department of Surgery, Faculty of Medicine, Universitas Brawijaya/Dr. Saiful Anwar General Hospital, Malang, ²Department Neurosurgery, Airlangga University/Dr. Soetomo General Hospital, Surabaya, East Java, Indonesia.

E-mail: Tommy Alfandy Nazwar - tommy@ub.ac.id; Farhad Bal'afif - farblf@ub.ac.id; Donny Wisnu Wardhana - donnywisnuw@ub.ac.id; Akmal Niam Firdaus Masyhudi - akmalmasyhudi69@gmail.com; Christin Panjaitan - christinpanjaitan28@gmail.com



*Corresponding author:

Tommy Alfandy Nazwar,
Division of Neurosurgery,
Department of Surgery, Faculty
of Medicine, Universitas
Brawijaya/Dr. Saiful Anwar
General Hospital, Malang,
East Java, Indonesia.

tommy@ub.ac.id

Received: 05 January 2024

Accepted: 21 February 2024

Published: 15 March 2024

DOI

10.25259/SNI_18_2024

Quick Response Code:



ABSTRACT

Background: Pediatric penetrating brain injuries (PBIs) are rare but critical traumatic events, often involving foreign objects. This report will emphasize the clinical presentation, diagnosis, and treatment strategies for pediatric PBI cases.

Case Description: This report presents a case of a 7-year-old male patient with a PBI resulting from a nail that penetrated the left mastoid region following a fall from a tree. On admission, the patient maintained consciousness, displayed stable vital signs, and showed no neurological deficits. Crucial radiological examinations, including skull X-rays and head computed tomography (CT) scans, revealed a 6.5 mm caliber nail penetrating 5.5 cm into the brain, with intraventricular hemorrhage filling the bilateral posterior horns of the lateral ventricles. In addition, the CT angiography (CTA) of the head provided a visual of the internal carotid arteries and the vertebrobasilar artery system, obscured by metal artifacts but showing no evidence of thrombus, aneurysm, or vascular malformation. The patient underwent an urgent mastoidectomy and retro sigmoid craniotomy to remove a foreign object, involving a multidisciplinary team. Subsequent to the intervention, the patient sustained full consciousness without neurological impairments and received intensive care.

Conclusion: Radiological tools, notably skull X-rays and head CT scans, are pivotal for the precise diagnosis of pediatric PBI. The combined mastoidectomy and retro sigmoid craniotomy approach offers a safe and efficient means of foreign body removal. Tailoring treatments to individual patient needs enhances outcomes.

Keywords: Case report, Computed tomography angiography, Foreign object, Pediatric, Penetrating brain injury

INTRODUCTION

Penetrating brain injury (PBI) in the pediatric population is a rare subset of traumatic brain injury (TBI). PBI accounts for around 0.4% of total brain injuries; despite this low incidence, it is associated with a significantly higher level of morbidity and mortality.^[11,15] Immediate management of PBI patients is paramount due to the high risks of morbidity and mortality resulting from vascular damage, seizures, infection, and cerebrospinal fluid (CSF) leakage.^[9] The management of PBI cases is highly challenging due to their location, the vascular structures and surrounding tissues encasing the foreign object within the skull, intracranial bleeding, and the risk of infection.^[8] A transmastoid nail PBI to the posterior fossa area is a life-threatening situation, and to the best of our knowledge, cases of this nature have not been previously reported. This

This is an open-access article distributed under the terms of the Creative Commons Attribution-Non Commercial-Share Alike 4.0 License, which allows others to remix, transform, and build upon the work non-commercially, as long as the author is credited and the new creations are licensed under the identical terms.

©2024 Published by Scientific Scholar on behalf of Surgical Neurology International

report will emphasize the clinical presentation, diagnosis, and treatment strategies for pediatric PBI cases.

CASE DESCRIPTION

A 7-year-old boy was admitted to the emergency department with a punctured nail in the left mastoid area after he fell off from a tree [Figure 1]. The patient was fully conscious with stable vital signs and no neurologic deficit. The patient exhibited a Glasgow Coma Scale (GCS) score of 4-5-6, demonstrating isocoric and reactive pupils with a diameter of 3 mm/3 mm. There was no medical history indicating fainting, vomiting, nausea, or seizure activity.

A head CT scan reveals a PBI by a foreign nail object in the left mastoid region [Figure 2]. The lesion, ± 6.5 mm caliber, and ± 7 cm length penetrates from the left mastoid, traverses the left cerebellum, and terminates in the right cerebellum [Figure 3]. The metal artifact caused blurring in the visualization of critical structures such as the pons, cerebellum, ventricle IV, cisternal systems, and cerebellopontine angle. The lesion, with a depth of approximately ± 5.5 cm, entered through the left temporal bone's mastoid part, traversing the left cerebellum and terminating in the right cerebellum. Furthermore, there was a hyperdense lesion filling the bilateral posterior horns of the lateral ventricles. There was no apparent soft-tissue swelling. The internal carotid arteries and the vertebralbasilar arteries are challenging to assess due to metal artifacts. The visualized CTA of the head appears within normal limits, with no evidence of thrombus, aneurysm, or vascular malformation. The patient received an anti-tetanus and antibiotic.

A multidisciplinary team comprising neurosurgeons, otolaryngologists, vascular surgeons, and anesthesiologists performed immediate surgical procedures, including mastoidectomy and retro sigmoid craniotomy. Surgical neurotreatment through craniotomy remains considered the safest approach. A crucial aspect of this procedure involved achieving hemostasis to reduce active bleeding and securely closing the dura to prevent CSF leakage.

During the surgical procedure, the patient was positioned in the park bench position to enhance access to the surgical site. The incision employed was a Lazy S-shaped postauricular incision, precisely aligned with the entry point of the foreign object. Initial management of the sizable wooden block necessitated meticulous handling, with its gradual removal in segments adhering to stringent sterilization protocols. Preceding patient positioning, electrical sawing was conducted to ensure sterility maintenance. Subsequent to the incision, a layered approach was adopted for mastoidectomy, systematically removing bone until visualization of the foreign object was achieved. Following nail localization, dural closure was effectuated utilizing primary closure techniques.

The absence of damage to adjacent intracranial tissues underscores the success of this surgical approach. The patient received broad-spectrum anti-tetanus and antibiotic treatment for three months. Following the operation, the patient's recovery progressed positively, with full restoration of consciousness and no apparent neurological issues.

DISCUSSION

PBI in children poses significant clinical challenges. This condition occurs when an object penetrates through the

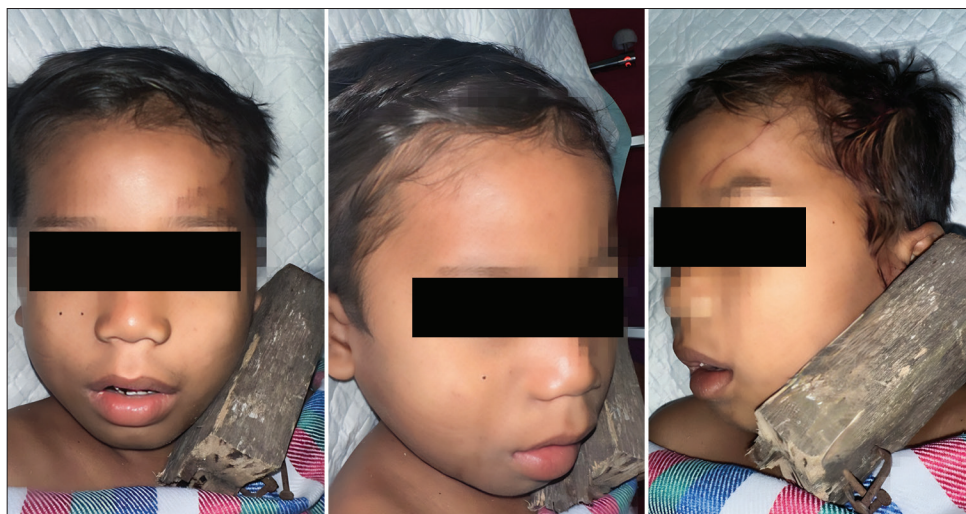

Figure 1: Clinical image capturing the entry point and trajectory of a foreign nail object in the left mastoid area of a 7-year-old patient. The photograph serves to highlight the specific characteristics and location of the penetrating object.

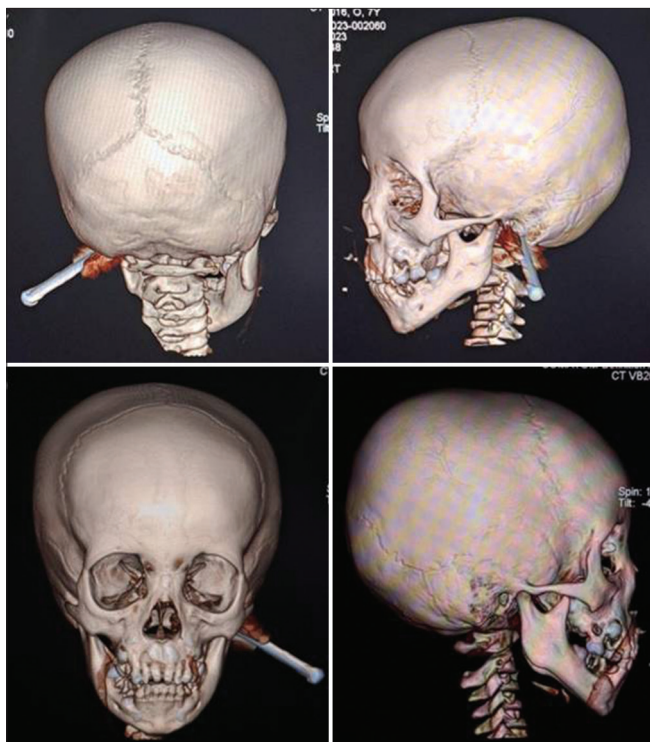


Figure 2: Head CT scan reveals a penetrating brain injury by a foreign nail object in the left mastoid region.

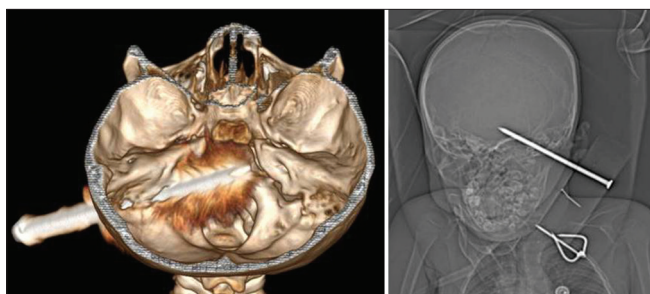


Figure 3: Head CT scan reveals the lesion, ± 6.5 mm caliber and ± 7 cm length, penetrating from the left mastoid, traversing the left cerebellum, and terminating in the right cerebellum.

skin and skull, causing damage to the brain tissue and intracranial blood vessels.^[2] Pediatric patients exhibit a diverse range of skull development and thickness, as well as thinner layers of surrounding soft tissue. This combination of factors implies that skull penetration might occur at lower velocities than required in adult cases.^[5] The factors influencing the outcomes of penetrating head injuries are diverse, including the type of object causing the injury, the trajectory of the object, the identification of vascular injuries, and the initial management of the patient.^[1] A low GCS score, especially below five, often serves as a poor predictor of patient outcomes.^[12] Therefore, the initial

evaluation of GCS is crucial in determining the next course of action.

Neuroimaging plays an important role in managing penetrating head injuries, helping to define an appropriate surgical strategy. Cranial computed tomography (CT) scans are the primary choice for neuroradiological evaluations in patients with penetrating head injuries.^[2] This preference is mainly due to the speed and efficiency of CT scans, which provide essential information about the projectile trajectories, the extent of cerebral impairments, the ability to detect even tiny bone fragments in the cranial cavity, and identifying intracranial hematomas and associated problems.^[4,7,12] Skull X-rays play a crucial role in detecting metallic foreign objects inside the skull cavity.^[14] In contrast, magnetic resonance imaging is limited in diagnosing intracranial nail injuries due to prolonged scanning times and susceptibility to interference from metal components.^[13,14] Cerebral angiography is highly recommended when the trajectory or location of the injury is near critical cerebral areas, such as the Sylvian fissure, supra clinoid carotid artery, verteobasilar vessels, cavernous sinus, or major dural venous sinuses.^[13] In our particular case, angiographic results indicated no vascular contact with the foreign object.

The management of PBI necessitates a comprehensive assessment, encompassing critical factors such as the precise site of injury, the intricate vascular architecture, the adjacent tissue relationship with the foreign body, and the inherent risks of infection and intracranial bleeding.^[1] The movement of foreign objects can lead to additional injuries. After the initial resuscitation, the treatment aims to remove the foreign object to prevent further injury, cleanse the brain tissue from bone fragments and foreign objects, and achieve other goals such as evacuating hematomas, achieving hemostasis, removing necrotic brain tissue, tightly closing the dura, and making precise incision sutures.^[10]

In cases where foreign objects penetrate a child's brain, potential complications can include damage to blood vessels from the object or its removal, unintentional harm to brain tissue, and the risk of c CSF.^[1] In addition, due to the distinctive nature of PBI, patients may be at risk of specific complications such as meningitis (inflammation of the brain's membranes) and vascular injuries.^[11] The use of nonspecifically specified broad-spectrum antibiotics is recommended as a prophylactic measure to prevent such infections.^[10] The decision to administer prophylactic antibiotics to TBI patients is largely based on previous guidelines and the preferences of neurosurgeons.^[3] In a study conducted by Marut *et al.*,^[6] it was found that 24 out of 33 patients received prophylactic antibiotics, and none of these 33 patients experienced central nervous system infections.

Although PBI has a high mortality rate, this patient had a good recovery and outcome. The collaborative,

interdisciplinary approach employed throughout this case proved instrumental in optimizing the patient's overall care journey. Drawing on various medical specialists' expertise, this approach ensured that the patient received a comprehensive continuum of care, ultimately enhancing the prospects for a successful recovery and sustained clinical improvement.

CONCLUSION

Radiological tools, notably skull X-rays and head CT scans, are pivotal for the precise diagnosis of pediatric PBI. The combined mastoidectomy and retro sigmoid craniotomy approach offers a safe and efficient means of foreign body removal. Tailoring treatments to individual patient needs enhances outcomes.

Ethical Approval

The Institutional Review Board approval is not required.

Declaration of patient consent

The authors certify that they have obtained all appropriate patient consent.

Financial support and sponsorship

Nil.

Conflicts of interest

There are no conflicts of interest.

Use of artificial intelligence (AI)-assisted technology for manuscript preparation:

The authors confirm that there was no use of artificial intelligence (AI)-assisted technology for assisting in the writing or editing of the manuscript and no images were manipulated using AI.

REFERENCES

- Cage TA, Sanai N, Lawton MT, Auguste KI. Penetrating knife injury to the skull: A case report in pediatric neurosurgical care. *Trauma (United Kingdom)* 2016;19:302-7.
- Ferraz VR, Aguiar GB, Vitorino-Araujo JL, Badke GL, Veiga JC. Management of a low-energy penetrating brain injury caused by a nail. *Case Rep Neurol* 2016;2016:4371367.
- Ganga A, Leary OP, Sastry RA, Asaad WF, Svokos KA, Oyelese AA, *et al*. Antibiotic prophylaxis in penetrating traumatic brain injury: Analysis of a single-center series and systematic review of the literature. *Acta Neurochir (Wien)* 2023;165:303-13.
- Kazim SF, Shamim MS, Tahir MZ, Enam SA, Waheed S. Management of penetrating brain injury. *J Emerg Trauma Shock* 2011;4:395-402.
- Kumar R, Kumar R, Mallory GW, Jacob JT, Daniels DJ, Wetjen NM, *et al*. Penetrating head injuries in children due to BB and pellet guns: A poorly recognized public health risk. *J Neurosurg Pediatr* 2016;17:15-221.
- Marut D, Shammassian B, McKenzie C, Adamski J, Traeger J. Evaluation of prophylactic antibiotics in penetrating brain injuries at an academic level 1 trauma center. *Clin Neurol Neurosurg* 2020;193:105777.
- Mikhael M, Frost E, Cristancho M. Perioperative care for pediatric patients with penetrating brain injury: A review. *J Neurosurg Anesthesiol* 2018;30:290-8.
- Muballe KD, Hardcastle T, Kiratu E. Neurological findings in pediatric penetrating head injury at a university teaching hospital in Durban, South Africa: A 23-year retrospective study. *J Neurosurg Pediatr* 2016;18:550-7.
- Samuthrat T, Ye K, Tong Y. Transoral intracranial injury via middle skull base by a blunt chopstick in a child. *World Neurosurg* 2017;103:952.e11-7.
- Tabibkhooei A, Taheri M, Rohani S, Chanideh I, Rahatlou H. Penetrating brain injury with a metal bar and a knife: Report of two interesting cases. *Neuroradiol J* 2018;31:203-6.
- Takahashi CE, Virmani D, Chung DY, Ong C, Cervantes-Arslanian AM. Blunt and penetrating severe traumatic brain injury. *Neurol Clin* 2021;39:443-69.
- Vakil MT, Singh AK. A review of penetrating brain trauma: Epidemiology, pathophysiology, imaging assessment, complications, and treatment. *Emerg Radiol* 2017;24:301-9.
- Woo X, Yap NK, Toh TH, Yiek SH. Accidental low-velocity penetrating brain injury by glass marble. *Asian J Neurosurg* 2022;17:116-9.
- Wu R, Ye Y, Liu C, Yang C, Qin H. Management of penetrating brain injury caused by a nail gun: Three case reports and literature review. *World Neurosurg* 2018;112:143-7.
- Wu Y, Chen TG, Chen SM, Zhou L, Yuan M, Wang L, *et al*. Trans-base and trans-vault low-velocity penetrating brain injury: A retrospective comparative study of characteristics, treatment, and outcomes. *Chin J Traumatol* 2021;24:273-9.

How to cite this article: Nazwar TA, Ba'afif F, Wardhana DW, Masyhudi AN, Panjaitan C. Transmastoid pediatric penetrating brain injury, interdisciplinary, and tailored patient's treatment. *Surg Neurol Int.* 2024;15:85. doi: 10.25259/SNI_18_2024

Disclaimer

The views and opinions expressed in this article are those of the authors and do not necessarily reflect the official policy or position of the Journal or its management. The information contained in this article should not be considered to be medical advice; patients should consult their own physicians for advice as to their specific medical needs.