

# Diagnostic and therapeutic pitfalls in benign vocal fold diseases

## Abstract

More than half of patients presenting with hoarseness show benign vocal fold changes. The clinician should be familiar with the anatomy, physiology and functional aspects of voice disorders and also the modern diagnostic and therapeutic possibilities in order to ensure an optimal and patient specific management. This review article focuses on the diagnostic and therapeutic limitations and difficulties of treatment of benign vocal fold tumors, the management and prevention of scarred vocal folds and the issue of unilateral vocal fold paresis.

**Keywords:** benign vocal fold lesions, unilateral vocal fold paralysis, evaluation of voice, voice disorder, vocal fold scarring, phonosurgery, voice therapy

## Jörg Bohlender<sup>1</sup>

1 Phoniatics and Logopedics, Department of Otorhinolaryngology, Head and Neck Surgery, University Hospital of Zurich, Zurich, Switzerland

## Introduction

The management of patients presenting with voice disorders is complex and often controversial. An expert knowledge of diagnostic and therapeutic possibilities [1] is clearly required, but often good quality evidence is lacking as to the best treatment for the individual patient. Voice disorders present in a wide spectrum of patients, across all ages, gender and social status. The causes are often multifactorial and cannot always be fully described in anatomical or functional terms. Furthermore, voice disorders are much more varied than mere hoarseness. Indeed, a voice disorder may only have a limited affect on vocal ability, and yet strongly affect the patient's quality of life, whether at work or at home [2]. Dysphonia only loosely describes the variety of possible voice disorders and their severity [3].

Furthermore, voice disorders cannot always be reduced to anatomical and functional disorders of the larynx and vocal folds. The perceived voice is much more than simple vocal fold vibration at the laryngeal level. Breath control, vocal tract and articulatory movements are integral to the production and character of a voice and influence, in their respective ways, the perceived voice.

With regards to the larynx itself, many different pathologies can lead to vocal disorders. These include, amongst others, congenital malformations, inflammatory conditions, benign and malignant tumors and neurogenic functional problems. Moreover pulmonary, endocrine, gastrointestinal, neurological, medical, and psychosocial factors can affect the voice [4]. Even in the absence of organic pathology, functional problems can also lead to voice disorders and thus the clinician must always consider the interplay between any underlying organic disorders and psychogenic problems.

The ENT surgeon is often the first specialist consulted by a patient with a voice disorder. More than half of these patients will have benign vocal fold changes [5], [6] and

their treatment is often a combination of conservative and interventional measures. To this end, ENT surgeons with an interest in voice disorders rarely work alone, and a multidisciplinary team consisting of, amongst others, speech and language therapists allows for the best possible patient care.

This article focuses on these benign voice pathologies and explores the many and varied diagnostic and therapeutic possibilities.

## Background

The importance of laryngoscopic findings for voice disorders is beyond question. Especially with prolonged, unexplained hoarseness an endoscopy to rule out malignancy is essential. Beyond this however, the voice specialist must have a more holistic approach to the patient. Simply focusing on the larynx and initiating a therapy is not sufficient.

An analogous situation can be seen in otology. Patients need more than an otoscopic assessment for hearing loss. A broad differential diagnosis must first be established from a thorough history and then, following a physical examination which clearly includes otoscopy, this differential can be narrowed down with the various hearing tests, blood tests and imaging studies available. Thought must also be given to the vestibular apparatus even if the patient has no specific vertigo complaints.

Laryngoscopy and stroboscopy can often visualise structural vocal fold changes in the lamina propria (Table 1). Polyps, nodules, Reinke's edema and pseudocysts are all exudative lesions of Reinke's space which share a sub-epithelial edema. It can therefore be difficult to distinguish from one another, both clinically and even histologically [7], [8].

**Table 1: Localisation of benign vocal fold lesions**

<b>Vocal fold epithelium</b>	Laryngeal papillomatosis Hyperkeratosis
<b>Lamina propria</b>	Reinke's Edema Pseudocyst Vascular malformations Vocal fold nodules Vocal fold polyp Vocal fold cyst Vocal fold scarring Bamboo nodes
<b>Arytaenoid</b>	Vocal process granuloma Postintubation granuloma

modified after: Rosen CA, Murry T. Nomenclature of voice disorders and voice pathology. 2000. [81]

Even if the diagnosis seems evident on inspection of the vocal folds, for example a vocal fold polyp, the specialist must resist the temptation to jump to conclusions and rather, as described above, carry out a thorough holistic work-up.

One specific feature which must be carefully clarified is evidence for acute or chronic phono-trauma. This can lead to a remodeling of the vocal folds [9], [10] and is a potential cause of many voice pathologies. As such, it must be recognized in order to allow appropriate therapy.

## Diagnosis

Accurate history taking, clinical examination and up-to-date investigations allow for the accurate diagnosis and documentation of various voice disorders. A multi-modal approach, using the various investigations available can help assess a therapeutic indication and allows for pre- and post-therapeutic (surgical or otherwise) evaluation of the voice [11].

A standardized approach to voice disorders makes documentation, diagnosis and treatment more straightforward and consistent and as such guidelines were established by the European Laryngological Society (ELS) in 2001 [12].

This approach consists of 5 parts:

1. Subjective rating by the patient
2. Perceptual voice evaluation by the specialist
3. Acoustics
4. Videostroboscopy/vibration analysis of the vocal folds
5. Aerodynamics

Through this framework, great advances have been made in terms of standardization and quality control. The ELS guidelines provide a minimum consensus amongst voice specialists and allow diagnostics and other voice-related data to be collected across centres in an understandable and comparable way. By having more consistent and better baseline diagnostics, the better various treatments can be evaluated against a variety of therapeutic goals

and hopefully, better quality data and evidence based therapy will follow.

Nevertheless, these guidelines should not be relied on as a treatment protocol with specific findings implying specific treatments. Any diagnostic information is only as good as the person interpreting the different results and combining them into a consistent whole. The limitations of specific tests need to be known, and it should always be borne in mind that these tests only provide a snapshot in time of the voice.

Often, repeated testing with time intervals is necessary to aid accurate diagnosis. The ELS guidelines should guide the specialist, but should not be seen as a rigid framework. There are, for example, many situations such as spasmodic dysphonia, aphonia, and post-laryngectomy where the ELS protocol is inappropriate.

## Subjective rating by the patient

The self-assessment of voice quality is an important criterion for the diagnosis and treatment of voice patients. The structured assessment of subjective vocal impairment or disability is performed using a questionnaire (Voice Handicap Index, VHI). The VHI integrates the functional, physical and emotional aspects of a voice disorder. The subjective severity of the voice-related problems is rated by the patient on a scale of 0 to 4 and these summated to provide an overall voice handicap score. This questionnaire is an essential part of both the initial and ongoing assessment of voice patients and a validated German version consisting of 9-questions (VHI 9i) is available [13], [14].

The clinician must be aware that the subjective VHI score does not necessarily correlate well with clinical examination findings and therefore complements, rather than replaces, a thorough medical history and examination. The VHI's categories of functional, physical and emotional also do not necessarily help uncover the underlying cause of dysphonia.

It cannot, however, be emphasized enough that treatment planning can only follow-on from an accurate assessment of both the patient's subjective and objective problems [15].

## Perceptual evaluation by the voice specialist

Clinician-based perceptual assessment involves the auditory evaluation of the voice based on defined acoustic features [16]. The evaluation of hoarseness (H) focuses primarily on voice characteristics associated with disorders of the vocal fold. Thus, irregular vocal fold vibrations can be defined as rough (R) and an incomplete glottis closure defined as breathy (B). Hoarseness often combines varying degrees of both roughness and breathiness. The RBH scale has been established in the Germanspeaking world as a standardized and validated method for evaluating hoarseness [17]. Internationally

the GBRAS includes the overall dysphonia grade, roughness, breathiness, asthenia and strain [18].

Acoustic vocal phenomena cannot, however, be entirely reduced to the glottis alone. The vocal tract configuration is also key. Vocal sound phenomena that are not captured by the RBH or GRBAS approach should be listed separately. For example, nasality, diplophonia, voice instability, unsuitable average of the fundamental frequency of the voice, pathological vocal onset and release [19], [20].

An objective, systematic, sophisticated and non-prejudiced voice evaluation is no easy skill and requires continuous training of the examining physician. Unfortunately, despite efforts to standardize voice assessment, the more complex and sophisticated a voice assessment the less inter- and intra-observer reliability.

## Acoustics

### Objective methods

Due to the poor inter-observer reproducibility mentioned above, more 'objective' methods of voice assessment have been established. These should be performed in addition to complement the evaluation detailed above [21].

Computer-assisted acoustic analysis includes measures of sound irregularity (jitter, shimmer, glottal-to-noise excitation ratio) and acoustic spectra (broadband and narrowband) as important elements of a comprehensive voice evaluation [22]. These computer analyses are not mere research tools, and can be clinically used for initial examination and to document the therapeutic response, for example before and after surgery or other interventional measures [23], [24], [25], [26], [27].

The difficulty of this easily usable technique lies in the interpretation of the findings. The results are influenced among other things by the research methodology, age and gender groups, software and hardware, as well as ambient noise. Furthermore, the lack of interference independent standard values limits the application of these measurements to serial measurements of an individual. The physician should be familiar with his equipment and in particular the standard values used in order to avoid drawing hasty conclusions from the results. Computer aided measurements are one of many investigations at the clinician's disposal and it is the interpretation of these results that a relevant and accurate diagnosis can be made.

### Voice range profile

This is the computer-assisted determination of individual vocal range and power profiles by the measurement of the pitch (=fundamental frequency in Hz) and vocal intensity range (=sound pressure level in dB (A)) for both the speaking and singing voice [28].

Starting from 'normal' unstressed speech, the power is increased in stepwise fashion until shouting. When the singing voice is evaluated, tonal range and the corres-

ponding dynamic range from the quietest to the loudest singing voice are assessed. The use of the vocal range measurements is primarily used in evaluating the impact of therapy on an individual.

The presently available standard values must be interpreted with caution as they are mostly estimations based on small groups and therefore cannot be considered as truly representative of all age and gender groups. Furthermore, the healthy voice shows significant variation [29]. Recent studies have attempted to provide normative values for range and power profiles in defined age/gender groups [30], [31], [32].

### Dysphonia Severity Index (DSI)

The Dysphonia Severity Index (DSI) has four different levels of severity [33], [34] and reflects the desire of the clinician to combine all the various data collected into a single score. The DSI includes the highest phonational frequency (F0 max) and the lowest vocal intensity (SPL min), and the maximum phonation time (MPT) and jitter (%). Thus the DSI provides a useful score which can be used in studies and patient follow-up [33], [35]. However, the physician must remain critical as the measurements contributing to the DSI – as explained above – may be erroneous [36].

### Laryngoscopy and stroboscopy

Both the morphological and functional assessment of the larynx is essential to a thorough work-up. Good visualization of the vocal folds is the springboard for an accurate diagnosis of hoarseness. The increasing use of digital photographic documentation allows findings to be shared with the patient and comparisons to be made both inter and intra-patient.

Whichever of the rigid or flexible endoscopes used, sufficient magnification and resolution must be achieved. During inspection of the various laryngeal structures, subtle changes of the vocal fold mucosa and adjacent areas should be documented and interpreted in the overall context of the voice disorder. The examiner should not be distracted by obvious pathology, but rather carry out a systematic evaluation.

The endoscope is however, not all seeing. Pathology lying below the free vocal fold edge cannot always be detected in the examination stool and requires more invasive techniques. The examination is also very dependent on both the skill of the examiner and the cooperation of the patient. Strong gag reflexes can be subdued with local anaesthesia or may be less apparent with a transnasal flexible endoscopy. The latter technique also allows for a more normal phonation and provides an excellent method of assessing both the singing and speaking voice [37], [38].

Endoscopy can also be supplemented with stroboscopy, allowing the complex vibrations of the vocal folds to be examined at different pitches, registers and sound intensities. Vibratory amplitude, features of vocal fold edge,

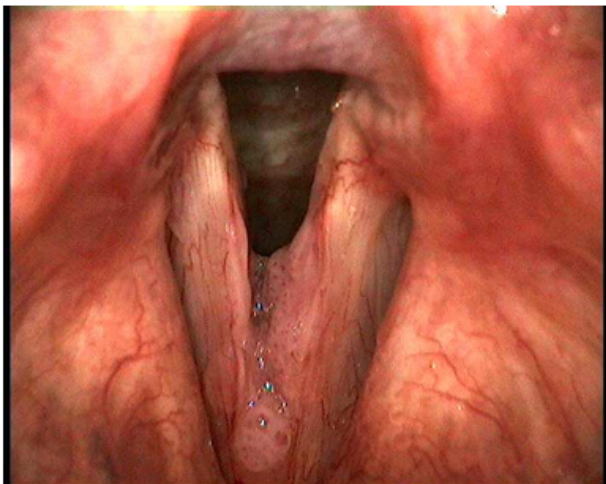
mucosal wave, glottic closure, phase symmetry, regularity and glottal cycle periodicity [39] can all be assessed, however, the interpretation of these stroboscopic findings is highly userdependent. Additional features such as the stroboscopic assessment of glottic closure and vertical plane show poor inter-observer reliability and are less suitable for the clinical practice [40]. Unstable phonation makes stroboscopic examination impossible. In these cases, high-speed digital imaging (HSDI) of the vocal folds allows for accurate assessment despite moderate to severe aperiodic vibration. This technique complements stroboscopy and may even, in the future, come to largely replace it.

## Benign vocal fold pathologies

### Laryngeal papillomatosis

The incidence of laryngeal papillomatosis is roughly 1.8 per 100,000 [41] and Human Papilloma Virus (HPV) subtypes 6 and 11 are chiefly responsible. Despite being a histologically benign disease, the growth and propensity for recurrence of laryngeal papillomatosis makes them dangerous. Disease spreading into the lungs and even malignant transformation have been reported [42].

Endoscopically, laryngeal papillomas are isolated, exophytic or sessile, “raspberry”-like growths (Figure 1). They can sometimes be mistaken for vocal fold polyps, or even a malignancy, especially when only visualized using transnasal flexible endoscopy [43]. The clinical course of laryngeal papillomatosis is difficult to predict and patients require long term, regular care. Treatment, whether conservative, medical or surgical, represents a challenge for both the patient and physician.



**Figure 1: Laryngeal papillomatosis**

When conservative and medical approaches have failed, and especially in the setting of increasing airway obstruction or significant worsening of the voice, surgery can be considered.

Pre-operative staging of the disease in terms of localization, size and number is recommended. The epithelial

nature of the disease allows for excision but the surgeon is often confronted with problem that seemingly normal looking tissue may well harbor HPV infection [44], [45]. Due to the high recurrence rate and the probable need for a great number of interventions during the patient's life, a “less is more” approach should be employed. Functional laryngeal structures should be preserved and a debulking of disease rather than radical excision may help prevent excessive post-operative scarring. It must be emphasized that surgery is not curative, it is only for symptom control [46], [47]. Furthermore, irrespective of the method used (micro-surgical cold steel resection, micro-debrider or laser), post-operative scarring can greatly affect the voice [48].

Recently, adjuvant treatment has been added to surgery in order to reduce the frequency and extent of surgery. For example, intra-lesional cidofovir injections, a virostatic agent, have shown encouraging results in the few published studies [49], [50], [51]. ENT associations have however issued warnings about this off-label use of cidofovir since as long ago as 2011 [52]. The manufacturer lists serious side effects including potential nephrotoxicity, neutropenia and potential teratogenesis [53]. Currently the risk-benefit profile of this treatment needs further study, preferably in large well conducted studies before its use can be recommended [54], [55], [56].

Another adjuvant option is bevacizumab [57], [58]. This monoclonal antibody has been used in malignancy where it prevents angiogenesis and thereby slows tumor growth. Intra-lesional injections together with the use of the KTP laser have again showed promise [59].

Case reports have also documented the effect of HPV vaccination against subtypes 6 and 11, not only in terms of disease prevention but also showing a therapeutic effect on existing papillomas [60], [61], [62].

Due to the life-long nature of the disease and the requirement for multiple interventions during the disease course, a good doctor-patient rapport is needed. This includes a full and frank discussion of the natural history of the disease and its implications for the patient's work and social life. Moreover, a well informed patient is better able to recognize problems early and cope with the multiple interventions [46].

### Vocal fold polyps

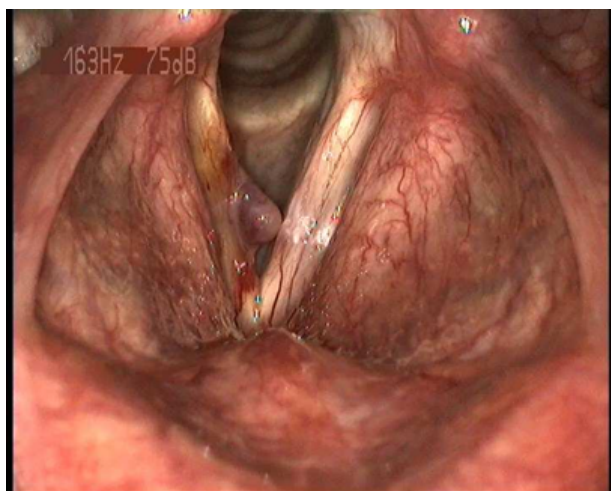
Vocal fold polyps can be either sessile or pedunculated, unilateral or bilateral and occur commonly at the free edge of the vocal fold. They can be further characterized as edematous, hyaline or mixed [63] (Figure 2).

Often as the result of acute or chronic voice abuse, microvascular trauma leads to sub-cellular changes and the typical histological features found in the lamina propria. Edematous changes, increased capillarization and inflammation are characteristic [64]. These same exudative inflammatory changes can often be seen in vocal fold nodules and Reinke's edema [7].

In addition to the repetitive trauma mentioned above, airway infections, allergies, nicotine, gastro-esophageal



reflux, aspirin and other blood thinning medications can also contribute to polyp formation [64].



**Figure 2: Vocal fold polyp**

Voice quality often correlates with the size and location of the polyps. Such polyps typically affect adults whose work involves frequent voice stress [64], for example, teachers. These patients are also at higher risk of vocal fold cysts and nodules [65].

Although the finding initially appears as a purely structural and primarily surgical problem, the treating otolaryngologist should check the specific requirements of the patient for his work and leisure time and organize the relevant voice diagnostics. If the underlying pathogenesis is ignored, recurrence is possible even with successful surgical dissection. In some cases it is advisable to instigate postoperative voice therapy though voice therapy as the sole treatment modality is unlikely to cure vocal fold polyps despite anecdotal reports of its success [66].

## Reinke's edema

Reinke's edema is an edematous swelling of the superficial layer of the lamina propria. The extent of swelling can vary between only a subtle swelling through to massive swelling and obstruction (Figure 3).

Reinke's edema statistically presents most often in women between 40–60 years old. The exact etiology of these benign chronic changes is unclear [67] but inhaled chemicals (eg. nicotine), laryngo-pharyngeal reflux and hyperfunctional vocal behavior have all been suggested [68], [69]. The mass and volume increase of the vocal folds is especially noticeable in the female voice as it results in a deeper, more hoarse speaking voice. With massive edema, airway obstruction may be the most significant symptom.

Therapeutically, Reinke's edema is tackled both conservatively and surgically depending on the patient's complaints and the presumed cause. Conservative measures include smoking cessation [7], proton pump inhibitors for reflux and voice therapy to reduce chronic vocal hyperfunction. (Whilst smoking cessation does not contribute to a reduction in Reinke's edema, it does significantly

improve postoperative wound healing [43].) Significant obstruction and extreme hoarseness are indications for surgery [70].

Surgery is almost never urgent in the management of Reinke's edema, and as such, the treating clinician should only recommend it with great care. It is essential to match the objective findings with the patient's subjective complaints and also carefully elucidate the patient's expectations.

If surgery is being contemplated the surgeon should ask himself: How strongly does the patient feel impaired by his hoarse? Does the patient in fact feel that his deep and raspy voice is an integral part of his identity? Does he actually want this audible personality trait to be changed at all?

Often a trial of voice therapy is warranted, and if surgery is performed, this can be a "sandwich" therapy, i.e. both pre-and post-operatively. Through intensive voice therapy, often over a considerable length of time, the patient should be able to break his vocal bad habits and prevent re-injury to the vocal folds.

The patient should be informed of the above-average risk of debilitating postoperative vocal scarring and possible incomplete adduction of the folds following surgery [71]. The amorphous morphology of Reinke's edema, which includes the entire vocal fold length, makes surgery difficult [72]. To avoid irreversible scarring, the surgery should be performed carefully taking into account the vocal fold architecture [73], [74]. The traditional method of stripping the vocal folds is now obsolete.

Despite the controversy surrounding surgical intervention for Reinke's edema, we would recommend a two-stage technique [75]. This is applicable throughout the spectrum of disease and not only to massive and troublesome, incompletely viewable edema of the anterior commissure, which can give rise postoperative scarring and synechia in the anterior region to be [3], [76]. Some patients can achieve a satisfactory voice with only a unilateral procedure. This often leads in time to a reduction of edema on the contralateral side which can be documented endoscopically [75].

## Vocal fold cysts

An estimated 14% of all benign vocal fold tumors can be classified as vocal fold cysts [77] and these should be sub-classified as either retention or epidermoid cysts.

Retention cysts are found within the lamina propria and are lined with a thin glandular epithelium. Inflammatory obstruction of mucous glands in the vocal fold or mechanical phono-trauma can lead to the formation of retention cysts. These are characteristically seen in occupational groups with a high vocal stress (Figure 4a and 4b).

Epidermoid cysts, on the other hand, are congenital or secondary to a vocal trauma and are typically surrounded by a solid epithelium. The cyst sac often extends to the vocalis ligament and rupture can lead to scarring and changes of the lamina propria (Figure 4c).

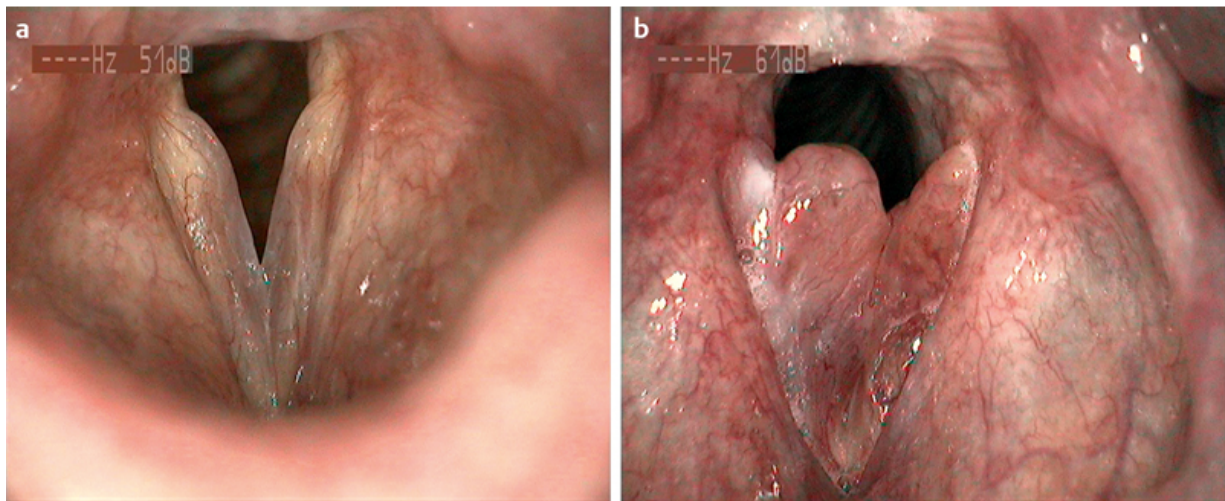


Figure 3: a) Reinke's edema; b) Bilateral massive vocal fold thickening due to Reinke's edema

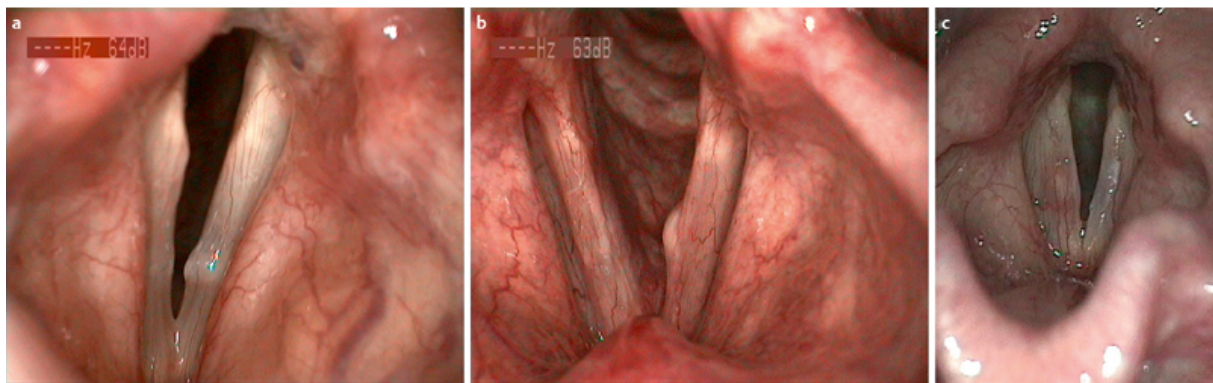


Figure 4: a) Vocal fold cyst; b) Vocal fold cyst with corresponding scars; c) Epidermoid cyst

Cysts can be uni- or bi-lateral. Their affect on voice quality depends on their size and location. Due to their adherence to the deeper layers of the lamina propria, epidermoid cysts in particular can have a substantial affect on the voice.

Stroboscopically, diagnosis can be made difficult by contra-lateral lesions which the otolaryngologist may confuse with vocal fold nodules. Both lesions can affect the mucosal wave in similar ways, depending on their size and depth [78], [79], [80].

Prior to excision, two problems must be discussed with the patient. Firstly the extent of the cyst and secondly whether complete removal is possible. The deeper the cyst, the more likely, despite careful operating technique, that postoperatively the vocal fold will not vibrate normally.

Intra-operatively, the entire cyst sack should be excised in order to reduce the risk of recurrence. This is normally made easier by not bursting the sack, though in some cases this is unavoidable. The surgeon must then strive to peel the remaining cyst wall off the surrounding structures.

Postoperatively up to 20% of cases will show scarring, polyps and/or vascular changes in the vicinity of the excised cyst [80]. These changes should actively be looked for on postoperative laryngoscopy and documented. When severe, they may necessitate further surgical intervention.

Intra-operatively, changes which are thought to be reactive to the cyst need not be addressed during cyst excision, as once the cyst is excised, they often regress [81].

Due to the risk of poor postoperative function despite successful cyst excision, surgical intervention should be used sparingly. Patients, such as opera singers or actors, who use their voice for their work must especially beware of the foreseeable and unforeseeable complications of excision. All alternative therapies should be discussed. In a few cases, despite cystic changes to the vocal folds, no functional limitations can be found [3].

## Vocal fold nodules

Vocal fold nodules (eg. singer's nodes), are traditionally seen as the consequence of functional voice disorders, often caused by vocal abuse or misuse, and are amongst the most common vocal fold pathologies. These nodules are typically bilaterally symmetrical in the middle third of the vocal fold and located superficially on the vibrating free edge of the fold (Figure 5).

Anatomically, the diagnosis can be made difficult by the heterogeneity of lesions. These range from discrete, poorly circumscribed edematous lesions to hard, horny nodules [82]. Stroboscopically, incomplete glottis closure (classically an hour-glass closure pattern) can help make the



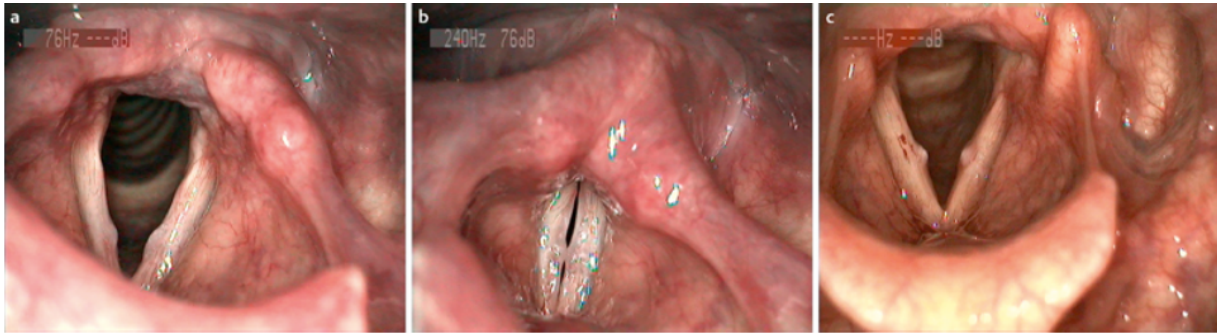


Figure 5: a and b) Soft vocal fold; c) Hard vocal fold nodules

diagnosis [83]. Functionally, patients often present with a poor vocal endurance and a quickly tiring voice.

Vocal fold nodules are thought to be the result of quantitative and qualitative excessive voice misuse or abuse. Boys and young women and teachers are particularly affected [84]. Usually, an increased vocal load, for example, due to the patient's profession, is responsible for the formation of nodules.

The pathogenesis of these lesions is due to the disproportionately high mechanical shear on the free edge of the vocal fold which damages the superficial layer of the lamina propria and results in micro-vascular changes in the middle third of the fold. In time, this results in remodeling of the tissue with increasing hyalinization and epithelial hyperplasia, leading to typically circumscribed lesions in the vocal folds. Histologically, thickening of the basement membrane and an edematous swelling of the lamina propria are characteristic [85].

Noteworthy is that histologically it is often difficult to tell the different lesions of the lamina propria apart (eg. nodules, polyps and Reinke's edema) [86], [87]. The correct diagnosis cannot therefore be made purely histologically, but requires a complete assessment including history, voice assessment and laryngoscopic/stroboscopic findings [88].

Conservative voice hygiene and voice therapy are viable therapeutic measures for nodules. The patient's motivation, vocal requirements in social and professional life together with the correct diagnosis allows an appropriate conservative treatment plan to be formulated. It is worth noting that a specifically tailored program, including targeted voice therapy, achieves better results than a generic program [89].

Whilst there is often a subjective and objective improvement of the voice, this is not always matched by improvements in the laryngoscopic/stroboscopic findings. When conservative measures fail to achieve the desired results [90], [91] phonosurgery may be indicated. It is therefore the patient who dictates the need for surgery rather than the size of the nodules alone. Furthermore, it should also be borne in mind that surgery does not necessarily correct the underlying causal process at hand [88]. Voice therapy is therefore key to gain a long lasting improvement after surgery and reduce the likelihood of recurrence.

Surgical intervention is also not without risks. Despite careful micro-dissection, damage to the lamina propria

can lead to further voice problems. The deeper the resection, the more likely changes in stiffness of the vibrating free edge will lead to a poor voice [92]. Lesions which are only identifiable on stroboscopic examination can be particularly difficult to operate on under general anesthesia. For all intents and purposes, the surgeon is carrying out a "blind" dissection which increases therefore the post-operative risks.

Whether surgery should be performed with cold steel dissection or laser is still a matter of controversy as both afford much the same results in experienced hands. We would argue however that the use of the laser for superficial lesions should only be performed if good tissue protection can be afforded. Until further evidence of its safety, overall we would recommend against the use of lasers [93].

## Contralateral lesions

Not every contralateral vocal fold lesion is a nodule. The differential diagnosis includes benign vocal fold tumors and a corresponding contralateral thickening. A history of chronic, tissue-damaging phonotrauma is the differentiating factor [81]. Altered vibrations of the vocal fold result in microtrauma and secondary epithelial thickening of the contralateral vocal fold. These morphological differences can be so subtle as to be only distinguishable on stroboscopic assessment [81].

Correct diagnosis is essential before deciding on treatment. Cystic or edematous lesions do not normally respond to voice therapy and will require surgery. Only the primary lesion needs to be excised, as the corresponding contralateral lesion will then often regress [94].

## Bamboo nodes

Bamboo nodes (Figure 6) can be the first sign of a chronic systemic autoimmune disease such as rheumatoid arthritis [95]. The symptoms of hoarseness often correlate with the history and frequency of exacerbations of the underlying disease.

Suspicion of an autoimmune disease necessitates a complete work up and appropriate onward referral. The voice complaints can then be followed whilst the patient undergoes treatment of the underlying disease. Persistent hoarseness despite good underlying disease control can

be ameliorated with voice therapy and intra-lesional steroid injections [96]. Microsurgical excisions should be reserved for treatment failure, and always combined with post-operative voice therapy [97], [98].

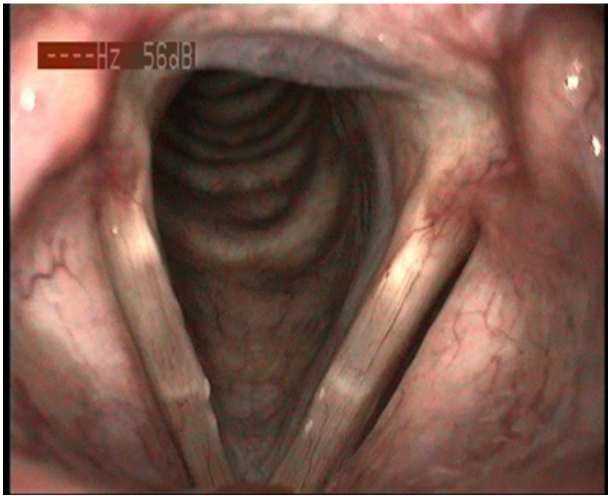


Figure 6: Bamboo nodes

Unfortunately, there is as yet no ideal management for these rare lesions. The most important thing is therefore that the otolaryngologist recognizes these manifestations of systemic disease and differentiate bamboo nodes from other similar findings such as bilateral cysts.

### Vocal process granulomas

Vocal process granulomas are classified as benign chronic inflammatory lesions arising in the cartilaginous third of the vocal fold. They are believed to arise after mechanical trauma or inflammation of the posterior glottis. Chronic coughing, voice abuse or continual clearing of the throat, when extreme enough, can damage the epithelium of the processus vocalis. Following a hammer/anvil analogy, repetitive trauma prevents normal healing and leads to eventual ulcerative tissue changes and reactive overgrowth (Figure 7).

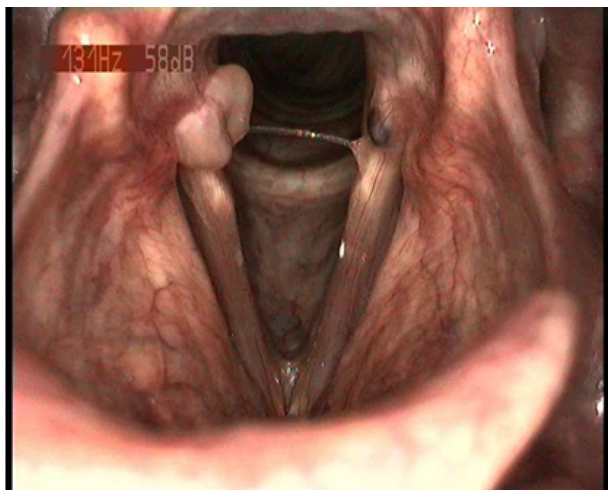


Figure 7: Vocal process granuloma and microweb

Trigger factors include laryngo-pharyngeal reflux [99] and psychosomatic issues. Patients often exhibit compulsive or depressive character traits or may have loss emotionally significant persons [100]. The role of glottal insufficiency in the pathogenesis of contact granulomas is still a matter for debate [101].

Vocal process granulomas are diagnosed on laryngoscopy, and are characterized by unilateral tissue augmentation with a corresponding ulcer. The granulations tissue is usually medio-cranial of processus vocalis. The contact granuloma may mimic the appearance of a malignant process by its enormous size, but the granulation tissue itself shows no tendency to malignant transformation [102]. Contact granulomas are very common in men, especially between 40–50 years of age.

Due to high recurrence rates, treatment is conservative rather than surgical, with voice therapy and proton pump inhibitors [75]. Indeed, surgery as the single treatment modality has no role [103]. Recurrence rates of up to 92% are reported [104] despite careful microsurgical excision and cleaning of the perichondrium [105]. We reserve surgery only to exclude malignancy or for obstructing granulomas [106], [107].

Medical treatment modalities such as botulinum toxin injection [108], steroid injection [109] and zinc sulfate therapy [110] have been described. Despite the reported higher rates of depression in this patient group, the success of psychotherapy is as yet unproven [111].

### Post-intubation granulomas of the larynx

These granulomas are a delayed complication of tracheal intubation and are differentiated from classical contact granulomas through an accurate patient history. They arise secondary to direct mucosal trauma of the posterior glottis during intubation/extubation and can be unilateral or bilateral. They often first appear roughly 4 weeks after extubation [112] (Figure 8).

In contrast to classical contact granulomas, intubation granulomas are more often seen in women [113]. This may be due to the anatomy of the female larynx [114]. Further risk factors for granuloma formation include the tube size, the individual larynx configuration, tube movement, the type of intubation and gastro-esophageal reflux. The duration of intubation does not seem to be relevant, at least if it is less than 3 days [115].

Interestingly, despite their very different etiologies, no specific treatment strategies for intubation granulomas, as opposed to contact granulomas, exist. Presumably, the risk of recurrence should be lower. In our experience, intubation granulomas spontaneously regress and therefore a “watchful waiting” approach may be adopted [116].



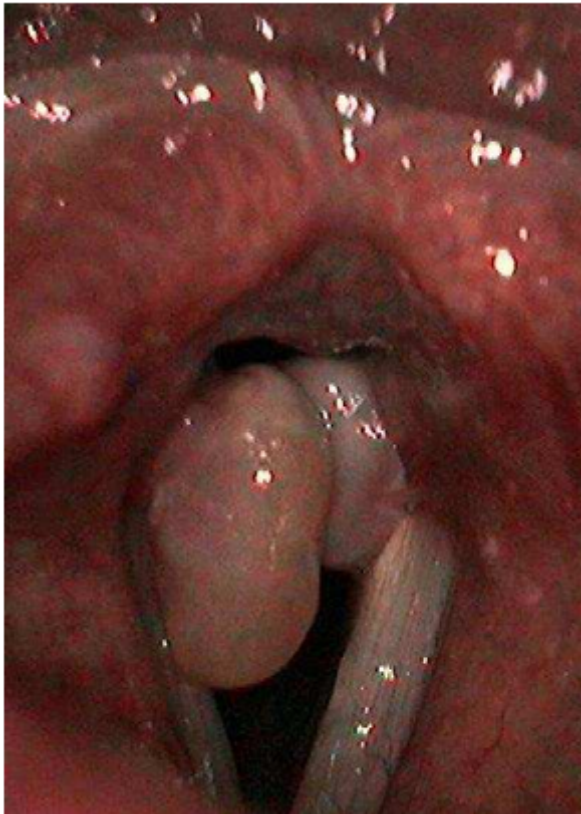

Figure 8: Postintubation granulomas of the larynx

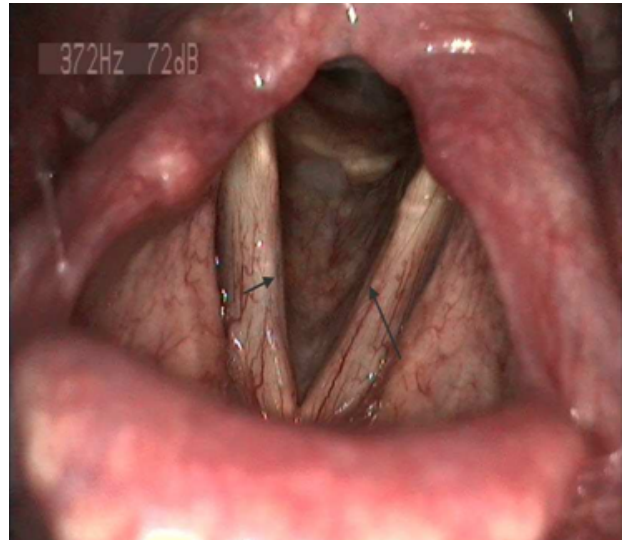


Figure 9: Bilateral vocal fold scarring

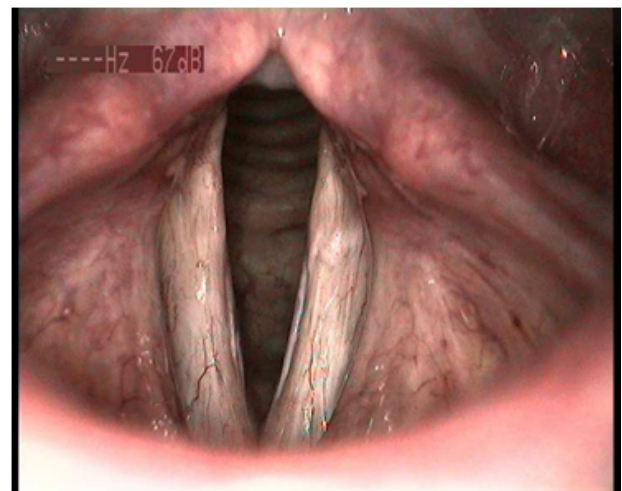


Figure 10: Bilateral sulcus glottidis

## Vocal fold scarring, sulcus glottidis

### Introduction

Scarring of the vocal folds can lead to lifelong impairment of the vocal performance. Even small amounts of scarring can have a marked affect. Scarring can be congenital or acquired, the latter generally associated with traumatic or inflammatory insults. Acute or chronic phonotrauma, iatrogenic damage during surgery, intubation, chemical and thermal insults and external laryngeal injuries can all lead to irreversible scarring of the vocal fold. The scarring process itself is a complex interplay of genetic factors and the particular insult [117].

Scarring, whether circumscribed or superficial, has multiple effects on the lamina propria. Together with a volume loss, scarring can result in altitude changes in comparison to the healthy fold, or increased tissue bulk (Figure 9).

Trough shaped depressions reaching the vocal ligament as a result of degenerative processes in the sulci vocales can be seen (Figure 10).

Vocal fold scarring represents a major challenge for the treating physician, specifically in three main areas [71], [118], [119]:

1. Phonosurgery and the risk of scarring
2. Diagnosis and treatment of existing scars
3. Postoperative wound healing

### Phonosurgery and the risk of scarring

Before any surgical intervention, no matter how small, the risk of scarring and its impact on the voice should be thoroughly discussed.

During excision of benign vocal fold lesions, the functional consequences and the body cover model should be remembered. Careful microsurgical dissection should be restricted to the lesion with minimal disruption of surrounding tissue. Due to advances in technique and a better functional understanding of the vocal folds, vocal fold stripping is now obsolete [20], [72], [75].

The surgeon should select either laser or cold steel according to his experience and which tool he believes will offer him the very best precision during the surgery [92], [120], [121], [122], [123]. Each method has its pros and cons and the surgeon should use the technique with which he is most confident [124], [125]. The patient must still be aware that even expert surgical dissection, depending on healing, can result in scarring [75].

In some cases, corticosteroid injections may be used to minimize the inflammatory response [126] though it

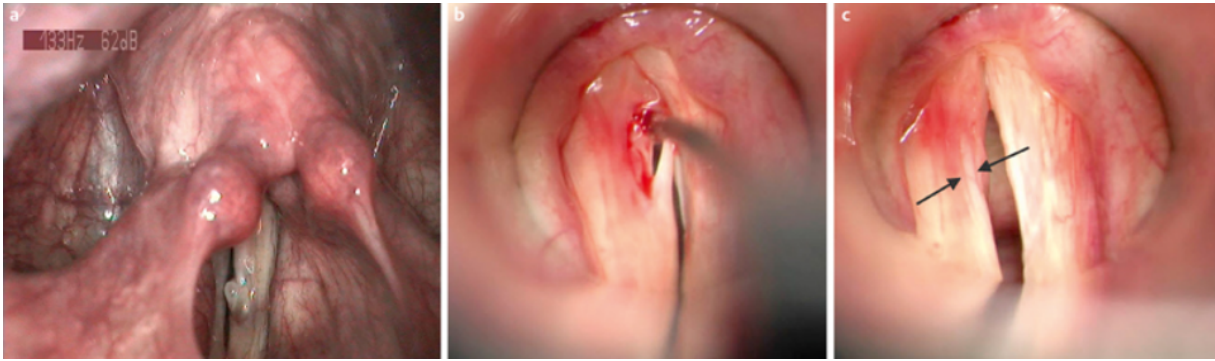


Figure 11: a, b and c) Vocal fold cyst and mucosal bridge after dissection

cannot be routinely recommended. The role of hepatocyte growth factor preparations, which have a very strong anti-fibrotic effect on vocal fold scarring has not yet been established [127]. Postoperative topical application of chemotherapeutic agents such as mitomycin C is strongly discouraged: mitomycin C exerts a damaging effect on the movable structures of the vocal fold [119].

### Diagnosis and management of existing scar tissue

Depending of the extent and infiltration of the lamina propria, the viscoelastic changes caused by scarring can result in irregular vibration of the vocal folds and incomplete adduction of the folds with resultant glottic insufficiency and air escape.

The resultant symptoms can vary greatly from patient to patient. Thus, a comprehensive voice analysis with detailed laryngoscopic and stroboscopic findings is necessary prior to any treatment. With the help of stroboscopy, typical free edge changes resulting from scarring can be detected. These alterations may be discrete or affect the entire vocal fold [3], [83].

However, the examiner must be aware that stroboscopy does not visualise the entire, surface of the vocal fold. The more lesions extend medially and inferiorly, the easier they can be overlooked [128]. If voice analysis points to an organ pathology and stroboscopy shows no direct evidence of functional dysphonia, we therefore recommend microlaryngoscopy to exclude pathology such as scars and mucosal bridges, hidden from stroboscopic view (Figure 11). Microlaryngoscopy reduces the risk of missing small scars and arriving at an incorrect diagnosis such as a functional problem or an aging voice [128], [129], [130], [131].

Surgical treatment for scars is extremely challenging. We recommend intensive voice therapy for up to 6 months before any consideration for surgery [132]. Many patients with scarred vocal folds changes have become accustomed to a counter-productive and inefficient voice and breathing technique. This is associated with an increased effort which results in not only the acoustic phenomenon of hoarseness, but also a limited capacity in spoken communication. Voice therapy can greatly help the faulty compensation patterns and therefore improve the voice.

Surgery of the scars can always be performed after a trial of such conservative treatment.

The goal of surgery should be to allow complete glottic closure and improve the vibration characteristics of the free edges. This can be achieved by augmentation of the vocal fold or thyroplasty [133], [134].

Scarring results in stiffening and loss of volume of the movable structures. Depending on its extent, different techniques can be used to ameliorate the situation. Local undermining procedures that remove the scar tissue from underneath are recommended as well as injections of various substances such as corticosteroids [109] or biocompatible materials [135], [136], [137], [138], [139], [140], [141]. Newer substances such as mesenchymal stem cells and growth factors [141], [142] can also be injected. In well-circumscribed scars, often appearing in the sulci vocales, special incision techniques or complete excision of the scar are can be performed [138]. Several different laser techniques can also be employed, most notably, pulsed dye laser [73], [143].

Unfortunately, due to the plethora of techniques and the fact that they are often repeated on combined, good evidence is lacking as to when to use which therapy [134]. Furthermore, post-interventional outcomes can only be reliably assessed one year later [131], [144]. With augmentation (for example, with autologous fat transfer) or thyroplasty, an improvement of voice often corresponds with a stroboscopic improvement of the vibrating free edge 3–6 months post-intervention [135].

### Postoperative wound healing

Postoperative wound healing follows a complex, overlapping sequence of defined stages [71]. This process can be disrupted by trauma or inflammation. The question is therefore, what postoperative measures can be taken to ensure optimal wound healing?

Although there is agreement that post-operative voice abuse has deleterious effects on healing, no consensus exists as to an optimal rehabilitation program [145]. Voice rest, together with avoiding coughing and throat clearing is usually recommended in the first few weeks [146], [147] but it remains unclear if complete voice rest is better than judicious voice use.

What is clear is that the longer a doctor orders voice rest, the less likely a patient will be compliant [148]. A middle

path of voice rest followed by gentle voice use is probably the most pragmatic option [149]. We recommend 3 days of complete voice rest followed by 4 days of gentle voice use. Whispering should only be done if the patient can master the technique of a “relaxed whisper”.

The role of specific voice exercises and whether they could affect wound healing is also unclear [145]. We recommend close cooperation with voice therapists, both before and after surgery. By sharing accurate information regarding the extent of the operative procedure the voice therapist can then devise a program leading to full voice rehabilitation.

In summary, however, the otolaryngologist remains ultimately responsible for the pre-/intra-/post-operative care of the patient, and as such, he cannot just delegate tasks to other disciplines. An otolaryngologist who focuses only on the surgical, intraoperative details will not provide optimal care to his patient [150], [151].

## Digression: Unilateral vocal fold palsy

Otolaryngologists often make the diagnosis of unilateral vocal fold palsy. The patient may have presented with voice changes, breathing or swallowing difficulties [152] but sometimes the patient has no symptoms at all.

There are many potential causes of unilateral vocal fold palsy including iatrogenic, traumatic, malignant, thoracic or systemic disease [153]. The potential risk of postoperative vocal cord paralysis, by a direct or indirect damage of the vagus or recurrent laryngeal nerve depends on the surgical procedure and technique [154]. For example, post-operative palsies following operations for esophageal cancer can be as high as 11%. The incidence of permanent postoperative vocal fold paralysis after thyroid surgery varies between 0.5% and 2.7% [155], [156].

In roughly a quarter of cases, no cause for the vocal fold palsy is found and patient therefore diagnosed with an idiopathic vocal fold palsy. These patients form a heterogeneous group and the majority show spontaneous improvement in less than a year [157].

As mentioned above, hoarseness is not the only feature of a unilateral vocal fold palsy. Associated problems such as increased breathlessness whilst speaking (speech dyspnea) or swallowing difficulties should be specifically sought and may require further investigation and treatment [158].

A thorough voice examination should be performed including voice diagnostics, flexible transnasal and rigid transoral laryngoscopy. Often, patients have increased muscle tension making an adequate transoral laryngoscopy difficult [9]. Stroboscopy is usually unhelpful in the setting of unilateral fold paresis combined with severe hoarseness and high speed video assessment is preferred [159], [160].

Unfortunately, no matter how accurate an assessment of vocal fold function is made, it is impossible to deduce

from paralyzed vocal fold position alone the location of the nerve damage [161], [162], [163].

After clinical examination, the first line investigation for unilateral fold paresis is imaging of the entire length of the recurrent laryngeal nerve with either contrast enhanced CT or MRI [164]. This can be supplemented with neck ultrasound to exclude malignant processes in the thyroid or cervical lymph nodes [165]. The preferred modality is the subject of debate, as is its timing and cost-benefit. Routine serological investigations are not indicated unless history and/or clinical examination have raised the suspicion of underlying disease [166].

The clinical use of electromyography (EMG) for evaluation of vocal fold paralysis is less useful than in palsies of the facial nerve. In contrast to facial nerve palsies, laryngeal electromyographic assessment provides little prognostic information [167]. Physiological laryngeal nerve recovery is highly complex and varied in terms of its functional outcome [161], [168].

Laryngeal EMG does however allow a clear distinction to be made between true paresis [169], [170], [171] and mimicking traumatic arytenoid subluxation or ankylosis [81]. The extent to which acquired arytenoid subluxation or ankylosis presents as an independent disease is debatable [172].

Once diagnosis and work up is completed, the goal of treatment should be to improve glottis closure in order to achieve better voice and less speech dyspnea. Also, breathing/swallowing problems and counter-productive compensation mechanisms should be addressed. Conservative treatment revolves around voice therapy, supplemented by physiotherapy when necessary. Surgical options include a variety of procedures designed to medialise the paretic vocal fold, especially useful when there is marked failure of glottic closure [173], [174]. Often a combination of voice therapy and surgical options is used.

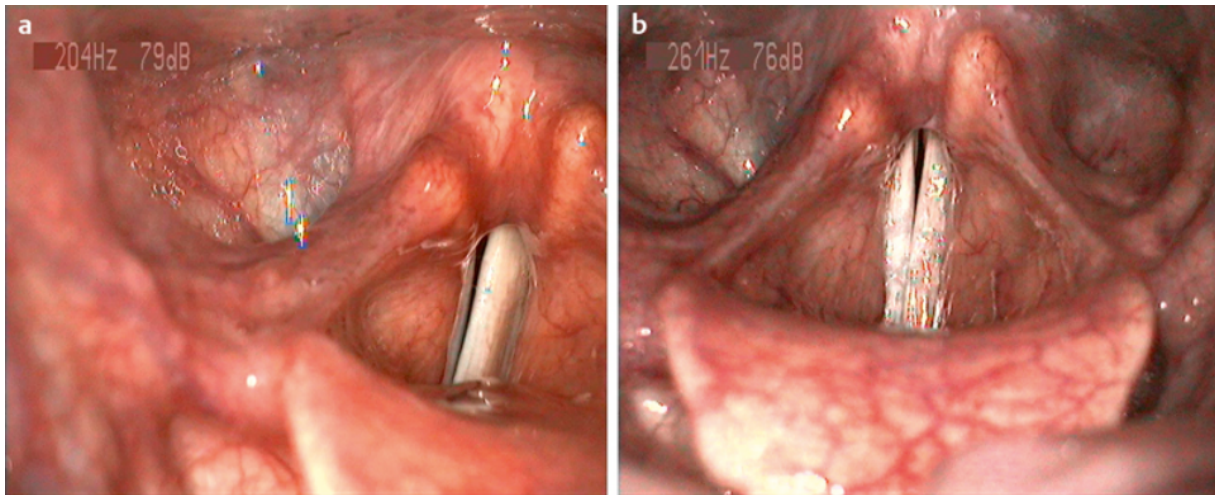
## Conservative measures

Voice therapy can afford both a subjective and objective improvement for patients. Early intervention by an experienced speech therapist prevents counterproductive, non-physiological habits from forming [175], [176]. As with much voice therapy, there is however a lack of good quality evidence as to which techniques are best, and no single therapy for unilateral vocal fold palsy can be recommended above another. The influence of so-called “soft-factors” such as patient motivation, rapport and cooperation is difficult to judge [176], [177], [178].

A further conservative technique is electrical stimulation of the damaged nerve. This is thought to help nerve regeneration and prevent muscle atrophy [179], [180], [181] by providing a customized stimulus current during phonation. The functional result is perhaps less easily judged than with voice therapy, and again good evidence of its effects is lacking.

Overall, many questions concerning conservative approaches remain unanswered. What is the goal of therapy? How long should therapy last? When should other,





**Figure 12:** a) Unilateral vocal fold paralysis with persistent insufficiency of glottal closure; b) Same patient with complete glottal closure, 18 months after vocal fold augmentation with hyaluronic acid

for example surgical, modalities be used? Could one not proceed directly to surgery?

The last question is particularly pertinent as many experts now recommend early intervention, even with only a mild glottis insufficiency, in order to prevent bad habits from forming. Medialisation procedures with absorbable injections can be performed even before voice therapy has begun. This affords a speedy improvement in voice [173], [182] and supports the speech therapists efforts [183], [184]. Reports of early surgical intervention following thoracic surgery have lent evidence to this approach [185], [186]. These early interventional successes cast doubt on the need for purely conservative initial therapies.

## Surgical interventions

Surgical interventions aim to adduct the paralyzed vocal fold to the midline. Three general techniques can be used: vocal fold augmentation, framework surgery (thyroplasty type 1) with or without arytenoid adduction, and operative re-innervation techniques [187], [188], [189], [190].

In recent years the growing literature attests to the increasing number of materials and techniques used to medialise the vocal fold [153], [191]. The advantages and disadvantages of each individual technique [192], [193] must be discussed with the patient in light of his particular complaints, and the appropriate treatment chosen. Mere assessment of the position of the paralyzed vocal fold and the resulting glottic insufficiency is not enough. The extent of denervation and its functional consequence must be assessed before choosing the appropriate intervention and even then, results are difficult to predict.

Vocal fold augmentation has become more popular and makes use of different injection materials of varying half-life and biocompatibility [194]. The technique is appropriate for mild to moderate glottic insufficiency caused either by paralysis or reduced excursion secondary to scarring or atrophy. The injection can only usefully augment the ligamentous portion in the anterior two thirds of the fold.

Large glottic insufficiencies, or those of the posterior third cannot be treated with injection augmentation. Neither can these posterior insufficiencies be treated well with a thyroplasty. Posterior problems need an arytenoid adduction [195], [196],

Vocal fold augmentation has the great advantage that, in experienced hands, it can be performed under local anesthetic in an outpatient setting [197]. Regardless of whether the access is transnasal, transoral or percutaneous, continuous assessment both by inspection and aurally can be made [198], [199] (Figure 12).

Rarely, for example due to a strong gag reflex, the injection must be performed under general anesthesia. This has the distinct disadvantage that the functional result cannot be immediately verified and therefore the amount and location of injection appropriately adjusted [182].

Furthermore, injections are, as all surgical interventions, not without complication. Nowadays, the safety profile of the injected material is very good. Biodegradable, nonimmunogenic materials are used and, despite repeated injections, are generally safe [124], [138]. The danger lies rather in injecting the correct amount and in the correct place. If Reinke's space is injected, the material will never be resorbed and this can result in marked hoarseness. Over injection can even lead to dyspnea and stridor. Abscess formation often infiltrating subglottically or extralaryngeally has also been reported [200].

For these reasons, when the glottic insufficiency is more than 3mm, thyroplasty type I is generally recommended. Various materials of various shapes can be used, but it should be remembered that complications from this procedure are far more frequent than with injections, up to 15% in a recent review article [201].

Complications of implants include postoperative swelling, bleeding and wound infection which can all potentially require operative revision or even tracheotomy. Procedure specific complications such as implant extrusion, mis-sizing or misplacement may also require a second operation. Furthermore, the consent process should explicitly

mention the possibility of no voice improvement, or even a worsening of the voice.

The choice of implant is largely at the surgeon's discretion. The functional results of implantation are difficult to predict even when the procedure is done under light sedation with endoscopic control. Even if laryngoscopy shows a good placement of the implant, an improvement in voice is not always found. Depth, position, shape and the material's properties together with the initial pathological findings all play a role.

Furthermore, despite implants being often regarded as giving a permanent improvement, it must be remembered that the larynx is an ever changing organ. Age related changes in tissue bulk, atrophy and strength can mean that long term functional results deteriorate.

In summary, injections and implantations should not be seen as exclusive modalities, but rather as complementary, each with its own strengths and limitations. The treatment of patients with vocal fold paresis often means repeated and varied interventions in order to achieve optimal results. The surgeon should thus be thoroughly familiar with the different techniques available.

## Future

The treatment of voice disorders is no longer restricted to just ENT surgeons, phoniatricians and voice therapists. Singing teachers, public speaker trainers, speech scientists and linguists all offer to help patients with voice problems. In this context, it remains paramount to have an expert knowledge of the anatomy, physiology and function of the voice and the multitude of therapies available. In the future, an objective, critical approach will lead to the accumulation of good quality data and allow proper evidence based treatment of the individual patient.

## Notes

## Competing interests

The author declares that he has no competing interests.

## References

- Zeitels SM, Healy GB. Laryngology and phonosurgery. *N Engl J Med*. 2003 Aug;349(9):882-92. DOI: 10.1056/NEJMra035148
- Cohen SM, Kim J, Roy N, Asche C, Courey M. The impact of laryngeal disorders on work-related dysfunction. *Laryngoscope*. 2012 Jul;122(7):1589-94. DOI: 10.1002/lary.23197
- Altman KW. Vocal fold masses. *Otolaryngol Clin North Am*. 2007 Oct;40(5):1091-108, viii. DOI: 10.1016/j.otc.2007.05.011
- Sataloff RT. G. Paul Moore Lecture. Rational thought: the impact of voice science upon voice care. *J Voice*. 1995 Sep;9(3):215-34.
- Johns MM. Update on the etiology, diagnosis, and treatment of vocal fold nodules, polyps, and cysts. *Curr Opin Otolaryngol Head Neck Surg*. 2003 Dec;11(6):456-61.
- Roy N, Merrill RM, Gray SD, Smith EM. Voice disorders in the general population: prevalence, risk factors, and occupational impact. *Laryngoscope*. 2005 Nov;115(11):1988-95. DOI: 10.1097/01.mlg.0000179174.32345.41
- Hantzakos A, Remacle M, Dikkers FG, Degols JC, Delos M, Friedrich G, Giovanni A, Rasmussen N. Exudative lesions of Reinke's space: a terminology proposal. *Eur Arch Otorhinolaryngol*. 2009 Jun;266(6):869-78. DOI: 10.1007/s00405-008-0863-x
- Oates J, Winkworth A. Current knowledge, controversies and future directions in hyperfunctional voice disorders. *Int J Speech Lang Pathol*. 2008;10(4):267-77. DOI: 10.1080/17549500802140153
- Sulica L. Hoarseness. *Arch Otolaryngol Head Neck Surg*. 2011 Jun;137(6):616-9. DOI: 10.1001/archoto.2011.80
- Gray SD, Hammond E, Hanson DF. Benign pathologic responses of the larynx. *Ann Otol Rhinol Laryngol*. 1995 Jan;104(1):13-8.
- Schneider B, Bigenzahn W. *Stimmdiagnostik: Ein Leitfaden für die Praxis*. Vienna: Springer; 2007.
- Dejonckere PH, Bradley P, Clemente P, Cornut G, Crevier-Buchman L, Friedrich G, Van De Heyning P, Remacle M, Woisard V; Committee on Phoniatrics of the European Laryngological Society (ELS). A basic protocol for functional assessment of voice pathology, especially for investigating the efficacy of (phonosurgical) treatments and evaluating new assessment techniques. Guideline elaborated by the Committee on Phoniatrics of the European Laryngological Society (ELS). *Eur Arch Otorhinolaryngol*. 2001 Feb;258(2):77-82.
- Nawka T, Wiesmann U, Gonnermann U. Validierung des Voice Handicap Index (VHI) in der deutschen Fassung [Validation of the German version of the Voice Handicap Index]. *HNO*. 2003 Nov;51(11):921-30. DOI: 10.1007/s00106-003-0909-8
- Nawka T, Verdonck-de Leeuw IM, De Bodt M, Guimaraes I, Holmberg EB, Rosen CA, Schindler A, Woisard V, Whurr R, Konerding U. Item reduction of the voice handicap index based on the original version and on European translations. *Folia Phoniatr Logop*. 2009;61(1):37-48. DOI: 10.1159/000200767
- Carding PN, Steen IN, Webb A, MacKenzie K, Deary IJ, Wilson JA. The reliability and sensitivity to change of acoustic measures of voice quality. *Clin Otolaryngol Allied Sci*. 2004 Oct;29(5):538-44. DOI: 10.1111/j.1365-2273.2004.00846.x
- Carding PN, Wilson JA, MacKenzie K, Deary IJ. Measuring voice outcomes: state of the science review. *J Laryngol Otol*. 2009 Aug;123(8):823-9. DOI: 10.1017/S0022215109005398
- Ptok M, Schwemmler C, Iven C, Jessen M, Nawka T. Zur auditiven Bewertung der Stimmqualität [On the auditory evaluation of voice quality]. *HNO*. 2006 Oct;54(10):793-802. DOI: 10.1007/s00106-005-1310-6
- Hirano M. *Clinical Examination of Voice*. Wien, New York: Springer; 1981.
- Wendler J, Seidner W, Eysholdt U. *Lehrbuch der Phoniatrie und Pädaudiologie*. Stuttgart: Thieme; 2005.
- Nawka T, Wirth G. *Stimmstörungen: Für Ärzte, Logopäden, Sprachheilpädagogen und Sprechwissenschaftler*. Köln: Dt. Ärzte-Verl.; 2008.
- Carding PN, Steen IN, Webb A, MacKenzie K, Deary IJ, Wilson JA. The reliability and sensitivity to change of acoustic measures of voice quality. *Clin Otolaryngol Allied Sci*. 2004 Oct;29(5):538-44. DOI: 10.1111/j.1365-2273.2004.00846.x

22. Friedrich G, Dejonckere PH. Das Stimm diagnostik-Protokoll der European Laryngological Society (ELS) – erste Erfahrungen im Rahmen einer Multizenterstudie [The voice evaluation protocol of the European Laryngological Society (ELS) – first results of a multicenter study]. *Laryngorhinootologie*. 2005 Oct;84(10):744-52. DOI: 10.1055/s-2005-861450
23. Dejonckere PH, Remacle M, Fresnel-Elbaz E, Woisard V, Crevier L, Millet B. Reliability and clinical relevance of perceptual evaluation of pathological voices. *Rev Laryngol Otol Rhinol (Bord)*. 1998;119(4):247-8.
24. DeJonckere PH, van Wijck I, Speyer R. Efficacy of voice therapy assessed with the Voice Range Profile (Phonetogram). *Rev Laryngol Otol Rhinol (Bord)*. 2003;124(5):285-9.
25. Schindler A, Bottero A, Capaccio P, Ginocchio D, Adorni F, Ottaviani F. Vocal improvement after voice therapy in unilateral vocal fold paralysis. *J Voice*. 2008 Jan;22(1):113-8. DOI: 10.1016/j.jvoice.2006.08.004
26. Stajner-Katusić S, Horga D, Zrinski KV. A longitudinal study of voice before and after phonosurgery for removal of a polyp. *Clin Linguist Phon*. 2008 Oct-Nov;22(10-11):857-63. DOI: 10.1080/02699200802130813
27. Berke GS, Gerratt BR, Hanson DG. An acoustic analysis of the effects of surgical therapy on voice quality. *Otolaryngol Head Neck Surg*. 1983 Oct;91(5):502-8.
28. Schutte HK, Seidner W. Recommendation by the Union of European Phoniatrians (UEP): standardizing voice area measurement/phonetography. *Folia Phoniatri (Basel)*. 1983;35(6):286-8.
29. Baken RJ, Orlikoff RF. *Clinical Measurement of Speech & Voice*. 2nd ed. New York: Singular Publ.; 1999.
30. Siupsinskiene N, Lycke H. Effects of vocal training on singing and speaking voice characteristics in vocally healthy adults and children based on choral and nonchoral data. *J Voice*. 2011 Jul;25(4):e177-89. DOI: 10.1016/j.jvoice.2010.03.010
31. Hacki T. Tonhöhen- und Intensitätsbefunde bei Stimmgeübten. Vergleichende Sprechstimmfeld-, Rufstimmfeld- und Singstimmfeldmessung [Vocal capabilities of nonprofessional singers evaluated by measurement and superimposition of their speaking, shouting and singing voice range profiles]. *HNO*. 1999 Sep;47(9):809-15.
32. Schneider B, Zumtobel M, Prettenhofer W, Aichstill B, Jocher W. Normative voice range profiles in vocally trained and untrained children aged between 7 and 10 years. *J Voice*. 2010 Mar;24(2):153-60. DOI: 10.1016/j.jvoice.2008.07.007
33. Hakkesteeft MM, Brocaar MP, Wieringa MH. The applicability of the dysphonia severity index and the voice handicap index in evaluating effects of voice therapy and phonosurgery. *J Voice*. 2010 Mar;24(2):199-205. DOI: 10.1016/j.jvoice.2008.06.007
34. Hakkesteeft MM, Brocaar MP, Wieringa MH, Feenstra L. The relationship between perceptual evaluation and objective multiparametric evaluation of dysphonia severity. *J Voice*. 2008 Mar;22(2):138-45. DOI: 10.1016/j.jvoice.2006.09.010
35. Dejonckere P, Schoentgen J, Giordano A, Fraj S, Bocchi L, Manfredi C. Validity of jitter measures in non-quasi-periodic voices. Part I: perceptual and computer performances in cycle pattern recognition. *Logoped Phoniatri Vocol*. 2011 Jul;36(2):70-7. DOI: 10.3109/14015439.2011.578078
36. Werth K, Voigt D, Döllinger M, Eysholdt U, Lohscheller J. Clinical value of acoustic voice measures: a retrospective study. *Eur Arch Otorhinolaryngol*. 2010 Aug;267(8):1261-71. DOI: 10.1007/s00405-010-1214-2
37. Fleischer S, Hess M. Systematischer Untersuchungsablauf bei der Videolaryngoskopie und Stroboskopie [Systematic investigation technique in videolaryngoscopy and stroboscopy]. *HNO*. 2003 Feb;51(2):160-7. DOI: 10.1007/s00106-002-0796-4
38. Fleischer S, Hess M. Die Bedeutung der Stroboskopie in der laryngologischen Praxis [The significance of videostroboscopy in laryngological practice]. *HNO*. 2006 Aug;54(8):628-34. DOI: 10.1007/s00106-006-1437-0
39. Boehme G, Gross M. *Stroboscopy*. London, Philadelphia: Wiley; 2005.
40. Nawka T, Konerding U. The interrater reliability of stroboscopy evaluations. *J Voice*. 2012 Nov;26(6):812.e1-10. DOI: 10.1016/j.jvoice.2011.09.009
41. Derkay CS, Wiatrak B. Recurrent respiratory papillomatosis: a review. *Laryngoscope*. 2008 Jul;118(7):1236-47. DOI: 10.1097/MLG.0b013e31816a7135
42. Dedo HH, Yu KC. CO(2) laser treatment in 244 patients with respiratory papillomas. *Laryngoscope*. 2001 Sep;111(9):1639-44. DOI: 10.1097/00005537-200109000-00028
43. Mau T. Diagnostic evaluation and management of hoarseness. *Med Clin North Am*. 2010 Sep;94(5):945-60. DOI: 10.1016/j.mcna.2010.05.010
44. Steinberg BM, Topp WC, Schneider PS, Abramson AL. Laryngeal papillomavirus infection during clinical remission. *N Engl J Med*. 1983 May;308(21):1261-4. DOI: 10.1056/NEJM198305263082104
45. Pasquale K, Wiatrak B, Woolley A, Lewis L. Microdebrider versus CO2 laser removal of recurrent respiratory papillomas: a prospective analysis. *Laryngoscope*. 2003 Jan;113(1):139-43. DOI: 10.1097/00005537-200301000-00026
46. Zeitels SM, Casiano RR, Gardner GM, Hogikyan ND, Koufman JA, Rosen CA; Voice and Swallowing Committee, American Academy of Otolaryngology–Head and Neck Surgery. Management of common voice problems: Committee report. *Otolaryngol Head Neck Surg*. 2002 Apr;126(4):333-48.
47. Nawka T, Hosemann W. Surgical procedures for voice restoration. *GMS Curr Top Otorhinolaryngol Head Neck Surg*. 2005;4:Doc14. Available from: <http://www.egms.de/en/journals/cto/2005-4/cto000020.shtml>
48. Mortensen M, Woo P. An underreported complication of laryngeal microdebrider: vocal fold web and granuloma: a case report. *Laryngoscope*. 2009 Sep;119(9):1848-50. DOI: 10.1002/lary.20563
49. Dikkers FG. Treatment of recurrent respiratory papillomatosis with microsurgery in combination with intralesional cidofovir—a prospective study. *Eur Arch Otorhinolaryngol*. 2006 May;263(5):440-3. DOI: 10.1007/s00405-005-1013-3
50. Mikolajczak S, Quante G, Weissenborn S, Wafaisade A, Wieland U, Lüers JC, Klussmann JP, Beutner D. The impact of cidofovir treatment on viral loads in adult recurrent respiratory papillomatosis. *Eur Arch Otorhinolaryngol*. 2012 Dec;269(12):2543-8. DOI: 10.1007/s00405-012-2103-7
51. Bielecki I, Mniszek J, Cofala M. Intralesional injection of cidofovir for recurrent respiratory papillomatosis in children. *Int J Pediatr Otorhinolaryngol*. 2009 May;73(5):681-4. DOI: 10.1016/j.ijporl.2009.01.002
52. Waldfahrer F. Lokale Applikation von Cidofovir bei Larynxpapillomatose: aktuelle Hinweise und Warnungen. *HNO Informationen*. 2011;36(4):156.



53. Gillen D. Direct healthcare professional communication regarding serious adverse reactions following off-label use of Vistide.[letter]. Vistide DHPC letter. 2011. Available from: <http://www.cbgmeb.nl/NR/rdonlyres/FFB51936-EC22-4180-A213-9E907F06A774/011.pdf>
54. Donne AJ, Hampson L, He XT, Day PJ, Salway F, Rothera MP, Homer JJ, Hampson IN. Potential risk factors associated with the use of cidofovir to treat benign human papillomavirus-related disease. *Antivir Ther (Lond)*. 2009;14(7):939-52. DOI: 10.3851/IMP1421
55. Man LX, Statham MM, Rosen CA. Mucosal bridge and pitting of the true vocal fold: an unusual complication of cidofovir injection. *Ann Otol Rhinol Laryngol*. 2010 Apr;119(4):236-8.
56. Tjon Pian Gi RE, Dietz A, Djukic V, Eckel HE, Friedrich G, Golusinski W, Hantzakos A, Lawson G, Remacle M, Rihkanen H, Dikkers FG. Treatment of recurrent respiratory papillomatosis and adverse reactions following off-label use of cidofovir (Vistide®). *Eur Arch Otorhinolaryngol*. 2012 Feb;269(2):361-2. DOI: 10.1007/s00405-011-1804-7
57. Nagel S, Busch C, Blankenburg T, Schütte W. Behandlung der respiratorischen Papillomatose–Kasuistik zur systemischen Therapie mit Bevacizumab [Treatment of respiratory papillomatosis—a case report on systemic treatment with bevacizumab]. *Pneumologie*. 2009 Jul;63(7):387-9. DOI: 10.1055/s-0029-1214714
58. Zeitels SM, Lopez-Guerra G, Burns JA, Lutch M, Friedman AM, Hillman RE. Microlaryngoscopic and office-based injection of bevacizumab (Avastin) to enhance 532-nm pulsed KTP laser treatment of glottal papillomatosis. *Ann Otol Rhinol Laryngol Suppl*. 2009 Sep;201:1-13.
59. Zeitels SM, Barbu AM, Landau-Zemer T, Lopez-Guerra G, Burns JA, Friedman AD, Freeman MW, Halvorsen YD, Hillman RE. Local injection of bevacizumab (Avastin) and angiolytic KTP laser treatment of recurrent respiratory papillomatosis of the vocal folds: a prospective study. *Ann Otol Rhinol Laryngol*. 2011 Oct;120(10):627-34.
60. Förster G, Boltze C, Seidel J, Pawlita M, Müller A. Juvenile Larynxpapillomatose–Impfung mit dem polyvalenten Spaltimpfstoff Gardasil [Juvenile laryngeal papillomatosis–immunisation with the polyvalent vaccine gardasil]. *Laryngorhinootologie*. 2008 Nov;87(11):796-9. DOI: 10.1055/s-2008-1077527
61. Pawlita M, Gissmann L. Rekurrenzierende respiratorische Papillomatose: Indikation für HPV-Vakzination [Recurrent respiratory papillomatosis: indication for HPV vaccination?]. *Dtsch Med Wochenschr*. 2009 Apr;134 Suppl 2:S100-2. DOI: 10.1055/s-0029-1220219
62. Goon P, Sonnex C, Jani P, Stanley M, Sudhoff H. Recurrent respiratory papillomatosis: an overview of current thinking and treatment. *Eur Arch Otorhinolaryngol*. 2008 Feb;265(2):147-51. DOI: 10.1007/s00405-007-0546-z
63. Wallis L, Jackson-Menaldi C, Holland W, Giraldo A. Vocal fold nodule vs. vocal fold polyp: answer from surgical pathologist and voice pathologist point of view. *J Voice*. 2004 Mar;18(1):125-9. DOI: 10.1016/j.jvoice.2003.07.003
64. Martins RH, Defaveri J, Domingues MA, de Albuquerque e Silva R. Vocal polyps: clinical, morphological, and immunohistochemical aspects. *J Voice*. 2011 Jan;25(1):98-106. DOI: 10.1016/j.jvoice.2009.05.002
65. Thibeault SL, Merrill RM, Roy N, Gray SD, Smith EM. Occupational risk factors associated with voice disorders among teachers. *Ann Epidemiol*. 2004 Nov;14(10):786-92. DOI: 10.1016/j.annepidem.2004.03.004
66. Srirompotong S, Saeseow P, Vatanasapt P. Small vocal cord polyps: completely resolved with conservative treatment. *Southeast Asian J Trop Med Public Health*. 2004 Mar;35(1):169-71.
67. Dworkin JP. Laryngitis: types, causes, and treatments. *Otolaryngol Clin North Am*. 2008 Apr;41(2):419-36, ix. DOI: 10.1016/j.otc.2007.11.011
68. Branski RC, Saltman B, Sulica L, Szeto H, Duflo S, Felsen D, Kraus DH. Cigarette smoke and reactive oxygen species metabolism: implications for the pathophysiology of Reinke's edema. *Laryngoscope*. 2009 Oct;119(10):2014-8. DOI: 10.1002/lary.20592
69. Raabe J, Pascher W. Das Reinke-Ödem: Eine Untersuchung zu Fragen der Ätiologie, der Prognose und der Wirksamkeit therapeutischer Interventionen [Reinke's edema: an investigation of questions related to etiology, prognosis and the effectiveness of therapeutic methods]. *Laryngorhinootologie*. 1999 Feb;78(2):97-102. DOI: 10.1055/s-2007-996839
70. Zeitels SM, Hillman RE, Bunting GW, Vaughn T. Reinke's edema: phonatory mechanisms and management strategies. *Ann Otol Rhinol Laryngol*. 1997 Jul;106(7 Pt 1):533-43.
71. Allen J. Cause of vocal fold scar. *Curr Opin Otolaryngol Head Neck Surg*. 2010 Dec;18(6):475-80. DOI: 10.1097/M00.0b013e32833fecd1
72. Nawka T, Hosemann W. Gestörte Stimme. Chirurgische Verfahren [Voice disorder. Surgical procedures]. *Laryngorhinootologie*. 2005 May;84 Suppl 1:S201-12. DOI: 10.1055/s-2005-861177
73. Martínez Arias A, Remacle M, Lawson G. Treatment of vocal fold scar by carbon dioxide laser and collagen injection: retrospective study on 12 patients. *Eur Arch Otorhinolaryngol*. 2010 Sep;267(9):1409-14. DOI: 10.1007/s00405-010-1231-1
74. Benninger MS, Alessi D, Archer S, Bastian R, Ford C, Koufman J, Sataloff RT, Spiegel JR, Woo P. Vocal fold scarring: current concepts and management. *Otolaryngol Head Neck Surg*. 1996 Nov;115(5):474-82.
75. Sataloff RT, Hawkshaw MJ, Divi V, Heman-Ackah YD. Voice surgery. *Otolaryngol Clin North Am*. 2007 Oct;40(5):1151-83, ix. DOI: 10.1016/j.otc.2007.05.015
76. Desloge RB, Zeitels SM. Endolaryngeal microsurgery at the anterior glottal commissure: controversies and observations. *Ann Otol Rhinol Laryngol*. 2000 Apr;109(4):385-92.
77. Bouchayer M, Cornut G. Microsurgery for benign lesions of the vocal folds. *Ear Nose Throat J*. 1988 Jun;67(6):446-9, 452-4, 456-64 passim.
78. Rosen CA, Gartner-Schmidt J, Hathaway B, Simpson CB, Postma GN, Courey M, Sataloff RT. A nomenclature paradigm for benign midmembranous vocal fold lesions. *Laryngoscope*. 2012 Jun;122(6):1335-41. DOI: 10.1002/lary.22421
79. Mortensen M, Schaberg M, Woo P. Diagnostic contributions of videolaryngostroboscopy in the pediatric population. *Arch Otolaryngol Head Neck Surg*. 2010 Jan;136(1):75-9. DOI: 10.1001/archoto.2009.209
80. Martins RH, Santana MF, Tavares EL. Vocal cysts: clinical, endoscopic, and surgical aspects. *J Voice*. 2011 Jan;25(1):107-10. DOI: 10.1016/j.jvoice.2009.06.008
81. Rosen CA, Murry T. Nomenclature of voice disorders and vocal pathology. *Otolaryngol Clin North Am*. 2000 Oct;33(5):1035-46.
82. Rubin AD, Gherson S, Sataloff RT. Vocal fold nodules. *Ear Nose Throat J*. 2004 Jul;83(7):450.
83. Sataloff RT, Spiegel JR, Hawkshaw MJ. Stroboscopic results and clinical value. *Ann Otol Rhinol Laryngol*. 1991 Sep;100(9 Pt 1):725-7.

84. Smolander S, Huttunen K. Voice problems experienced by Finnish comprehensive school teachers and realization of occupational health care. *Logoped Phoniatr Vocol*. 2006;31(4):166-71. DOI: 10.1080/14015430600576097
85. Martins RH, Defaveri J, Custódio Domingues MA, de Albuquerque E Silva R, Fabro A. Vocal fold nodules: morphological and immunohistochemical investigations. *J Voice*. 2010 Sep;24(5):531-9. DOI: 10.1016/j.jvoice.2009.01.002
86. Marcotullio D, Magliulo G, Pietrunti S, Suriano M. Exudative laryngeal diseases of Reinke's space: a clinicohistopathological framing. *J Otolaryngol*. 2002 Dec;31(6):376-80.
87. Dikkers FG, Nikkels PG. Lamina propria of the mucosa of benign lesions of the vocal folds. *Laryngoscope*. 1999 Oct;109(10):1684-9. DOI: 10.1097/00005537-199910000-00025
88. Pedersen M, McGlashan J. Surgical versus non-surgical interventions for vocal cord nodules. *Cochrane Database Syst Rev*. 2012;6:CD001934. DOI: 10.1002/14651858.CD001934.pub2
89. Behrman A, Rutledge J, Hembree A, Sheridan S. Vocal hygiene education, voice production therapy, and the role of patient adherence: a treatment effectiveness study in women with phonotrauma. *J Speech Lang Hear Res*. 2008 Apr;51(2):350-66. DOI: 10.1044/1092-4388(2008)026
90. Leonard R. Voice therapy and vocal nodules in adults. *Curr Opin Otolaryngol Head Neck Surg*. 2009 Dec;17(6):453-7. DOI: 10.1097/M00.0b013e3283317fd2
91. Holmberg EB, Hillman RE, Hammarberg B, Södersten M, Doyle P. Efficacy of a behaviorally based voice therapy protocol for vocal nodules. *J Voice*. 2001 Sep;15(3):395-412. DOI: 10.1016/S0892-1997(01)00041-8
92. Benninger MS. Microdissection or microspot CO2 laser for limited vocal fold benign lesions: a prospective randomized trial. *Laryngoscope*. 2000 Feb;110(2 Pt 2 Suppl 92):1-17. DOI: 10.1097/00005537-200002001-00001
93. Benninger MS. Laser surgery for nodules and other benign laryngeal lesions. *Curr Opin Otolaryngol Head Neck Surg*. 2009 Dec;17(6):440-4. DOI: 10.1097/M00.0b013e3283317cae
94. Rosen CA, Lombard LE, Murry T. Acoustic, aerodynamic, and videostroboscopic features of bilateral vocal fold lesions. *Ann Otol Rhinol Laryngol*. 2000 Sep;109(9):823-8.
95. Murano E, Hosako-Naito Y, Tayama N, Oka T, Miyaji M, Kumada M, Niimi S. Bamboo node: primary vocal fold lesion as evidence of autoimmune disease. *J Voice*. 2001 Sep;15(3):441-50. DOI: 10.1016/S0892-1997(01)00044-3
96. Hilgert E, Toleti B, Kruger K, Nejedlo I. Hoarseness due to bamboo nodes in patients with autoimmune diseases: a review of literature. *J Voice*. 2008 May;22(3):343-50. DOI: 10.1016/j.jvoice.2006.10.009
97. Immerman S, Sulica L. Bamboo nodes. *Otolaryngol Head Neck Surg*. 2007 Jul;137(1):162-3. DOI: 10.1016/j.otohns.2006.12.027
98. Schwemmler C, Kreipe HH, Witte T, Ptok M. Bamboo nodes associated with mixed connective tissue disease as a cause of hoarseness. *Rheumatol Int*. 2013 Mar;33(3):777-81. DOI: 10.1007/s00296-011-2214-2
99. Storck C, Brockmann M, Zimmermann E, Nekahm-Heis D, Zorowka PG. Laryngeales Kontaktgranulom. *Ätiologie, Symptomatik, Diagnose und Therapie [Laryngeal granuloma. Aetiology, clinical signs, diagnostic procedures, and treatment]*. *HNO*. 2009 Oct;57(10):1075-80. DOI: 10.1007/s00106-008-1778-y
100. Mans EJ, Kühn AG, Lamprecht-Dinnesen A. Persönlichkeitsmerkmale von Patienten mit Kontaktgranulom [Personality markers of patients with vocal cord granuloma]. *Laryngorhinootologie*. 1993 May;72(5):225-30. DOI: 10.1055/s-2007-997889
101. Carroll TL, Gartner-Schmidt J, Statham MM, Rosen CA. Vocal process granuloma and glottal insufficiency: an overlooked etiology? *Laryngoscope*. 2010 Jan;120(1):114-20. DOI: 10.1002/lary.20656
102. Devaney KO, Rinaldo A, Ferlito A. Vocal process granuloma of the larynx-recognition, differential diagnosis and treatment. *Oral Oncol*. 2005 Aug;41(7):666-9. DOI: 10.1016/j.oraloncology.2004.11.002
103. Benjamin B, Croxson G. Vocal cord granulomas. *Ann Otol Rhinol Laryngol*. 1985 Nov-Dec;94(6 Pt 1):538-41.
104. Ylitalo R, Lindestad PA. A retrospective study of contact granuloma. *Laryngoscope*. 1999 Mar;109(3):433-6.
105. Havas TE, Priestley J, Lowinger DS. A management strategy for vocal process granulomas. *Laryngoscope*. 1999 Feb;109(2 Pt 1):301-6.
106. Sieron J, Johannsen HS. Das Kontaktgranulom: Symptomatik-Ätiologie-Diagnostik-Therapie [Contact granuloma: symptoms, etiology, diagnosis, therapy]. *Laryngorhinootologie*. 1992 Apr;71(4):193-7. DOI: 10.1055/s-2007-997276
107. Hoffman HT, Overholt E, Karnell M, McCulloch TM. Vocal process granuloma. *Head Neck*. 2001 Dec;23(12):1061-74.
108. Damrose EJ, Damrose JF. Botulinum toxin as adjunctive therapy in refractory laryngeal granuloma. *J Laryngol Otol*. 2008 Aug;122(8):824-8. DOI: 10.1017/S0022215107000710
109. Mortensen M, Woo P. Office steroid injections of the larynx. *Laryngoscope*. 2006 Oct;116(10):1735-9. DOI: 10.1097/01.mlg.0000231455.19183.8c
110. Sun GB, Sun N, Tang HH, Zhu QB, Wen W, Zheng HL. Zinc sulfate therapy of vocal process granuloma. *Eur Arch Otorhinolaryngol*. 2012 Sep;269(9):2087-90. DOI: 10.1007/s00405-012-1971-1
111. Kiese-Himmel C, Kruse E. Ein Follow-up von Patienten mit laryngealem Kontaktgranulom [Follow-up of patients with laryngeal contact granuloma]. *HNO*. 1997 May;45(5):389-95.
112. Santos PM, Afrassabi A, Weymuller EA Jr. Risk factors associated with prolonged intubation and laryngeal injury. *Otolaryngol Head Neck Surg*. 1994 Oct;111(4):453-9.
113. Drosnes DL, Zwillenberg DA. Laryngeal granulomatous polyp after short-term intubation of a child. *Ann Otol Rhinol Laryngol*. 1990 Mar;99(3 Pt 1):183-6.
114. Pontes P, De Biase N, Kyriillos L, Pontes A. Importance of glottic configuration in the development of posterior laryngeal granuloma. *Ann Otol Rhinol Laryngol*. 2001 Aug;110(8):765-9.
115. Lemos EM, Sennes LU, Imamura R, Tsuji DH. Vocal process granuloma: clinical characterization, treatment and evolution. *Braz J Otorhinolaryngol*. 2005 Jul-Aug;71(4):494-8. DOI: 10.1590/S0034-72992005000400016
116. Wang CP, Ko JY, Wang YH, Hu YL, Hsiao TY. Vocal process granuloma - A result of long-term observation in 53 patients. *Oral Oncol*. 2009 Sep;45(9):821-5. DOI: 10.1016/j.oraloncology.2009.01.008
117. Martins RH, Gonçalves TM, Neves DS, Fracalossi TA, Tavares EL, Moretti-Ferreira D. Sulcus vocalis: evidence for autosomal dominant inheritance. *Genet Mol Res*. 2011;10(4):3163-8. DOI: 10.4238/2011.December.19.5
118. Hansen JK, Thibeault SL. Current understanding and review of the literature: vocal fold scarring. *J Voice*. 2006 Mar;20(1):110-20. DOI: 10.1016/j.jvoice.2004.12.005

119. Branski RC, Verdolini K, Sandulache V, Rosen CA, Hebda PA. Vocal fold wound healing: a review for clinicians. *J Voice*. 2006 Sep;20(3):432-42. DOI: 10.1016/j.jvoice.2005.08.005
120. Yan Y, Olszewski AE, Hoffman MR, Zhuang P, Ford CN, Dailey SH, Jiang JJ. Use of lasers in laryngeal surgery. *J Voice*. 2010 Jan;24(1):102-9. DOI: 10.1016/j.jvoice.2008.09.006
121. Zeitels SM. Laser versus cold instruments for microlaryngoscopic surgery. *Laryngoscope*. 1996 May;106(5 Pt 1):545-52.
122. Hörmann K, Baker-Schreyer A, Keilmann A, Biermann G. Functional results after CO2 laser surgery compared with conventional phonosurgery. *J Laryngol Otol*. 1999 Feb;113(2):140-4.
123. Schindler A, Palonta F, Preti G, Ottaviani F, Schindler O, Cavalot AL. Voice quality after carbon dioxide laser and conventional surgery for T1A glottic carcinoma. *J Voice*. 2004 Dec;18(4):545-50. DOI: 10.1016/j.jvoice.2004.03.001
124. Schwartz SR, Cohen SM, Dailey SH, Rosenfeld RM, Deutsch ES, Gillespie MB, Granieri E, Hapner ER, Kimball CE, Krouse HJ, McMurray JS, Medina S, O'Brien K, Ouellette DR, Messinger-Rapport BJ, Stachler RJ, Strode S, Thompson DM, Stemple JC, Willging JP, Cowley T, McCoy S, Bernad PG, Patel MM. Clinical practice guideline: hoarseness (dysphonia). *Otolaryngol Head Neck Surg*. 2009 Sep;141(3 Suppl 2):S1-S31. DOI: 10.1016/j.otohns.2009.06.744
125. Johns MM, Garrett CG, Hwang J, Ossoff RH, Courey MS. Quality-of-life outcomes following laryngeal endoscopic surgery for non-neoplastic vocal fold lesions. *Ann Otol Rhinol Laryngol*. 2004 Aug;113(8):597-601.
126. Mortensen M. Laryngeal steroid injection for vocal fold scar. *Curr Opin Otolaryngol Head Neck Surg*. 2010 Dec;18(6):487-91. DOI: 10.1097/M00.0b013e32833fe112
127. Suehiro A, Hirano S, Kishimoto Y, Tateya I, Rousseau B, Ito J. Effects of basic fibroblast growth factor on rat vocal fold fibroblasts. *Ann Otol Rhinol Laryngol*. 2010 Oct;119(10):690-6.
128. Welham NV, Dailey SH, Ford CN, Bless DM. Voice handicap evaluation of patients with pathologic sulcus vocalis. *Ann Otol Rhinol Laryngol*. 2007 Jun;116(6):411-7.
129. Poels PJ, de Jong FI, Schutte HK. Consistency of the preoperative and intraoperative diagnosis of benign vocal fold lesions. *J Voice*. 2003 Sep;17(3):425-33.
130. Dailey SH, Spanou K, Zeitels SM. The evaluation of benign glottic lesions: rigid telescopic stroboscopy versus suspension microlaryngoscopy. *J Voice*. 2007 Jan;21(1):112-8. DOI: 10.1016/j.jvoice.2005.09.006
131. Dailey SH, Ford CN. Surgical management of sulcus vocalis and vocal fold scarring. *Otolaryngol Clin North Am*. 2006 Feb;39(1):23-42. DOI: 10.1016/j.otc.2005.10.012
132. Rosen CA. Vocal fold scar: evaluation and treatment. *Otolaryngol Clin North Am*. 2000 Oct;33(5):1081-6.
133. Su CY, Tsai SS, Chiu JF, Cheng CA. Medialization laryngoplasty with strap muscle transposition for vocal fold atrophy with or without sulcus vocalis. *Laryngoscope*. 2004 Jun;114(6):1106-12. DOI: 10.1097/00005537-200406000-00028
134. Welham NV, Choi SH, Dailey SH, Ford CN, Jiang JJ, Bless DM. Prospective multi-arm evaluation of surgical treatments for vocal fold scar and pathologic sulcus vocalis. *Laryngoscope*. 2011 Jun;121(6):1252-60. DOI: 10.1002/lary.21780
135. Sataloff RT. Autologous fat implantation for vocal fold scar. *Curr Opin Otolaryngol Head Neck Surg*. 2010 Dec;18(6):503-6. DOI: 10.1097/M00.0b013e32833f8c21
136. Sataloff RT, Spiegel JR, Hawkshaw M, Rosen DC, Heuer RJ. Autologous fat implantation for vocal fold scar: a preliminary report. *J Voice*. 1997 Jun;11(2):238-46.
137. Neuenschwander MC, Sataloff RT, Abaza MM, Hawkshaw MJ, Reiter D, Spiegel JR. Management of vocal fold scar with autologous fat implantation: perceptual results. *J Voice*. 2001 Jun;15(2):295-304. DOI: 10.1016/S0892-1997(01)00031-5
138. Hertegård S, Hallén L, Laurent C, Lindström E, Olofsson K, Testad P, Dahlqvist A. Cross-linked hyaluronan versus collagen for injection treatment of glottal insufficiency: 2-year follow-up. *Acta Otolaryngol*. 2004 Dec;124(10):1208-14.
139. Svensson B, Nagubothu SR, Cedervall J, Chan RW, Le Blanc K, Kimura M, Åhrlund-Richter L, Tolf A, Hertegård S. Injection of human mesenchymal stem cells improves healing of vocal folds after scar excision—a xenograft analysis. *Laryngoscope*. 2011 Oct;121(10):2185-90. DOI: 10.1002/lary.22143
140. Kishimoto Y, Welham NV, Hirano S. Implantation of atelocollagen sheet for vocal fold scar. *Curr Opin Otolaryngol Head Neck Surg*. 2010 Dec;18(6):507-11. DOI: 10.1097/M00.0b013e32833f8bdc
141. Suehiro A, Hirano S, Kishimoto Y, Rousseau B, Nakamura T, Ito J. Treatment of acute vocal fold scar with local injection of basic fibroblast growth factor: a canine study. *Acta Otolaryngol*. 2010 Jul;130(7):844-50. DOI: 10.3109/00016480903426618
142. Chhetri DK, Mendelsohn AH. Hyaluronic acid for the treatment of vocal fold scars. *Curr Opin Otolaryngol Head Neck Surg*. 2010 Dec;18(6):498-502. DOI: 10.1097/M00.0b013e32833f85d1
143. Mortensen MM, Woo P, Ivey C, Thompson C, Carroll L, Altman K. The use of the pulse dye laser in the treatment of vocal fold scar: a preliminary study. *Laryngoscope*. 2008 Oct;118(10):1884-8. DOI: 10.1097/MLG.0b013e32831817d7546
144. Welham NV, Rousseau B, Ford CN, Bless DM. Tracking outcomes after phonosurgery for sulcus vocalis: a case report. *J Voice*. 2003 Dec;17(4):571-8.
145. Emerich KA, Spiegel JR, Sataloff RT. Phonomicrosurgery III: pre- and postoperative care. *Otolaryngol Clin North Am*. 2000 Oct;33(5):1071-80.
146. Behrman A, Sulica L. Voice rest after microlaryngoscopy: current opinion and practice. *Laryngoscope*. 2003 Dec;113(12):2182-6. DOI: 10.1097/00005537-200312000-00026
147. Ishikawa K, Thibeault S. Voice rest versus exercise: a review of the literature. *J Voice*. 2010 Jul;24(4):379-87. DOI: 10.1016/j.jvoice.2008.10.011
148. Rousseau B, Cohen SM, Zeller AS, Searce L, Tritter AG, Garrett CG. Compliance and quality of life in patients on prescribed voice rest. *Otolaryngol Head Neck Surg*. 2011 Jan;144(1):104-7. DOI: 10.1177/0194599810390465
149. Nawka T. Postoperative Betreuung in der operativen Laryngologie [Postoperative care in operative laryngology]. *HNO*. 2008 Dec;56(12):1183-9. DOI: 10.1007/s00106-008-1726-x
150. Richter B, Echternach M. Stimmdiagnostik und -therapie bei Angehörigen stimmintensiver Berufe [Diagnostics and therapy in professional voice-users]. *HNO*. 2010 Apr;58(4):389-98. DOI: 10.1007/s00106-009-2070-5
151. Richter B, Echternach M. Stimmärztliche Betreuung und Behandlung von Sängern [Medical treatment of singers' voices]. *HNO*. 2011 Jun;59(6):547-55. DOI: 10.1007/s00106-011-2307-y
152. Brunner E, Friedrich G, Kiesler K, Chibidziura-Priesching J, Gugatschka M. Subjective breathing impairment in unilateral vocal fold paralysis. *Folia Phoniatr Logop*. 2011;63(3):142-6. DOI: 10.1159/000316320
153. Misono S, Merati AL. Evidence-based practice: evaluation and management of unilateral vocal fold paralysis. *Otolaryngol Clin North Am*. 2012 Oct;45(5):1083-108. DOI: 10.1016/j.otc.2012.06.011



154. Apfelbaum RI, Kriskovich MD, Haller JR. On the incidence, cause, and prevention of recurrent laryngeal nerve palsies during anterior cervical spine surgery. *Spine*. 2000 Nov;25(22):2906-12. DOI: 10.1097/00007632-200011150-00012
155. Bergamaschi R, Becouarn G, Ronceray J, Arnaud JP. Morbidity of thyroid surgery. *Am J Surg*. 1998 Jul;176(1):71-5. DOI: 10.1016/S0002-9610(98)00099-3
156. Chiang FY, Wang LF, Huang YF, Lee KW, Kuo WR. Recurrent laryngeal nerve palsy after thyroidectomy with routine identification of the recurrent laryngeal nerve. *Surgery*. 2005 Mar;137(3):342-7. DOI: 10.1016/j.surg.2004.09.008
157. Sulica L. The natural history of idiopathic unilateral vocal fold paralysis: evidence and problems. *Laryngoscope*. 2008 Jul;118(7):1303-7. DOI: 10.1097/MLG.0b013e31816f27ee
158. Leder SB, Ross DA. Incidence of vocal fold immobility in patients with dysphagia. *Dysphagia*. 2005;20(2):163-7; discussion 168-9. DOI: 10.1007/s10350-005-0002-4
159. Harries ML, Morrison M. The role of stroboscopy in the management of a patient with a unilateral vocal fold paralysis. *J Laryngol Otol*. 1996 Feb;110(2):141-3.
160. Eysholdt U, Lohscheller J. Phonovibrogramm: Stimmlippendynamik in einem Bild [Phonovibrogram: vocal fold dynamics integrated within a single image]. *HNO*. 2008 Dec;56(12):1207-12. DOI: 10.1007/s00106-007-1541-9
161. Crumley RL. Laryngeal synkinesis: its significance to the laryngologist. *Ann Otol Rhinol Laryngol*. 1989 Feb;98(2):87-92.
162. Woodson GE. Configuration of the glottis in laryngeal paralysis. I: Clinical study. *Laryngoscope*. 1993 Nov;103(11 Pt 1):1227-34. DOI: 10.1288/00005537-199311000-00004
163. Sulica L, Myssiorek D. Vocal fold paralysis. *Otolaryngol Clin North Am*. 2004 Feb;37(1):xi-xiv. DOI: 10.1016/S0030-6665(03)00178-6
164. El Badaway MR, Puneekar S, Zammit-Maempel I. Prospective study to assess vocal cord palsy investigations. *Otolaryngol Head Neck Surg*. 2008 Jun;138(6):788-90. DOI: 10.1016/j.otohns.2008.03.004
165. Wang CP, Chen TC, Lou PJ, Yang TL, Hu YL, Shieh MJ, Ko JY, Hsiao TY. Neck ultrasonography for the evaluation of the etiology of adult unilateral vocal fold paralysis. *Head Neck*. 2012 May;34(5):643-8. DOI: 10.1002/hed.21794
166. Merati AL, Halum SL, Smith TL. Diagnostic testing for vocal fold paralysis: survey of practice and evidence-based medicine review. *Laryngoscope*. 2006 Sep;116(9):1539-52. DOI: 10.1097/01.mlg.0000234937.46306.c2
167. Rickert SM, Childs LF, Carey BT, Murry T, Sulica L. Laryngeal electromyography for prognosis of vocal fold palsy: a meta-analysis. *Laryngoscope*. 2012 Jan;122(1):158-61. DOI: 10.1002/lary.22354
168. Crumley RL. Laryngeal synkinesis revisited. *Ann Otol Rhinol Laryngol*. 2000 Apr;109(4):365-71.
169. Woo P, Arandia H. Intraoperative laryngeal electromyographic assessment of patients with immobile vocal fold. *Ann Otol Rhinol Laryngol*. 1992 Oct;101(10):799-806.
170. Rubin AD, Hawkshaw MJ, Moyer CA, Dean CM, Sataloff RT. Arytenoid cartilage dislocation: a 20-year experience. *J Voice*. 2005 Dec;19(4):687-701. DOI: 10.1016/j.jvoice.2004.11.002
171. Rieger A, Hass I, Gross M, Gramm HJ, Eyrich K. Intubationstraumen des Larynx—eine Literaturübersicht unter besonderer Berücksichtigung der Aryknorpelluxation [Intubation trauma of the larynx—a literature review with special reference to arytenoid cartilage dislocation]. *Anesthesiol Intensivmed Notfallmed Schmerzther*. 1996 Jun;31(5):281-7. DOI: 10.1055/s-2007-995921
172. Norris BK, Schweinforth JM. Arytenoid dislocation: An analysis of the contemporary literature. *Laryngoscope*. 2011 Jan;121(1):142-6. DOI: 10.1002/lary.21276
173. Miller S. Voice therapy for vocal fold paralysis. *Otolaryngol Clin North Am*. 2004 Feb;37(1):105-19. DOI: 10.1016/S0030-6665(03)00163-4
174. Schuster M, Eysholdt U. Therapie der einseitigen Stimmlippenparese [Therapy for unilateral vocal fold palsy]. *HNO*. 2005 Sep;53(9):756-65. DOI: 10.1007/s00106-005-1297-z
175. Isshiki N. Mechanical and dynamic aspects of voice production as related to voice therapy and phonosurgery. *J Voice*. 1998 Jun;12(2):125-37. DOI: 10.1016/S0892-1997(98)80031-3
176. Mattioli F, Bergamini G, Alicandri-Ciuffelli M, Molteni G, Luppi MP, Nizzoli F, Grammatica A, Presutti L. The role of early voice therapy in the incidence of motility recovery in unilateral vocal fold paralysis. *Logoped Phoniatr Vocol*. 2011 Apr;36(1):40-7. DOI: 10.3109/14015439.2011.554433
177. Hazlett DE, Duffy OM, Moorhead SA. Review of the impact of voice training on the vocal quality of professional voice users: implications for vocal health and recommendations for further research. *J Voice*. 2011 Mar;25(2):181-91. DOI: 10.1016/j.jvoice.2009.08.005
178. Kelchner LN, Lee L, Stemple JC. Laryngeal function and vocal fatigue after prolonged reading in individuals with unilateral vocal fold paralysis. *J Voice*. 2003 Dec;17(4):513-28. DOI: 10.1067/S0892-1997(03)00067-5
179. Ptok M, Strack D. Klassische Stimmtherapie versus Elektrostimulationstherapie bei einseitiger Rekurrensparese [Voice exercise therapy versus electrostimulation therapy in patients with unilateral vocal fold paralysis]. *HNO*. 2005 Dec;53(12):1092-7. DOI: 10.1007/s00106-004-1216-8
180. Ptok M, Strack D. Electrical stimulation-supported voice exercises are superior to voice exercise therapy alone in patients with unilateral recurrent laryngeal nerve paresis: results from a prospective, randomized clinical trial. *Muscle Nerve*. 2008 Aug;38(2):1005-11. DOI: 10.1002/mus.21063
181. Ptok M, Strack D. Therapeutische Beeinflussung von Schwingungsirregularitäten durch Elektrostimulationstherapie [Therapeutic effects of electrical stimulation therapy on vocal fold vibration irregularity]. *HNO*. 2009 Nov;57(11):1157-62. DOI: 10.1007/s00106-008-1828-5
182. Rosen CA, Statham MM. Vocal fold injection as a treatment for glottic insufficiency: pro. *Arch Otolaryngol Head Neck Surg*. 2010 Aug;136(8):825-7. DOI: 10.1001/archoto.2010.115
183. Chang JI, Bevans SE, Schwartz SR. Otolaryngology clinic of North America: evidence-based practice: management of hoarseness/dysphonia. *Otolaryngol Clin North Am*. 2012 Oct;45(5):1109-26. DOI: 10.1016/j.otc.2012.06.012
184. Carroll TL, Rosen CA. Trial vocal fold injection. *J Voice*. 2010 Jul;24(4):494-8. DOI: 10.1016/j.jvoice.2008.11.001
185. Friedman AD, Burns JA, Heaton JT, Zeitels SM. Early versus late injection medialization for unilateral vocal cord paralysis. *Laryngoscope*. 2010 Oct;120(10):2042-6. DOI: 10.1002/lary.21097
186. Graboyes EM, Bradley JP, Meyers BF, Nussenbaum B. Efficacy and safety of acute injection laryngoplasty for vocal cord paralysis following thoracic surgery. *Laryngoscope*. 2011 Nov;121(11):2406-10. DOI: 10.1002/lary.22178
187. Sittel C, Bosch N, Plinkert PK. Operative Stimmrehabilitation bei einseitiger Lähmung des N. laryngeus inferior (recurrens) [Surgical voice rehabilitation in unilateral vocal fold paralysis]. *Chirurg*. 2008 Nov;79(11):1055-64. DOI: 10.1007/s00104-008-1550-6

188. Friedrich G. Externe Stimmlippenmedialisation: Funktionelle Ergebnisse [External vocal cord medialization: functional outcome]. *Laryngorhinootologie*. 1998 Jan;77(1):18-26. DOI: 10.1055/s-2007-996925
189. Friedrich G. Externe Stimmlippenmedialisation: Operative Erfahrungen und Modifikationen [External vocal fold medialization: surgical experiences and modifications]. *Laryngorhinootologie*. 1998 Jan;77(1):7-17. DOI: 10.1055/s-2007-996924
190. Friedrich G, de Jong FI, Mahieu HF, Benninger MS, Isshiki N. Laryngeal framework surgery: a proposal for classification and nomenclature by the Phonosurgery Committee of the European Laryngological Society. *Eur Arch Otorhinolaryngol*. 2001 Oct;258(8):389-96.
191. Sittel C. Larynx: Implantate und Stents [Larynx: implants and stents]. *Laryngorhinootologie*. 2009 May;88 Suppl 1:S119-24. DOI: 10.1055/s-0028-1119503
192. Morgan JE, Zraick RI, Griffin AW, Bowen TL, Johnson FL. Injection versus medialization laryngoplasty for the treatment of unilateral vocal fold paralysis. *Laryngoscope*. 2007 Nov;117(11):2068-74. DOI: 10.1097/MLG.0b013e318137385e
193. Vinson KN, Zraick RI, Ragland FJ. Injection versus medialization laryngoplasty for the treatment of unilateral vocal fold paralysis: follow-up at six months. *Laryngoscope*. 2010 Sep;120(9):1802-7. DOI: 10.1002/lary.20982
194. O'Leary MA, Grillone GA. Injection laryngoplasty. *Otolaryngol Clin North Am*. 2006 Feb;39(1):43-54. DOI: 10.1016/j.otc.2005.10.008
195. Zeitels SM, Hochman I, Hillman RE. Adduction arytenopexy: a new procedure for paralytic dysphonia with implications for implant medialization. *Ann Otol Rhinol Laryngol Suppl*. 1998 Sep;173:2-24.
196. Zeitels SM, Mauri M, Dailey SH. Adduction arytenopexy for vocal fold paralysis: indications and technique. *J Laryngol Otol*. 2004 Jul;118(7):508-16. DOI: 10.1258/0022215041615263
197. Mallur PS, Rosen CA. Vocal fold injection: review of indications, techniques, and materials for augmentation. *Clin Exp Otorhinolaryngol*. 2010 Dec;3(4):177-82. DOI: 10.3342/ceo.2010.3.4.177
198. Amin MR. Thyrohyoid approach for vocal fold augmentation. *Ann Otol Rhinol Laryngol*. 2006 Sep;115(9):699-702.
199. Trask DK, Shellenberger DL, Hoffman HT. Transnasal, endoscopic vocal fold augmentation. *Laryngoscope*. 2005 Dec;115(12):2262-5. DOI: 10.1097/01.mlg.0000184316.51516.83
200. Sulica L, Rosen CA, Postma GN, Simpson B, Amin M, Courey M, Merati A. Current practice in injection augmentation of the vocal folds: indications, treatment principles, techniques, and complications. *Laryngoscope*. 2010 Feb;120(2):319-25. DOI: 10.1002/lary.20737
201. Young VN, Zullo TG, Rosen CA. Analysis of laryngeal framework surgery: 10-year follow-up to a national survey. *Laryngoscope*. 2010 Aug;120(8):1602-8. DOI: 10.1002/lary.21004

**Corresponding author:**

Jörg Bohlender, MD

Phoniatrics and Logopedics, Department of Otorhinolaryngology, Head and Neck Surgery, University Hospital of Zurich, Frauenklinikstrasse 24, 8091 Zurich, Switzerland, Phone: + 41-44-255-5830, Fax: +41-44-255-4164

joerg.bohlender@usz.ch

**Please cite as**

Bohlender J. Diagnostic and therapeutic pitfalls in benign vocal fold diseases. *GMS Curr Top Otorhinolaryngol Head Neck Surg*. 2013;12:Doc01. DOI: 10.3205/cto000093, URN: urn:nbn:de:0183-cto0000936

**This article is freely available from**

<http://www.egms.de/en/journals/cto/2013-12/cto000093.shtml>

**Published:** 2013-12-13**Copyright**

©2013 Bohlender. This is an Open Access article distributed under the terms of the Creative Commons Attribution License (<http://creativecommons.org/licenses/by-nc-nd/3.0/deed.en>). You are free: to Share – to copy, distribute and transmit the work, provided the original author and source are credited.