

Received: 2013.12.16
Accepted: 2014.01.07
Published: 2014.04.24

Small longitudinal S incision and page turning style of annular ligament partial resection to treat stenosing tenosynovitis of thumb flexor tendon

Authors' Contribution:
Study Design A
Data Collection B
Statistical Analysis C
Data Interpretation D
Manuscript Preparation E
Literature Search F
Funds Collection G

ABCDEFG **Yu-ping Liu**
BEF **Yan-ying Du**
CDE **Ming-ming Wang**
BF **Ming Li**
BD **Shi-you Liu**
DE **Wei Liu**

Department of Orthopedics, Tengzhou Central Peoples' Hospital, Tengzhou, China

Corresponding Author: Yu-ping Liu, e-mail: liu9534@sohu.com
Source of support: Departmental sources

Background: To present the treatment outcome for patients with stenosing tenosynovitis of thumb flexor tendon treated with a small S incision and page turning style of annular ligament partial resection.





Material/Methods: During a 2-year period between August 2011 and July 2013, 12 consecutive patients (mean age, 45.8 years) with stenosing tenosynovitis of the thumb flexor tendon were prospectively enrolled into this study. All 12 patients underwent longitudinal S skin incision to expose annular ligament and thumb flexor tendon, and with page turning style of annular ligament partial resection to finish the operation. The average range of motion of metacarpophalangeal thumb joint, Quick disability of arm, shoulder, and hand and Short Musculoskeletal Function Assessment Dysfunction score of arm and hand were primary outcome measures.

Results: There were 9 cases of stiff metacarpophalangeal joint of thumb and 3 cases of snapping thumb for stenosing tenosynovitis. At 1-year follow-up, all stenosing tenosynovitis had healed by an average of 4 weeks. The average range of motion of the metacarpophalangeal joint was 37.1° (range, 34–40°). No patients had recurrence, cicatricial contraction, or postoperative infection. The average disability of arm, shoulder, and hand was 0.3 out of 100 (range, 0–1.67), and average Short Musculoskeletal Functional Assessment Dysfunction score of arm and hand was 6.9 out of 40 (range, 0–15.6). All 12 patients stated that they were highly satisfied.

Conclusions: Small S incision and page turning style of annular ligament partial resection for stenosing tenosynovitis of thumb flexor tendon is a safe, simple, and reliable alternative treatment with minimal soft-tissue irritation, good functional results and recovery can be expected.

MeSH Keywords: **S Incision • Aper Turning Style • Partial Resection • Annular Ligament • Tendon Entrapment**

Full-text PDF: <http://www.medscimonit.com/download/index/idArt/890197>

 1874  1  3  10

Background

Stenosing tenosynovitis of the thumb flexor tendon account for the majority of stenosing tenosynovitis of the hand flexor tendon. The disease was more common in women and manual workers, mainly caused by overuse and causing great pain and inconvenience to the patients. Conventional treatments included immobilization, rest, and oral anti-inflammatory drugs, as well as local injection of steroids and other serious cases, require surgical treatment.

We knew that transverse incision was the main conventional surgical approach, but it has disadvantages, including both sides of the dorsal nerve being damaged easily [1], sometimes the annular ligament and flexor tendon are not readily exposed, and its biggest advantage is that it is not prone to form scar contracture. Advantages of longitudinal incision are that it readily revealed the annular ligament and flexor tendon, but the biggest drawback is that it is prone to form scar contracture. Some surgical methods, such as using a mini-scalpel-needle to perform percutaneous trigger thumb release, often damage tendon, blood vessels [2] and nerves and lead to incomplete release [3] and, thus, extremely easy relapse. The best method for treatment of the trigger digit remains unclear [4]. We designed a kind of page turning style of the annular ligament partial resection with a small longitudinal S incision to more easily expose the tendon and avoid the recurrence of stenosing tenosynovitis. This article represents our experiences in 12 cases of stenosing tenosynovitis of the thumb flexor tendon in which a small longitudinal S incision and page turning style of annular ligament partial resection was performed.

Material and Methods

During a 2-year period from 1 August 2011 to 31 July 2013, 96 outpatients with stenosing tenosynovitis of the thumb flexor tendon were treated in our hospital. There were 9 cases of stiff metacarpophalangeal joint of the thumb and 3 cases of snapping thumb. All 12 patients were treated operatively with small longitudinal S incision and page turning style of annular ligament partial resection. The other 84 cases with stenosing tenosynovitis were initially treated with restricted thumb flexion and extension activities, physiotherapy, local injection of steroids, as well as other surgical methods, were excluded from this study cohort. There were 8 re-treatments and 4 initial treatments of patients in this study cohort. After Institutional Review Board approval, the patients were enrolled consecutively in this prospective study. We recorded patient demographic data and preoperative symptoms. Postoperative symptoms and operative findings are shown in Table 1. There were 8 women and 4 men with an average age

of 45.8 years (range, 29–62 years). Four patients were agricultural workers and 5 patients were manual workers (employed mainly in garment factories, mills, and toy factories), 1 patient was a fisherman, and 2 patients were housewives. Comorbidities included cardiac disease in 1 patient, diabetes in 2, and heavy smoking in 1. All patients had palpable indurations in the front of the flexor tendon. The preoperative average range of motion of the metacarpophalangeal joint was 6.75° (range, 2–25°).

Surgical techniques

The procedure was similar to the conventional longitudinal incision. The palpable indurations were approached through the small longitudinal S incision. First, we touch the stenosing tenosynovitis nodules and then the center of it up and down to make the 5-mm S skin incision marks (Figure 1). The operation does not need many surgical instruments, but 2 small retractors are necessary. A small automatic retractor is needed if the operation is performed by just 1 surgeon (Figure 2). If the surgery is done under local anesthesia, the patient needs local lidocaine infiltration after disinfection is completed. The surgeons use a 15th blade to cut open the skin; blunt dissection is done with a hemostat (not with the blade) until the flexor tendon and annular ligament are exposed. The main purpose of not using a blade to expose the tendon and annular ligament is to avoid damage to both sides of the dorsal nerves. We used a page turning style of annular ligament partial excision to manage the annular ligament after we revealed the annular ligament and flexor tendon, which requires cutting open the annular ligament from the extreme lateral or medial part. The advantage of this approach is that you can achieve an effective annular ligament partial resection; you can avoid the annular ligament contraction of both sides not effectively removed when it was cut from the middle, thus avoiding postoperative recurrence of stenosis tenosynovitis. The procedure is shown in Figure 3. We used forceps to provoke the flexor tendon to test the extent of tendon release after the annular ligament partial resection to see if it releases thoroughly. The patients were encouraged to flex the thumb metacarpophalangeal joint and interphalangeal joint, and feel the extent of release by themselves. The final release of the stenosing tenosynovitis is tested by moving the thumb through a range of motions. If the release is complete, we directly suture the skin.

The postoperative rehabilitation protocol was standardized. External splints were not used. The patients were encouraged to exercise the thumb metacarpophalangeal joint and interphalangeal joint after the 24th postoperative hour. After the incision stabilized, usually at 3 or 4 days, thumb flexation was encouraged to gain full range of motion of flexion. Patients were followed up after surgery at 1, 3, 6, and

Table 1. Patients data.

Case No	Age (years)/sex	Occupation	Second treatment/ treated methods	Preoperative symptom	Preoperative/average range motion of metacarpophalangeal joint(°)
1	29/F	Picking farmer	Y/miniscalpel- needle	Snapping thumb	0–25°
2	57/F	Manual workers	N	Snapping thumb	0–2°
3	62/F	Manual workers	Y/steroids	Stiff thumb	0–3°
4	37/F	Picking farmer	Y/miniscalpel- needle	Stiff thumb	0–3°
5	51/F	Picking farmers	N	Stiff thumb	0–2°
6	46/F	Manual workers	Y/steroids	Stiff thumb	0–1°
7	35/M	Manual workers	N	Stiff thumb	0–2°
8	45/F	Picking farmers	Y/miniscalpel- needle	Snapping thumb	0–18°
9	39/F	Picking farmers	Y/steroids	Stiff thumb	0–4°
10	51/F	Picking farmers	Y/miniscalpel- needle	Stiff thumb	0–3°
11	43/M	Fisherman	N	Snapping thumb	0–15°
12	55/F	Manual workers	Y/steroids	Stiff thumb	0–3°

Case No	Prospective Follow-Up (months)	Postoperative average range motion of meta- carpophalangeal joint (°)	SFMA dysfunction score of arm and hand	DASH score	Complications	Patient-rated satisfaction
1	12	0–37°	12.5	0.83	No	Highly satisfied
2	12	0–36°	6.25	1.67	No	Highly satisfied
3	12	0–34°	0	0	No	Highly satisfied
4	12	0–40°	15.6	0	No	Highly satisfied
5	12	0–37°	12.5	0.83	No	Highly satisfied
6	12	0–36°	6.25	0	No	Highly satisfied
7	12	0–40°	0	0	No	Highly satisfied
8	12	0–35°	6.25	0	No	Highly satisfied
9	12	0–36°	3.125	0.83	No	Highly satisfied
10	12	0–38°	0	1.67	No	Highly satisfied
11	12	0–40°	0	0	No	Highly satisfied
12	12	0–36°	15.6	0	No	Highly satisfied

SFMA – short musculoskeletal functional assessment; F – female; M – male; DASH – disability of arm shoulder and hand.

12 months after surgery. At the last follow-up at 1 year, all patients were asked to complete a validated outcome measure, Quick disability of arm, shoulder and hand and average Short Musculoskeletal Functional Assessment Dysfunction score of arm and hand.

Results

All 12 patients had primary incision healing, with 1 skin slough. No patients had scar contracture affecting thumb function, incision union, or wound infection. No patients reported soft-tissue

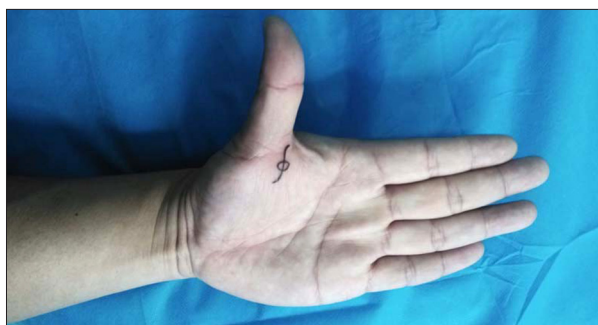

Figure 1. The small longitudinal S incision in thumb.

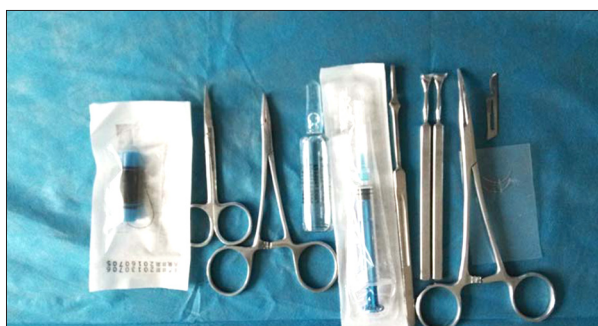

Figure 2. The necessary surgical instruments and drugs in this surgery.

irritation as manifested by pain around the thumb flexor tendon. All 12 patients were followed up for 12 months. At final follow-up, the average range of motion arc of the metacarpophalangeal thumb joint was 37.1° (range, 29–40°). With regard to the formal functional outcome assessment, all 12 patients stated they were “highly satisfied”. Quick disability of arm, shoulder, and hand was 0.3 out of 100 (range, 0–3), and average Short Musculoskeletal Functional Assessment dysfunction score of arm and hand was 6.9 out of 40 (range, 6.3–11.2). As a point of reference, the average Short Musculoskeletal Functional Assessment dysfunction score of arm and hand is 6.02 points for the general population, and Quick disability of arm, shoulder, and hand was 0 points for the general population (Table 1).

Discussion

Usually, stenosing tenosynovitis of thumb flexor tendon, commonly known as “snapping thumbs” or “trigger thumbs” occurs most commonly in manual workers, especially in elderly women [5]. With the popularity of mobile phones and computers, more and more young people have begun to have the disease. The manifestations of thumb flexor tenosynovitis include metacarpophalangeal joint soreness and pain or snapping resulting in flexion and extensor dysfunction. In more severe cases, patients can have stiff thumbs or flexion deformity and active and passive extension limitation. The

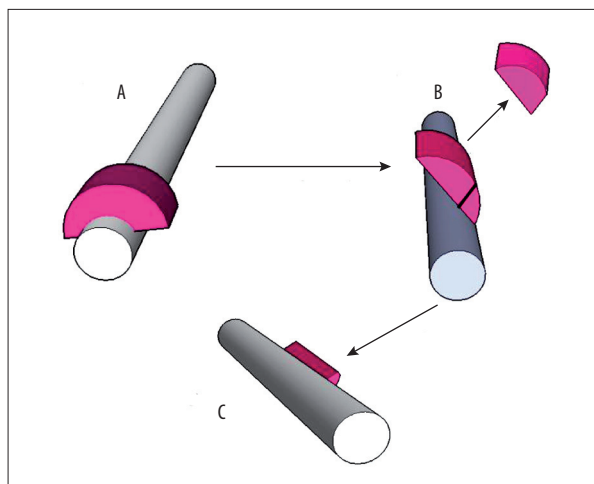


Figure 3. The process of paper turning style of annular ligament partial resection, the grey color of columnar structure referred to flexor tendon, the red color arc structure referred to annular ligament.

flexor tendon passes through a relatively narrow tunnel composed of thumb metacarpal bones, thumb flexor tendon, and annular ligament. If repeated stimulation occurs, the tunnel gradually becomes more and more narrow, then the flexor tendon is slowly squeezed into the spindle- or gourd-shaped swollen tendon. We have often found localized subcutaneous palpable hard nodules, which cause thumbs movement disorder, snapping, and pain. These greatly affect the function of the hand and thus affect the performance of activities of daily living.

Some researchers have used closed treatment with steroids and narcotic drugs to treat it [6,7], but the effect is not ideal and often causes tendon rupture [8,9]. Some surgeons reported that they treated stenosing tenosynovitis of the thumb with a mini-scalpel needle and achieved good effect, but with mini-scalpel needle surgery it is very easy to damage nerves, blood vessels, and tendons, in which case repeated surgery may be necessary. Endoscopic treatment [10] of stenosing tenosynovitis requires specialized equipment to perform complicated operations, thus it is not widely used. The classic surgical approach is to cut the skin with a transverse or longitudinal incision, revealing the nerve, artery, and flexor tendon, and cutting open the annular ligament and then releasing the flexor tendon, then the incision is sutured. The surgeons must protect the nerves, blood vessels, and tendons during surgery. Transverse incision has some disadvantages; for example, tendons are often more difficult to expose, sometimes requiring extension of the incision, which can easily damage the dorsal nerve of the thumb, especially the radial. The longitudinal incision often causes scarring of the skin, thus affect the thumb activities. In addition, only cutting open the annular ligaments often leads to stenosing tenosynovitis recurrence.

We designed a small longitudinal S incision and page turning style of annular ligament partial resection to treat the stenosing tenosynovitis. The patients are asked to begin active functional exercise beginning 24 hours after the operation. This method has the following advantages. Firstly, it can easily expose the flexor tendons in a longitudinal direction along the metacarpal and phalanx bones. Secondly, it does not easily damage the dorsal nerves. For the incision located in the middle of the metacarpophalangeal joint, when we cut open the skin, we separate subcutaneous tissue with a vascular clamp (not with surgical blades) until the flexor tendon is exposed, which avoids the surgical blades damaging dorsal nerves. Thirdly, the S incision can effectively avoid thumb flexion and extension activities and restricting skin scarring. Fourthly, the page turning style of annular ligament partial resection ensures that the annular ligament is effectively resected, because cutting open the annular ligament in the middle causes the flexor tendon to squeeze the 2 parts of the annular ligament into lateral and medial sides, which causes the annular ligament to not be effectively resected. The surgical release is thorough, safe, and effective, and lessens the chance of recurrence of annular ligament adhesion, even if the patient could not exercise due to wound pain.

The small longitudinal S incision and page turning style of annular ligament partial resection to treat stenosing tenosynovitis

of the thumb flexor tendon to relieve the flexor tendon is simple, safe, causes less damage, and is worthy of promotion. It can completely cure the disease. We often need to correctly select patients. Conservative therapy should be chosen for serious cases such as those with snapping or stiff thumbs to ensure annular ligament partial resection effectively allows full release the thumb flexor tendon. In patients without snapping or stiff thumbs or in pediatric patients with congenital conditions, we should cut open the annular ligament in the extreme lateral or medial side, and be careful to not damage the flexor tendons. Finally, we test if the snapping or stiff thumbs can disappear and release completely. The clinical results of this method are good and recurrence rate is very low.

Conclusions

In conclusion, thumb flexor tendon stenosing tenosynovitis is a common disease. The small longitudinal S incision and page turning style of annular ligament partial resection causes less trauma, has low cost and low rate of recurrence, is effective, and leads to rapid recovery. It is safe, simple, and reliable treatment alternative. It is a reliable treatment method with full release and with early range of motion. Excellent results in thumb function can be predicted.

References:

1. Hirasawa Y, Sakakida K, Tokioka T, Ohta Y: An investigation of the digital nerves of the thumb. *Clin Orthop Relat Res*, 1985; (198): 191–96
2. Taylor SA, Osei DA, Jain S, Weiland AJ: Digital artery pseudoaneurysm following percutaneous trigger thumb release: a case report. *J Bone Joint Surg Am*, 2012; 94(2): e6
3. Torudom Y: Percutaneous trigger thumb release with 18 guage needle. *J Med Assoc Thai*, 2012; 95(Suppl.12): S90–92
4. Wang J, Zhao JG, Liang CC: Percutaneous release, open surgery, or corticosteroid injection, which is the best treatment method for trigger digits? *Clin Orthop Relat Res*, 2013; 471(6): 1879–86
5. Sato J, Ishii Y, Noguchi H, Takeda M: Sonographic appearance of the flexor tendon, volar plate, and A1 pulley with respect to the severity of trigger finger. *J Hand Surg Am*, 2012; 37(10): 2012–20
6. Dala-Ali BM, Nakhdjvani A, Lloyd MA, Schreuder FB: The efficacy of steroid injection in the treatment of trigger finger. *Clin Orthop Surg*, 2012; 4(4): 263–68
7. Murphy AD, Lloyd-Hughes H, Ahmed J: Complex regional pain syndrome (Type 1) following steroid injection for stenosing tenosynovitis. *J Plast Reconstr Aesthet Surg*, 2010; 63(10): e740–41
8. Jianmongkol S, Kosuwon W, Thammaroj T: Intra-tendon sheath injection for trigger finger: the randomized controlled trial. *Hand Surg*, 2007; 12(2): 79–82
9. Gyuricza C, Umoh E, Wolfe SW: Multiple pulley rupture following corticosteroid injection for trigger digit: case report. *J Hand Surg Am*, 2009; 34(8): 1444–48
10. Kang HJ, Koh IH, Jang JW, Choi YR: Endoscopic versus open release in patients with de Quervain's tenosynovitis: a randomised trial. *Bone Joint J*, 2013; 95-B(7): 947–51