

# Is the Capsular Bag Perimeter Round or Elliptical?

Alfredo Amigó<sup>1</sup>, MD, PhD; Sergio Bonaque-González<sup>1,2</sup>, MS

<sup>1</sup>Department of Ophthalmology, Instituto Oftalmológico Amigó, Tenerife, Spain

<sup>2</sup>Department of Physics, University of La Laguna, Tenerife, Spain

## Abstract

**Purpose:** To report findings that could suggest an elliptical shape of the capsular bag.

**Methods:** Five eyes of three patients with axial length greater than 24 mm underwent phacoemulsification cataract surgery with plate-haptic multifocal toric intraocular lens (IOL) implantation oriented in the vertical meridian.

**Results:** In all cases, correct orientation of the IOLs was verified 30 minutes after surgery. After 24 hours, all eyes demonstrated unwanted rotation of the IOLs ranging from 15 to 45 degrees. The IOLs remained stable in the new position in all cases until adhesion of the capsular bag took place.

**Conclusion:** These observations could suggest that the perimeter of the capsular bag has an elliptical shape. Therefore, the IOL tends to become fixated in a meridian of the capsular bag that best fits the diagonal diameter of the IOL.

**Keywords:** Capsular Bag; Cataract Surgery; Intraocular Lens; Phacoemulsification Surgery

*J Ophthalmic Vis Res* 2016; 11 (2): 159-161.

## INTRODUCTION

Knowledge of the shape of the lens capsule perimeter is a relevant issue because intraocular lenses (IOLs) implanted within the capsular bag obtain their stability from the support offered by its perimeter.<sup>[1]</sup>

When the diameter of the IOL is significantly smaller than that of the capsular bag (which mainly occurs in eyes with large axial length),<sup>[2]</sup> rotational IOL instability may occur, causing unexpected rotation.<sup>[3]</sup>

Based on accurate measurements, it is well known that the anterior segment of the human eye is not perfectly circular with the horizontal corneal diameter being

significantly greater than its vertical diameter.<sup>[4]</sup> The perimeter of the sulcus is also significantly ellipsoidal, however its vertical diameter is larger than the horizontal one.<sup>[5]</sup> There is also evidence indicating that the ciliary ring is ellipsoid.<sup>[6]</sup>

Keeping these facts in mind, it seems reasonable that the perimeter of the zonules also has an ellipsoid shape and that this form is transmitted, to some extent, to the capsular bag. Although we have not found any publication addressing this issue, we have accumulated some experience indicating that the capsular bag perimeter is not perfectly circular.

We have previously demonstrated that the position of IOLs with C-loop haptics significantly changed with respect to the center of the cornea due to rotation of the IOL within the capsular bag.<sup>[7]</sup> As IOL haptics shrink and extend symmetrically and the achieved centration is stable after surgery, a reasonable explanation could be that the perimeter of the capsular bag is not round.

### Correspondence to:

Alfredo Amigó, MD, PhD. Department of Ophthalmology, Instituto Oftalmológico Amigó, C/Bravo Murillo 10, Santa Cruz de Tenerife 38003, Canary Islands, Spain.  
E-mail: amigo@ioamigo.com

Received: 08-05-2015

Accepted: 29-06-2015

### Access this article online

Quick Response Code:



Website:

www.jovr.org

DOI:

10.4103/2008-322X.183925

This is an open access article distributed under the terms of the Creative Commons Attribution-NonCommercial-ShareAlike 3.0 License, which allows others to remix, tweak, and build upon the work non-commercially, as long as the author is credited and the new creations are licensed under the identical terms.

For reprints contact: reprints@medknow.com

**How to cite this article:** Amigó A, Bonaque-González S. Is the capsular bag perimeter round or elliptical? *J Ophthalmic Vis Res* 2016;11:159-61.

## METHODS

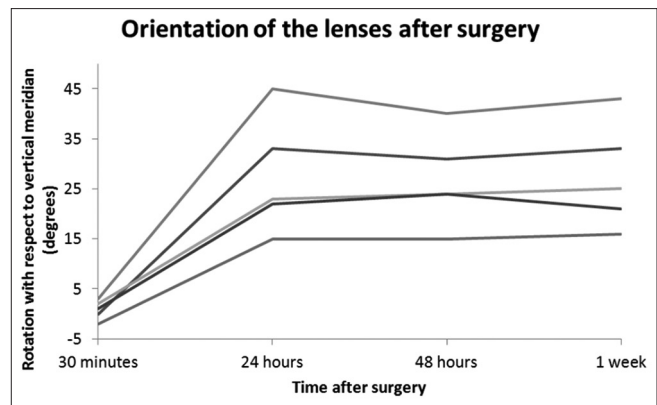
This case series introduces 5 eyes of 3 patients with large axial length (more than 24 mm in all cases) in which a multifocal toric IOL with plate haptic (Lentis Mplus Toric IOL, Oculentis GMBH, Berlin, Germany) was implanted. Orientation of all lenses was measured at the slit lamp 30 minutes, 24 and 48 hours, and one week after surgery. Because of its particular optical design, this type of customized IOL must always be oriented along the vertical meridian regardless of the axis of corneal astigmatism.

## RESULTS

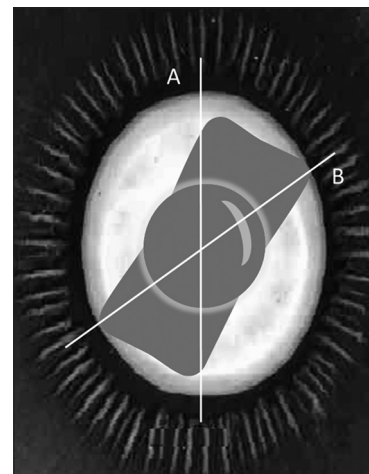
In all cases, a 2.2 millimeters (mm) temporal incision with a 5.0 mm capsulorrhexis size was used. Standard divide and conquer phaco emulsification technique was performed in all eyes. OVD cleanup was performed after IOL implantation by using mechanical irrigation aspiration from the anterior chamber and also from the capsular bag behind the IOL in every case. At thirty minutes after surgery, correct orientation of the IOLs was verified which was within  $\pm 3$  degrees of the desired vertical meridian in all cases. Twenty-four hours after surgery, once cycloplegia and hence zonular tension had worn off, all eyes demonstrated unwanted IOL rotation to a new meridian between  $15^\circ$  and  $45^\circ$  away from its primary position. The IOLs remained stable in the new meridian at 48 hours and after seven days [Figure 1].

## DISCUSSION

It is unclear why the IOLs rotate a few hours after surgery into a new stable meridian different from the intended one, instead of turning randomly until adhesion of the capsular bag takes place to stabilize the IOL; this adhesion never occurs before 2 days. We believe that this finding may be a sign that the perimeter of the capsular bag is not round but elliptical. In this manner, the lens takes a position which finally prevents further rotation, fitting into the capsular bag diameter that best suits the diagonal diameter of the IOL as shown in Figure 2. Our observations regarding the early rotation of IOLs reported in this case series are compatible with an ovoid capsular bag shape with the larger diameter close to the vertical meridian; findings consistent with other anatomical structures of the anterior segment of the eye.<sup>[4-6]</sup> This possibly new finding in ocular anatomy, if confirmed, could lead to open new strategies to prevent intraocular lens rotational instability or create new haptic designs, among others. It may also allow a better understanding of the phenomenon of rotational instability with some types of IOLs in eyes with large axial length. However, one may argue that further



**Figure 1.** Postoperative rotations of the intraocular lenses with respect to the intended orientation in the vertical meridian.



**Figure 2.** Miyake-Apple view representation of the intraocular lens fitted in a new meridian of the capsular bag due to early rotational instability. A=Initial axis of implantation. B=Saccular meridian, which fits the diagonal axis of the intraocular lens.

studies are warranted to precisely measure the capsule perimeter *in vivo*.

## Financial Support and Sponsorship

Nil.

## Conflicts of Interest

There are no conflicts of interest.

## REFERENCES

- Hirschschall N, Maedel S, Weber M, Findl O. Rotational stability of a single-piece toric acrylic intraocular lens: A pilot study. *Am J Ophthalmol* 2014;157:405-411.e1.
- Vass C, Menapace R, Schmetterer K, Findl O, Rainer G, Steineck I. Prediction of pseudophakic capsular bag diameter based on biometric variables. *J Cataract Refract Surg* 1999;25:1376-1381.
- Shah GD, Praveen MR, Vasavada AR, Vasavada VA, Rampal G,

- Shastry LR. Rotational stability of a toric intraocular lens: Influence of axial length and alignment in the capsular bag. *J Cataract Refract Surg* 2012;38:54-59.
4. Khng C, Osher RH. Evaluation of the relationship between corneal diameter and lens diameter. *J Cataract Refract Surg* 2008;34:475-479.
  5. Oh J, Shin HH, Kim JH, Kim HM, Song JS. Direct measurement of the ciliary sulcus diameter by 35-megahertz ultrasound biomicroscopy. *Ophthalmology* 2007;114:1685-1688.
  6. Marchini G, Pedrotti E, Modesti M, Visentin S, Tosi R. Anterior segment changes during accommodation in eyes with a monofocal intraocular lens: High-frequency ultrasound study. *J Cataract Refract Surg* 2008;34:949-956.
  7. Amigó A, Bonaque S. Surgical technique for centering diffractive intraocular lenses with open-loop haptics. *Arch Soc Esp Ophthalmol* 2014;89:239-241.