

## Unusually Located Proximal Middle Cerebral Artery Saccular Aneurysm

### Abstract

Middle cerebral aneurysms constitute almost one-third of all anterior circulation aneurysms. Most of the saccular aneurysms originate from the arterial branching sites, but origins other than at the branching site are extremely rare. In this article, we are describing a unique M1 segment middle cerebral artery aneurysm which is not related with any branching site. Our literature search suggests that atherosclerotic changes in the arterial wall and local hemodynamic forces play an important role in the development of these types of aneurysm. Surgical management is not so unique in this type of aneurysm, but due to atherosclerotic parent arterial wall and thin-walled aneurysm sac, a neurosurgeon should be more cautious.

**Keywords:** Atherosclerosis, hemodynamic stress, middle cerebral artery, saccular aneurysm

### Introduction

Cerebral aneurysm is prevalent all over the world. Some studies suggest its incidence in 1%–5%;<sup>[1-3]</sup> in the Japanese population, is a little bit higher (6.8%).<sup>[4]</sup> Aneurysm rupture rate is 0.95%–1.4% per year.<sup>[3]</sup> One of the most common sites of cerebral saccular aneurysms is the middle cerebral artery (MCA).<sup>[5]</sup> Curvature and turns of the MCA categorized its surgical anatomy. The branches of the MCA do not contribute to the segments. From sphenoidal (M1) to cortical (M4) segments are defined by arterial bending which forms genu of the artery. M1 starts from the bifurcation of the internal carotid artery (ICA) and ends at the acute bend of the artery around 90° which runs over the limen insulae. M1 or sphenoidal segment was named after the sphenoid ridge where the artery follows along the ridge. The aneurysms of the proximal segment (M1) of the MCA usually arise at the origin of the anterior temporal artery and lateral lenticulostriate arteries.<sup>[6]</sup> Aneurysms arising without any branch patterns are rare. In this article, we are presenting a case report of saccular MCA aneurysm which has no relation with any branch.

### Case Report

A 38-year-old male, average built, nonsmoker, occasional drinker had

presented in our emergency with a history of sudden-onset severe headache. He had no history of high blood pressure but no family history of cerebral aneurysm. The patient was neurologically intact with mild neck stiffness (H and H Grade 2 and World Federation of Neurological Surgeons Grade 1). Evaluation with noncontrast cerebral computed tomography scan revealed diffuse subarachnoid hemorrhage (Fisher Grade 3). Cerebral computed tomography (CT) angiography showed a large right side M1 MCA saccular aneurysm pointing downward and laterally, arising from the dorsal wall of the vessel [Figure 2 and 3]. Aneurysm was not associated with any M1 early branch (anterior temporal or lenticulostriate arteries). Aneurysm sac's neck was 2.23 mm, and the dome was 8.20 mm × 6.23 mm. Computational fluid dynamics (CFD) showed moderate high wall pressure with low wall shear stress (WSS), vectors were divergent to the base, and streamline was disturbed. By this CFD observation, we concluded that the aneurysm had a high tendency to rupture [Figure 1].

Intraoperatively, after careful Sylvian fissure dissection, proximal MCA (M1) segment large saccular aneurysm was found which was not associated with any early branch, arising from the dorsal wall of the MCA. There were multiple atherosclerotic

Raghavendra  
Kumar Sharma,  
Yashuhiro Yamada<sup>1</sup>,  
Riki Tanaka<sup>1</sup>,  
Saurabh Sharma<sup>2</sup>,  
Kyosuke Miyatani<sup>1</sup>,  
Saeko  
Higashiguchi<sup>1</sup>,  
Tsukasa Kawase<sup>1</sup>,  
Srikanth Talluri<sup>3</sup>,  
Yoko Kato<sup>1</sup>

*Department of Neurosurgery,  
AIIMS, Raipur, C.G.*

*<sup>2</sup>Department of Neurosurgery,  
Max Patparganj Hospital,  
New Delhi, <sup>3</sup>Department of*

*Neurosurgery, SVIMS, Tirupati,  
Andhra Pradesh, India,*

*<sup>1</sup>Department of Neurosurgery,  
Bantane Hospital, Fujita Health  
University, Nagoya, Japan*

### Address for correspondence:

Dr. Raghavendra Kumar  
Sharma,

Department of Neurosurgery,  
AIIMS, Raipur, Chhattisgarh,  
India.

E-mail: sdr.raghavendra@gmail.  
com

### Access this article online

Website: www.asianjns.org

DOI: 10.4103/ajns.AJNS\_264\_19

### Quick Response Code:



**How to cite this article:** Sharma RK, Yamada Y, Tanaka R, Sharma S, Miyatani K, Higashiguchi S, et al. Unusually located proximal middle cerebral artery saccular aneurysm. *Asian J Neurosurg* 2020;15:769-72.

Submitted: 28-Aug-2019

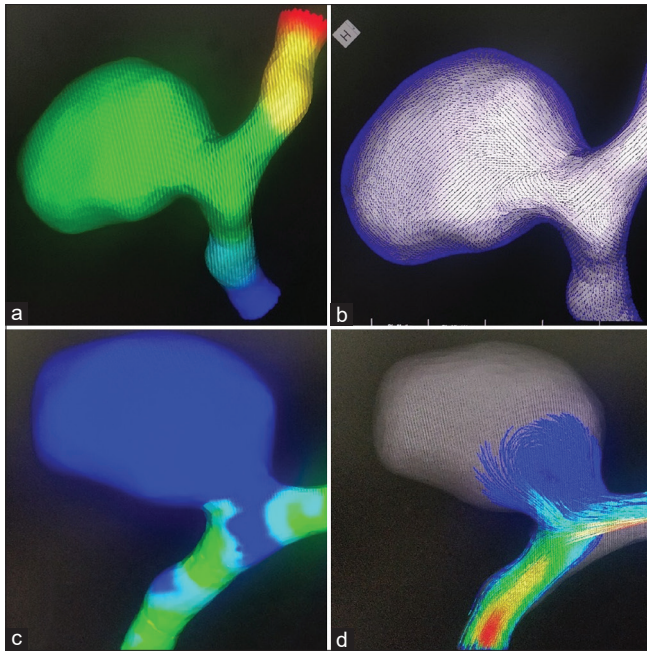
Revised: 28-Oct-2019

Accepted: 06-Jun-2020

Published: 28-Aug-2020

This is an open access journal, and articles are distributed under the terms of the Creative Commons Attribution-NonCommercial-ShareAlike 4.0 License, which allows others to remix, tweak, and build upon the work non-commercially, as long as appropriate credit is given and the new creations are licensed under the identical terms.

For reprints contact: WKHLRPMedknow\_reprints@wolterskluwer.com



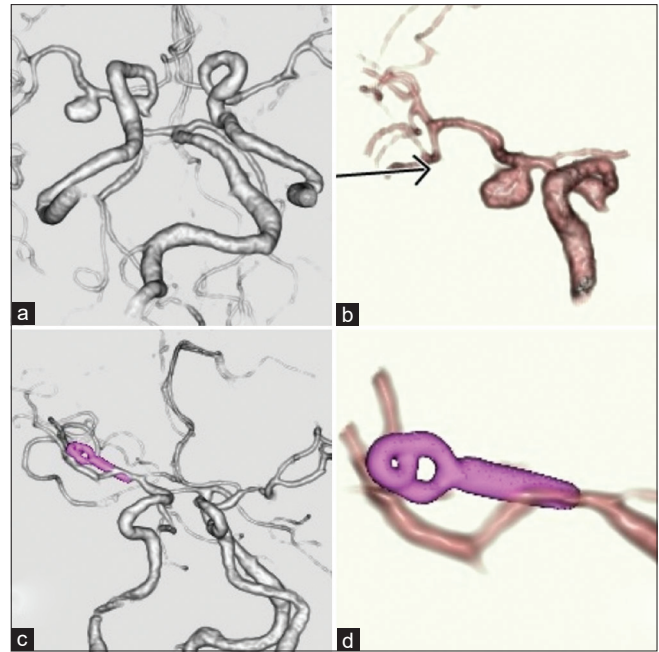
**Figure 1: Computational fluid dynamics.** Computational fluid dynamics using Hemoscope® 2015 software: (a) wall pressure, moderately high in the aneurismal sac; (b) wall shear stress vectors, showing direction of flow within the surrounding blood vessels and aneurysm; (c) wall shear pressure, showing low wall shear pressure within the aneurysm; (d) streamline, showing stream pattern with color coding (to determine the velocity) within the surrounding vessels and aneurysm

patches over the ICA. Beside this aneurysm, no other aneurysm and bleb was found in ICA or MCA. Clipping was done successfully flushed with the parent artery without any residual neck after meticulously dissecting the aneurysm neck. Complete occlusion of an aneurysm and patency of vessels were confirmed by indocyanine green and dual-image video angiography [Figure 4].

Postoperatively, cerebral CT angiography showed no residual neck or aneurysm with clip *in situ* [Figure 2]. After clipping, the patient did well with no neurological deficit and discharged with a modified Rankin score 0.

## Discussion

Among all cerebral aneurysms, the incidence of aneurysm in the MCA is 18%–40%, and most of them are found at the bifurcation of the artery and are rare at the cortical segment.<sup>[5-7]</sup> Most of the saccular aneurysm follows Rhoton's 4 rule of aneurysm.<sup>[8]</sup> He suggested that these aneurysms originate at a branching site or by subdivision of the parent artery, mostly at a turn or curve in the artery and if there is no curve then in the direction of blood flow. Dome or fundus of the saccular aneurysm was directed by the maximal hemodynamic thrust in the preaneurysmal segment of the parent artery. There are also multiple perforators at the aneurysm site. The incidence of unusual location aneurysm is rare. Several authors described the cases of aneurysm at an unusual site such as Nutik and Fox.<sup>[9,10]</sup> Nutik showed aneurysm in paraclinoid



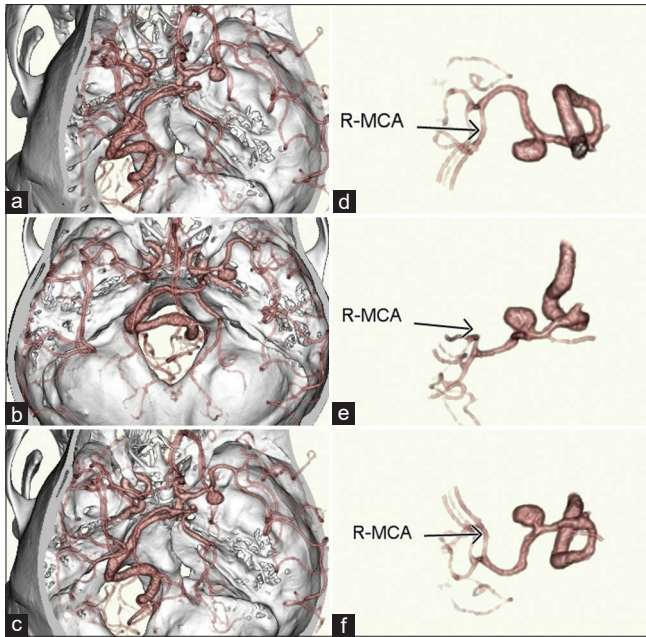
**Figure 2: Computed tomography angiography:** (a) preoperative 3D reconstruction of angiography showing large saccular middle cerebral artery aneurysm on head view and (b) lateral view; (c) postoperative angiography showing complete obliteration of aneurysmal sac with clip *in situ* on anterior view and (d) lateral view

ICA aneurysm where the aneurysm was arising from the wall of the ICA just contralateral to the ophthalmic artery. Yoshimoto *et al.* reported that the incidence of these types of aneurysm was 5.2% in their study,<sup>[11]</sup> and ICA was the most common location. Saccular aneurysm other than branching pattern is not common. Unusual location aneurysm in the ICA has been described, but M1 MCA unusual aneurysm has not been reported.<sup>[11,12]</sup>

Based on the origin of aneurysms, M1 segment aneurysm can be classified. Hosoda *et al.* classified these aneurysms into two groups “superior wall type and inferior wall type. M1 aneurysms of superior wall type arise at the origins of the lenticulostriate artery or fronto-orbital artery. M1 aneurysms of the inferior wall arise at the origins of the temporopolar or anterior temporal branches of MCA.”<sup>[13]</sup> In our case report, M1 aneurysm was arising from the superior wall of the MCA (superior wall type), but it was not associated with either lenticulostriate artery or fronto-orbital artery.

**Pathogenesis** – Many theories have been suggested for the pathogenesis of the aneurysm formation; these include the congenital and acquired etiology.<sup>[1,14-16]</sup> Recent theories suggest that the internal elastic lamina gives the strength to the vessels, and degeneration or discontinuity plays an important role in the formation of saccular aneurysm. However, hypertension, atherosclerosis, and smoking contribute in the pathogenesis of aneurysm. Disturbance in hemodynamic forces was also described.<sup>[17]</sup>

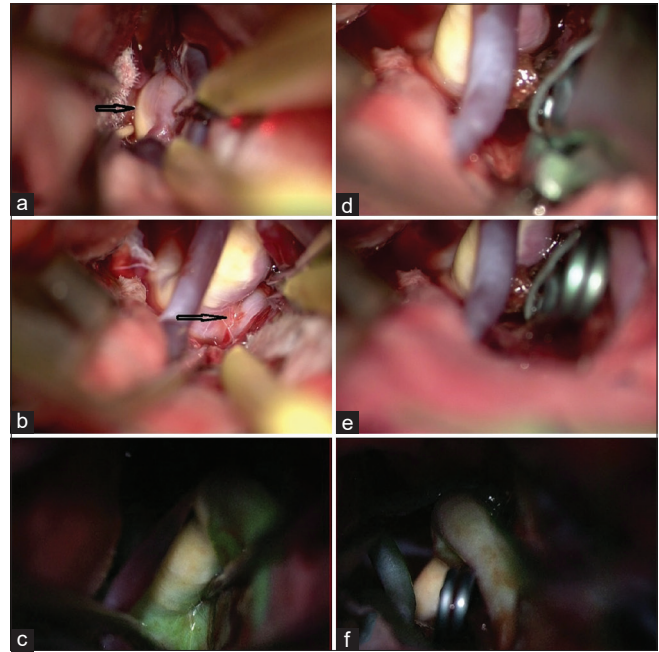
Nixon *et al.* described the pathogenesis of aneurysm formation. They coined the term “disturbed laminar flow”



**Figure 3:** For better visualization of small perforators from (a-c), three-dimensional computed tomography angiographic pictures of the middle cerebral artery aneurysm with bone, from (d-f) isolated view of the right middle cerebral artery and aneurysm from different angles

which is one of the responsible factors for aneurysm; these types of flow pattern give several types of mechanical stimulation to vessels.<sup>[18]</sup> Endothelial cells get elongated by periodic vessel dilatation which comes from pulsatile flow by heart contractility, and the pressure which is exerted tangentially by blood flow in the vessel is called the WSS. Out of all these mechanical forces, WSS plays an important role because many studies have shown its effect on endothelial. Vessel wall condition is determined by many variables of shear stress, out of which the amount of force, direction, and temporal and spatial variation exerts its effect significantly. We can easily understand the WSS, streamline flow disturbances, in our case by CFD study.<sup>[19,20]</sup>

However, the pathogenesis of unusual aneurysm formation is not identical to typical branching aneurysm, but some aneurysm may arise from the curvature of the parent vessel due to hemodynamic stress.<sup>[17]</sup> In our case, this unusual aneurysm arises from the concave surface of the MCA. Stebuns described that the atherosclerosis may be a causative factor of the aneurysm which is not related with any branching pattern.<sup>[21]</sup> Atherosclerosis causes narrowing of the lumen, and due to stenosis, the distal vessels become dilated which may be a causative factor of fusiform dilation. This causative agent has been studied pathologically.<sup>[18]</sup> Disturbed streamline flow also causes damage to the endothelial cells and causes the aneurysmal formation. Yoshimoto *et al.* found that in their case series, around half of the patients have atherosclerosis.<sup>[11]</sup> Kondo *et al.* also support this cause in experimental animals.<sup>[22]</sup> In our case, the MCA was atherosclerotic which supports the above studies. Ittichai Sakarunchai *et al.* observed in



**Figure 4:** Intraoperative microscopic view: (a) Initial arachnoid dissection, arrow indicates atherosclerotic plaque on the middle cerebral artery; (b) arrow showing aneurysmal neck and sac on the left direction; (c) Dual-image video angiography used to inspect the sac of aneurysm before clip application; (d and e) application of the aneurysmal clip; (f) repeat dual-image video angiography showing total occlusion of the sac of the aneurysm

their study that more than half of the patients of aneurysm associated with atherosclerotic aneurysmal wall had a coexisting hypertension.<sup>[23]</sup> Yoshimoto *et al.* also found the coexisting fusiform aneurysm in 50% of their patients. In these patients, they suggested that turbulent blood flow distal to the stenotic part of the parent vessel causes vibration in the vessel wall, and thus further weakening of elasticity causes the abnormal distention of the vessel wall.<sup>[11]</sup> Regarding unusual aneurysm, etiology fibromuscular dysplasia and infective endocarditis were explained, but these are very rare.<sup>[24,25]</sup> In our patient, both of the causes were ruled out.

### Surgery

This aneurysm was not associated with any branch; hence, dissection and applying the clip was not very difficult. In Yoshimoto's *et al.*'s study, the outcome was good in two-third of their cases.<sup>[11]</sup> However, every surgeon should keep several points in his/her mind that due to thin wall, the risk of rupture is high, and the atherosclerotic wall also causes the slippage of the clip. To avoid the rupture, keep the blades of the clip parallel to the parent artery. Some authors prefer hypotension and temporary clip on the parent artery while aneurysm clipping.<sup>[26]</sup> Some surgeons prefer wrapping with muscle and gauze. One should be careful in handling of perforator because in these patients, it is possible to have atherosclerotic perforators, and even gentle manipulation can cause vasospasm of perforators. Sakarunchai *et al.* introduced a new technique of surgical

clipping to avoid placing a clip in the atherosclerotic area to decrease the incidence of ischemia and leaving some areas of that yellow plaque.<sup>[23]</sup> After applying this technique, they observed good outcomes in the patients.

## Conclusion

Unusual location MCA aneurysm clinically and surgically resembles to that of the usual branching type of aneurysm. In our patient, we found that atherosclerosis, physiological curvature, and local hemodynamic stress induced the formation of this aneurysm without branching site. Clipping is not very difficult by expert hands in these types of cases, but due to thin-walled aneurysm and atherosclerosis, there are chances of intraoperative rupture and vasospasm for which we have to be more cautious.

## Declaration of patient consent

The authors certify that they have obtained all appropriate patient consent forms. In the form the patient(s) has/have given his/her/their consent for his/her/their images and other clinical information to be reported in the journal. The patients understand that their names and initials will not be published and due efforts will be made to conceal their identity, but anonymity cannot be guaranteed.

## Financial support and sponsorship

Nil.

## Conflicts of interest

There are no conflicts of interest.

## References

1. Brisman JL, Song JK, Newell DW. Cerebral aneurysms. *N Engl J Med* 2006;355:928-39.
2. Wiebers DO, Whisnant JP, Huston J 3<sup>rd</sup>, Meissner I, Brown RD Jr., Piepgras DG, *et al.* Unruptured intracranial aneurysms: Natural history, clinical outcome, and risks of surgical and endovascular treatment. *Lancet* 2003;362:103-10.
3. International study of Unruptured Intracranial Aneurysms Investigators. Unruptured intracranial aneurysm — Risk of rupture and risks of surgical intervention. *N Engl J Med* 1998;339:1725-33.
4. UCAS Japan Investigators; Morita A, Kirino T, Hashi K, Aoki N, Fukuhara S, *et al.* The natural course of unruptured cerebral aneurysms in a Japanese cohort. *N Engl J Med* 2012;366:2474-82.
5. Ulm AJ, Fautheree GL, Tanriover N, Russo A, Albanese E, Rhoton AL Jr., *et al.* Microsurgical and angiographic anatomy of middle cerebral artery aneurysms: Prevalence and significance of early branch aneurysms. *Neurosurgery* 2008;62:ONS344-52.
6. Paulo MS, Edgardo S, Fernando M, Pablo P, Alejandro T, Verónica V. Aneurysms of the middle cerebral artery proximal segment (M1) anatomical and therapeutic considerations revision of a series. Analysis of a series of the pre bifurcation segment aneurysms. *Asian J Neurosurg* 2010;5:57-63.
7. Ricci A, Di Vitantonio H, De Paulis D, Del Maestro M, Raysi SD, Murrone D, *et al.* Cortical aneurysms of the middle cerebral artery: A review of the literature. *Surg Neurol Int* 2017;8:117.
8. Rhoton AL Jr. Aneurysms. *Neurosurgery* 2002;51:S121-58.
9. Nutik S. Carotid paraclinoid aneurysms with intradural origin and intracavernous location. *J Neurosurg* 1978;48:526-33.
10. Fox JL. Microsurgical treatment of ventral (paraclinoid) internal carotid artery aneurysms. *Neurosurgery* 1988;22:32-9.
11. Yoshimoto Y, Ochiai C, Nagai M. Cerebral aneurysms unrelated to arterial bifurcations. *Acta Neurochir (Wien)* 1996;138:958-63.
12. Redekop GJ, Woodhurst B. Unusual aneurysms of the distal internal carotid artery. *Can J Neurol Sci* 1998;25:202-8.
13. Hosoda K, Fujita S, Kawaguchi T, Shose Y, Hamano S. Saccular aneurysms of the proximal (M1) segment of the middle cerebral artery. *Neurosurgery* 1995;36:441-6.
14. Sekhar LN, Heros RC. Origin, growth, and rupture of saccular aneurysms: A review. *Neurosurgery* 1981;8:248-60.
15. McCormick WF, Acosta-Rua GJ. The size of intracranial saccular aneurysms. An autopsy study. *J Neurosurg* 1970;33:422-7.
16. Stehbens WE. The pathology of intracranial arterial aneurysms and their complications. In: *Intracranial Aneurysms*. New York, NY: Springer; 1983.
17. Sano K. Internal carotid-posterior communicating anterior choroidal region aneurysms. Microsurgical treatment. In: Pia HW, Langmaid C, Zierski J, eds. *Berlin-Heidelberg-New York Springer* 1979;252-9.
18. Nixon AM, Gunel M, Sumpio BE. The critical role of hemodynamics in the development of cerebral vascular disease. *J Neurosurg* 2010;112:1240-53.
19. Cebral JR, Castro MA, Burgess JE, Pergolizzi RS, Sheridan MJ, Putman CM. Characterization of cerebral aneurysms for assessing risk of rupture by using patient-specific computational hemodynamics models. *AJNR Am J Neuroradiol* 2005;26:2550-9.
20. Hoi Y, Meng H, Woodward SH, Bendok BR, Hanel RA, Guterman LR, *et al.* Effects of arterial geometry on aneurysm growth: Three-dimensional computational fluid dynamics study. *J Neurosurg* 2004;101:676-81.
21. Stehbens WE. Etiology and pathogenesis of intracranial berry aneurysms. In: *Intracranial Aneurysms*. New York, NY: Springer US; 1983. p. 358-95.
22. Kondo S, Hashimoto N, Kikuchi H, Hazama F, Nagata I, Kataoka H. Cerebral aneurysms arising at nonbranching sites. An experimental Study. *Stroke* 1997;28:398-403.
23. Sakarunchai I, Kato Y, Yamada Y, Inamasu J. Ischemic event and risk factors of embolic stroke in atherosclerotic cerebral aneurysm patients treated with a new clipping technique. *J Stroke Cerebrovasc Dis* 2015;24:2497-507.
24. Barrow DL, Prats AR. Infectious intracranial aneurysms: Comparison of groups with and without endocarditis. *Neurosurgery* 1990;27:562-72.
25. Rhee RY, Głowiczki P, Cherry KJ Jr., Edwards WD. Two unusual variants of internal carotid artery aneurysms due to fibromuscular dysplasia. *Ann Vasc Surg* 1996;10:481-5.
26. Nakagawa F, Kobayashi S, Takemae T, Sugita K. Aneurysms protruding from the dorsal wall of the internal carotid artery. *J Neurosurg* 1986;65:303-8.