

Single Case

# Subungual Squamous Cell Carcinoma: The Diagnostic Challenge and Clinical Pearls

Wai Leong Kok Joyce Siong See Lee Martin Tze-wei Chio

National Skin Centre, Singapore, Singapore

## Keywords

Subungual squamous cell carcinoma · Nail bed tumours · Dermoscopy · Biopsy

## Abstract

Subungual squamous cell carcinoma is a rare entity and difficult to diagnose as its clinical presentation may resemble benign conditions. This case report highlights the need to maintain a high clinical index of suspicion, and recommends a practical approach for subungual conditions. Dermoscopy and a biopsy for histology are important adjuncts to clinch the diagnosis.

© 2016 The Author(s)  
Published by S. Karger AG, Basel

## Background

Subungual carcinomas are often undiagnosed as their clinical presentation may resemble benign conditions. Nail bed tumours range from squamous cell carcinomas (SCC), malignant melanomas, verrucous carcinomas to keratoacanthomas [1]. However, in the current literature, subungual SCC involving the toenails are uncommon [2].

## Case Report

A 58-year-old male, with no significant comorbidities, presented to our outpatient dermatology clinic with pain over his right fourth toe for 2 months. Notably, he reported prior trauma to the foot before the development of pain. Thereafter, the nail did not heal and he visited a primary care physician, who diagnosed an underlying viral wart, and he was referred for dermatological care. He was well, with no history of immunosuppression or human papillomavirus (HPV)-related infections.

Physical examination revealed a horizontal split of the toenail at the distal margin with a subungual verrucous papule, with features suspicious of a viral wart (fig. 1). He was commenced on cryotherapy and during his third session he developed purulent discharge and pain over that toe. Pyogenic cultures were despatched and the patient was commenced on empirical antibiotics. The pyogenic cultures grew *Staphylococcus aureus* and *Citrobacter* species sensitive to penicillin. The infection improved with a course of oral antibiotics and he was resumed on cryotherapy.

He returned 2 weeks later due to persistent discharge from the toe; in view of the lack of response to therapy, he then underwent a nail bed biopsy with nail avulsion, and histology revealed irregular buds and sheets of atypical well-differentiated squamous cells arising from the surface and invading the underlying dermis (fig. 2–4). There were also foci of dystrophic calcification present and a brisk lymphocytic infiltration. HPV stain was negative. A diagnosis of invasive well-differentiated SCC was made and the patient subsequently underwent surgical management by the orthopaedic surgeons.

## Discussion

Subungual SCC remain the most common primary malignant neoplasm of the nail bed, which usually presents in middle-aged male subjects aged 50–59 years [3], and have a higher incidence in the fingers, and rarely in the toes. Subungual carcinomas have a wide variety of presentation and are commonly mistaken as verruca vulgaris [4]. It is therefore important to exclude malignancy in non-resolving verrucae or recurrent infections of the toenail [5].

We propose that the physician should note the following important features and clinical algorithm in evaluating a subungual lesion as presented in figure 5. In the history taking, chronic pain, splitting of nails, or change in nail colour and immunosuppression as a risk factor or previous history of HPV-related infections should be elucidated [3]. Other risk factors include radiation exposure, chronic infection, arsenic ingestion and prior trauma [6]. A thorough physical examination of the affected nail is required, looking for features such as nail plate variation, hyperkeratosis and nodularity. However, worrying signs include an uncharacteristic site of onycholysis, a friable lesion, and a chronically infected nail bed with ulceration. If direct dermoscopy can be performed, it is useful to look for longitudinal melanonychia or erythronychia, irregular vascularity, and haemorrhages [7]. If direct visualization of the nail bed is not possible, removal of the nail bed for further examination is required and a nail bed matrix biopsy for histology is mandatory. Nail avulsion for exposure is required and normal tissue should be included in the specimen [8]. HPV staining, although not routine, should be considered because type 16 HPV associations have been found most commonly, albeit in fingernails, for Bowen's disease and SCC [9]. However, other high-risk HPV subtypes such as HPV26, HPV33, HPV51, HPV56 and HPV73 have been found as well [10]. In the same study by Kreuter et al. [10], HPV-associated subungual SCC had a higher

expression of p16INK4a and Ki67 biomarkers compared to non-HPV subungual SCC. The higher proliferative rate in the former may suggest a potentially more aggressive course than the latter.

Treatment options are dependent on the extent of the disease and include wide local excision, digital amputation, and Mohs surgery. Mohs surgery offers maximal tissue conservation and is often considered the gold standard for treating subungual SCC, as it allows the evaluation of periosteal invasion to be distinguished from inflammation or compression [5]. Local adjuvant treatment, such as curettage, imiquimod or carbon dioxide laser, can be used to reduce recurrence in patients with co-existing HPV infection [11].

Subungual SCC may be locally invasive but rarely metastasizes. However, complete wide local excision of the tumour may be required to prevent recurrence, especially if there is evidence of local invasion [4], as bony involvement can be found in up to 20% of patients [12]. Our patient was referred promptly and underwent surgical excision due to the locally invasive disease. Lastly, it is also suggested that HPV-positive cases be followed up closely as HPV-associated subungual SCC has been found to be more likely to recur after surgery [9].

## Conclusion

Subungual SCC is an uncommon carcinoma that may mimic a benign verruca. Physicians need to maintain heightened awareness and to consider a biopsy for suspicious lesions that are not responding to treatment. The proposed clinical algorithm serves as a useful tool for physicians in the outpatient dermatological setting to aid in the clinical diagnosis of this condition.

## Statement of Ethics

Informed consent for publishing the case was obtained from the patient.

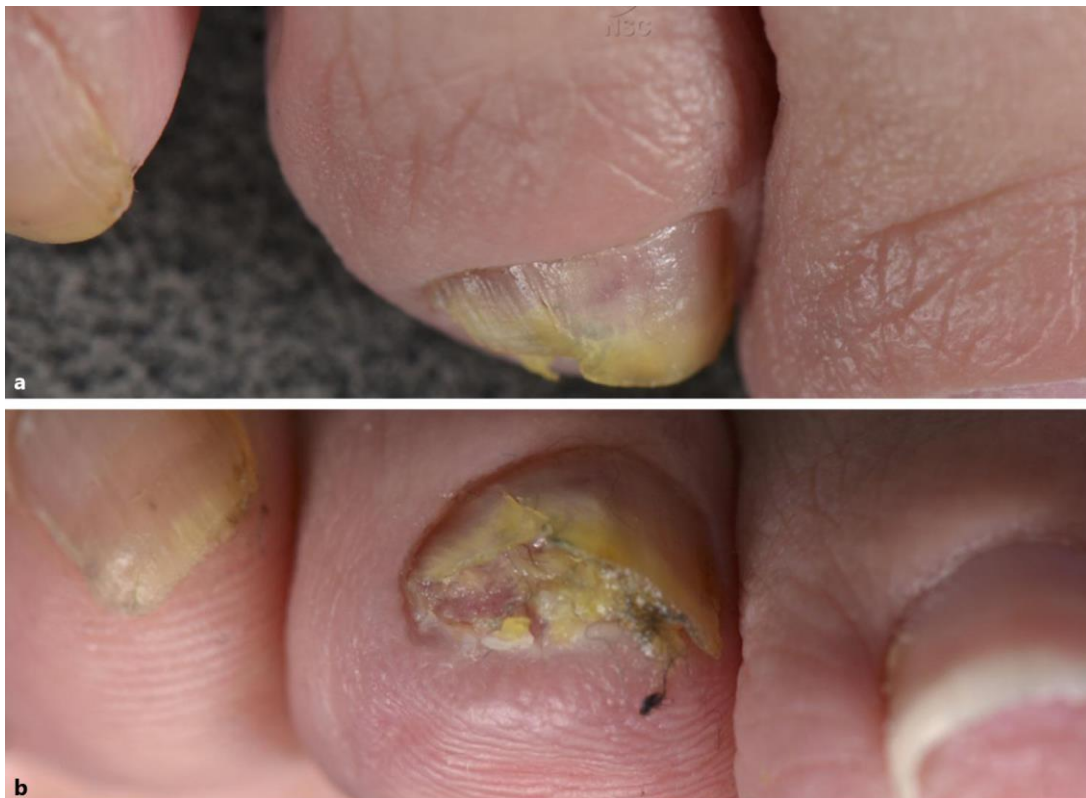## Disclosure Statement

The authors declare no conflicts of interest.

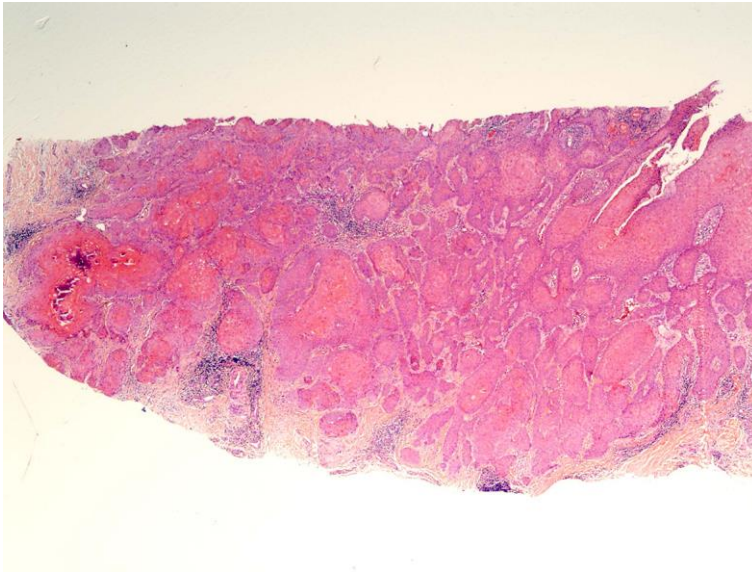
## References

- 1 Nasca MR, Innocenzi D, Micali G: Subungual squamous cell carcinoma of the toe: report on three cases. *Dermatol Surg* 2004;30:345–348.
- 2 Morule A, Adamthwaite DN: Squamous carcinoma of the nail bed: a case report. *S Afr Med J* 1984;65:63–64.
- 3 Riddel C, Rashid R, Thomas V: Ungual and periungual human papillomavirus-associated squamous cell carcinoma: a review. *J Am Acad Dermatol* 2011;64:1147–1153.
- 4 Gordon DK, Ponder EN, Berrey BH, Kubik MJ, Sindone J: Verrucous carcinoma of the foot, not your typical plantar wart: a case study. *Foot (Edinb)* 2014;24:94–98.
- 5 Bizzle PG: Subungual squamous cell carcinoma of the thumb masked by infection. *Orthopedics* 1992;15:1350–1352.
- 6 Oon HH, Kumarasinghe SP: Subungual squamous cell carcinoma masquerading as a melanotic macule. *Singapore Med J* 2008;49:e76–e77.
- 7 Dika E, Fanti PA, Patrizi A, Misciali C, Vaccari S, Piraccini BM: Mohs surgery for squamous cell carcinoma of the nail unit: 10 years of experience. *Dermatol Surg* 2015;41:1015–1019.

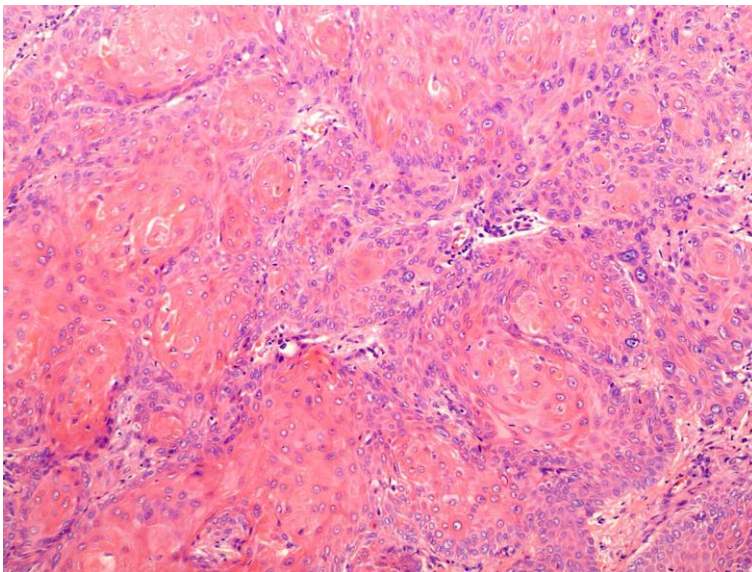
- 8 Patel PP, Hoppe IC, Bell WR, Lambert WC, Fleegler EJ: Perils of diagnosis and detection of subungual squamous cell carcinoma. *Ann Dermatol* 2011;23(suppl 3):285–287.
- 9 Alam M, Caldwell JB, Eliezri YD: Human papillomavirus associated digital squamous cell carcinoma: literature review and report of 21 new cases. *J Am Acad Dermatol* 2003;48:385–393.
- 10 Kreuter A, Gambichler T, Pfister H, Wieland U: Diversity of human papillomavirus types in periungual squamous cell carcinoma. *Br J Dermatol* 2009;161:1262–1269.
- 11 Ruiz Santiago H, Morales-Burgos A: Cryosurgery as adjuvant to Mohs micrographic surgery in the management of subungual squamous cell carcinoma. *Dermatol Surg* 2011;37:256–258.
- 12 Attiyeh FF, Shah J, Booher RJ, Knapper WH: Subungual squamous cell carcinoma. *JAMA* 1979;241:262–263.



**Fig. 1.** Clinical photographs showing the verrucous lesion (a) under the nail bed and after partial trimming of the nail (b).

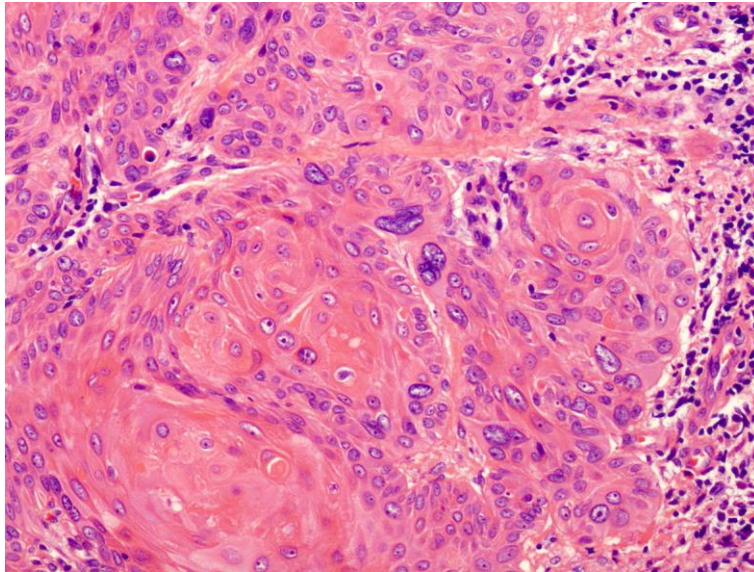


**Fig. 2.** Within the nail bed, tongues of atypical squamous epithelium invade deeply into the dermis. H&E stain, magnification  $\times 20$ .

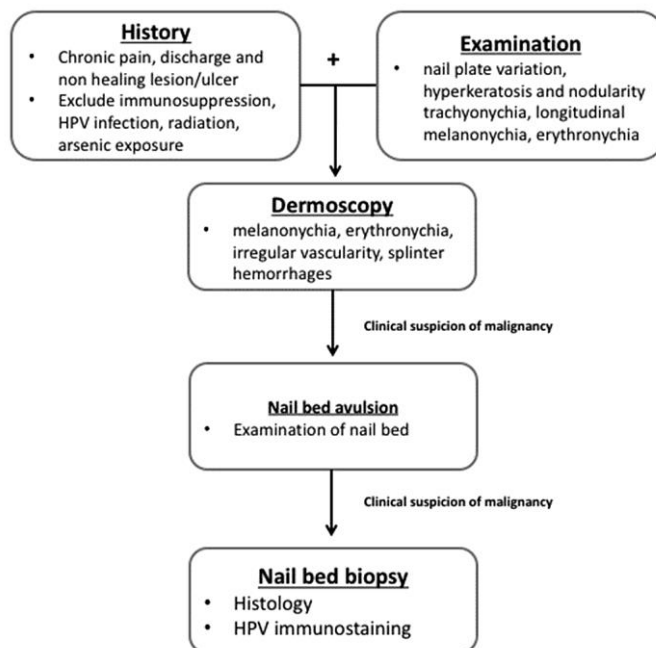


**Fig. 3.** Atypical squamous epithelium with dyskeratinization and pleomorphic keratinocytes. H&E stain, magnification  $\times 100$ .





**Fig. 4.** Whorls of dyskeratinization with atypical keratinocytes featuring pleomorphic nuclei. H&E stain, magnification  $\times 200$ .



**Fig. 5.** A proposed clinical approach to evaluate subungual lesions.