



Case Report

Intermittent ice-cooling to prevent skin heat injury caused by high-intensity focused ultrasound therapy targeting desmoid-type fibromatosis: A case report

Liangyu Fang ^a, Xiaoye Hu ^b, Yinchuan Xu ^c, Hongling Sun ^d, Hong Shen ^{b,*}

^a Department of Anesthesiology, The Second Affiliated Hospital of Zhejiang University, School of Medicine, Hangzhou, China

^b Department of Medical Oncology, The Second Affiliated Hospital of Zhejiang University, School of Medicine, Hangzhou, China

^c Department of Cardiology, The Second Affiliated Hospital of Zhejiang University, School of Medicine, Hangzhou, China

^d Department of Specialist Nursing, The Second Affiliated Hospital of Zhejiang University, School of Medicine, Hangzhou, China

ARTICLE INFO

Article history:

Received 14 September 2020

Received in revised form

30 November 2020

Accepted 14 December 2020

Available online 18 December 2020

Keywords:

Adult

Aggressive fibromatosis

Burns

High-intensity focused ultrasound ablation

Ice

Skin temperature

ABSTRACT

Introduction: Desmoid-type fibromatosis (DF) is a fibrous tumor characterized by low-grade malignant and easy invasive growth and high recurrence. High-intensity focused ultrasound (HIFU) therapy has been identified as a novel non-invasive approach for DF treatment; however, the ultrasonic energy generated by HIFU can cause skin heat injury.

Case: A 31-year-old female patient with signs and symptoms of DF received treatment in our institution. The patient had undergone HIFU treatment six times from April 27, 2018, to August 21, 2019. After HIFU therapy for the third time, she had a third-degree skin burn showing as orange peel-like change and spent three months to promote the recovery of the skin lesions. An intermittent ice-cooling strategy was used to avoid skin damage during the fourth HIFU treatment. This patient did not have any apparent skin injury during the last three HIFU therapy and acquired satisfactory anti-tumor therapeutic effect.

Conclusions: There are differences in the thermal selectivity of tumor tissues, which leads to different critical thermal injury temperature values that the tissue can tolerate. Ice-cooling can lower skin tissue temperature and reduce the thermal damage caused by HIFU treatment.

© 2020 The authors. Published by Elsevier B.V. on behalf of the Chinese Nursing Association. This is an open access article under the CC BY-NC-ND license (<http://creativecommons.org/licenses/by-nc-nd/4.0/>).

What is known?

- High-intensity focused ultrasound (HIFU) technology has been considered as a novel non-invasive therapeutic strategy for the treatment of aggressive fibrous sarcoma. However, skin burns is one of the complications of HIFU.

What is new?

- Intermittent ice-cooling strategy can prevent and reduce the skin burns caused by high-intensity focused ultrasound treatment of aggressive fibrous sarcoma.

1. Introduction

Desmoid-type fibromatosis (DF) is a fibrous tumor formed by

* Corresponding author.

E-mail address: shenhong0023@zju.edu.cn (H. Shen).

Peer review under responsibility of Chinese Nursing Association.

the clonal proliferation of fibroblasts or myofibroblasts within deep soft tissues, including muscle, fascia, or tendon. It is a rare interstitial tumor that lacks the capacity of long distant metastatic; however, it can invade adjacent important structures and organs and has a high recurrence rate [1]. DF mainly occurs in females, and the abdominal wall is one of its common lesion locations. Although surgery is the first choice for the treatment of DF, it could not provide a good long-term disease-free survival rate. Previous studies have demonstrated that the local recurrence rate of DF can be as high as 70% [2,3]. The technology of high-intensity focused ultrasound (HIFU) therapy has been considered as a novel non-invasive therapeutic strategy for solid tumors treatment [4]. Compared with other traditional approaches, HIFU has the advantages of high therapeutic accuracy and less destructive to the tissues adjacent to the lesion. Multiple clinical trials have proved the safety and feasibility of HIFU for the treatment of DF [5–8].

HIFU destroys the lesion through the ultrasonic energy generated by the external transducer. The incidence of several complications such as visceral bleeding and visceral perforation can be increased with the enhanced ultrasound energy, and skin burn is

one of the most common complications caused by HIFU [9,10]. Previous studies have revealed that the incidence of heat injury in subcutaneous fat and anterior abdominal wall muscle caused by HIFU can reach 11% [11,12]; so far, the effective preventive measures for tissue heat damage induced by HIFU therapy remain limited. Here, we presented a case report of a female patient with DF who had to stop HIFU therapy due to a third-degree skin burn. Subsequently, when this patient received high-dose, long-term HIFU treatment at the same lesion, intermittent ice-cooling during HIFU therapy could effectively prevent skin heat injury without affecting the therapeutic efficacy of the tumor.

2. Case report

2.1. Patient information

A 31-year-old female with a solid mass located in the left lower abdominal wall, with a size of 6.4 cm × 4.2 cm × 5.1 cm went to our institution, the Second Affiliated Hospital of Zhejiang University, School of Medicine, in April 2018. The patient is from the southern coastal area. She felt a swelling in the left groin area (close to the cesarean section scar) after a cesarean section surgery in March 2013, with no tenderness and no skin redness. An ultrasound examination by a local hospital revealed a hypoechoic mass on the left lower abdominal wall. Subsequently, surgical resection was performed, and the postoperative pathology suggested invasive DF (Fig. 1 A). Four months after the operation, the patient found a mass in the operation area by herself, and a second operation was performed in July 2013, followed by the postoperative pathology report revealing recurrence of invasive DF. This patient had tumor recurrence three times in the same location in the following five years, from 2013 to 2018, and she received surgery three times and radiotherapy for once. In March 2018, she had found a mass in the left lower abdominal wall again. The Magnetic resonance imaging (MRI) examination by another local hospital showed the recurrence of DF of 3.1 cm × 3.4 cm × 2.7 cm in March 2018 (Fig. 1 B). Subsequently, this patient was admitted to our hospital in April 2018.

Considering surgical difficulty caused by the complex adhesion between the tumor and the surrounding tissues as well as the disagreement of surgery from the patient, we ultimately performed HIFU ablation to treat DF after acquiring the patient's informed consent. The patient had received HIFU treatment six times from April 27, 2018, to August 21, 2019. In the first two HIFU treatments, the patient suffered mild skin injury. After the third HIFU therapy, she had a third-degree skin burn showing an orange peel-like change. Therefore, the patient had to stop the treatment and take three months for skin lesion recovery. During the fourth HIFU

treatment, intermittent ice-cooling therapy was used to avoid skin damage. After intermittent ice-cooling therapy, the skin surface temperature decreased significantly (Fig. 2). The patient did not have obvious skin injury during the three subsequent HIFU treatments (Fig. 3) and acquired a good anti-tumor therapeutic effect (Fig. 4). The patient was suggested to receive regular MRI examinations with an interval of 3 months. So far, there is no sign of recurrence. In this case, the patient's written informed consent for releasing case data and images has been obtained. The detailed ethical information has been approved by the ethics committee of the Second Affiliated Hospital of Zhejiang University, School of Medicine (2020784).

2.2. High-intensity focused ultrasound treatment

The FEP-BY02 high-intensity focused ultrasound tumor treatment system (Yuande Biomedical Engineering Co. Ltd, Beijing, China) was used, and the HIFU procedure was performed by Hu et al. [13] in this case. During the operation, a pulsed heat accumulation approach was applied to dynamically modulate the therapeutic area, intensity and dose based on the intraoperative ultrasound contrast imaging. The therapeutic regimen during HIFU was performed as previously described: T1 emission time is 200 ms; T2 interval time is 200 ms; a total number of shots at each therapeutic point is 25 times (lasting 10 s), keeping a spacing of 1 mm between adjacent treatment slices; Every three therapeutic points composed one unit with 30 s interval between units, and the whole therapeutic process was divided into three sections including five therapeutic units for each. The details of HIFU treatment were available in Table 1. During the operation, we firstly used an ultrasound coupling agent to the skin area that is or may be in contact with the ultrasound water bladder. It can fill the tiny gaps between the contact surfaces, reduce the reflection loss of ultrasonic energy at this interface. It also plays a "lubricating" role to reduce the friction between the probe surface and the skin. After a round of HIFU treatment, we use sonovi to perform ultrasound contrast to determine whether the treatment is effective. Then we adjust the position of the center point of ultrasound treatment for the next round of HIFU treatment. When there is a mass gray change in the treatment area or an obvious overall gray increase, and sonovi-used Doppler ultrasound immediately after treatment shows no obvious blood-flow signal inside the lesion, it is the standard for effective and discontinuation of treatment. After the treatment, the magnetic resonance examination is used as the evidence to determine whether the treatment is needed again.

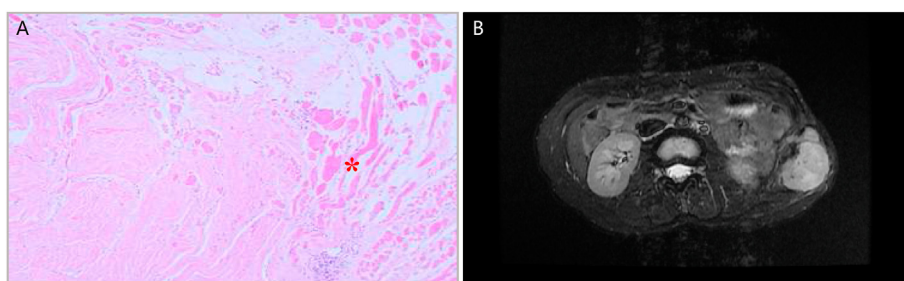


Fig. 1. Invasive desmoid-type fibromatosis of the patient. (A) H & E staining of the specimen from the patient in 2013 showed that the mass was irregular and infiltrated the adipose tissue (original magnification × 40). The red asterisk indicated the lesion. (B) MRI scan in 2018. MRI = magnetic resonance imaging.

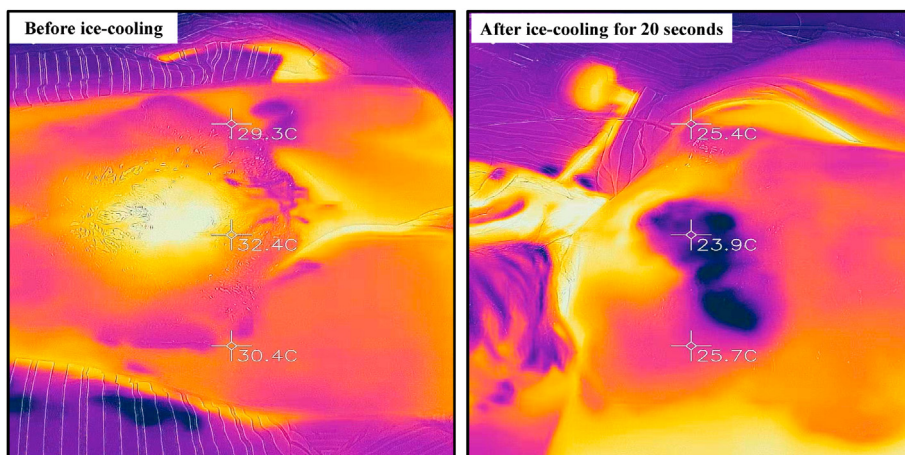


Fig. 2. The change of the patient's skin surface temperature during HIFU therapy. HIFU = high-intensity focused ultrasound.

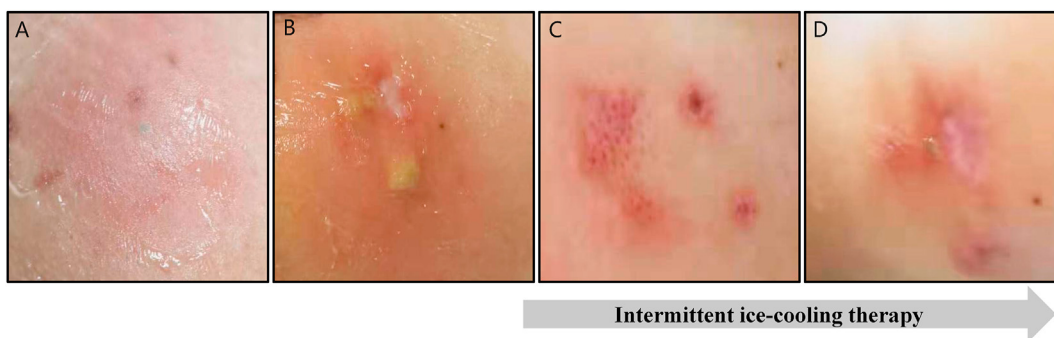


Fig. 3. The patient's skin changes after HIFU treatment. (A) Mild skin injury after the 1st HIFU treatment. (B) Skin burn due to the 3rd HIFU treatment. (C) Mild skin injury after the 5th HIFU treatment. (D) Mild skin injury after the 6th HIFU treatment. HIFU = high-intensity focused ultrasound.

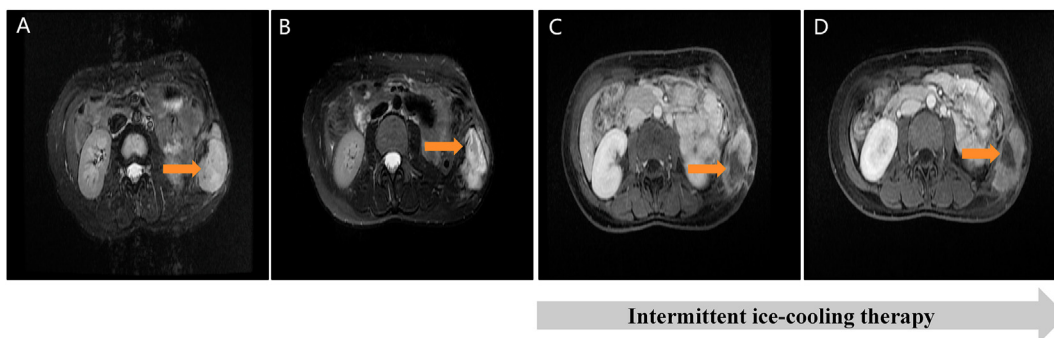

Fig. 4. Therapeutic effect of HIFU treatment on tumor detected by MRI. (A) Before the 1st HIFU treatment. (B) After the 1st HIFU treatment. (C) After the 3rd HIFU treatment. (D) After the 6th HIFU treatment. Red arrows indicated the lesion. HIFU = high-intensity focused ultrasound. MRI = magnetic resonance imaging.

Table 1

The detailed parameters utilized in multiple times of high-intensity focused ultrasound treatment for the patient.

HIFU treatment sequence	Performing date	Ultrasonic power (W)	Total emission energy (J)	Total treatment duration (min)	Total ice-cooling duration (min)
1	2018-04-27	500–520	40320.3	39.53	5.25
2	2018-05-23	420–480	49780.0	59.18	7.75
3	2018-07-04	360–400	44357.4	58.90	6.25
4	2018-12-05	350–400	64242.7	66.30	9.00
5	2019-07-19	420	65266.1	70.92	8.25
6	2019-08-21	520	198681.1	122.77	15.00

2.3. The process of intermittent ice-cooling therapy

We prepared ice packs before conducting HIFU treatment. To ensure patient safety and prevent infection, we injected 0.5ml solution of methylene blue into 500 ml sodium lactated ringer's injection in a VIAFLEX plastic container (produced by Shanghai Baxter Medical Products Co., Ltd.) and put it into a medical freezer (-4°C) to make an ice pack. During the process of HIFU treatment, we launched the ice-cooling therapy when we found that the patient's skin color changed. At the end of each round of HIFU treatment, the ice pack was placed onto the reddest spot on the patient's skin lesion for 10 s during the intermitted period of the HIFU therapeutic unit, then HIFU therapy was continued. These steps were cycled until the end of the treatment. If the skin appeared redness and swelling during the treatment, the ice-cooling duration would be extended to 20 s. If the skin became blister-like or dark, the total ice-cooling duration could be extended to 30 s. In addition, if noticeable blisters appear in the skin after the completion of HIFU therapy, the ice-cooling therapy could continue for 60 s, then stop for 30 s. The ice-cooling therapy could be cycled for a total of 10 min. When a round of ultrasound ablation treatment was finished, the skin temperature of the treatment point was measured with an infrared temperature irradiation equipment, FLIR ONE Pro thermal imaging camera (produced by Beijing Chuangcheng Zhijia Technology Co., Ltd.). After ice-cooling for 10 s, the patient's skin temperature of the treatment point was reduced by 6–10 $^{\circ}\text{C}$ on average.

3. Discussion

The biological characteristics of DF are low-grade malignant as well as easy invasive growth and high recurrence. Previous studies have revealed that HIFU is the first choice for treating DF, and surgical damage may also promote tumor recurrence [2]. Although HIFU has been identified as an effective non-invasive approach for DF treatment, the ultrasonic energy generated by HIFU therapy may cause heat injury [10]. This case report suggested that intermittent ice-cooling during HIFU can effectively prevent and reduce skin heat damage without affecting the therapeutic efficacy.

Selective hyperthermia therapy targeting tumor allows the reduction of blood flow within the tumor tissue compared with that in the surrounding tissue [14]. The temperature within the central part of the tumor tissue is usually 3–7 $^{\circ}\text{C}$ higher than the temperature within the surrounding tissue, which can cause the lethality of the tumor without damaging the surrounding normal tissue [15]. Therapeutic efficacy would be achieved ideally without skin heat injury if only lesion tissue absorbed heat energy while the skin tissue does not absorb it. However, the heterogeneity of tumor tissue can reduce the absorption of heat energy of tumor tissue, leading to decreased therapeutic effect and increased incidence of a complication caused by hyperthermia ablation. Ice-cooling can decrease local skin temperature, reduce local blood flow, and prevent tissue swelling and congestion. Meanwhile, ice can artificially decrease the temperature of the skin tissue around the tumor, causing a significant temperature difference between tumor tissue and its surrounding tissue, thus improve the therapeutic efficacy of selective hyperthermia ablation [16,17].

The effect of ice-cooling is mainly determined by the temperature changes within the tissue. Normal human skin temperature fluctuates from 20 $^{\circ}\text{C}$ to 47 $^{\circ}\text{C}$. When the skin surface temperature declines to 15 $^{\circ}\text{C}$, the cell metabolic rate starts to decrease. Furthermore, when the temperature reaches 10–11 $^{\circ}\text{C}$, the rate of cell metabolism decreases by 50%, indicating that the temperature of 15–20 $^{\circ}\text{C}$ is safe for skin care [18].

In previous cases of HIFU treatment, we used an infrared irradiator to measure the skin surface temperature and found that ice-cooling

for 10 s during the HIFU therapy led to the reduction of surface skin temperature by about 20 $^{\circ}\text{C}$. In the current case, we found that the skin temperature gradually increased with the extension of the HIFU time, reached the highest (40 $^{\circ}\text{C}$) at the moment of stopping the emission, and thereafter gradually decreased. Therefore, intermittent ice-cooling for 10 s to remain the skin surface temperature at 20 $^{\circ}\text{C}$, thus can prevent skin burns. Additionally, in the case of redness, swelling, and blisters appeared on the patient's skin, we extended ice-cooling duration to allow the heat diffused from deep tissues with high temperature to surrounding tissues with low temperature. The skin temperature was reduced to 15 $^{\circ}\text{C}$, and effectively attenuate heat injury caused by HIFU treatment.

In this study, ice-cooling therapy can effectively prevent the patient's skin burns. However, the patient's total HIFU treatment time was extended. The reason is that high-intensity focused ultrasound is a thermal ablation treatment. Through heat conduction, ice-cooling reduces the heat accumulation of the tissue. In order to achieve the same ablation goal, it is necessary to extend the time of heat accumulation, which leads to a prolonged treatment time for the operation. Furthermore, the heterogeneity of tumor tissue leads to the different tolerance of tumor tissue to heat energy. The specific cooling duration and area for specific tumors treated with HIFU need to be determined. Large-scale clinical trials need to be carried out in the future.

4. Conclusions

HIFU is an effective treatment for invasive fibromatosis, but there is a risk of skin heat damage during the treatment. Ice-cooling can prevent thermal damage to the skin tissue during HIFU treatment and reduce the degree of skin injury during thermal damage. It may be one of the methods to prevent heat injury during HIFU treatment.

Funding

This study was supported by the Medical and Health Science and Technology Project of Zhejiang Province (No. 2019325236), the Appropriate Technology Cultivation and Promotion Project of Zhejiang Medical and Health Office (2019325236).

Availability of data and materials

The data used and/or analyzed during the current study are available from the corresponding author on reasonable request.

CRedit authorship contribution statement

Liangyu Fang: Data curation, Writing - original draft. **Xiaoye Hu:** Conceptualization, Methodology. **Yinchuan Xu:** Writing - review & editing. **Hongling Sun:** Visualization, Investigation. **Hong Shen:** Supervision.

Declaration of competing interest

The authors declare that they have no competing interests.

Acknowledgement

The authors thank all participants in the study.

Appendix A. Supplementary data

Supplementary data to this article can be found online at <https://doi.org/10.1016/j.ijnss.2020.12.006>.

References

- [1] Otero S, Moskovic EC, Strauss DC, Benson C, Miah AB, Thway K, et al. Desmoid-type fibromatosis. *Clin Radiol* 2015;70(9):1038–45. <https://doi.org/10.1016/j.crad.2015.04.015>.
- [2] Shen CY, Wang CS, Yan JQ, He T, Zhou XQ, Ma WJ, et al. Clinicopathological characteristics, treatment, and survival outcomes of retroperitoneal desmoid-type fibromatosis: a single-institution experience in China. *Medicine* 2019;98(47):e18081. <https://doi.org/10.1097/md.00000000000018081>.
- [3] Skubitz KM. Biology and treatment of aggressive fibromatosis or desmoid tumor. *Mayo Clin Proc* 2017;92(6):947–64. <https://doi.org/10.1016/j.mayocp.2017.02.012>.
- [4] Copelan A, Hartman J, Chehab M, Venkatesan AM. High-intensity focused ultrasound: current status for image-guided therapy. *Semin Intervent Radiol* 2015;32(4):398–415. <https://doi.org/10.1055/s-0035-1564793>.
- [5] Endo Y. CORR insights®: is MR-guided high-intensity focused ultrasound a feasible treatment modality for desmoid tumors? *Clin Orthop Relat Res* 2016;474(3):705–6. <https://doi.org/10.1007/s11999-015-4427-2>.
- [6] Avedian RS, Bitton R, Gold G, Butts-Pauly K, Ghanouni P. Is MR-guided high-intensity focused ultrasound a feasible treatment modality for desmoid tumors? *Clin Orthop Relat Res* 2016;474(3):697–704. <https://doi.org/10.1007/s11999-015-4364-0>.
- [7] Wang Y, Wang W, Tang J. Ultrasound-guided high intensity focused ultrasound treatment for extra-abdominal desmoid tumours: preliminary results. *Int J Hyperther* 2011;27(7):648–53. <https://doi.org/10.3109/02656736.2011.597047>.
- [8] Zhao WP, Han ZY, Zhang J, Yu XL, Cheng ZG, Zhou X, et al. Early experience: high-intensity focused ultrasound treatment for intra-abdominal aggressive fibromatosis of failure in surgery. *Br J Radiol* 2016;89(1062):20151026. <https://doi.org/10.1259/bjr.20151026>.
- [9] Christoph GT, Robert S, Dirk André C, Peter H, Irene M, Sabine K, et al. Magnetic resonance imaging-guided focused ultrasound treatment of symptomatic uterine fibroids: impact of technology advancement on ablation volumes in 115 patients. *Invest Radiol* 2013;48(6):359–65. <https://doi.org/10.1097/RLI.0b013e3182806904>.
- [10] Gizzo S, Saccardi C, Patrelli TS, Ancona E, Noventa M, Fagherazzi S, et al. Magnetic resonance-guided focused ultrasound myomectomy: safety, efficacy, subsequent fertility and quality-of-life improvements, a systematic review. *Reprod Sci* 2014;21(4):465–76. <https://doi.org/10.1177/1933719113497289>.
- [11] Cheung VYT. High-intensity focused ultrasound therapy. *Best Pract Res Clin Obstet Gynaecol* 2018;46:74–83. <https://doi.org/10.1016/j.bpobgyn.2017.09.002>.
- [12] Chen JY, Chen WZ, Zhang L, Li KQ, Peng S, He M, et al. Safety of ultrasound-guided ultrasound ablation for uterine fibroids and adenomyosis: a review of 9988 cases. *Ultrason Sonochem* 2015;27:671–6. <https://doi.org/10.1016/j.ultsonch.2015.05.031>.
- [13] Zhao J, Wang Q, Li X, Hu X, Shen H. Effective high intensity focused ultrasound treatment in recurrent aggressive breast fibromatosis: a case report. *Oncotargets Ther* 2019;12:5251–6. <https://doi.org/10.2147/ott.s202933>.
- [14] Crum LA, Fowlkes JB. Acoustic cavitation generated by microsecond pulses of ultrasound. *Nature* 1986;319(6048):52–4. <https://doi.org/10.1038/319052a0>.
- [15] Dellian M, Walenta S, Kuhnle GEH, Gamarra F, Mueller-Klieser W, Goetz AE. Relation between autoradiographically measured blood flow and ATP concentrations obtained from imaging bioluminescence in tumors following hyperthermia. *Int J Canc* 1993;53(5):785–91. <https://doi.org/10.1002/ijc.2910530514>.
- [16] Yuan J, Wu C, Holland AJA, Harvey JG, Martin HCO, La Hei ER, et al. Assessment of cooling on an acute scald burn injury in a porcine model. *J Burn Care Res* 2007;28(3):514–20. <https://doi.org/10.1097/bcr.0b013e318053db13>.
- [17] Cho YS, Choi YH. Comparison of three cooling methods for burn patients: a randomized clinical trial. *Burns* 2017;43(3):502–8. <https://doi.org/10.1016/j.burns.2016.09.010>.
- [18] Prins JC, Stubbe JH, van Meeteren NL, Scheffers FA, van Dongen MC. Feasibility and preliminary effectiveness of ice therapy in patients with an acute tear in the gastrocnemius muscle: a pilot randomized controlled trial. *Clin Rehabil* 2011;25(5):433–41. <https://doi.org/10.1177/0269215510388312>.