



Successful management of a rudimentary uterine horn ectopic pregnancy by combining methotrexate and surgery: A case report

Ângela Rodrigues^{a,b,*}, Ana Raquel Neves^{a,b}, Maria Geraldina Castro^b, Miguel Branco^c,
Fernanda Geraldês^b, Fernanda Águas^b

^a University Clinic of Gynaecology, Faculty of Medicine, University of Coimbra, Clinical Academic Centre of Coimbra, CACC, Coimbra, Portugal

^b Department of Gynaecology, Coimbra Hospital and University Centre, Coimbra, Portugal

^c Department of Obstetrics, Coimbra Hospital and University Centre, Coimbra, Portugal

ARTICLE INFO

Article history:

Received 26 September 2019

Received in revised form 21 October 2019

Accepted 28 October 2019

Keywords:

Mullerian anomaly

Rudimentary horn pregnancy

Ectopic pregnancy

Methotrexate treatment

ABSTRACT

Pregnancy in a non-communicating rudimentary uterine horn is rare but presents a significantly increased risk of maternal and foetal morbidity due to uterine rupture.

We describe a case of rudimentary horn pregnancy diagnosed in the first trimester in an asymptomatic and haemodynamically stable woman. Medical termination of the pregnancy was performed with systemic and intrasacular methotrexate. Laparoscopic uterine horn excision was performed three months after termination.

This case shows that early diagnosis of a rudimentary horn pregnancy is key to the successful management of this condition. Preoperative medical termination in an asymptomatic woman proved to be an effective and safe option that minimized surgical risks.

© 2019 Published by Elsevier B.V. This is an open access article under the CC BY-NC-ND license (<http://creativecommons.org/licenses/by-nc-nd/4.0/>).

1. Introduction

The prevalence of rudimentary horn pregnancy is very low (1 in 76 000–150 000 pregnancies) [1,3–6,9,12,13,18]. It mainly occurs in a non-communicating rudimentary horn by transperitoneal migration of sperm or fertilized ovum [3–6,9,11,12]. The maternal and foetal prognosis in unrecognized rudimentary horn ectopic pregnancy is poor, with an average neonatal survival rate of 6% [11,15] and rate of uterine rupture close to 80% [1,2,4,5,11,15]. Due to this potentially life-threatening maternal complication and catastrophic foetal outcome, the classical treatment for this type of ectopic pregnancy is surgical excision of the entire rudimentary horn [1,15,17]. However, medical management followed by delayed surgical resection may be a therapeutic option due to current improvements in early diagnosis [15]. Nevertheless, there are very few reported cases in the literature regarding the diagnosis and management during the first trimester of asymptomatic patients without complications [2,13].

We report a case of complete laparoscopic excision of a rudimentary uterine horn and homolateral salpingectomy three

months after successful preoperative medical termination of an ectopic pregnancy.

2. Case report

A 34-year-old asymptomatic woman, gravida 4, para 1, was admitted to the emergency department at week 6 of gestation with a suspected ectopic pregnancy following prenatal ultrasound.

Regarding her obstetric history, she had a previous right tubal ectopic pregnancy treated with methotrexate, a first trimester spontaneous miscarriage and an elective caesarean section due to anomalous foetal position. With respect to her gynaecological history, a previous ultrasound scan had shown a 30 mm right-sided “pediculated myoma”.

Transvaginal ultrasound showed a gestational sac with a viable embryo with a crown-rump length of 4.6 mm, leading to diagnosis of right tubal ectopic pregnancy. In order to confirm these findings, diagnostic laparoscopy was performed. Both fallopian tubes and ovaries were normal but a left hemi-uterus with a pregnancy in the right rudimentary horn was found (Figs. 1 and 2).

A subsequent 3D ultrasound scan supported the diagnosis of a left hemi-uterus with a viable ectopic pregnancy on the right rudimentary horn, and suggested the presence of non-communicating cavities. These findings confirmed the diagnosis of a U4a uterine anomaly according to the ESHRE/ESGE classification [19] (Fig. 3).

* Corresponding author at: Azinhaga de Santa Comba, 3000-354, Coimbra, Portugal.

E-mail address: angela.reisrodrigues@gmail.com (Â. Rodrigues).

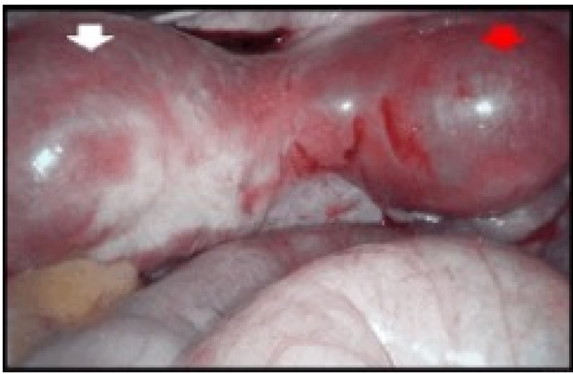

Fig. 1. Laparoscopic view of the left hemi-uterus (white arrow) and the right rudimentary horn (red arrow) containing the ectopic pregnancy before medical treatment. (For interpretation of the references to colour in this figure legend, the reader is referred to the web version of this article).

Clinical findings, prognosis and therapeutic options were explained to the patient and pregnancy termination was decided. Informed consent was obtained from the patient in order to report this case.

Before the procedure, she was clinically asymptomatic with a quantitative β human chorionic gonadotropin (β -hCG) level of 58,536 mUI/mL. The patient received 60 mg of intramuscular methotrexate (1 mg/kg). On the same day, transvaginal ultrasound-guided puncture of the gestational sac was performed, with drainage of 2 ml of extraembryonic fluid and a single-dose of MTX (50 mg) was injected. It was decided not to infuse intrasacral KCl because embryo cardiac activity was no longer present. On day 3, the β -hCG level had decreased to 43,796 mUI/mL and on day 5 it was 26,093 mUI/mL. The patient was attended weekly to follow β -hCG level, which had decreased to 32 mUI/mL 6 weeks later. At the same time, ultrasound demonstrated progressive regression of the trophoblast content.

Seven weeks after medical treatment, a pelvic magnetic resonance imaging (MRI) scan was obtained to better characterize the mullerian anomaly. This showed a rudimentary horn with involutive trophoblastic tissue connected to the left hemi-uterus by a fibrous band (Fig. 4). No urinary malformations were identified.

Approximately three months after the pregnancy termination, laparoscopic resection of the right rudimentary uterine horn and right salpingectomy were performed without incident. The intervention was carried out with a 10 mm laparoscope in the umbilical scar, with 5 mm trocars in the left and right lower quadrant and suprapubic region. A uterine manipulator was used for better pelvic exposure. A rudimentary horn, 4 cm in diameter, was attached to the left unicornuate uterus by a fibrous band. The right round ligament was sectioned and the anterior and posterior leaf of the broad ligament were dissected. After the ureter was identified, the right salpingectomy was performed and the utero-ovarian ligament was

transected. Finally, the fibromuscular band that connected the two uterine parts was carefully sectioned using bipolar laparoscopic forceps and scissors (Fig. 5). The uterine horn and right tube were removed with an endobag.

The patient was discharged on the second postoperative day and had a favourable postoperative course. One year after surgery the patient was asymptomatic and under combined oral hormonal contraception.

3. Discussion

The wide reported range of the incidence of rudimentary horn pregnancies (1 per 76 000 to 1 per 150 000 pregnancies) [1,3–6,9,11–13,18] reflects the rarity of the condition. A decrease in the mortality rate from 23% to 0.5% [2,11] in recent years may indicate that advances in imaging technology have allowed more accurate diagnosis of uterine malformations prior to pregnancy or before serious pregnancy-related complications arise [1,4].

Early diagnosis can be life-saving. However, only 14% of cases are diagnosed prior to clinical manifestations, usually in the second trimester [4,12,14], because rudimentary horns are frequently not diagnosed prior to pregnancy [13]. According to Goel et al., only 5% of all reported cases of these pregnancies were diagnosed pre-operatively [12]. The possible factors responsible for the diagnostic failure are the absence of symptoms in 40% of cases [2,12,14], previous normal pregnancy and vaginal delivery [14] or misdiagnosis [1]. In our case, a rudimentary horn pregnancy was suspected only after laparoscopic surgery was performed to confirm and treat the initial supposed ectopic tubal pregnancy. The low diagnostic suspicion may be attributed to the absence of clinical symptoms in pregnancy and, before it, the misdiagnosis of a subserous myoma and a previous normal pregnancy.

Transvaginal ultrasound is the gold standard for imaging both uterine and adnexal pathology. Nevertheless, it has a low sensitivity (26%–33%) for the diagnosis of a rudimentary horn even before pregnancy [1,2,4,6,12–14]. Two-dimensional pelvic ultrasound detects less than 75% of cases and its sensitivity decreases with gestational age due to the changing uterine anatomy [1,6,12,14,18]. Tsafir et al. and Mavrelou et al. suggested specific criteria to improve early ultrasound diagnosis [2–6,9,11]. Three-dimensional ultrasound and a pelvic MRI scan have become gold-standard imaging modalities for the characterization of mullerian anomalies with comparable results, and should be considered in suspicious cases [1–3,7,11,12,14]. An MRI study also excludes associated co-existing urinary system anomalies in 36% of cases [11,14,15] and may guide surgical planning [4,7,14]. In our case, both imaging techniques were performed and the same conclusions were obtained.

Upon diagnosis of pregnancy in a rudimentary horn, the standard treatment consists of immediate excision of the pregnant rudimentary horn and ipsilateral fallopian tube due to the high risk of rupture [1,4,6,11,13,14,17,18]. However, most reported cases

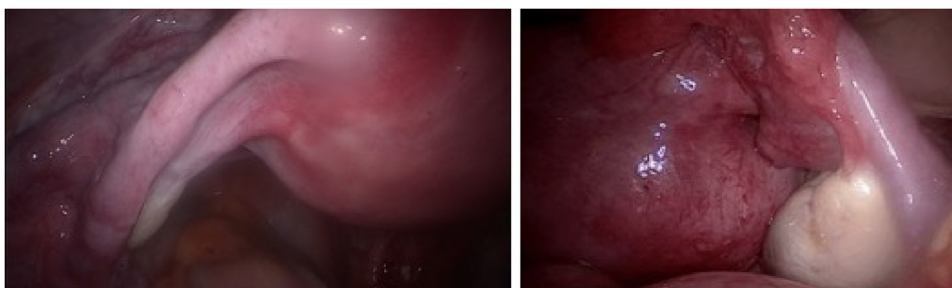


Fig. 2. Laparoscopic view of the normal left fallopian tube and ovary (left image) and the normal right fallopian tube and ovary (right image).

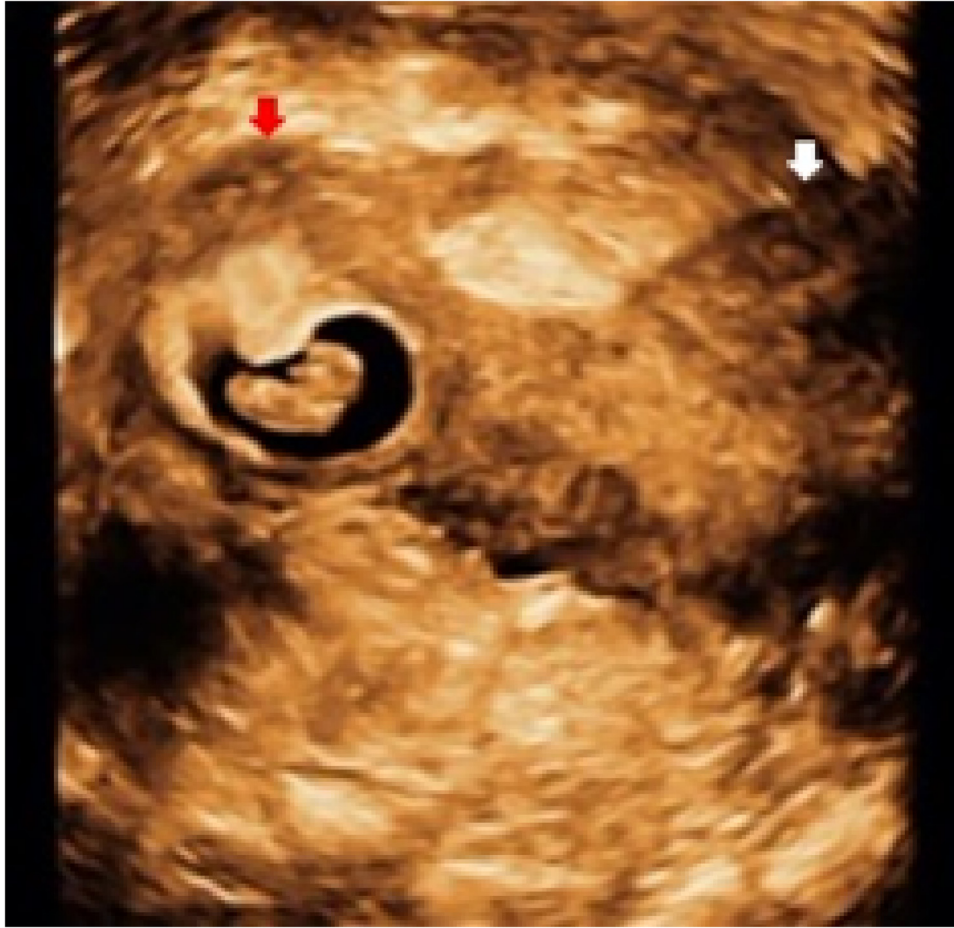

Fig. 3. Three-dimensional ultrasound shows a partial left-sided hemi-uterus (white arrow) and an ectopic pregnancy in a rudimentary horn (red arrow). (For interpretation of the references to colour in this figure legend, the reader is referred to the web version of this article).

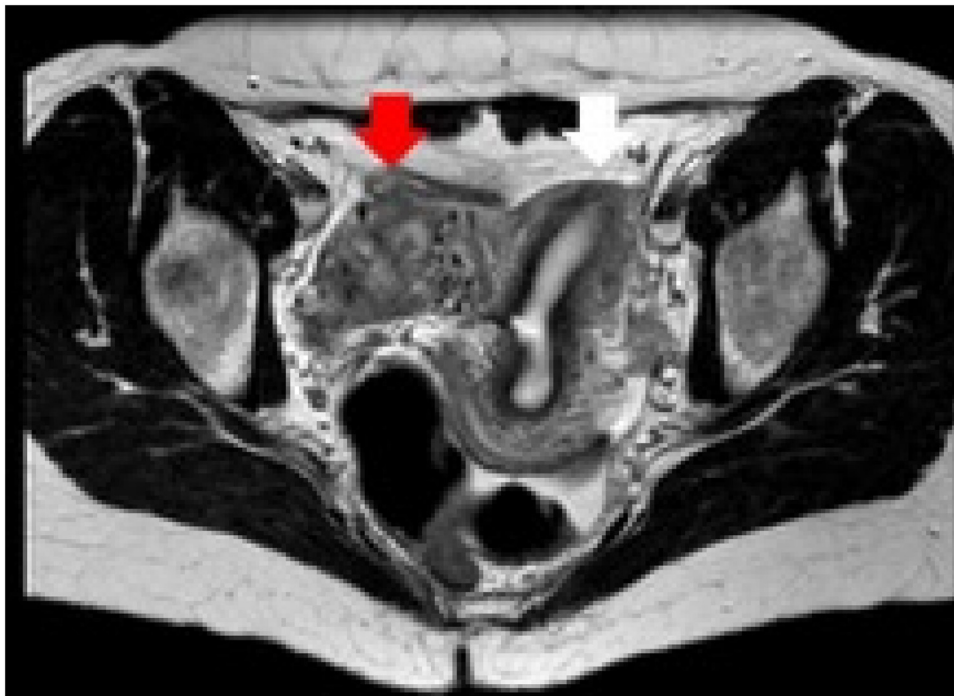


Fig. 4. Magnetic resonance image of the pelvis: axial view of the left hemi-uterus (white arrow) and the right rudimentary horn (red arrow) with involutive trophoblastic residues. (For interpretation of the references to colour in this figure legend, the reader is referred to the web version of this article).

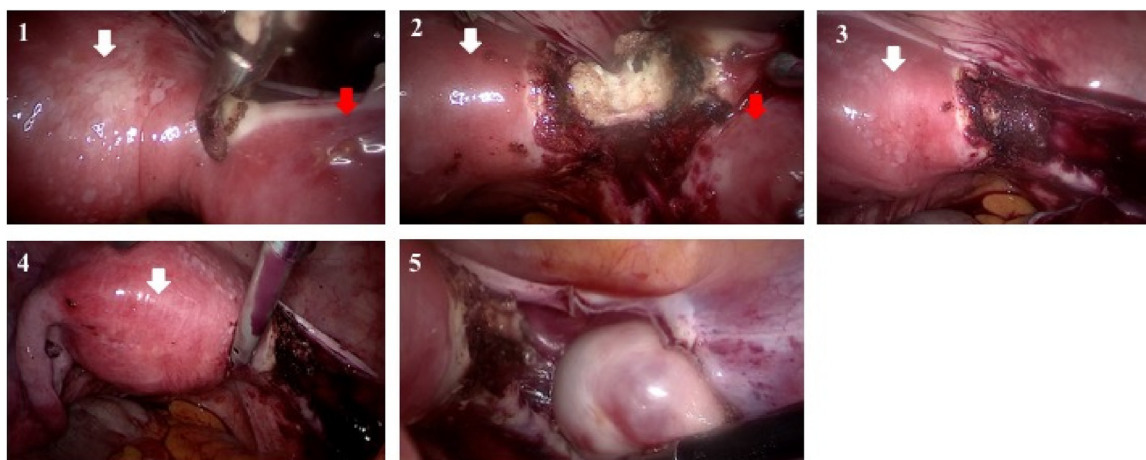


Fig. 5. Laparoscopic view of fibromuscular band section that connected the left hemi-uterus (white arrow) and the right rudimentary horn (red arrow) – images 1-3. Image 4 shows the left hemi-uterus sectioned with normal left fallopian tube and ovary, and image 5 shows the normal right ovary. (For interpretation of the references to colour in this figure legend, the reader is referred to the web version of this article).

concern patients who either are symptomatic or suffer a uterine rupture with hemoperitoneum [6,11,18]. There are few published cases of first-trimester pre-rupture in this condition [13,16–18] but they do demonstrate that it is possible to undertake other conservative measures that minimize the surgical risks. Edelman et al. reported the first case treated successfully with a single dose of intramuscular methotrexate [17]. Sevtap et al. [16] and Herchelroath et al. [18] each published a case of rudimentary horn pregnancy treated with local methotrexate administration. Additionally, Herchelroath et al. injected 1 mL lidocaine directly into the foetal pole, resulting in foetal bradycardia. All cases diagnosed in the first trimester involve asymptomatic and haemodynamically stable patients. They show that medical termination of pregnancy before surgery can decrease blood flow, making surgical management easier and preventing additional blood loss [11,15,16–18].

Currently, there are no standard recommendations for the management of these cases and published reports use different approaches. Nevertheless, a number of published case series of interstitial or cervical ectopic pregnancies report termination with local methotrexate combined with potassium chloride [20,21]. The doses reported for methotrexate are inconsistent, ranging from a 50 mg single dose to 1 mg/kg. A multidose or single series of intramuscular MTX has also been used. The combined approach with potassium chloride has the purpose of increasing the effectiveness of the local methotrexate [20,21].

In our case, an immediate surgical intervention was not needed as the patient was asymptomatic and haemodynamically stable. Medical termination with intrasacral and systemic methotrexate was effective in interrupting pregnancy and preventing uterine rupture. We monitored the patient with serial B-hCG measurements and periodic ultrasound scans, and we delayed surgical resection until B-hCG levels declined significantly.

Medical treatment is an effective and safe option in these cases but it does not prevent a recurrence of a pregnancy in the rudimentary horn [5]. A definitive rudimentary horn excision and homolateral salpingectomy should be undertaken a few weeks after the end of medical treatment, when there is a lower risk of haemorrhage and the tissues are less fragile [5,14]. At least three reasons support surgical intervention: avoiding recurrence of pregnancy, removing the cause of dysmenorrhoea and preventing possible endometriosis [8,13,14]. The surgical technique of choice should be adjusted to the type of malformation. In the case of a hemi-uterus with a rudimentary uterine horn, the most frequently described technique is the one used in this case [7,8].

In conclusion, our case shows that early diagnosis of a rudimentary horn pregnancy is the key to successful management. Medical treatment may be an adjuvant therapy to surgical removal in asymptomatic women with non-communicating rudimentary uterine horn pregnancies in early gestation. However, the ideal dosage of MTX is yet to be defined, as is the success rate of the possible MTX administration routes. Due to the rarity of this condition, its description and publication are of fundamental importance.

Contributors

All authors made a substantive contribution to the information or material submitted for publication.

Conflict of Interest

The authors declare that they have no conflict of interest regarding the publication of this case report.

Funding

No funding from an external source supported the publication of this case report.

Patient consent

Obtained.

Provenance and peer review

This case report was peer reviewed.

References

- [1] Paula C. Brady, Rose L. Molina, Michael G. Muto, Brenna Stapp, Serene S. Srouji. Diagnosis and management of a heterotopic pregnancy and ruptured rudimentary uterine horn. *Fertil. Res. Pract.* 4 (2018) 6. <http://dx.doi.org/10.1186/s40738-018-0051-7>.
- [2] Claudia Blancafort, Betlem Graupera, Maria Angela Pascual, Lourdes Hereter, Jean Laurent Browne, Maria Teresa Cusido, Diagnosis and laparoscopic management of a rudimentary horn pregnancy: role of three-dimensional ultrasound. *J. Clin. Ultrasound* 45 (2) (2017) 112–115. <http://dx.doi.org/10.1002/jcu.22393>.
- [3] Yu-Ju Lai, Chen-Hsien Lin, Wen-Chien Hou, Kwei-Shuai Hwang, Mu-Hsien Yu, Su. Her-Young, Pregnancy in a noncommunicating rudimentary horn of a unicornuate uterus: prerule diagnosis and management, Taiwan. *J. Obstet. Gynecol.* 55 (2016) 604–606. <http://dx.doi.org/10.1016/j.tjog.2016.06.009>.

- [4] María Luisa Sanchez-Ferrer, María Teresa Prieto-Sanchez, Francisco Sanchez del Campo, Variations in clinical presentation of unicornuate uterus with non-communicating rudimentary horn (class IIB of the American Fertility Society classification), *Taiwan. J. Obstet. Gynecol.* 57 (2018) 110–114, <http://dx.doi.org/10.1016/j.tjog.2017.12.018>.
- [5] Gaby N. Moawad, Elias D. Abi Khalil, A case of recurrent rudimentary horn ectopic pregnancies managed by methotrexate therapy and laparoscopic excision of the rudimentary horn, *Case Rep. Obstet. Gynecol.* (2016), <http://dx.doi.org/10.1155/2016/5747524>.
- [6] Mania Kaveh, Abolfazl Mehdizadeh Kashi, Kambiz Sadegi, Forough Forghani, Pregnancy in non-communicating rudimentary horn of a unicornuate uterus, *Int. J. Fertil. Steril.* 11 (4) (2018) 318–320, <http://dx.doi.org/10.22074/ijfs.2018.5022>.
- [7] Ignacio Zapardiel, Pilar Alvarez, Tirso Perez-Medina, Jose M. Bajo-Arenas, Laparoscopic management of a cavitated noncommunicating rudimentary uterine horn of a unicornuate uterus: a case report, *J. Med. Case Rep.* 4 (2010) 215, <http://dx.doi.org/10.1186/1752-1947-4-215>.
- [8] Luigi Fedel, Stefano Bianchi, Giovanni Zanconato, Nicola Berlanda, Valentino Bergamini, Laparoscopic removal of the cavitated noncommunicating rudimentary uterine horn: surgical aspects in 10 cases, *Fertil. Steril.* 83 (2) (2005) 432–436, <http://dx.doi.org/10.1016/j.fertnstert.2004.07.966>.
- [9] Genevieve Lennox, Sophia Pantazi, Johannes Keunen, Tim Van Mieghem, Lisa Allen, Minimally invasive surgical management of a second trimester pregnancy in a rudimentary uterine horn, *J. Obstet. Gynaecol. Can.* 35 (5) (2013) 468–472, [http://dx.doi.org/10.1016/S1701-2163\(15\)30938-5](http://dx.doi.org/10.1016/S1701-2163(15)30938-5).
- [11] S.1 Siwath, R. Mehra, D.K. Pandher, A. Huria, Rudimentary horn pregnancy: a 10-year experience and review of literature, *Arch. Gynecol. Obstet.* 287 (4) (2013) 687–695, <http://dx.doi.org/10.1007/s00404-012-2625-7>.
- [12] C.S. Souza, G.G. Dorneles, G.N. Mendonça, C.M.D. Santos, F.M.P. Gallarreta, C.K. Konopka, Pregnancy in non-communicating unicornuate uterus: diagnosis difficulty and outcomes - a case report, *Rev. Bras. Ginecol. Obstet.* 39 (11) (2017) 640–644, <http://dx.doi.org/10.1055/s-0037-1607046>.
- [13] Xiaoyan Li, Ping Peng, Xinyan Liu, Weilin Chen, Juntao Liu, Jianqiu Yang, Xuming Bian, He pregnancy outcomes of patients with rudimentary uterine horn: a 30-year experience, *PLoS One* 14 (1) (2019), e0210788, <http://dx.doi.org/10.1371/journal.pone.0210788>.
- [14] A. Yassin, S. Munaza, A. Mohammed, Tale of rudimentary horn pregnancy: case reports and literature review, *J. Matern. Fetal. Neonatal. Med.* 32 (4) (2019) 671–676, <http://dx.doi.org/10.1080/14767058.2017.1387533>.
- [15] J.K. Park, C.E. Dominguez, Combined medical and surgical management of rudimentary uterine horn pregnancy, *J. Matern. Neonatal Med.* 11 (1) (2007) 119–122, <http://dx.doi.org/10.1080/14767058.2017.1387533>.
- [16] H.K. Sevtap, A.M. Aral, B. Sertac, An early diagnosis and successful local medical treatment of a rudimentary uterine horn pregnancy: a case report, *Arch. Gynecol. Obstet.* 275 (2007) 297–298, <http://dx.doi.org/10.1007/s00404-006-0232-1>.
- [17] A.B. Edelman, J.T. Jensen, D.M. Lee, M.D. Nichols, Successful medical abortion of a pregnancy within a noncommunicating rudimentary uterine horn, *Am. J. Obstet. Gynecol.* 189 (3) (2003) 886–887, [http://dx.doi.org/10.1067/s0002-9378\(03\)00121-2](http://dx.doi.org/10.1067/s0002-9378(03)00121-2).
- [18] D. Herchelroath, J.L. Miller, K.C. Wang, Novel management of ectopic pregnancy in a noncommunicating rudimentary horn of a unicornuate uterus, *J. Am. Osteopath. Assoc.* 118 (9) (2018) 623–626, <http://dx.doi.org/10.7556/jaoa.2018.137>.
- [19] G.F. Grimbizis, S. Gordts, A. Di Spiezio Sardo, S. Brucker, C. De Angelis, M. Ger-golet, T.C. Li, V. Tanos, H. Brölmann, L. Gianaroli, R. Campo, The ESHRE/ESGE consensus on the classification of female genital tract congenital anomalies, *Hum. Reprod.* 28 (August 8) (2013) 2032–2044, <http://dx.doi.org/10.1093/humrep/det098>.
- [20] M.L.1 Swank, T.R. Harken, M. Porto, Management of interstitial ectopic pregnancies with a combined intra-amniotic and systemic approach, *Obstet. Gynecol.* 122 (2 Pt 2) (2013) 461–464, <http://dx.doi.org/10.1097/AOG.0b013e31828d58ee>.
- [21] M.J. Kim, J.H. Cha, H.S. Bae, M.K. Kim, M.L. Kim, B.S. Yun, Y.S. Kim, S.J. Seong, Y.W. Jung, Therapeutic outcomes of methotrexate injection in unruptured interstitial pregnancy, *Obstet. Gynecol. Sci.* 60 (November 6) (2017) 571–578, <http://dx.doi.org/10.5468/ogs.2017.60.6.571>.