



Improvement in exercise capacity after a modified Potts shunt in an adult patient with pulmonary arterial hypertension

Copyright ©The authors 2021

This version is distributed under the terms of the Creative Commons Attribution Non-Commercial Licence 4.0. For commercial reproduction rights and permissions contact permissions@ersnet.org

Received: 26 April 2021
Accepted: 13 July 2021

To the Editor:

The Potts shunt has been proposed as a strategy to alleviate symptoms and to delay lung transplantation in paediatric patients with pulmonary arterial hypertension (PAH) [1]. In a similar way to patients with Eisenmenger physiology with a patent ductus arteriosus, the Potts shunt may confer protection to the pressure-overloaded right ventricle in patients with suprasystemic pulmonary pressures. The results, in selected paediatric patients, have been encouraging in terms of survival, World Health Organization (WHO) functional classification and need for transplantation [1–4]. Recently, modifications to the classic Potts shunt have been reported by creating a unidirectional central valved conduit to protect the pulmonary circulation from reverse shunting [5, 6]. We report a second adult patient who underwent placement of a central unidirectional (valved) Potts shunt for severe suprasystemic PAH. After 1 year of follow up, the patient demonstrated overall clinical improvement with a significant increase in exercise tolerance.

A 22-year-old female was diagnosed with idiopathic PAH with suprasystemic pulmonary pressures 18 months prior to surgery. Her treatment consisted of macitentan, sildenafil and intravenous epoprostenol (2250 µg per 24 h). Despite medical therapy for 6 months, she remained in WHO functional class III with an arterial oxygen saturation (S_{aO_2}) of 93%, an N-terminal pro-brain natriuretic peptide (NT-proBNP) concentration of 434 pg·mL⁻¹ and a 6-min walking distance (6MWD) of 459 m (59% of expected). Baseline exercise testing showed a maximal load of 70 W (44%), maximal oxygen uptake ($V'_{O_{2,max}}$) 15.8 mL·min⁻¹·kg⁻¹ (38%), oxygen pulse 4.7 mL per beat (40.4%) and a drop in S_{aO_2} to 76% at maximal exertion. At right heart catheterisation (RHC), a suprasystemic pulmonary artery pressure (PAP) of 130/69 mmHg with a mean PAP of 95 mmHg was measured. Systemic artery pressure (SAP) was 110/78 mmHg with a mean of 87 mmHg. Other parameters of the RHC were mean right atrial pressure (RAP) 9 mmHg, cardiac index (CI) 3.1 L·min⁻¹·m⁻² and pulmonary vascular resistance (PVR) of 1367 dyn·s·cm⁻⁵. Given her lack of improvement, the patient underwent screening for lung transplantation. 2 months before surgery, her PAP had increased to 138/72 mmHg with a mean PAP of 99 mmHg, a SAP of 113/69 mmHg (mean 83 mmHg), mean RAP 10 mmHg, CI 2.3 L·min⁻¹·m⁻² and PVR 1921 dyn·s·cm⁻⁵. NT-proBNP was 422 pg·mL⁻¹. A month later, she was admitted with haemoptysis and desaturations due to a viral respiratory tract infection. Various treatment options were discussed after recovery. Because of a paucity of donor lungs for the patients' size (50 kg) and her reluctance to undergo transplantation, other options were considered. The anatomy was found to be suitable for a modified Potts shunt. A central valved conduit was preferred because it protects the pulmonary circulation from pressure overload and reverse shunting, is easier to manage surgically in the event of a lung transplantation, and avoids potential bleeding from intercostal aortopulmonary collaterals, and because of prior surgical experience (P. Eghtesady).

The operative technique consisted of a midsternal approach and the support of extracorporeal circulation. Care was taken not to open the pleural cavity. A unidirectional valved conduit was constructed with a 16-mm bovine jugular vein graft (Contegra; Medtronic, Minneapolis, MN, USA) reinforced with a polytetrafluoroethylene vascular graft (Gore, Flagstaff, AZ, USA). Upon institution of cardiopulmonary bypass, the aorta distal to the left subclavian artery was clamped and the distal end of the conduit was anastomosed to the aorta. Subsequently, the proximal end of the conduit was attached to the main pulmonary artery (figure 1a). Her immediate postoperative course was complicated by desaturations, pulmonary oedema and a respiratory tract infection that required antibiotics, diuretics and venovenous extracorporeal membrane oxygenation (ECMO) support for 4 days. A postoperative chest computed



Shareable abstract (@ERSpublications)

For young adults with end-stage idiopathic pulmonary hypertension, a valved graft connecting the central pulmonary artery to the distal aortic arch can provide substantial palliation of symptoms and may defer lung transplantation <https://bit.ly/2TvMFFC>

Cite this article as: Symersky P, Jansen SMA, Kamminga SK, *et al.* Improvement in exercise capacity after a modified Potts shunt in an adult patient with pulmonary arterial hypertension. *ERJ Open Res* 2021; 7: 00287-2021 [DOI: 10.1183/23120541.00287-2021].

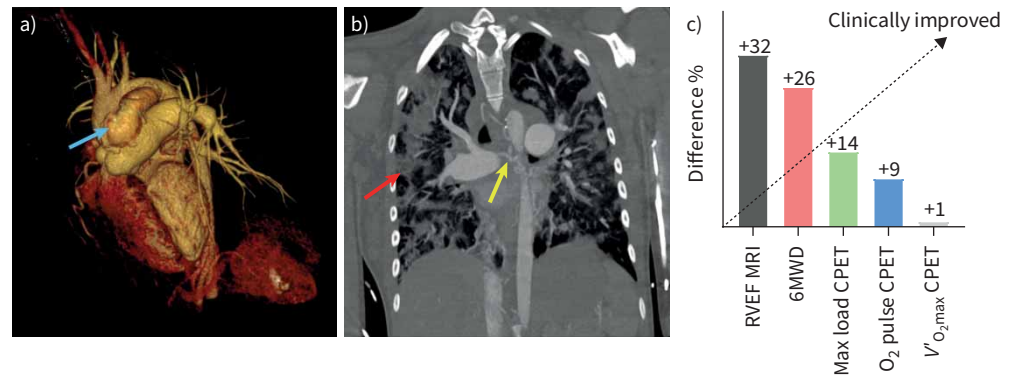




FIGURE 1 a) Three-dimensional image of the Potts shunt (blue arrow) using Volume Rendering Technique. The proximal end of the conduit was attached to the main pulmonary artery and the distal end was anastomosed to the aorta. b) Pulmonary oedema (red arrow) after Potts shunt procedure originated from large collateral bronchial vessels (yellow arrow). Coronal chest computed tomography image with a maximal intensity projection of 3 mm. c) Per cent difference in right ventricle ejection fraction (RVEF), 6-min walking distance (6MWD), maximal (max) load during cardiopulmonary exercise testing (CPET), oxygen pulse during CPET and maximal oxygen uptake ($V'_{O_{2,max}}$) during CPET. Per cent difference measured between 1 month prior to surgery and 1 year after surgery. MRI: magnetic resonance imaging.

tomography showed large aortopulmonary collateral vessels as a possible source for the pulmonary oedema (figure 1b). She was weaned from the ventilator on the 15th day postoperatively. Intravenous epoprostenol was tapered from the eighth postoperative day and substituted for the oral prostacyclin receptor agonist selexipag (1200 mg twice daily) 1 month postoperatively.

1 year after surgery, her exercise tolerance was measured (figure 1c). Maximal load was improved to 80 W (53%), $V'_{O_{2,max}}$ was 16 mL·min⁻¹·kg⁻¹ (41%) and oxygen pulse 5.1 mL (45.2%). Her 6MWD had increased to 580 m (75%). She was WHO functional class II, could climb a flight of stairs and swim, and had resumed work. NT-proBNP was decreased to 206 pg·mL⁻¹. Cardiac magnetic resonance imaging (MRI) 1 month prior to surgery and 1 year after surgery showed significant improvement: the right ventricular end-diastolic volume (EDV) was unchanged (138 compared to 137 mL), end-systolic volume (ESV) decreased from 86 to 68 mL and ejection fraction improved from 38% to 50%. The left ventricle EDV rose from 92 to a mildly dilated 121 mL, while the ESV rose from 31 to 51 mL. The left ventricular ejection fraction decreased mildly from 66% to 58%.

The improvement of exercise tolerance attests to the fact that a modified unidirectional Potts shunt may provide palliation of symptoms in adult patients with PAH. Walking distance (6MWD) improved most, with a more modest increase in maximal load and $V'_{O_{2,max}}$. Quality of life improved impressively and the patient remains in functional class II despite tapered medication. Several observations may be significant. First, the follow-up with MRI demonstrated a dilatation of the left ventricle and concomitant drop in left ventricular ejection fraction 1 year post-shunt. This is a novel observation and may have to be confirmed by other studies. Whether this remodelling improves or not requires further follow up. Possibly, older patients may adapt more slowly to the abrupt change in physiology caused by the modified Potts shunt. Similarly, the use of postoperative venovenous ECMO support in paediatric patients was rare compared to 80% in a recent series of older patients [5]. Another observation particular to this patient was the presence of aortopulmonary collateral vessels. These collaterals can occur in 15–30% of patients with idiopathic pulmonary hypertension and are the primary reason for haemoptysis requiring embolisation [7]. Presently, it is not known how the presence of the Potts shunt physiology interacts with existing collaterals. Historically, however, the development of such collaterals secondary to relative hypoxia was well described in the era of applying Potts shunt for the palliation of so-called blue babies, such as the Tetralogy of Fallot [8]. Given the inevitable diversion of pulmonary blood flow, the presence of large systemic collaterals may be a risk factor for postoperative pulmonary oedema as seen in this patient. In addition, collaterals may pose a considerable surgical challenge with an approach through a left thoracotomy. Opening the pleural space with collapse of the lung may cause tears of the collaterals emerging from the intercostal vessels with possibly intractable bleeding. A midsternal approach leaves the pleural space intact and avoids bleeding from these friable collaterals.

In summary the promising results of the modified Potts shunt need to be confirmed in more adult patients, but the first experience may help to pave the way for a broader use of these shunts in this specific population of patients.

Petr Symersky ^{1,2}, Samara M.A. Jansen³, Suzanne K. Kamminga⁴, Lilian J. Meijboom⁵, Erik J. Lust⁶, Pirooz Eghtesady ⁷, Robert M. Grady¹ and Harm J. Bogaard³

¹Dept of Cardiothoracic Surgery, Amsterdam UMC, Vrije Universiteit, Amsterdam, the Netherlands. ²Dept of Cardiothoracic Surgery, OLVG Hospital, Amsterdam, the Netherlands. ³Dept of Pulmonology, Amsterdam UMC, Vrije Universiteit, Amsterdam, the Netherlands. ⁴Dept of Anesthesiology, Amsterdam UMC, Vrije Universiteit, Amsterdam, the Netherlands. ⁵Dept of Radiology and Nuclear Medicine, Amsterdam UMC, Vrije Universiteit, Amsterdam, the Netherlands. ⁶Dept of Intensive Care, Amsterdam UMC, Vrije Universiteit, Amsterdam, the Netherlands. ⁷Depts of Surgery and Pediatrics, Washington University School of Medicine, St Louis, MO, USA.

Corresponding author: Petr Symersky (p.symersky@olvg.nl)

Provenance: Submitted article, peer reviewed.

Conflict of interest: None declared.

References

- 1 Blanc J, Vouhé P, Bonnet D. Potts shunt in patients with pulmonary hypertension. *N Engl J Med* 2004; 350: 623.
- 2 Baruteau AE, Belli E, Boudjemline Y, et al. Palliative Potts shunt for the treatment of children with drug-refractory pulmonary arterial hypertension: updated data from the first 24 patients. *Eur J Cardiothorac Surg* 2015; 47: e105–e110.
- 3 Aggarwal M, Grady RM, Choudhry S, et al. Potts shunt improves right ventricular function and coupling with pulmonary circulation in children with suprasystemic pulmonary arterial hypertension. *Circ Cardiovasc Imaging* 2018; 11: 007964.
- 4 Keogh AM, Nicholls M, Shaw M, et al. Modified Potts shunt in an adult with pulmonary arterial hypertension and recurrent syncope – three-year follow-up. *Int J Cardiol* 2015; 182: 36–37.
- 5 Rosenzweig EB, Ankola A, Krishnan U, et al. A novel unidirectional-valved shunt approach for end-stage pulmonary arterial hypertension: early experience in adolescents and adults. *J Thorac Cardiovasc Surg* 2021; 161: 1438–1446.
- 6 Salna M, van Boxtel B, Rosenzweig EB, et al. Modified Potts shunt in an adult with idiopathic pulmonary arterial hypertension. *Ann Am Thorac Soc* 2017; 14: 607–609.
- 7 Remy-Jardin M, Duhamel A, Deken V, et al. Systemic collateral supply in patients with chronic thromboembolic and primary pulmonary hypertension: assessment with multi-detector row helical CT angiography. *Radiology* 2005; 235: 274–281.
- 8 Ma M, Mainwaring RD, Hanley FL. Comprehensive management of major aortopulmonary collaterals in the repair of tetralogy of Fallot. *Semin Thorac Cardiovasc Surg Pediatr Card Surg Annu* 2018; 21: 75–82.