SAGE Open Medical Case Reports

SAGE Open Medical Case Reports
JCMS Case Reports
Volume 8: 1–5

DOI: 10.1177/2050313X20935736
journals.sagepub.com/home/sco

Multifocal cocaine-induced pyoderma gangrenosum: A report of two cases and review of literature

Alexandre Lemieux[1], Zhuo Ran Cai[1], Annie Belisle[2], Suzanne Chartier[1] and Chantal Bolduc[1]

Abstract

Pyoderma gangrenosum is often associated with a systemic disease. Cocaine-induced pyoderma gangrenosum, most probably caused by levamisole, has been described recently and typically presents as multiple, large cribriform ulcers. Peri-nuclear antineutrophil cytoplasmic antibody is the most common serological finding. A strong counseling for cocaine cessation, combined with wound care and immunosuppressive therapy, is the mainstay of treatment. We present two cases of cocaine-induced pyoderma gangrenosum and correlate their findings with the typical clinical, histological and serological presentation.

Keywords

Pyoderma gangrenosum, levamisole, cocaine

Introduction

Pyoderma gangrenosum (PG) is a neutrophilic dermatosis. Four main clinical variants are described: ulcerative, bullous, pustular or superficial granulomatous.[1] PG typically presents as a progressive painful ulcer with undermined borders. Half of the cases are associated with a systemic disease such as inflammatory bowel disease, arthritis or hematologic malignancies. Drug-induced PG can occur, with cocaine being the most common culprit.[2] Up to 80% of cocaine is adulterated with levamisole.[3] Levamisole is thought to be the agent responsible for cocaine-induced PG (CIPG). We describe two cases of CIPG that presented multiple and diffused ulcerative lesions and correlate their findings with other CIPG cases described in the literature.

Case presentations

Case #1

A 64-year-old man initially presented with a 1-month history of multiple painful ulcers with violaceous raised and undermined borders measuring up to 10 cm in diameter. Lesions were located on the trunk, lower leg, and intranasal cavity (Figure 1), with several crusted and necrotic plaques. PG was suspected. The investigation included skin biopsies for histology and cultures, laboratories, colonoscopy and imaging to rule out any malignancies. His medical history included atrial fibrillation, cardiac and peripheral atherosclerotic disease, chronic renal failure and diabetes.

The skin biopsy showed large abscesses in the dermis, surrounded by a mixed inflammatory infiltrate (lymphocytes, macrophages, plasma cells) (Figure 2). Tissue cultures were negative. The rest of the investigation was unremarkable including negative anti-neutrophil cytoplasmic antibodies (ANCA), anti-citrullinated protein antibody and serum protein electrophoresis. Cocaine and levamisole were not ordered. Despite courses of topical, intralesional and oral corticosteroids treatments, the lesions worsened and reached a total of 18, mostly located on the trunk and the lower extremities (Figure 3). The patient was hospitalized to optimize treatment and wound care.

[1]Department of Medicine, Division of Dermatology, Centre Hospitalier de l'Université de Montréal (CHUM), Montréal, QC, Canada
[2]Department of Pathology, Centre Hospitalier de l'Université de Montréal (CHUM), Montréal, QC, Canada

Corresponding Author:
Alexandre Lemieux, Department of Medicine, Division of Dermatology, Centre Hospitalier de l'Université de Montréal (CHUM), 1051 Rue Sanguinet, Montréal, QC H2X 3E4, Canada.
Email: alexandre.lemieux.2@umontreal.ca

Figure 1. Erosions with serous and haemorrhagic crusts with oedematous tissue in the right intranasal cavity.

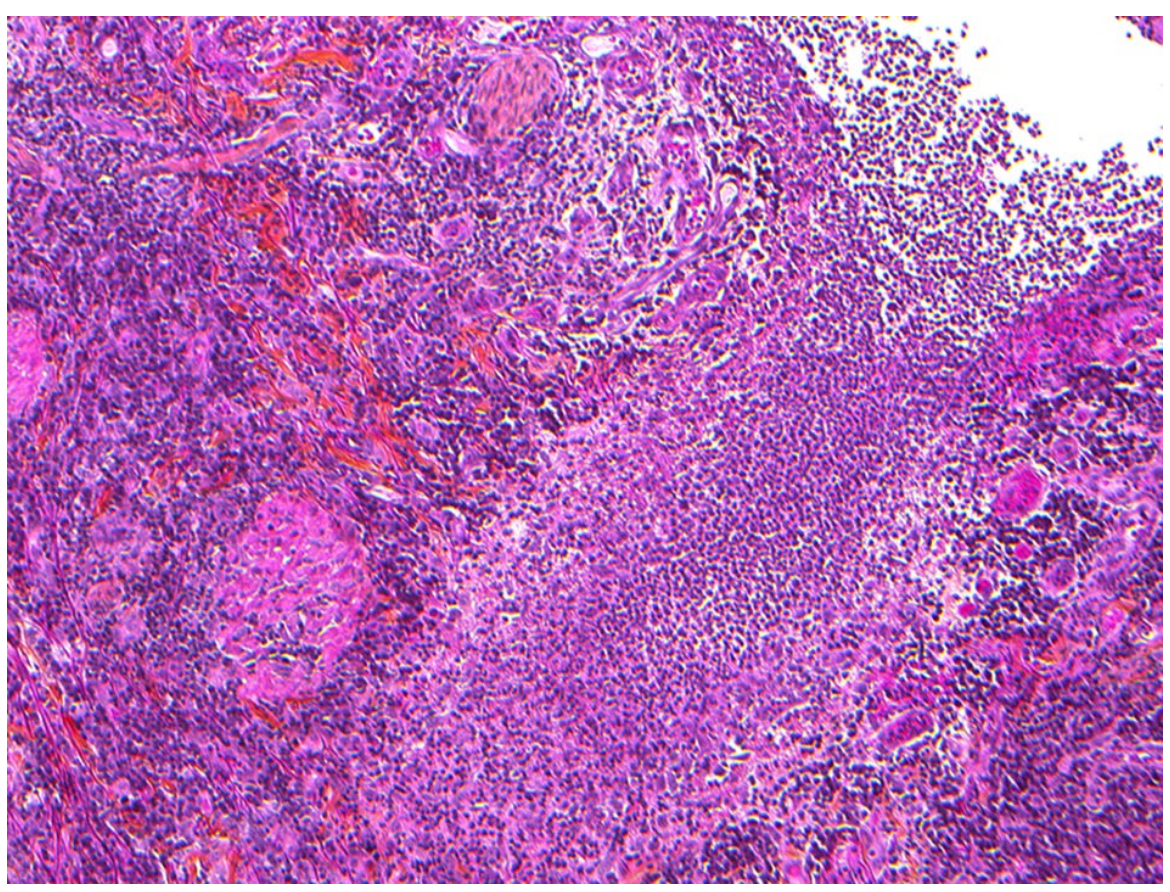

Figure 2. HPS staining of the skin biopsy at 10X showing a large abscess in the dermis surrounded by a mixed inflammatory infiltrate (lymphocytes, histiocyte and plasma cells).

During follow-ups, he admitted consuming intranasal cocaine on a weekly basis for the last 25 years. A counseling on the cessation of cocaine use was made. A significant improvement occurred. Infliximab was eventually introduced, and he had a gradual re-epithelialization with atrophic cribriform scars (Figure 4).

Case #2

A 46-year-old man was referred for a 1-year history of generalized PG resistant to treatments. The diagnosis had previously been confirmed with a biopsy in another center. He presented with up to 22 cribriform ulcers and atrophic scars mostly located on the trunk, with two lesions in the preauricular region (Figure 5). He had been previously treated with prednisone 50 mg daily combined with cyclosporine, but still presented relapses. A complete investigation was once again unremarkable, including ANCAs and the search for an associated disease.

Figure 3. Multiple deep, large and cribriform ulcers with erythemato-violaceous undermined borders sparse on the trunk with two crusted necrotic plaques on the left lower abdomen.

The patient was hospitalized and was still developing ulcers despite immunosuppressive treatments. Flares correlated with his temporary discharges from the hospital. He finally admitted using cocaine at these moments. Efficient therapy constituted strong counseling regarding his cocaine use, combined with prednisone 50 mg daily and mycophenolate mofetil 1000 mg twice a day. He was showing good improvement at his last follow-up.

Discussion

Historically, levamisole was used as a treatment for colon and breast cancer with 5-fluorouracil, and as an immunomodulator for rheumatoid arthritis.[3,4] It was thought to enhance T cells function and neutrophil chemotaxis.[5] It was withdrawn from Canadian market in 2003 because of its adverse effects, but is still being used in the United States as a veterinary antihelmintic.[3,6,7]

Up to 80% of the cocaine is adulterated with levamisole; since they both have a similar appearance, it can be used as a bulking agent, increasing the total weight of the drug.[3] It is thought to enhance its psychotropic effect, prolong the

Figure 4. Reepithelialisation with atrophic cribriform scars following the introduction of infliximab.

euphoria and act as an indirect serotonin agonist.[8,9] Levamisole was also found in heroin.[3] Beyond the skin manifestations, levamisole toxicity can manifest with several systemic adverse events including: fatigue, arthralgia, isolated neutropenia or leukopenia, agranulocytosis, seizure, pulmonary hemorrhage, hyponatremia and renal failure.[3,10] Several cases of agranulocytosis have been described and led to severe infections requiring hospitalizations.[4,7]

Several dermatologic manifestations have been associated with cocaine consumption and levamisole toxicity including CIPG, levamisole-associated cutaneous vasculitis/retiform purpura and cocaine-induced midline destructive lesions. The two cases we described were concordant with CIPG, considering the clear temporal association of improvement and worsening with the repeated use of cocaine and the severity of the cases. In both cases, other conditions were excluded as a potential cause. Their findings can be correlated with the other cases in the literature, which can help differentiate from classic ulcerative PG (Table 1).

Clinical presentation

The lesions of CIPG most commonly resemble the classic ulcerative variant of PG, although vesiculopustular, bullous or vegetative lesions have been described.[5] The clinical presentation is often more widespread than the classic forms; lesions are multiple, bigger in diameter and mostly located on the trunk.[11] A cohort of eight patients, however, showed the lower extremities being the most frequent site of involvement, followed by the upper extremities and the trunk.[5] Both our cases highlight these differences with an average of 20 lesions with a diameter up to 15 cm. Specific pre-auricular lesions are also described, just like our second case.[11,12] Head and neck lesions may also be a clue to the diagnosis as they represent less than 5% of the usual PG,[13] but have been reported in up to 75% of the CIPG.[5] The median interval between the cocaine consumption and the onset of symptoms is generally 1 week, ranging from 1–4 weeks.[5] The symptoms typically relapse and are refractory to treatments with the use of cocaine, and a urine drug test is useful to correlate this finding. Few cases specifically correlate the worsening of the symptoms with the patients' discharge from the hospital.[14]

Figure 5. Multiple well-circumscribed atrophic and hyperpigmented scars with telangiectasias on the back with several punched out ulcers within these scars. These ulcers represent signs of relapses of the lesions at the time of consultation.

Histopathologic findings

The CIPG shows similar features as classic PG on histopathology. Occasionally, an overlap between PG and vasculitis or vasculopathy can be seen with the concomitant presence of fibrinoid necrosis, leukocytoclastic vasculitis or thrombotic vasculopathy with usual signs of PG.[5] This is a potential clue for the implication of levamisole since it is well known that

Table 1. Main differences for clinical presentation, histopathologic findings and serologic profile between classical PG and cocaine or levamisole induced PG.

	Classical PG	Cocaine or levamisole induced PG
Most frequent clinical type	Ulcerative	Ulcerative
Most frequent sites of involvement	Lower extremities	Trunk; Face and Ears; Lower extremities
Lesions characteristics	Single or multiple	More often multiple and larger
Associated diseases	Inflammatory bowel disease; Arthritis; Hematologic malignancies	None
Drug testing	Negative	Cocaine: positive Levamisole: rarely positive[a]
Histology	Dermal infiltrate of neutrophils with or without ulceration and necrosis	Dermal infiltrate of neutrophils with or without ulceration and necrosis, with possibility of: Thrombotic vasculopathy Leukocytoclastic vasculitis
p-ANCA	Unfrequent	Positive (70%)
Anti-phospholipid antibodies	Unfrequent	Positive (40%); especially anticardiolipin IgM
Significant improvement of lesions with treatment	At least 2 months	Possible in 1 week[b]

PG: pyoderma gangrenosum.
[a]Rarely positive because of levamisole's short half-life of 5.6 h.
[b]With the combination of a systemic treatment and cocaine cessation.

this substance can induce vasculitic changes in the skin. It could also explain why some patients present with both lesions typical of CIPG and subtle signs of retiform purpura associated with the levamisole-associated vasculitis.

Serologic profile

CIPG shows a similar serologic profile to cases of levamisole-induced vasculitis. A recent review of 20 cases showed that 73% (11/15) of the cases were positive for p-ANCA and 43% (6/14) had at least one antiphospholipid antibody (APL), most frequently the anticardiolipin IgM.[11] Only two out of four were positive for levamisole; the search for levamisole is not often done nor positive considering its short half-life of 5.6 h.[7] It is therefore difficult to confirm its presence in cases of CIPG, but the serologic profiles of these two entities being similar raise the suspicion for its contribution in both cases.[15] Few other cases with negative ANCA and APL like our patients are also described.[8,11,14,16] Establishing a specific immunologic/serologic profile for CIPG is therefore challenging, but positive p-ANCA is still the most frequent finding.

Counseling on cocaine cessation is mandatory. Recurrences are almost always linked to a new exposure. In addition to wound care, topical or systemic corticosteroids have been shown to be effective; CIPG can improve following a one-week treatment with steroids, compared to classic ulcerative PG that usually take longer.[5] Other immunosuppressive treatments, including infliximab, can be an option considering the extensive disease.[1,17]

Declaration of conflicting interests

The author(s) declared no potential conflicts of interest with respect to the research, authorship and/or publication of this article.

Funding

The author(s) received no financial support for this research, authorship and/or publication of this article.

Informed consent

Informed consent from both patients was acquired for the publication of this article

References

1. Ashchyan HJ, Nelson CA, Stephen S, et al. Neutrophilic dermatoses: pyoderma gangrenosum and other bowel- and arthritis-associated neutrophilic dermatoses. *J Am Acad Dermatol* 2018; 79(6): 1009–1022.
2. Wang JY, French LE, Shear NH, et al. Drug-induced pyoderma gangrenosum: a review. *Am J Clin Dermatol* 2018; 19(1): 67–77.
3. Lee KC, Ladizinski B and Federman DG. Complications associated with use of levamisole-contaminated cocaine: an emerging public health challenge. *Mayo Clin Proc* 2012; 87(6): 581–586.
4. Zhu NY, Legatt DF and Turner AR. Agranulocytosis after consumption of cocaine adulterated with levamisole. *Ann Intern Med* 2009; 150(4): 287–289.
5. Jeong HS, Layher H, Cao L, et al. Pyoderma gangrenosum (PG) associated with levamisole-adulterated cocaine: clinical, serologic, and histopathologic findings in a cohort of patients. *J Am Acad Dermatol* 2016; 74(5): 892–898.

6. Sampson D. Immunopotentiation and tumor inhibition with levamisole. *Cancer Treat Rep* 1978; 62(11): 1623–1625.
7. Wolford A, McDonald TS, Eng H, et al. Immune-mediated agranulocytosis caused by the cocaine adulterant levamisole: a case for reactive metabolite(s) involvement. *Drug Metab Dispos* 2012; 40(6): 1067–1075.
8. Sehgal R, Resnick JM, Al-Hilli A, et al. Nasal septal and mucosal disease associated with pyoderma gangrenosum in a cocaine user. *JAAD Case Rep* 2017; 3(4): 284–287.
9. Lynch KL, Dominy SS, Graf J, et al. Detection of levamisole exposure in cocaine users by liquid chromatography-tandem mass spectrometry. *J Anal Toxicol* 2011; 35(3): 176–178.
10. Aberastury MN, Silva WH, Vaccarezza MM, et al. Epilepsia partialis continua associated with levamisole. *Pediatr Neurol* 2011; 44(5): 385–388.
11. Moreno-Artero E, Querol-Cisneros E, Rodríguez-Garijo N, et al. Cocaine-induced pyoderma gangrenosum-like lesions. *J Dtsch Dermatol Ges* 2018; 16(6): 763–768.
12. Keith PJ, Joyce JC and Wilson BD. Pyoderma gangrenosum: a possible cutaneous complication of levamisole-tainted cocaine abuse. *Int J Dermatol* 2015; 54(9): 1075–1077.
13. von den Driesch P. Pyoderma gangrenosum: a report of 44 cases with follow-up. *Br J Dermatol* 1997; 137(6): 1000–1005.
14. Baliu-Pique C and Mascaro JM. Multifocal and refractory pyoderma gangrenosum: possible role of cocaine abuse. *Australas J Dermatol* 2017; 58(3): e83–e86.
15. Dartevel A, Chaigne B, Moachon L, et al. Levamisole-induced vasculopathy: a systematic review. *Semin Arthritis Rheum* 2019; 48(5): 921–926.
16. Ruiz-Villaverde R and Sanchez-Cano D. Multiple pyoderma gangrenosum ulcers associated with cocaine abuse. *Sultan Qaboos Univ Med J* 2016; 16(4): e527–e528.
17. Roche E, Martínez-Menchón T, Sánchez-Carazo JL, et al. [Two cases of eruptive pyoderma gangrenosum associated with cocaine use]. *Actas Dermosifiliogr* 2008; 99(9): 727–730.