



Case report

Microscopic polyangiitis associated with pleuropericarditis, pulmonary embolism and pulmonary hemorrhage as a complication of silicosis



Amjad Al-Rajhi ^{a,*}, Elisa Ferreira Brega ^b, Neil C. Colman ^c

^a McGill University, Montreal General Hospital, D7.201, Montreal, Quebec H3G 1A4, Canada

^b Department of Pathology, McGill University, Duff Medical Building, 3775 University Street, Montreal, Quebec H3A 2B4, Canada

^c McGill University Health Centre, McGill University, Montreal General Hospital, D7.201, Montreal, Quebec H3G 1A4, Canada

ARTICLE INFO

Article history:

Received 20 January 2015

Accepted 22 March 2015

Keywords:

ANCA

Vasculitis

Silicosis

Occupational lung disease

Microscopic polyangitis

ABSTRACT

Silica (silicon dioxide) occupational exposure has been linked to both pulmonary and extra-pulmonary toxicity. Silicosis is the major pulmonary toxicity, which has also been associated with the development of collagen-vascular disease and with anti-neutrophil cytoplasmic antibody (ANCA)-positive vasculitis, especially perinuclear anti-neutrophil cytoplasmic antibodies (P-ANCA). The most common pulmonary manifestations of microscopic polyangiitis (MPA) are interstitial fibrosis and alveolar hemorrhage. We describe a patient who had unusual presentation of microscopic polyangiitis, characterized by lung hemorrhage, rapidly progressive glomerulonephritis, pleuropericarditis and pulmonary embolism that was associated with a history of silica exposure and radiologic evidence for silicosis.

© 2015 The Authors. Published by Elsevier Ltd. This is an open access article under the CC BY-NC-ND license (<http://creativecommons.org/licenses/by-nc-nd/4.0/>).

1. Introduction

Occupational exposures to silica dust has been linked to both pulmonary and extra-pulmonary toxicity [1–6]. The major pulmonary toxicity is silicosis. Silicosis has also been associated with the development of collagen-vascular disease and with anti-neutrophil cytoplasmic antibody (ANCA)-positive vasculitis, especially anti-myeloperoxidase (MPO) antibody [1,7]. The most common pulmonary manifestations of microscopic polyangiitis (MPA) are interstitial fibrosis and alveolar hemorrhage [8]. We describe a patient who had microscopic polyangiitis, characterized by lung hemorrhage, pulmonary embolism and pleuropericarditis that was associated with a history of silica exposure and radiologic evidence for silicosis.

2. Case report

A 68-year-old man reported a 2-week history of dry cough with a central chest discomfort radiating to the epigastrium. There was no associated hemoptysis, breathlessness or palpitations. He was

seen in another institution 11 days prior to admission where he was found to have atrial fibrillation. A CT scan of the chest with contrast revealed small filling defects at the sub segmental level in both lower lobes (Fig. 1) diagnostic of pulmonary embolism. No alveolar filling was seen. The patient was treated with IV heparin and amiodarone. He was discharged on oral anticoagulation (Rivaroxaban). However, cough persisted and he developed daily scanty hemoptysis with progressive breathlessness, for which he sought attention at our institution.

On initial evaluation there was no fever or hemodynamic instability. There was no clinical evidence of congestive heart failure. Oxygen requirements were high (90% saturation; FiO₂ 1.0) and he was admitted to the intensive care unit for further evaluation and monitoring.

Review of his occupational history revealed a 10-year history of sandblasting without respiratory protection while working in a automobile body shop between 1994 and 2004.

Laboratory tests showed a microcytic hypochromic anemia (Hgb 9 g/l, MCV 78.5 fl), INR 1.82, PTT 42.8, creatinine 150 μmol/L (Normal: 55–110 μmol/L) and positive anti-myeloperoxidase (MPO) antibodies (>200 RU/ml). Urine analysis showed: 60–80 RBC/high-powered field, several granular casts, with a few RBC and fatty casts. Multiple alveolar opacities were noted in both lungs on chest radiography (Fig. 2.1).

* Corresponding author.

E-mail addresses: amjad.al-rajhi@mail.mcgill.ca (A. Al-Rajhi), elisa.brega@mail.mcgill.ca (E.F. Brega), neil.colman@mcgill.ca (N.C. Colman).

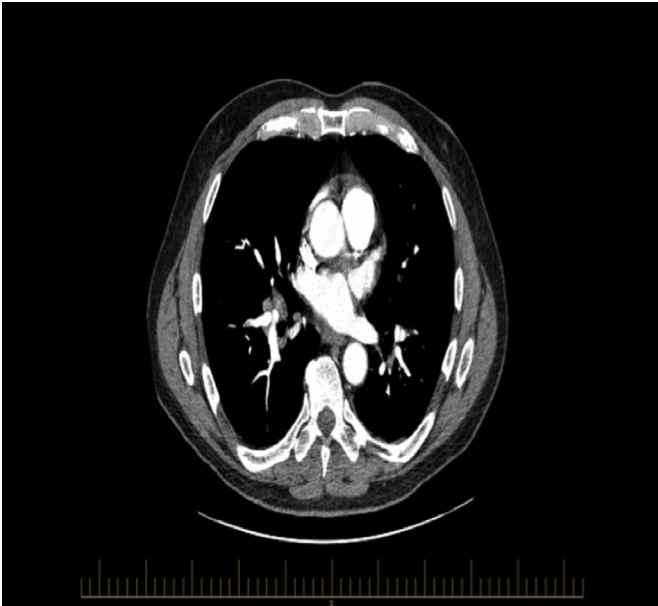


Fig. 1. CT chest with contrast showing small filling defects at sub segmental left lower lobe and right lower lobe.

A CT scan of the chest showed diffuse heterogeneous opacification of the lungs centrally with sparing of the lung periphery consistent with a diagnosis of diffuse alveolar hemorrhage. There were numerous small sub pleural nodules as well as mediastinal and hilar adenopathy, consistent with a diagnosis of silicosis (Fig. 3).

There were small bilateral pleural effusions and a moderate pericardial effusion with contrast enhancement (Fig. 4).

Kidney ultrasound was normal. Echocardiography revealed a moderate pericardial effusion with normal global and regional LV systolic function. A renal biopsy revealed changes compatible with active pauci-immune glomerulonephritis with focal and segmental fibrinoid necrosis associated with small cellular crescents (Fig. 5).

Treatment was initiated with methyl prednisone 1 g IV daily for two days that was followed by oral prednisone 80 mg daily.

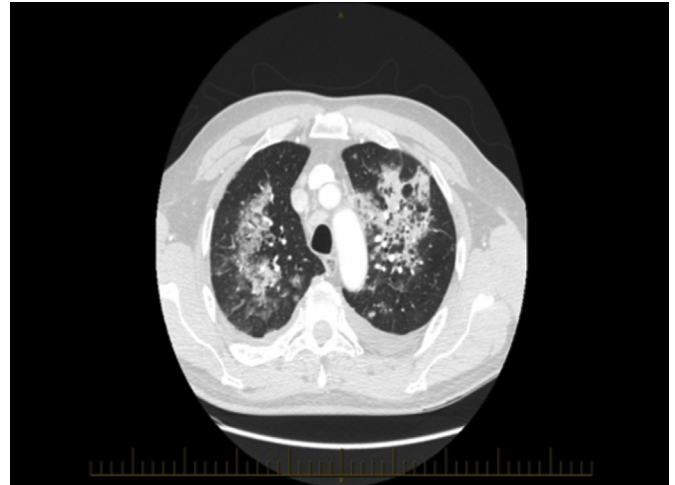


Fig. 3. Heterogeneous opacification of the lungs centrally with sparing the lung periphery diagnostic of the lung hemorrhage, with small sub pleural nodular opacities in the upper lobes diagnostic of silicosis.

Cyclophosphamide 1540 mg intravenously was given as a single dose in addition to Mesna.

There was dramatic and rapid improvement with reduction in oxygen requirements and significant radiographic clearing (Fig. 2.2) over the next 4 days. The patient was transfused packed red blood cells. The acute kidney injury persisted with elevated creatinine. One month following discharge there was resolution of the airspace lung opacities.

3. Discussion

Silica (silicon dioxide) exposure is the cause of silicosis. Occupations at risk include miners, foundry workers, sandblasters, as well as workers in the ceramic and glass manufacturing industries [1,4]. There are a number of recognized complications of silica exposure including silicosis, progressive massive fibrosis, chronic obstructive pulmonary disease, and increased risk of TB infection and lung cancer [4,9]. Systemic complications that have been linked to silica exposure with silicosis include: rheumatoid arthritis,

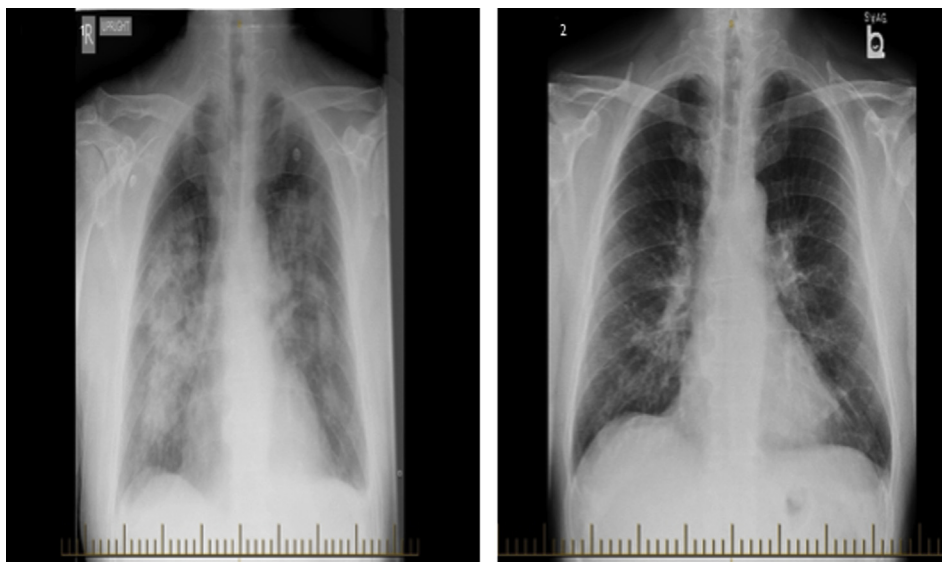


Fig. 2. 1 and 2. CXR before and after treatment.

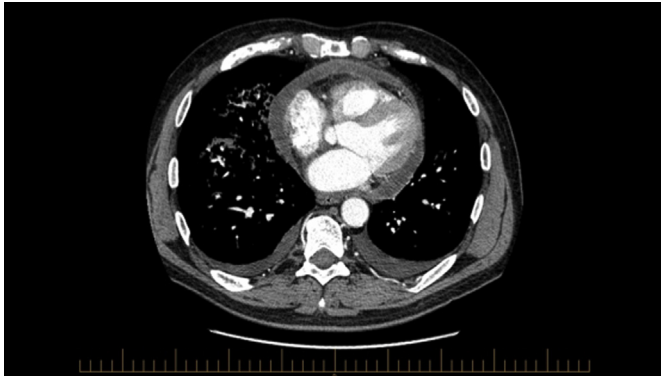


Fig. 4. Small bilateral pleural effusion and mild to moderate pericardial effusion with enhancement of the pericardium.

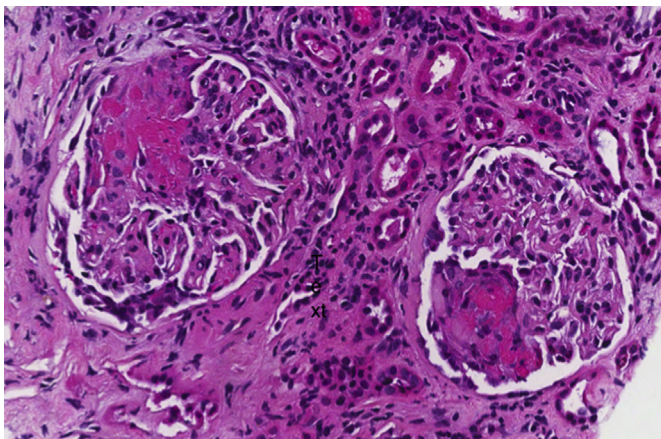


Fig. 5. Light microscopy showing glomeruli with cellular crescents and fibrin deposits. H&E staining, 20 \times .

scleroderma, systemic lupus erythematosus, autoimmune hemolytic anemia, dermatomyositis or dermatopolymyositis, renal failure and ANCA vasculitis [4,9].

Most of the studies that examine the relationship between silica exposure and the development of systemic vasculitides have been conducted among patients who have pulmonary silicosis [3,6,9–11]. There is insufficient evidence in the literature to support an association of silica exposure alone, in the absence of silicosis with systemic vasculitides.

Silica exposure can cause dysregulation of the immune system. Lee and colleagues showed that in men who have chronic exposure to silica particles, there is activation of both responder and regulatory T-cells leading to autoimmune dysregulation [12]. It is also plausible that free-oxygen radicals produced from silica stimulated-polymorphonuclear lymphocytes (PMN) could trigger a pathway leading to endothelial damage. The interaction with silica and the cell membrane induces the expression of myeloperoxidase on the cell membrane of PMN's and monocytes; its subsequent release could induce an autoimmune reaction characterized by the development of ANCA [2].

Microscopic polyangiitis is a systemic ANCA-associated vasculitis that clinically and histologically affects small blood vessels with pauci-immune necrotizing lesions affecting any organ but especially the respiratory tract and kidney [5]. In the perinuclear anti-neutrophil cytoplasmic antibodies (P-ANCA) vasculitis that characterizes MPA, interstitial pneumonitis and alveolar hemorrhage are the two most common pulmonary manifestations [8].

Workers who have had chronic exposure to silica with pulmonary silicosis and with and without connective tissue disease or vasculitis are at much greater risk of developing a wide variety of autoantibodies including P-ANCA when compared to the normal population [3,4,13]. Necrotizing crescentic glomerulonephritis with P-ANCA is strongly associated with MPA [4]. This association may depend more on the duration than on the intensity of silica exposure [7].

That this association is more than fortuitous is suggested by the provocative findings of Hogan and colleagues who reported in their population-based, case-control study that high silica exposure was found in 61 (47%) of 129 anca-associated vasculitis patients compared to 32 (29%) of 109 control subjects ($p < 0.05$) [7]. In addition, a retrospective study in one institution looked at the prevalence of connective tissue disorders in patients who had silicosis between 1985 and 2006 and found a 24-fold increased risk of scleroderma and ANCA-associated vasculitis [3]. Rapidly progressive glomerulonephritis (GN) with ANCA positivity with and without evidence for systemic vasculitis has also been reported in silica-exposed individuals [4].

In addition to alveolar hemorrhage and glomerulonephritis, our patient had pleuropericarditis and pulmonary embolism. These are uncommon manifestations of MPA. Two case reports of pericardial effusion in this context have been published [14,15]. Pleuritis and pleural effusion reflecting pulmonary involvement with MPA have been reported in 8–15% of affected individuals [16,17].

Patients who have ANCA-associated vasculitis also have an increased risk of developing venous thromboembolism especially during the active phase of disease [18]. The increased risk has been hypothesized to result from endothelial changes and hypercoagulability caused by ANCA-vasculitis and its treatment [18–20].

In conclusion, we report a patient with silicosis and complicating microscopic polyangiitis characterized by lung hemorrhage, rapidly progressive glomerulonephritis pleuropericarditis and pulmonary embolism. This report strengthens the evidence supporting the causality of this association and reinforces the need for obtaining a detailed work history in patients who have systemic vasculitis.

Competing interests

None declared.

Acknowledgments

The authors thank Dr. Chantal Bernard for the assistance pathology slides for this case reports.

References

- [1] G. Zaghi, F. Koga, R.M. Nishihara, et al., Autoantibodies in silicosis patients and in silica-exposed individuals, *Rheumatol. Int.* 30 (8) (2010) 1071–1075.
- [2] P. Stratta, A. Messuerotti, C. Canavese, et al., The role of metals in autoimmune vasculitis: epidemiological and pathogenic study, *Sci. Total Environ.* 270 (1–3) (2001) 179–190.
- [3] A. Makol, M.J. Reilly, K.D. Rosenman, Prevalence of connective tissue disease in silicosis (1985–2006)—a report from the State of Michigan Surveillance system for silicosis, *Am. J. Ind. Med.* 54 (4) (2011) 255–262.
- [4] K.B. Mulloy, Silica exposure and systemic vasculitis, *Environ. Health Perspect.* 111 (16) (2003) 1933–1938.
- [5] Z. Rihova, D. Maixnerova, E. Jancova, et al., Silica and asbestos exposure in Anca-associated vasculitis with pulmonary involvement, *Ren. Fail.* 27 (5) (2005) 605–608.
- [6] J.W. Tervaert, C.A. Stegeman, C.G. Kallenberg, Silicon exposure and vasculitis, *Curr. Opin. Rheumatol.* 10 (1) (1998) 12–17.
- [7] S.L. Hogan, G.S. Cooper, D.A. Savitz, et al., Association of silica exposure with anti-neutrophil cytoplasmic autoantibody small-vessel vasculitis: a population-based, case-control study, *Clin. J. Am. Soc. Nephrol.* 2 (2) (2007) 290–299.

- [8] Y. Arimura, S. Minoshima, U. Tanaka, et al., Pulmonary involvement in patients with myeloperoxidase specific-antineutrophil cytoplasmic antibody, *Ryumachi* 35 (1) (1995) 46–55.
- [9] J.A. Gomez-Puerta, L. Gedmintas, K.H. Costenbader, The association between silica exposure and development of Anca-associated vasculitis: systematic review and meta-analysis, *Autoimmun. Rev.* 12 (12) (2013) 1129–1135.
- [10] C.G. Parks, K. Conrad, G.S. Cooper, Occupational exposure to crystalline silica and autoimmune disease, *Environ. Health Perspect.* 107 (Suppl. 5) (1999) 793–802.
- [11] G. Gregorini, P. Tira, J. Frizza, et al., Anca-associated diseases and silica exposure, *Clin. Rev. Allergy Immunol.* 15 (1) (1997) 21–40.
- [12] S. Lee, H. Hayashi, M. Maeda, et al., Environmental factors producing autoimmune dysregulation—chronic activation of T cells caused by silica exposure, *Immunobiology* 217 (7) (2012) 743–748.
- [13] J. Bartunkova, V. Tesar, A. Sediva, Diagnostic and pathogenetic role of anti-neutrophil cytoplasmic autoantibodies, *Clin. Immunol.* 106 (2) (2003) 73–82.
- [14] A.M. Suarez Lares, L. Quinones, A. Torres, A. Pobes, R. Forascepi, A case of P-Anca-positive vasculitis with associated pericardial effusion, *Nefrologia* 30 (2) (2010) 268–269.
- [15] P. Kaur, A. Palya, H. Hussain, S. Dabral, Microscopic polyangiitis presenting as early cardiac tamponade, *J. Clin. Rheumatol.* 16 (2) (2010) 86–87.
- [16] H. Shibuya, H. Sano, K. Osamura, K. Kujime, K. Hara, T. Hisada, Microscopic polyangiitis accompanied by pleuritis as the only pulmonary manifestation of occupational silica exposure, *Intern. Med.* 49 (10) (2010) 925–929.
- [17] J.J. Jin, J.H. Shi, W.X. Lu, Y.J. Zhu, Clinical features of pulmonary involvement in patients with microscopic polyangiitis, *Zhonghua Jie He He Hu Xi Za Zhi* 34 (5) (2011) 339–343.
- [18] P.M. Stassen, R.P. Derks, C.G. Kallenberg, C.A. Stegeman, Venous thromboembolism in Anca-associated vasculitis—incidence and risk factors, *Rheumatol. (Oxford)* 47 (4) (2008) 530–534.
- [19] G. Tomasson, P.A. Monach, P.A. Merkel, Thromboembolic disease in vasculitis, *Curr. Opin. Rheumatol.* 21 (1) (2009) 41–46.
- [20] A.N. Santana, T.Y. Takagaki, C.S. Barbas, Incidence of fatal venous thromboembolism in antineutrophil cytoplasmic antibody-associated vasculitis, *J. Bras. Pneumol.* 37 (3) (2011) 409–411.