

A case of classic adult pityriasis rubra pilaris successfully treated with a combination of acitretin and ustekinumab: A case report

SAGE Open Medical Case Reports
JCMS Case Reports
Volume 10: 1–4
© The Author(s) 2022
Article reuse guidelines:
sagepub.com/journals-permissions
DOI: 10.1177/2050313X221093453
journals.sagepub.com/home/sco



Celina DeBiasio¹ , Janelle Cyr², Yasmine Ayroud³
and Steven J Glassman² 

Abstract

Classic adult pityriasis rubra pilaris is a severe papulosquamous disease that tends to resolve in 3–5 years but can have a devastating impact on patients while active. It shares features with psoriasis, but treatment remains largely empiric, based on case reports and series. The condition is often refractory to treatment, especially initially, with topical corticosteroids and oral acitretin the more commonly employed agents. Relatively high doses of acitretin are needed for adequate response, and adverse events often limit adherence. Given the similarity to psoriasis, biologic agents approved for psoriasis have been used with good effect in classic adult pityriasis rubra pilaris and show better tolerance than other agents. In this report, we describe the successful use of a combination of acitretin and ustekinumab in a case of classic adult pityriasis rubra pilaris.

Keywords

Pityriasis rubra pilaris, systemic therapy, skin diseases, papulosquamous

Introduction

Pityriasis rubra pilaris (PRP) is an uncommon, heterogeneous inflammatory skin disease characterized by salmon scaly papules and plaques with a similarity to psoriasis.^{1,2} Six clinical subtypes have been described, with the classic adult type (Type I) being the most common.³ This presents with acute onset erythema, papules and scale on the scalp and face, spreading downward to the torso and limbs, and featuring a waxy orange-red palmoplantar keratoderma.² Nutmeg grater-like follicular papules on the knuckles, and islands of sparing on the torso and limbs are characteristic. Pruritus and burning can be severe, and the eruption can evolve relatively quickly into erythroderma. Histopathology can be non-specific but in typical cases shows psoriasiform hyperplasia, a retained granular layer, and alternating orthokeratosis and parakeratosis in vertical and horizontal planes.⁴ Treatment of classic adult PRP is largely empiric as there are no large-scale randomized clinical trials.^{2,4,5} Although the disease resolves spontaneously in many cases, there is still an urgent need for effective and safe treatments as this can take several years.⁵

Traditional treatments include topical corticosteroids and vitamin D products, oral retinoids, methotrexate or cyclosporine.^{4,6,7} With some of these systemics, adverse effects often limit chronic treatment. Recently, biologics

have gained popularity owing to their favorable side-effect profile.⁴ Given the similarity to psoriasis, biologics that have been approved for psoriasis have been tried with success in PRP, especially tumor-necrosis factor α (TNF- α) inhibitors like adalimumab and infliximab and more recently anti-interleukin (IL)-17 agents.^{3,8–10} Ustekinumab, an IL-12/23 inhibitor approved for psoriasis as well as Crohn's disease, ulcerative colitis and psoriatic arthritis, has been used effectively in classic adult PRP, underlying a probable role for the IL-23/T helper 17 (Th17) axis in PRP as well as psoriasis.^{8,11,12} In PRP, ustekinumab has been mostly used off-label as monotherapy.^{5,13} In the present report, we describe successful treatment of case of classic adult PRP with a combination of low-dose acitretin and ustekinumab.

¹Faculty of Medicine, University of Ottawa, Ottawa, ON, Canada

²Division of Dermatology, Department of Medicine, University of Ottawa, Ottawa, ON, Canada

³Department of Anatomical Pathology and Laboratory Medicine, University of Ottawa, Ottawa, ON, Canada

Corresponding Author:

Steven J. Glassman, Division of Dermatology, Department of Medicine, University of Ottawa, 4th Floor Civic Parkdale Clinic, 737 Parkdale Ave, Ottawa, ON K1Y 1J8, Canada.

Email: sglassman@toh.ca



Case report

An otherwise healthy 58-year-old woman, without a prior history of eczema or psoriasis, developed an extensive erythematous scaly eruption which started on her face and scalp, and spread rapidly to her torso and limbs. The rash was initially asymptomatic. Her only chronic medication at the time included citalopram 20 mg/d. On examination, she had type II skin with a strikingly symmetrical rash consisting of bright red scaly plaques on the face, torso and limbs, with follicular papules on the dorsal hand and at the advancing edge of the plaques (Figures 1, 2, 3(a)). The scalp showed mild diffuse erythema and scale. There was an orange-red waxy palmoplantar keratoderma and nutmeg grater-like follicular papules on the knuckles (Figure 4(a)). Islands of sparing were prominent on the torso. The initial body surface area (BSA) was 50%. Classic adult PRP was favored, with a differential of psoriasis and progressive symmetric erythrokeratoderma. The skin punch biopsy revealed alternating parakeratosis and orthokeratosis on a vertical and horizontal plane, irregular psoriasiform hyperplasia, thickened papillary dermal plates, preserved granular layer and a perivascular lymphocytic infiltrate in the superficial dermis (Figure 5(a) and (b)). This supported the diagnosis of PRP.

The patient was treated with acitretin 10 mg/d together with copious betamethasone valerate ointment 0.1% twice daily. A month later, her rash continued to extend, and she became erythrodermic. Nocturnal itch became noticeable, associated with tightness of the skin and chills. Acitretin was increased to 20 mg/d and ustekinumab 45 mg subcutaneously was added, utilizing the psoriasis regimen: repeated at 4 weeks and then every 12 weeks. There was a gradual improvement after the second dose of ustekinumab, and her skin had almost cleared by 3 months. The palmoplantar keratoderma resolved completely (Figures 3(b), 4(b)). The scalp was the only site that remained active, with erythema, scale, itch and some alopecia. The dose of ustekinumab was then increased to 90 mg, with improvement in scalp symptoms. The only side effect was some “tackiness” to the palms from the acitretin, which was reduced to 10 mg/d. She remains on this regimen of low-dose acitretin and ustekinumab 90 mg every 12 weeks. Blood work for liver function, complete blood count and lipids remains normal. The plan is to taper the therapy very slowly over 1–2 years.

Discussion

There is emerging anecdotal evidence for the use of psoriasis-type biologics, particularly ustekinumab, as off-label treatments in PRP suggesting similar cytokine profiles in the two diseases.^{1,2,4,5} Recently, a group demonstrated the role of the IL-23/Th17 axis in PRP and found that levels of Th17 cytokines in patients' skin samples paralleled clinical and histological improvements during anti-IL12/23 treatment.¹ IL-17, a key proinflammatory cytokine in psoriasis, has also

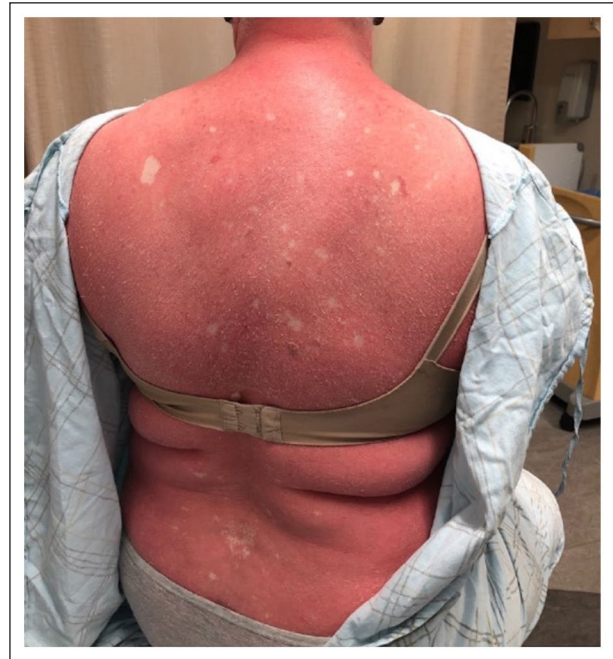

Figure 1. Confluent salmon erythema on the back with islands of sparing.

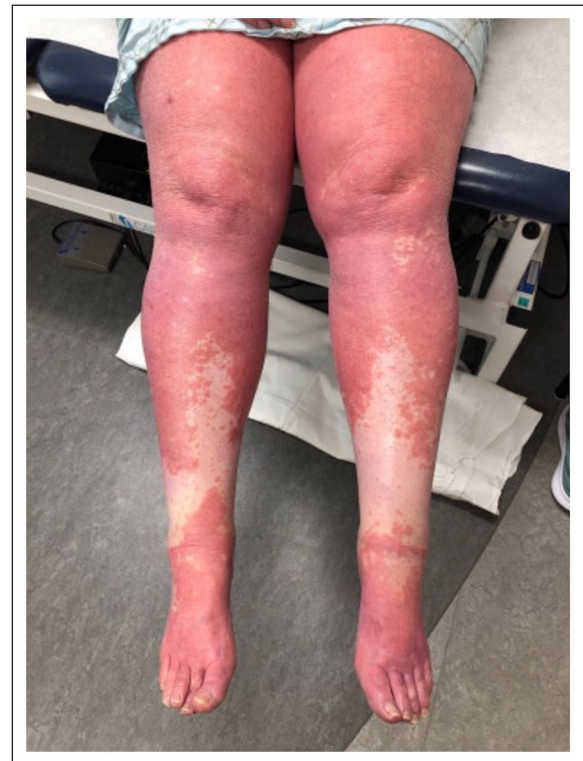

Figure 2. Symmetric confluent salmon erythema on the lower limbs with follicular papules at the active, spreading edge.

been shown to be increased in patients with PRP.^{1,14} While IL-17 inhibitors have been successful in treating PRP, evidence is limited.^{10,13} Ustekinumab is a more commonly

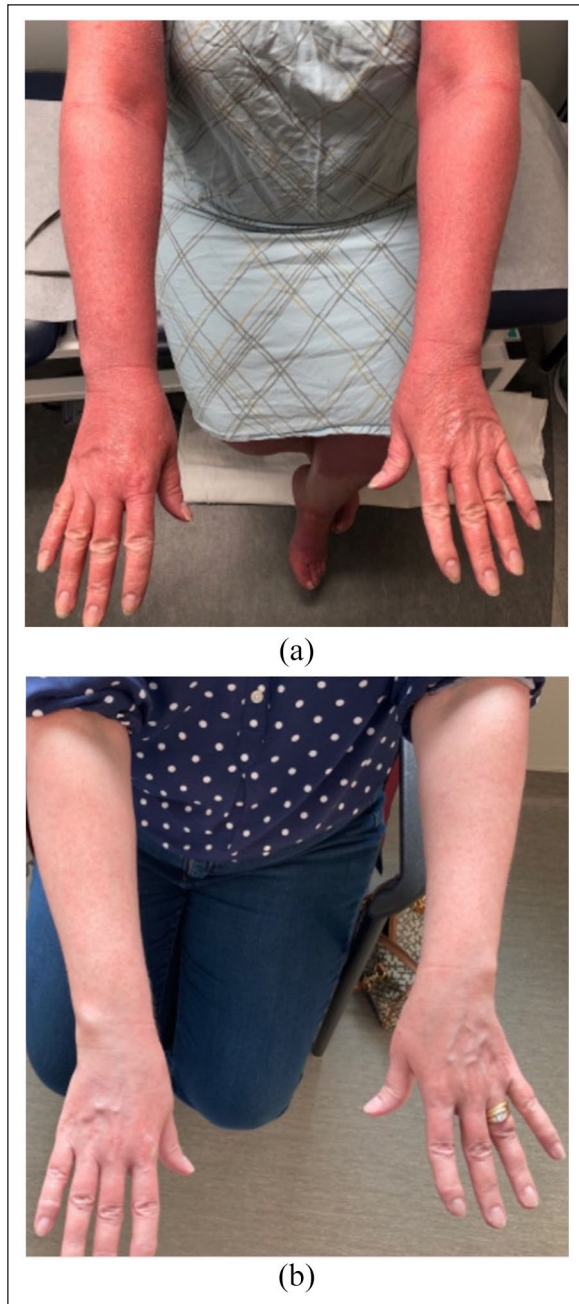

Figure 3. (a) Confluent salmon erythema of the arms with follicular papules on the knuckles. (b) Complete resolution after 3 months' therapy.

reported biologic used in PRP, supported by case reports and case series.^{2,4,8,15} Given our patient's excellent response to ustekinumab, our report provides further support for the effectiveness of anti-IL12/23 agents in PRP.

The treatment of PRP can be challenging given the lack of universal treatment recommendations. With the growing body of anecdotal evidence supporting the use of psoriasis biologics in PRP, case reports can play an important role in clinical decision making and improving the quality of life for patients with PRP. Compared to traditional systemic

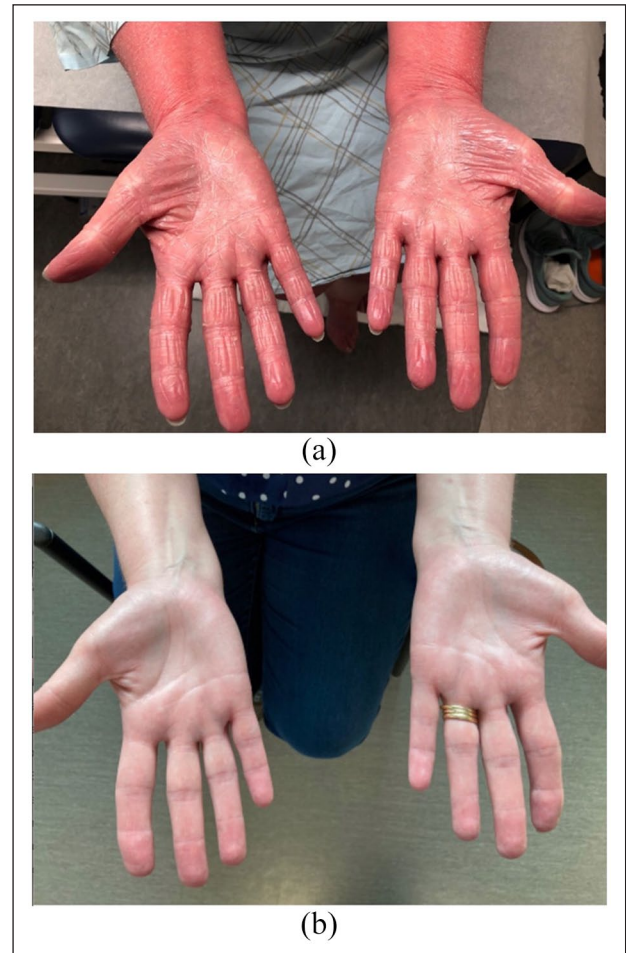


Figure 4. (a) Palmar keratoderma. (b) Complete resolution after 3 months' therapy.

treatments like acitretin and methotrexate, biologics have fewer side effects and preferred tolerance and safety. Nevertheless, a combination of low-dose acitretin and biologics is worth pursuing, especially for the difficult to treat keratoderma in PRP. To our knowledge, there are only two reported cases using concomitant ustekinumab and acitretin in classic adult PRP.^{8,16} In both cases, the acitretin was added later because of persistent palmoplantar lesions; in one patient, there was complete resolution of the keratoderma,¹⁶ and in the other, there was a partial response.⁸

While ustekinumab has been used more commonly as off-label third-line monotherapy in treatment-resistant PRP, a combination of biologics and traditional systemics may be more effective in PRP than biologics alone.^{2,5,8,16} Our report provides further evidence of this observation and suggests that first-line treatment for severe classic adult PRP could include low-dose acitretin in combination with IL-12/23 inhibitors like ustekinumab. Given the lack of randomized controlled trials, further research is needed to accurately assess the efficacy and safety of psoriasis-approved biologics in conjunction with traditional systemic therapy for the treatment of classic adult PRP.

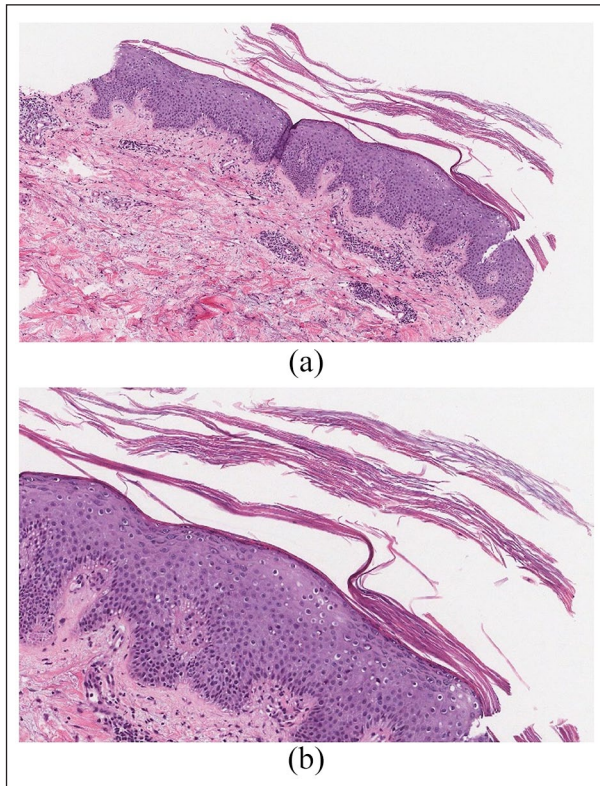


Figure 5. Skin histopathology: (a) Irregular psoriasiform hyperplasia, thickened suprapapillary plates and lymphocytic infiltrate in superficial dermis. Hematoxylin and eosin, original magnification $\times 10$. (b) Preserved granular layer with alternating ortho- and parakeratosis. Hematoxylin and eosin, original magnification $\times 14$.

Acknowledgements

The authors declare that the contents of this article are their own original unpublished findings and that they did not receive any funding for the writing of this manuscript. All authors have contributed equally and agree with the content of the manuscript.

Declaration of conflicting interests

The author(s) declared no potential conflicts of interest with respect to the research, authorship and/or publication of this article.

Funding

The author(s) received no financial support for the research, authorship and/or publication of this article.

Informed consent

The patient provided informed consent for publication of the case report and images.

ORCID iD

Celina DeBiasio  <https://orcid.org/0000-0002-5960-3821>

Steven J Glassman  <https://orcid.org/0000-0002-9699-303X>

References

1. Feldmeyer L, Mylonas A, Demaria O, et al. Interleukin 23-Helper T Cell 17 axis as a treatment target for pityriasis rubra pilaris. *JAMA Dermatology* 2017; 153(4): 304–308.
2. Naidoo A, Sibbald C, Fleming PJ, et al. Use of biologics in pityriasis rubra pilaris refractory to first-line systemic therapy: a systematic review. *J Cutan Med Surg* 2020; 24(1): 73–78.
3. Klein A, Landthaler M and Karrer S. Pityriasis rubra pilaris: a review of diagnosis and treatment. *Am J Clin Dermatol* 2010; 11: 157.
4. Wang D, Chong VCL, Chong WS, et al. A review on pityriasis rubra pilaris. *Am J Clin Dermatol* 2018; 19(3): 377–390.
5. Napolitano M, Abeni D and Didona B. Biologics for pityriasis rubra pilaris treatment: a review of the literature. *J Am Acad Dermatol* 2018; 79(2): 353–359.
6. Walling HW and Swick BL. Pityriasis rubra pilaris responding rapidly to adalimumab. *Arch Dermatol* 2009; 145(1): 99–101.
7. Chowdhary M, Davila U and Cohen DJ. Ustekinumab as an alternative treatment option for chronic pityriasis rubra pilaris. *Case Rep Dermatol* 2015; 7(1): 46–50.
8. Napolitano M, Lembo L, Fania L, et al. Ustekinumab treatment of pityriasis rubra pilaris: a report of five cases. *J Dermatol* 2018; 45(2): 202–206.
9. Maloney NJ, Hisaw LD and Worswick S. Refractory pityriasis rubra pilaris treated with etanercept, adalimumab, or ustekinumab: a retrospective investigation. *Dermatol Ther* 2017; 30(6): 1–5.
10. Bonomo L and Levitt JO. Secukinumab emerges as a rapidly effective therapy for pityriasis rubra pilaris. *Cutis* 2018; 101(5): 367–369.
11. Svoboda SA, Rush PS, Sharghi KG, et al. A case report of disseminated verrucosis secondary to ustekinumab in a patient with Crohn's disease. *SAGE Open Med Case Rep* 2021; 9: 1–4.
12. Ghosh S, Gensler LS, Yang Z, et al. Ustekinumab Safety in Psoriasis, Psoriatic Arthritis, and Crohn's Disease: An Integrated Analysis of Phase II/III Clinical Development Programs. *Drug Saf* 2019; 42(6): 751–768.
13. Engelmann C, Elsner P and Miguel D. Treatment of pityriasis rubra pilaris type I: a systematic review. *Eur J Dermatology* 2019; 29(5): 524–537.
14. Ward M, Maliyar K and Gooderham M. A case report of recalcitrant aphthous ulcers in two patients treated with interleukin-17 inhibitors. *SAGE Open Med Case Reports* 2021; 9: 5–7.
15. Wohlrab J and Kreft B. Treatment of pityriasis rubra pilaris with ustekinumab. *Br J Dermatol*. 2010; 163(3): 655–656.
16. Byekova Y and Sami N. Successful response of refractory type I adult-onset pityriasis rubra pilaris with ustekinumab and acitretin combination therapy. *J Dermatol* 2015; 42(8): 830–831.