




# A Case of an Obstructed Delivery by a Large, Lower Uterine Segment Fibroid Interlocked with a Fetal Mentum

Sarah E. Miller, MD<sup>1</sup>  Hayley E. Miller, MD<sup>1</sup> Anne R. Waldrop, MD<sup>1</sup> Scarlett D. Karakash, MD<sup>1</sup>  
Kate A. Shaw, MD, MS<sup>1</sup>

<sup>1</sup>Department of Obstetrics and Gynecology, Stanford University School of Medicine, Stanford, California

**Address for correspondence** Sarah E. Miller, MD, Department of Obstetrics and Gynecology, Stanford University School of Medicine, 453 Quarry Road, Palo Alto, CA 94304 (e-mail: smiller63@bwh.harvard.edu).

AJP Rep 2024;14:e85–e87.

## Abstract

Uterine leiomyomata are associated with many pregnancy complications and will likely become increasingly common as the average age of childbearing increases. We describe a case of an obstructed delivery by a large fibroid. A 37-year-old G2P1001 with a 10-cm anterior, lower uterine segment fibroid presented for labor induction. Labor was complicated by arrest of descent due to suspected obstruction of the fetal body by the fibroid after descent of the fetal head, and delivery during cesarean section was complicated by apparent interlocking of the fetal mentum with the fibroid. Large, anterior lower uterine segment fibroids have the potential to obstruct delivery of the fetal head or of the fetal body, and these patients should be counseled regarding the potential for complications via both vaginal and cesarean deliveries.

## Keywords

- ▶ cesarean section
- ▶ leiomyomas of the uterus
- ▶ obstructed delivery
- ▶ labor
- ▶ management

Uterine leiomyomata during pregnancy are becoming increasingly common. Prior to the late 2000s, the reported prevalence ranged from 0.1 to 3.9%, with more recent data suggesting rates closer to 11%.<sup>1,2</sup> As the average age of first-time mothers in addition to higher birth orders continues to increase, so does the prevalence of fibroids in pregnancy which is known to increase with age.<sup>3,4</sup> This increase in prevalence will disproportionately affect women of black race given the prevalence of fibroids in this population is two- to threefold higher than women of white race.<sup>4</sup> Leiomyomata have been associated with both maternal and fetal complications during pregnancy, some with severe morbidity. Studies have suggested complications including increased rates of cesarean delivery, fetal malposition, preterm delivery, placenta previa, and postpartum hemorrhage—among others.<sup>5</sup> Data surrounding the relative risk of many of these complications are mixed, however, making

management decisions for these patients challenging, especially regarding mode of delivery.

These complications may vary based on location, size, and number of leiomyomata. Some studies have suggested that fibroids more than 3 cm result in an increased rate of malpresentation, preterm labor, placental abruption, pelvic pain, and cesarean delivery.<sup>5</sup> Another study specifically compared labor-eligible patients with leiomyomata more than or less than 10 cm in size, reporting that there was no statistically significant difference in cesarean section rates between these groups.<sup>2</sup> Additionally, multiple studies have demonstrated an increased risk of cesarean section prior to the onset of labor in patients with large uterine fibroids, even after controlling for potential confounders including maternal age, nulliparity, fetal presentation, and placenta previa.<sup>2,6</sup> However, there is significant variability in the location and type of these large fibroids. For example, obstructive fibroids,

received  
October 18, 2021  
accepted  
October 22, 2023

DOI <https://doi.org/10.1055/s-0043-1778002>.  
ISSN 2157-6998.

© 2024. The Author(s).

This is an open access article published by Thieme under the terms of the Creative Commons Attribution-NonDerivative-NonCommercial-License, permitting copying and reproduction so long as the original work is given appropriate credit. Contents may not be used for commercial purposes, or adapted, remixed, transformed or built upon. (<https://creativecommons.org/licenses/by-nc-nd/4.0/>)

Thieme Medical Publishers, Inc., 333 Seventh Avenue, 18th Floor, New York, NY 10001, USA

or fibroids that are in a position that obstructs the vaginal canal, lead to very different challenges from pedunculated fibroids that are distant from the vaginal canal. Similarly, a large, intramural fundal fibroid may not cause the same difficulty with delivery of a fetus than a large, intramural fibroid located in the anterior lower uterine segment when planning a hysterotomy incision during cesarean section. This variability therefore leads to expectedly different complications, thus leading to decisions surrounding mode of delivery being provider dependent and not particularly data driven.

The case described later outlines a large lower uterine segment fibroid obstructing delivery. To our knowledge, it is the first reported case of a fibroid obstructing delivery of the fetal body, after successful descent of the fetal head below the fibroid. A cesarean delivery was performed and complicated by difficulty delivering the fetal head through the hysterotomy due to its entrapment below the lower uterine segment fibroid. Informed consent was obtained from the patient for publication of her case.

## Case

### Labor Course

A 37-year-old woman, G2P1001 presented to labor and delivery at 39<sup>5/7</sup> weeks of gestation for induction of labor for gestational hypertension. Her pregnancy was complicated by a history of enlarged uterine fibroids, with the largest noted in the lower uterine segment measuring 9.6 cm in the largest dimension on her 36<sup>0/7</sup>-week growth scan. The fibroid's size was monitored throughout her pregnancy via ultrasound, increasing in size from 6.1 cm in its largest dimension on her 20<sup>0/7</sup>-week anatomy scan. In the patient's prior pregnancy, she reported that her fibroid was significantly smaller in size and ultimately resulted in an uncomplicated vaginal delivery.

On admission, the patient's cervix was examined, and the fibroid was not felt to be obstructive given the fetal head was palpable, with the fibroid palpated anterior to and clear of the vaginal vault. Given this examination and the patient's history of a prior successful vaginal delivery, after extensive counseling, the shared decision was made to proceed with a trial of labor with a low threshold to proceed with cesarean delivery. The patient was counseled that fetal descent would be closely monitored given our concern for the possibility of the fibroid to prevent descent of the fetal head. It was discussed that there would be a low threshold to proceed with cesarean delivery with a likely classical uterine incision given the location of her lower uterine segment, anterior fibroid.

The patient progressed over a normal labor curve. Bedside ultrasounds were serially performed during her labor course, noting descent of the fetal head below the lower uterine segment fibroid upon ultrasound and concurrent sterile vaginal examination at a cervical dilation of 5 cm. The patient reached complete dilation at two stations after 2 hours in the active stage of labor. After 90 minutes of pushing with excellent maternal effort, the patient had made minimal descent to one station with development of a Category II fetal

heart tracing, with recurrent variable decelerations. Given the patient was remote from delivery with minimal descent, the patient was counseled and amenable to proceed with the recommendation for an urgent cesarean section for arrest of descent at one station in setting of a Category II fetal heart tracing.

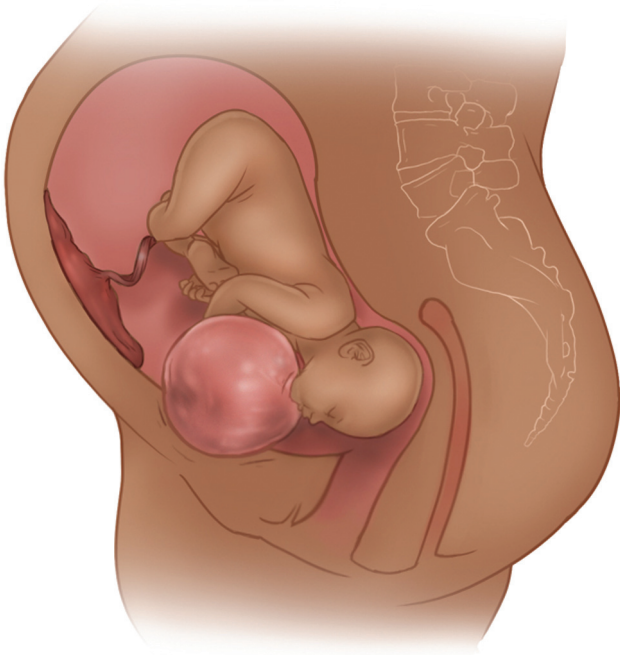
### Cesarean Section

In dorsal lithotomy, a Pfannenstiel incision was made under epidural anesthesia. Upon peritoneal entry, the uterus was examined noting a 9 to 10 cm midline anterior lower uterine segment fibroid encompassing nearly the entire lower uterine segment in addition to an anterior 4 cm fibroid on the right mid-uterus. The decision was made to proceed with a classical uterine incision in an attempt to avoid the large lower uterine segment fibroid. Following hysterotomy, delivery of the fetal head in vertex position, with assistance of a hand in the vagina to elevate the fetal head from below, was unsuccessful given deep impaction of the fetal head beneath the fibroid. Reverse breech extraction was then attempted. Despite ongoing attempted elevation of the fetal head vaginally, it remained impacted beneath the fibroid with the fetal mandible interlocking with the fibroid. Ultimately, with manual rotation vaginally to disengage the fetal chin from the fibroid, the fetus was delivered via reverse breech extraction, 8 minutes following hysterotomy. One- and 5-minute Apgar scores were 2 and 8, and venous cord pH was 7.09 with a base excess of 8.1. The infant was successfully resuscitated in the operating room, admitted to the well-baby nursery, and discharged routinely on day of life 3.

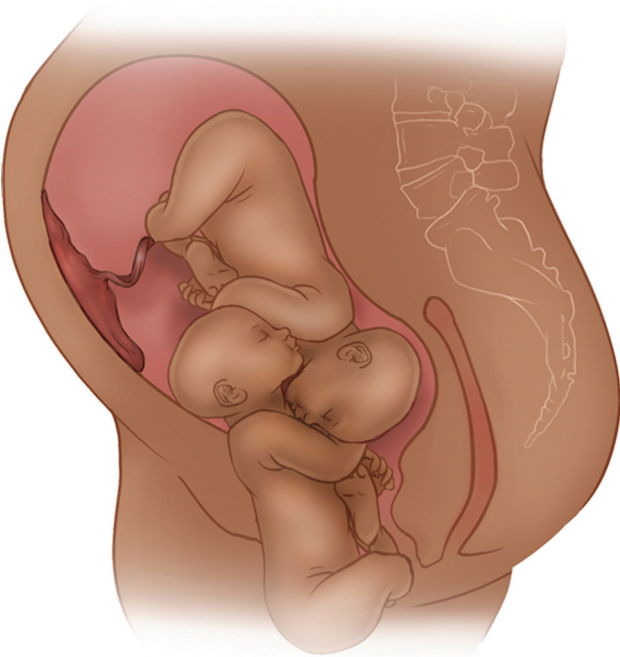
## Discussion

Our case outlines a not previously described complication of a failed trial of labor in a patient, after descent of the fetal head, from suspected obstruction of the fetal body by a large, anterior lower uterine segment fibroid (► **Fig. 1**). Data surrounding pregnancy outcomes in women with leiomyomata are both limited and mixed. Given the variability in complications based on fibroid size and location, there are currently no standardized recommendations regarding mode of delivery in these patients. Despite this, multiple studies have shown that the rate of scheduled cesarean delivery is higher in patients with uterine leiomyomas even when they are otherwise eligible for labor, suggesting that providers are recommending cesarean section in these patients more frequently.<sup>2,6</sup> While future research is warranted to investigate the rationale of these recommendations more granularly, we believe that this case highlights an important complication to consider in the setting of a large fibroid in the anterior lower uterine segment.

A mechanistically similar phenomenon is that of interlocking twins, in which Twin A presents as breech and Twin B presents as vertex, and the heads of the twins become interlocked preventing the vaginal breech delivery of the head of Twin A (► **Fig. 2**). These cases have a high fetal morbidity and mortality and are rare, especially given the rare occurrence of term, breech vaginal deliveries. In our



**Fig. 1** Fibroid position relative to fetus at the time of cesarean section.



**Fig. 2** Mechanistic similarity to interlocking twins.

case, the infant was unable to deliver vaginally given collision of the fetal shoulder with the fibroid, and this also resulted in a challenging cesarean delivery given the fetal head interlocking with the fibroid. This possibility should therefore be considered when making recommendations for the mode of delivery in the setting of a large, lower uterine segment fibroid.

## Conclusion

While the case presented is unique, it identifies an important potential complication that should be discussed when counseling patients. Uterine fibroids are common in pregnancy and will continue to become increasingly common as the average age of pregnant patients increases. This burden will disproportionately affect black patients given the higher prevalence in this patient population. Given the increased morbidity and mortality of pregnancies complicated by fibroids, more research is warranted to identify how the size, type, and location of fibroids may impact delivery and increase risk of complications. It is our hope that the current case allows physicians to provide more comprehensive counseling surrounding the potential complications of a trial of labor with large uterine fibroids.

## Conflict of Interest

None declared.

## Acknowledgments

We would like to thank Dr. Halley Darrach for her contribution in designing and creating **–Figs. 1 and 2.**

## References

- 1 Laughlin SK, Baird DD, Savitz DA, Herring AHS, Hartmann KE. Prevalence of uterine leiomyomas in the first trimester of pregnancy: an ultrasound-screening study. *Obstet Gynecol* 2009;113(03):630–635
- 2 Qidwai GI, Caughey AB, Jacoby AF. Obstetric outcomes in women with sonographically identified uterine leiomyomata. *Obstet Gynecol* 2006;107(2 Pt 1):376–382
- 3 Mathews TJ, Hamilton BE. Mean age of mothers is on the rise: United States, 2000–2014. *NCHS Data Brief* 2016;(232):1–8
- 4 Stewart EA, Cookson CL, Gandolfo RA, Schulze-Rath R. Epidemiology of uterine fibroids: a systematic review. *BJOG* 2017;124(10):1501–1512
- 5 Rice JP, Kay HH, Mahony BS. The clinical significance of uterine leiomyomas in pregnancy. *Am J Obstet Gynecol* 1989;160(5 Pt 1):1212–1216
- 6 Vergani P, Locatelli A, Ghidini A, Andreani M, Sala F, Pezzullo JC. Large uterine leiomyomata and risk of cesarean delivery. *Obstet Gynecol* 2007;109(2 Pt 1):410–414