


STANDARD ARTICLE

Assessment of eosinophils in gastrointestinal inflammatory disease of dogs

Idil Bastan¹ | Aaron K. Rendahl² | Davis Seelig¹ | Michael J. Day³ | Edward J. Hall³ |
Savita P. Rao²  | Robert J. Washabau¹ | P. Sriramarao²

¹Department of Veterinary Clinical Sciences, University of Minnesota, St. Paul, Minnesota

²Department of Veterinary and Biomedical Sciences, University of Minnesota, St. Paul, Minnesota

³Bristol Veterinary School, University of Bristol, Bristol, United Kingdom

Correspondence:

Robert J. Washabau, Department of Veterinary Clinical Sciences, University of Minnesota, 1365 Gortner Avenue, St Paul, MN 55108.

washabau@umn.edu

and

Savita P. Rao, Department of Veterinary and Biomedical Sciences, 1971 Commonwealth Avenue, St. Paul, MN 55108.

raox099@umn.edu

Present address

Idil Bastan, Department of Internal Medicine, Faculty of Veterinary Medicine, Ankara University, Ziraat Mahallesi, Şht. Ömer Halisdemir Blv, 06110 Altındağ, Ankara, Turkey.

Michael J. Day, School of Veterinary and Life Sciences, Murdoch University, South Street, Murdoch 6150, Perth, Western Australia, Australia.

Funding information

University of Minnesota College of Veterinary Medicine Research Office, Minnesota Agricultural Experiment Station, and General Ag Research Funds, Grant/Award Number: RJW; Grant No. MIN-62-059

Background: Accurate identification of eosinophils in the gastrointestinal (GI) tract of dogs with eosinophilic GI disease (EGID) by histological evaluation is challenging. The currently used hematoxylin and eosin (H&E) staining method detects intact eosinophils but does not detect degranulated eosinophils, thus potentially underrepresenting the number of infiltrating eosinophils.

Objective: To develop a more sensitive method for identifying and quantifying both intact and degranulated eosinophils to diagnose EGID more accurately.

Methods: Endoscopically obtained paraffin-embedded intestinal biopsy specimens from dogs with GI signs were examined. The study groups were dogs with eosinophilic enteritis (EE), lymphoplasmacytic and mixed enteritis, and control dogs with GI signs but no histologic changes on tissue sections. Consecutive sections were immunolabeled with monoclonal antibodies (mAbs) against the eosinophil granule protein eosinophil peroxidase (Epx) and stained by H&E, respectively. The number of eosinophils was manually quantified and classified as intact or degranulated.

Results: The number of intact eosinophils detected in Epx mAb-labeled duodenal sections was significantly higher compared with that in H&E-stained sections, with a similar relationship noted in the colon and stomach. The Epx mAb allowed the unique assessment of eosinophil degranulation. The number of intact and degranulated eosinophils was significantly higher in duodenal lamina propria of the EE and mixed group compared to the control group.

Conclusion: Immunohistochemical detection of Epx provides a more precise method to detect GI tract eosinophils compared to H&E staining and could be used as an alternative and reliable diagnostic tool for assessment of biopsy tissues from dogs with EGID.

KEYWORDS

dog, eosinophil peroxidase, diagnostic marker, gastrointestinal inflammation

1 | INTRODUCTION

Eosinophilic gastrointestinal disease (EGID) includes a spectrum of disorders defined by eosinophilic inflammation in ≥ 1 sites (ie, esophagus,

Abbreviations: EE, eosinophilic enteritis; EGID, eosinophilic gastrointestinal disease; Epx, eosinophil peroxidase; GI, gastrointestinal; H&E, hematoxylin and eosin; IBD, inflammatory bowel disease; IHC, immunohistochemistry; LP, lamina propria; LPE, lymphoplasmacytic enteritis; mAb, monoclonal antibody

stomach, intestine, and colon) of the GI mucosa without any known cause for such infiltration (eg, drug reactions, parasitic infections, malignancy, and other causes).^{1,2} Eosinophils play a crucial role in innate and adaptive immunity of the GI tract by participating in host defense against luminal pathogens and maintaining intestinal epithelial homeostasis.³⁻⁵ In dogs, IBD is the term used to describe persistent or recurrent GI signs (eg, weight loss, vomiting, and diarrhea) and histopathological evidence of intestinal inflammation without underlying

causes (eg, infection, endocrine, and neoplastic disease).^{6,7} Mucosal inflammation is a characteristic histopathological feature of IBD and the primary forms of small intestinal IBD in dogs are LPE, characterized by increased numbers of lymphocytes and plasma cells, and EE, which is characterized by infiltration predominantly of eosinophils.⁶

Eosinophils are multifunctional granulocytes that, upon activation, play a critical role in regulating innate and adaptive immune responses by release of various mediators such as cytokines, growth factors, chemokines, and cytotoxic granule proteins (degranulation).^{4,8} Preformed cytotoxic granule proteins such as eosinophil cationic protein, Epx, and major basic protein released by activated eosinophils during inflammation can contribute to tissue damage and dysfunction.⁹⁻¹² Therefore, it is important to accurately detect not only intact eosinophils with intracellular granule proteins but also extracellular release of granule proteins by activated eosinophils, to obtain a better understanding of the contribution of eosinophil activation to disease pathogenesis. The pathophysiological effects associated with eosinophilic infiltration of the GI tract remain poorly defined.⁴ Histological evaluation of endoscopic biopsy specimens is performed frequently in the diagnosis and management of dogs with IBD. This evaluation entails detailed characterization of the inflammatory infiltrate (ie, lymphocytes, plasma cells, and eosinophils), the area affected (ie, focal or generalized, superficial, or deep), the severity of inflammation (ie, mild, moderate, and severe), and any microarchitectural changes (ie, villus fusion or atrophy and fibrosis).¹³

The assessment of GI mucosal inflammation, including the quantification of eosinophils, by H&E staining of biopsy tissues in conjunction with exclusion of underlying disease is used as a guideline in the diagnosis of IBD.¹⁴ However, H&E staining can only detect intact but not degranulated, eosinophils, and therefore may underrepresent the extent of eosinophilic infiltration.¹⁵ Although eosinophils are present in the normal small intestinal mucosa, the distinction between the upper limit of normal and abnormally increased tissue eosinophils is not clearly defined using H&E staining.^{14,16,17} Using jejunal tissue collected at necropsy examination from dogs with IBD, we previously have demonstrated that IHC using a mAb specific for the eosinophil granule protein Epx allows reliable morphological identification of degranulated as well as intact eosinophils and could serve as a tool for quantitative evaluation of eosinophils in the small intestine.¹⁵ Our specific aim in the present study was to quantify and compare eosinophil counts by H&E versus Epx mAb IHC of endoscopically obtained biopsy specimens from a larger, clinically well-defined cohort of dogs to further our understanding of the role of eosinophils and eosinophil degranulation in intestinal inflammation in dogs.

2 | MATERIALS AND METHODS

2.1 | Animals and samples

Thirty dogs (17 male and 13 female) were included in our retrospective study based on duodenal histopathology of endoscopic biopsy specimens from cases submitted to the Pathology Unit of University of Bristol, Bristol, United Kingdom. Dogs were of 17 different breeds: Terrier-cross (n = 2), German Shepherd (n = 3), Labrador Retriever

(n = 6), Dachshund (n = 2), Jack Russell Terrier (n = 3), Cross-bred (n = 2), Cavalier King Charles Spaniel (n = 2), and 1 each of the following breeds: Miniature Schnauzer, Pit Bull Terrier, Saluki, Doberman Pincher, Boxer, Staffordshire Bull Terrier, Lurcher, Chihuahua, Rhodesian Ridgeback, and Foxhound. The study population included dogs with EE (n = 10; median age, 5.5 years, with a mean \pm standard deviation [STD] of 5.5 ± 3.8 years) and dogs with mixed eosinophilic/LPE (n = 10; median age, 3.5 years, with a mean \pm STD of 4.5 ± 3.1 years). Because endoscopic biopsy of healthy dogs is not permitted at the Pathology Unit of University of Bristol, the control group (n = 10; median age, 3.5 years, with a mean \pm STD of 4.5 ± 2.8 years) comprised dogs with a variety of GI signs (eg, regurgitation, vomiting, weight loss, intermittent diarrhea, and abdominal pain) requiring endoscopic investigation, but in which intestinal biopsy specimens were assessed as histologically normal. All dogs underwent standard investigations consisting of hematological examination, serum biochemistry, serum folate and cobalamin concentrations, basal cortisol concentration or ACTH stimulation test, urinalysis, and abdominal imaging (transabdominal ultrasound examination, radiographs, or computed tomography). Fecal parasitological examinations were performed in all dogs unless they had recently undergone trial treatment with fenbendazole before referral, and all were negative. Records before referral were sometimes incomplete, but no dog was reported to have responded to a diet trial, and all dogs had been on a regular diet without administration of any immunosuppressive agents or antibiotics for at least 2 weeks before endoscopy. Final diagnoses included pancreatitis, megaesophagus protein-losing nephropathy, food-responsive enteropathy, hiatal hernia, or unknown.

Available tissue consisted of adequate endoscopically obtained biopsy specimens of the stomach (fundus, n = 30; antrum, n = 24), duodenum (n = 30), and colon (n = 10) that were formalin fixed and paraffin embedded. The original histopathology report for each dog provided information on 4 morphologic variables (ie, epithelial injury, crypt distension, lacteal dilatation, and mucosal fibrosis) and 4 inflammatory variables (intraepithelial lymphocytes, LP lymphocytes and plasma cells, LP eosinophils, and LP neutrophils) in accordance with the World Small Animal Veterinary Association guidelines.¹³ Each variable was scored by a veterinary pathologist (MJD) as: 0 = normal, 1 = mild, 2 = moderate, or 3 = marked, as previously described.¹³ Because architectural changes were limited, histopathological severity was quantified by the numerical score attributed to the inflammatory infiltration. In addition, the dominant inflammatory population was recorded and biopsy specimens were classified as containing only eosinophilic or lymphoplasmacytic and eosinophilic (referred to as mixed enteritis) inflammation. Based on this scoring system, 8 dogs were scored as having mild EE or mixed enteritis and 12 dogs were scored as having moderate EE or mixed enteritis.

2.2 | Histology and immunohistochemistry

Serial 4- μ m-thick sections were cut from each paraffin block. Section 1 was stained with H&E, whereas Sections 2 and 3 were immunolabeled with Epx mAb (Mayo Clinic, Scottsdale, Arizona) and normal mouse IgG (negative control, Sigma-Aldrich, St. Louis, Missouri), respectively, as previously described.¹⁵ Slides were

evaluated using an Olympus BX53 upright light microscope and photomicrographs were acquired using an Olympus DP73 camera and Olympus cellSens Software (Olympus, Center Valley, Pennsylvania).

2.3 | Quantification of eosinophils

Eosinophils were quantified in each H&E-stained and Epx mAb-labeled tissue section in a blinded fashion (IB). Several randomly selected sections were evaluated separately by an American College of Veterinary Pathologists Diplomate (DS) to ensure consistency in quantitation. For each case, the 5 largest biopsy tissue sections on the slide were evaluated for each organ. For each tissue section, eosinophils were manually quantified in contiguous $\times 400$ fields spanning the entire section (range, 10-25 fields, depending on the size of the section). Eosinophils were classified as either intact or degranulated. Degranulated eosinophils were identified based on immunopositive Epx staining in the extracellular space (ie, free cytoplasmic granules, extracellular matrix deposition of eosinophil secondary granule proteins, or both), which corresponded to an adjacent nucleus that fitted the morphologic criteria for an eosinophil (ie, hyperchromatic bilobed nucleus) as described previously.^{15,18} In the case of duodenum, the microscopic location of each cell was defined as either upper (villus) or lower LP (between the muscularis mucosae and crypts) and for the stomach the location was defined as either antrum or fundus. Degranulated eosinophils were quantitated only in duodenal biopsy specimens (not stomach and colon). The average number of eosinophils per field first was calculated for each region (ie, stomach [antrum and fundus], duodenum [upper and lower LP], and colon) and type (H&E [intact], Epx [intact], and Epx [degranulated]) combination for each dog and used for all further analyses.

2.4 | Statistical analysis

Samples from dogs diagnosed as having marked inflammation based on histopathological scoring were combined with those with moderate cellular infiltration as a single group in the statistical analysis. Visual inspection indicated that the data were not normally distributed, with substantial skew and several outlying points. To compare the 2 measurement types for intact eosinophils, H&E (intact) and Epx (intact), paired Wilcoxon tests were performed for each region separately. To compare the disease groups (control, EE, and mixed) and severity levels (control, mild, and moderate) for each duodenum region (upper LP and lower LP) and type (Epx only) combination, pairwise Wilcoxon tests were performed, with *P* values corrected for multiple comparisons within each region and type using the Bonferroni-Holm correction. Statistical analysis was performed using R Statistical Software (version 3.4.3). All tests were considered significant at a value of $P \leq .05$.

3 | RESULTS

3.1 | Evaluation of eosinophil infiltration by H&E staining versus Epx mAb immunolabeling

H&E-stained sections of the duodenum from dogs with intestinal inflammation (EE or mixed enteritis) disclosed the presence of a mixed cellular infiltrate consisting primarily of eosinophils or a mixture of

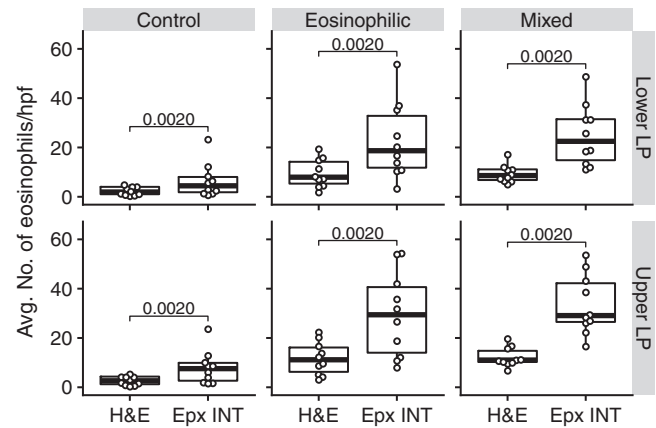


FIGURE 1 Quantitation of eosinophils in duodenal biopsy specimens by hematoxylin and eosin (H&E) staining and eosinophil peroxidase (Epx) immunolabeling. Average number of positively stained or labeled intact eosinophils per high-power field at $\times 400$ magnification in the upper and lower LP in serial duodenal sections from control dogs and dogs with either eosinophilic enteritis or mixed enteritis stained with H&E and Epx monoclonal antibody immunohistochemical, respectively

eosinophils, lymphocytes, and plasma cells. Duodenal sections of control dogs did not show any abnormal cellular infiltrates. The density of eosinophil infiltration in duodenal sections of these groups of dogs after H&E staining was quantified by manual counting and then compared with eosinophil numbers quantified after IHC with Epx mAb. The number of eosinophils detected per $\times 400$ microscopic field after Epx mAb IHC in both the upper and lower LP was significantly higher than that detected in H&E-stained sections in each of the groups in both regions (Figure 1). This finding was consistent in other regions of the GI tract (ie, colon and stomach [fundus and antrum]). Quantitative assessment of intact eosinophils detected by H&E staining and Epx mAb IHC for each region of the GI tract for individual dogs is shown in Figure 2. In all cases, the number of intact eosinophils detected after Epx mAb IHC was higher than that detected by H&E staining, thus demonstrating that routine H&E staining alone underrepresents the number of eosinophils present.

Although H&E staining detected only intact eosinophils in duodenal sections from dogs with eosinophilic or mixed inflammation, Epx IHC easily allowed identification of intact eosinophils based on the prominent dark red-brown color within intracellular membrane-bound secondary granules and as well as degranulated eosinophils with diffuse extracellular granule staining (Figure 3). This finding is consistent with our previous study using jejunal tissue collected at the time of necropsy examination from dogs with IBD in which Epx IHC detected both intact and degranulated eosinophils.¹⁵ Representative H&E-stained and Epx-labeled images showing the presence and distribution of eosinophils in the lower and upper LP of the duodenum of control dogs and dogs with EE or mixed enteritis are shown in Figure 4.

3.2 | Quantitative assessment of intact and degranulated eosinophils after Epx mAb labeling

Next, the number of intact and degranulated eosinophils in the upper and lower regions of the duodenal LP in dogs with EE and mixed

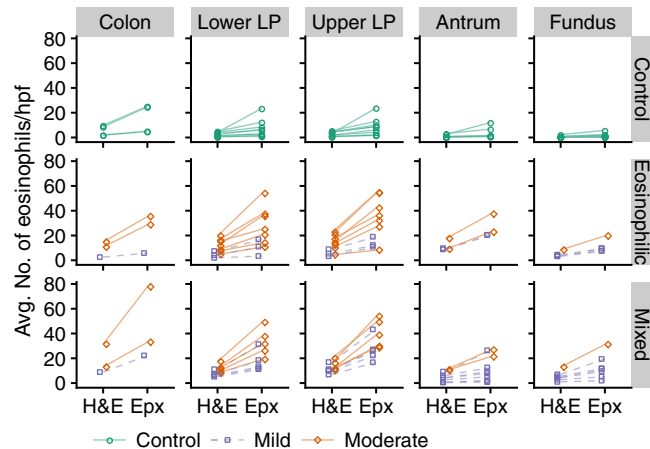


FIGURE 2 Quantitative assessment of intact eosinophils detected by hematoxylin and eosin (H&E) staining and eosinophil peroxidase (Epx) immunolabeling for different regions of the gastrointestinal tract. Average number of positively stained/labeled intact eosinophils per high-power field at $\times 400$ magnification in serial sections of colon, duodenum (upper LP and lower LP), and stomach (antrum and fundus) stained with H&E and Epx monoclonal antibody immunohistochemistry, respectively. Data for individual dogs in the control, eosinophilic (mild and moderate), and mixed (mild and moderate) enteritis groups are shown

enteritis and control dogs was quantified based on Epx IHC. A significantly higher number of intact and degranulated eosinophils was detected in the upper and lower LP of the samples from dogs with EE and mixed enteritis compared with the number of intact and degranulated eosinophils in these regions in control dogs. The number of intact and degranulated eosinophils in the upper and lower regions of the LP of dogs with EE and mixed enteritis was not significantly different from each other (Figure 5).

In terms of disease severity (EE and mixed enteritis combined), the number of intact eosinophils detected by Epx IHC was significantly higher in the upper and lower LP in dogs with mild and moderate disease compared with control dogs (Figure 6). Furthermore, the number of intact eosinophils in the upper and lower LP of dogs with

moderate disease was significantly higher than in dogs with mild disease. In the case of degranulated eosinophils, compared with control dogs, the number of these cells was significantly higher in the upper and lower LP in dogs with moderate disease and only in the upper LP for dogs with mild disease. No significant difference in the number of degranulated eosinophils was noted between dogs with mild and moderate disease in the upper or lower LP.

4 | DISCUSSION

Eosinophils are present in the healthy human and canine intestine in variable number.^{14,16,17} Abnormal accumulation of eosinophils in the intestine in the absence of other underlying causes (eg, parasitic infections) is a characteristic feature of EGID, including IBD.^{4,19} Staining of duodenal biopsy specimens with H&E for histopathological evaluation is routinely performed during diagnosis of IBD in dogs.^{13,14} In a previous study, we determined that unlike H&E staining, which detects only intact eosinophils, Epx IHC allows reliable identification of intact and degranulated eosinophils in jejunal tissue (collected at necropsy) of dogs with IBD, and potentially could allow quantitative analysis of eosinophils in the small intestine.¹⁵ In the current study, we have extended these findings to endoscopically obtained biopsy specimens from the stomach, duodenum, and colon of dogs with GI inflammation (EE or mixed enteritis) and confirmed the utility of this technique in eosinophil identification and quantitation using clinically relevant samples.

Evaluation of serial sections of duodenal biopsy specimens from control dogs and dogs with either EE or mixed enteritis that were stained with H&E and labeled with Epx mAb indicated that Epx mAb-based IHC consistently results in detection of significantly higher numbers of intact eosinophils relative to H&E staining. A similar finding was observed on evaluation of serially stained sections (using H&E and Epx mAb) from the stomach (antrum and fundus) and colon of these dogs. These findings suggest that quantification of eosinophil infiltration based on H&E staining is likely to be an underrepresentation of the

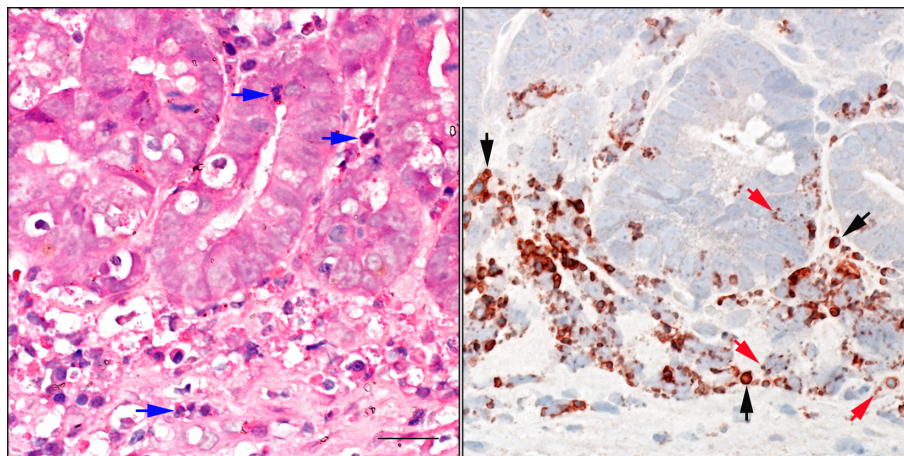


FIGURE 3 Eosinophil degranulation assessed by eosinophil peroxidase (Epx) immunohistochemistry (IHC). The presence of intact eosinophils is noted in hematoxylin and eosin (H&E)-stained (left) and Epx-labeled (right) sections. Blue arrows in H&E-stained section indicate intact eosinophils. The fine detail of eosinophil granules within the cytoplasm of intact eosinophils (black arrows) and in the extracellular matrix (red arrows) indicating degranulation is noted only after Epx IHC. Scale bar = 20 μ m

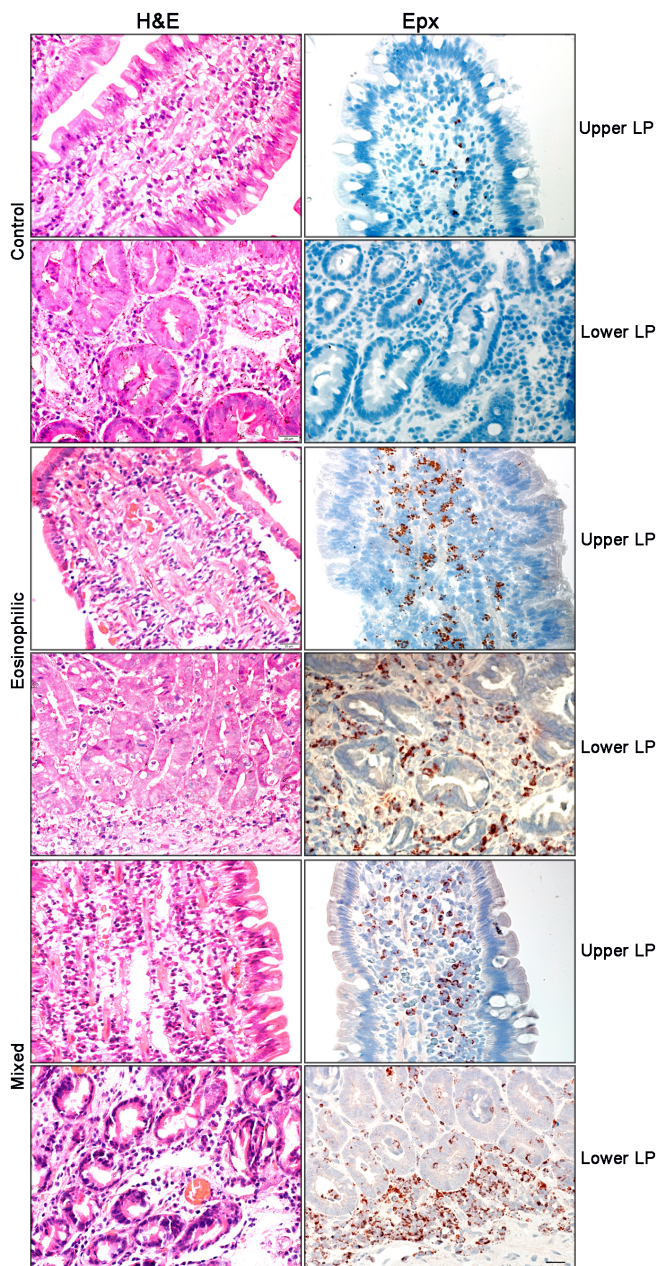


FIGURE 4 Eosinophils in duodenum of control, eosinophilic enteritis, and mixed enteritis groups of dogs by hematoxylin and eosin (H&E) staining and eosinophil peroxidase (Epx) labeling. Distribution of eosinophils within the upper and lower lamina propria (LP) of control, eosinophilic, and mixed enteritis groups of dogs. H&E-stained sections are on the left, and Epx IHC sections on the right. Note the ease in observing eosinophils in Epx-labeled versus H&E-stained sections in the upper and lower LP within each group. Scale bar = 20 μ m

magnitude of inflammation. Previous studies using esophageal tissue sections from human patients with eosinophilic esophagitis have shown that Epx mAb-based IHC detects a 4-fold higher number of eosinophils compared with H&E staining and potentially enables differentiation of difficult-to-diagnose eosinophilic esophagitis and gastroesophageal reflux disease.²⁰ In another study using lung biopsy specimens from patients with acute lung injury, a >40-fold higher sensitivity in the detection of eosinophils was achieved by IHC with Epx mAb relative to H&E-stained sections, resulting in the identification of higher numbers

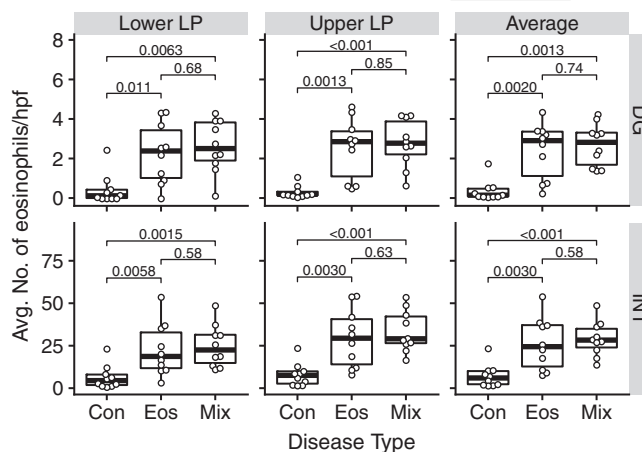


FIGURE 5 Quantitation of intact and degranulated eosinophils in duodenal biopsy specimens based on disease type. Average number of positively labeled intact and degranulated cells per high-power field at $\times 400$ magnification in the upper and lower lamina propria of control (Con) dogs and dogs with eosinophilic enteritis (Eos) or mixed enteritis (Mix) after eosinophil peroxidase monoclonal antibody immunohistochemical

of eosinophils in these patients compared with controls in whom differences using H&E staining alone were not significant.¹⁸ Similar findings were observed in canine skin in which Epx mAb IHC detected significantly higher numbers of eosinophils as compared to H&E staining.²¹ Based on our findings of enhanced detection of intact eosinophils by Epx mAb-based IHC relative to H&E staining, this method could be used to accurately assess eosinophilic inflammation in formalin-fixed and paraffin-embedded tissues from the duodenum, stomach and colon to improve diagnostic sensitivity for EGID in dogs.

Eosinophilic gastrointestinal disease often is caused by food allergen-driven Th2 inflammation that is likely to be responsible for the predominant infiltration of eosinophils.²² When activated,

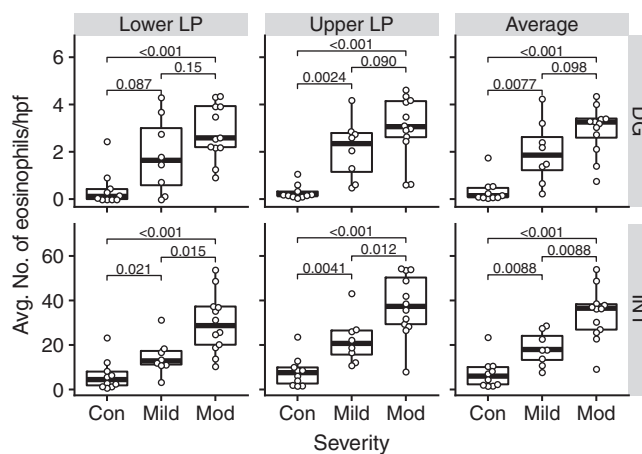


FIGURE 6 Quantitation of intact and degranulated eosinophils in duodenal biopsy specimens based on disease severity. Average number of eosinophil peroxidase-positive intact and degranulated cells per high-power field at $\times 400$ magnification in the upper and lower lamina propria from control (Con) dogs and dogs with mild or moderate (Mod) disease (eosinophilic and mixed enteritis groups combined in this analysis) is shown. Histopathological severity is based on the cumulative numerical score determined according to World Small Animal Veterinary Association guidelines

eosinophils can secrete various preformed inflammatory cytokines such as interleukin (IL)-4, IL-5, IL-10, IL-12, and IL-13 as well as growth factors (eg, transforming growth factor [TGF]- β), chemokines (regulated on activation, normal T cell expressed and secreted and eotaxin-1), lipid mediators (platelet-activating factor and leukotriene C4), and cytotoxic granule proteins.²³ These inflammatory mediators are known to induce various effects such as up-regulation of adhesion molecules to modulate cellular trafficking and recruitment, mucus secretion, tissue remodeling, and impairment of barrier integrity,^{24,25} which can contribute to disease progression. For example, eosinophil-derived TGF- β is linked to tissue remodeling and induction of the extracellular matrix protein periostin in patient biopsy specimens which increases eosinophil infiltration in the mucosal layer, thus facilitating disease pathogenesis.^{26,27} Furthermore, as indicated above, granule proteins such as eosinophil cationic protein, Epx, and major basic protein released by activated eosinophils during inflammation can contribute to tissue damage (alter barrier function) and dysfunction (diarrhea with bleeding).⁹⁻¹² Deficiency of eotaxin-1, the eosinophil-specific chemokine, or blockade of its receptor (CCR3) resulting in depletion of eosinophils has been shown to attenuate inflammation in experimental models of IBD,^{9,28} thus supporting the overall importance of eosinophil involvement in EGID.

One of the limitations of H&E staining is its inability or poor ability to detect degranulated eosinophils.¹⁵ Studies in patients with different forms of GI eosinophilic inflammation have shown increased numbers of activated eosinophils and increased concentrations of extracellular granule protein, suggesting that these cells may be important players in promoting and mediating inflammation in the intestinal mucosa.²⁹⁻³² Therefore, it is important to be able to reliably detect and quantify both intact and degranulated eosinophils in order to better understand their involvement and contribution to disease pathogenesis. In our previous study, enumeration of eosinophils after Epx mAb IHC indicated the presence of increased numbers of degranulated eosinophils in the upper and lower LP of the jejunum in dogs diagnosed with IBD compared with control dogs and dogs that had been treated for IBD.¹⁵ The current study confirms this observation in the duodenum of dogs with EE or mixed enteritis. In both cases, the number of degranulated eosinophils was significantly higher than in control dogs. The presence of an increased number of degranulated eosinophils in the upper and lower LP may be a previously unrecognized feature of IBD. Previous studies indicate that eosinophil granule proteins (eg, eosinophil cationic protein, major basic protein) released by activated eosinophils contribute to tissue damage and inflammation during GI disorders and may be indicative of active ongoing disease.^{3,10,30,33,34}

Interestingly, in the current study, tissue from dogs with EE and mixed enteritis had similar numbers of intact and degranulated eosinophils after Epx mAb IHC, suggesting that eosinophils are an important cellular component of disease pathogenesis in both of these histologic forms of IBD. Eosinophil peroxidase mAb-based IHC clearly differentiates between mild and moderate disease based on the number of intact eosinophils in the lower and upper LP. Furthermore, a consistently higher number of degranulated eosinophils was found in duodenal tissue from dogs with moderate disease compared to dogs with mild disease, although it did not reach statistical significance. Although

one would expect degranulation to correlate with severity, it is still unclear how many eosinophils must degranulate to increase disease severity, and our study group may not have been large enough (ie, small sample size) to establish a statistically significant difference. Furthermore, discordance may exist between histological changes and severity of disease, and a disease activity index was not calculated for these dogs. Similarly, in our previous study a significant difference in the number of intact eosinophils was noted between dogs with IBD (untreated) and treated IBD dogs, albeit only in the upper LP.¹⁵ Based on the observation that H&E staining resulted in an underrepresentation of the number of eosinophils (intact) relative to Epx mAb IHC not only in the duodenum but also in the stomach and colon in the current study, it is possible that evaluation of biopsy specimens by H&E stain only may result in underdiagnosis of disease as well as severity of disease in dogs with EGID.

A limitation of our study is that the control group consisted of dogs with various GI signs but with histologically normal intestinal biopsy specimens and were not healthy controls. Additionally, information regarding the diets that the dogs were fed was limited and therefore could not be controlled in the study. Evaluating the correlation of Epx mAb IHC to treatment outcome (ie, diet), can be the basis of a future investigation. Overall, we have demonstrated that detection of eosinophils by IHC with Epx mAb provides a more accurate and reliable method for detection of tissue-infiltrating eosinophils in duodenal biopsy specimens for the diagnosis of EGIDs such as IBD in dogs. This technique can be used as an alternative or additional diagnostic tool in assessment of dogs with IBD. Importantly, Epx mAb-based IHC allows for the assessment of eosinophil degranulation and thus enables a better understanding of the role of eosinophils and their granule proteins in the pathogenesis of IBD in dogs.

CONFLICT OF INTEREST DECLARATION

Authors declare no conflict of interest.

OFF-LABEL ANTIMICROBIAL DECLARATION

Authors declare no off-label use of antimicrobials.

INSTITUTIONAL ANIMAL CARE AND USE COMMITTEE (IACUC) OR OTHER APPROVAL DECLARATION

Authors declare no IACUC or other approval was needed.

ORCID

Savita P. Rao  <https://orcid.org/0000-0001-9763-199X>

REFERENCES

1. Samiullah BH, Sohail U. Eosinophilic disorders of the gastrointestinal tract. *Prim Care* 2016;43:495-504.
2. Collins MH, Capocelli K, Yang G-Y. Eosinophilic gastrointestinal disorders pathology. *Front Med*. 2018;4:261.
3. Powell N, Walker MM, Talley NJ. Gastrointestinal eosinophils in health, disease and functional disorders. *Nat Rev Gastroenterol Hepatol*. 2010;7:146-156.

4. Sattasathuchana P, Steiner JM. Canine eosinophilic gastrointestinal disorders. *Anim Health Res Rev.* 2014;15:76-86.
5. Marichal T, Mesnil C, Bureau F. Homeostatic eosinophils: characteristics and functions. *Front Med.* 2017;4:101.
6. German AJ. Small intestine. In: Washabau RJ, Day MJ, eds. *Canine and Feline Gastroenterology.* Saint Louis, MO: W.B. Saunders; 2013: 695-699.
7. Haas E, Rutgen BC, Gerner W, et al. Phenotypic characterization of canine intestinal intraepithelial lymphocytes in dogs with inflammatory bowel disease. *J Vet Intern Med.* 2015;28:1708-1715.
8. Davoine F, Lacy P. Eosinophil cytokines, chemokines, and growth factors: emerging roles in immunity. *Front Immunol.* 2014;5:570.
9. Forbes E, Murase T, Yang M, et al. Immunopathogenesis of experimental ulcerative colitis is mediated by eosinophil peroxidase. *J Immunol.* 2004;172:5664-5675.
10. Furuta GT, Nieuwenhuis EES, Karhausen J, et al. Eosinophils alter colonic epithelial barrier function: role for major basic protein. *Am J Physiol Gastrointest Liver Physiol.* 2005;289:G890-G897.
11. Wedemeyer J, Vosskuhl K. Role of gastrointestinal eosinophils in inflammatory bowel disease and intestinal tumours. *Best Pract Res Clin Gastroenterol.* 2008;22:537-549.
12. Hogan SP, Waddell A, Fulkerson PC. Eosinophils in infection and intestinal immunity. *Curr Opin Gastroenterol.* 2013;29:7-14.
13. Day MJ, Bilzer T, Mansell J, et al. Histopathological standards for the diagnosis of gastrointestinal inflammation in endoscopic biopsy samples from the dog and cat: a report from the World Small Animal Veterinary Association Gastrointestinal Standardization Group. *J Comp Pathol.* 2008;138:S1-S43.
14. Washabau RJ, Day MJ, Willard MD, et al. WSAVA International Gastrointestinal Standardization Group. Endoscopic, biopsy, and histopathologic guidelines for the evaluation of gastrointestinal inflammation in companion animals. *J Vet Intern Med.* 2010;24:10-26.
15. Bastan I, Robinson NA, Ge XN, et al. Assessment of eosinophil peroxidase as a potential diagnostic and prognostic marker in dogs with inflammatory bowel disease. *Am J Vet Res.* 2017;78:36-41.
16. Rothenberg ME, Mishra A, Brandt EB, et al. Gastrointestinal eosinophils. *Immunol Rev.* 2001;179:139-155.
17. German AJ, Hall EJ, Day MJ. Analysis of leucocyte subsets in the canine intestine. *J Comp Pathol.* 1999;120:129-145.
18. Willetts L, Parker K, Wesselius LJ, et al. Immunodetection of occult eosinophils in lung tissue biopsies may help predict survival in acute lung injury. *Resp Res.* 2011;12:116.
19. Mehta P, Furuta GT. Eosinophils in gastrointestinal disorders- eosinophilic gastrointestinal diseases, celiac disease, inflammatory bowel diseases and parasitic infections. *Immunol Allergy Clin North Am.* 2015;35: 413-437.
20. Protheroe C, Woodruff SA, de Petris G, et al. A novel histologic scoring system to evaluate mucosal biopsies from patients with eosinophilic esophagitis. *Clin Gastroenterol Hepatol.* 2009;7:749-755.
21. Gomes P, Torres SM, Plager DA, et al. Comparison of three staining methods to identify eosinophils in formalin-fixed canine skin. *Vet Dermatol.* 2013;24:323-328.
22. Cianferoni A, Spergel JM. Eosinophilic esophagitis and gastroenteritis. *Curr Allergy Asthma Rep.* 2015;15:58.
23. Hogan SP. Functional role of eosinophils in gastrointestinal inflammation. *Immunol Allergy Clin North Am.* 2009;29:129-140.
24. Rothenberg ME, Hogan SP. The eosinophil. *Annu Rev Immunol.* 2006; 24:147-174.
25. Suzuki T. Regulation of intestinal epithelial permeability by tight junctions. *Cell Mol Life Sci.* 2013;70:631-659.
26. Abonia JP, Marc ER. Eosinophilic esophagitis: rapidly advancing insights. *Annu Rev Med.* 2012;63:421-434.
27. Blanchard C, Mingler MK, McBride M, et al. Periostin facilitates eosinophil tissue infiltration in allergic lung and esophageal responses. *Mucosal Immunol.* 2008;1:289-296.
28. Masterson JC, EiN MN, Jedlicka P, et al. CCR3 blockade attenuates eosinophilic ileitis and associated remodeling. *Am J Pathol.* 2011;179: 2302-2314.
29. Bischoff SC, Mayer J, Nguyen Q-T, et al. Immunohistological assessment of intestinal eosinophil activation in patients with eosinophilic gastroenteritis and inflammatory bowel disease. *Am J Gastroenterol.* 1999;94:3521-3529.
30. Carlson M, Raab Y, Peterson C, et al. Increased intraluminal release of eosinophil granule proteins EPO, ECP, EPX, and cytokines in ulcerative colitis and proctitis in segmental perfusion. *Am J Gastroenterol.* 1999; 94:1876-1883.
31. Alexandre L, Vivek C, Tatiana B, et al. Inflammatory bowel disease detection and monitoring by measuring biomarkers in non-invasively collected colorectal mucus. *J Gastroenterol Hepatol.* 2017;32:992-1002.
32. Smyth CM, Akasheh N, Woods S, et al. Activated eosinophils in association with enteric nerves in inflammatory bowel disease. *PLoS One* 2013;8:e64216.
33. Talley NJ, Kephart GM, McGovern TW, et al. Deposition of eosinophil granule major basic protein in eosinophilic gastroenteritis and celiac disease. *Gastroenterology* 1992;103:137-145.
34. Kristjansson G, Venge P, Wanders A, et al. Clinical and subclinical intestinal inflammation assessed by the mucosal patch technique: studies of mucosal neutrophil and eosinophil activation in inflammatory bowel diseases and irritable bowel syndrome. *Gut* 2004;53:1806-1812.

How to cite this article: Bastan I, Rendahl AK, Seelig D, et al. Assessment of eosinophils in gastrointestinal inflammatory disease of dogs. *J Vet Intern Med.* 2018;32:1911-1917. <https://doi.org/10.1111/jvim.15310>